

## Research Article

# The occurrence of two species of the genus *Myxobolus* Bütschli, 1882 (Myxozoa: Myxosporea) for the first time in Iraq from freshwater fishes

Rana Shalal and Kefah Naser Abdul–Ameer

Department of Biology, College of Education for Pure Science (Ibn Al–Haitham),  
University of Baghdad, Baghdad, Iraq

### Article Info

#### Article history:

Received 1-4-2023

Received in revised form  
12-4-2023

Accepted 21-6-2023

Available online 23- 7-2023

Keywords: *Myxobolus*  
*dermatoulcerans*,  
*Myxobolus*  
*pharyngobranchialis* ,  
*Cyprinus carpio*, *Planiliza*  
*abu*, Iraq.

### Abstract

Two species of myxosporean species are recorded for the first time in Iraq in the present paper from two freshwater fishes from fish markets in Baghdad city. The first species, *Myxobolus dermatoulcerans* Stilwell, Stilwell, Camus, Ware, Rosser & Griffin, 2020 was recorded from the gills of the common carp *Cyprinus carpio* Linnaeus, 1758 and the second species, *M. pharyngobranchialis* Rocha, Casal, Alves, Antunes, Rodrigues & Azevedo, 2019 was recorded from the gills of the mugilid fish *Planiliza abu* (Heckel, 1843). The descriptions and measurements of these parasites and their illustrations were given.

## Introduction

Within the Myxosporidia, *Myxobolus* Butschli, 1882 is the biggest genus with about 2600 genuine species were listed by (1) many more species have subsequently been described. Although a small number of species have already been discovered parasitizing amphibians and reptiles, these parasites mostly affect fish.

Myxozoans are highly specialized metazoan parasites with a very diverse host range that live on aquatic hosts. Multicellular spores with polar capsules carrying extrudable polar filaments distinguish this varied group of organisms. Since several of these species cause significant disease outbreaks in farmed fish species in both freshwater and marine habitats, interest in this group has increased along with aquaculture development (2). The degree of host specificity that each fish-parasitic myxosporean exhibits varies. This genus' spores are tiny, multicellular, and appear as pseudocysts between or within tissues (histozoic) (coelozoic). These

## Material and Methods

Throughout January and March of 2022, a total of 25 samples of common carp, *C. carpio* and *L. abu*, were from three different fish markets, Baghdad city. Fish were tested in the lab for any possible myxozoan infection. In the laboratory, fish were examined for myxozoan infection. Fresh smears of the external parts (gills and surface of the body) and all internal organs (intestine, gallbladder, kidneys, and liver) of fishes were prepared and microscopically examined macroscopically for visible plasmodia (vegetative stages). Some of the fresh spores were examined immediately after they were removed from cysts, the spores were immediately photographed in a live state by

## Results

The results revealed the presence of two myxosporean species which belonged to the

pseudocysts might appear as a white to pale yellow bump on the body's affected areas and can be noticed with the naked eye (3 & 4).

There was 16 distinct species of fish examined by (5) from various areas in Iraq and found 16 different parasitic species. Among them, he noted the presence of three myxozoan parasites, *Myxobolus muelleri*, *M. multiplicatus* (reported as *Myxosoma multiplicata*), and *M. oviformis*. According to a recent checklist of *Myxobolus* species infecting fish in Iraq (6), there are currently 97 species of this genus known from 43 different fish species, along with some species that have not yet been discovered. Recently three species of *Myxobolus* were reported by (7) in floating cage fishes in Iraq till the end of 2021.

The current work reports the first occurrence of a new host for these two parasites in Iraq which found in the gills of *C. carpio* and *L. abu*.

using a Camera Lucida, and then drawn by using a digital Camera and measured. For permanent specimens, the spores were stained with Giemsa solution for approximately 25 to 30 minutes, washed in water, and desiccated after being fixed in 100% methanol for five minutes (8). Spores were described and measured according to the guidelines of (9). All measurements are given here in  $\mu\text{m}$  as minimum-maximum (mean) values. Parasites were referred to by their scientific name according to (10). All recordings of *Myxobolus* species in fishes of Iraq were reviewed with the index catalogue of parasites and disease agents of fishes of Iraq by correspondence via his e-mail (11).

genus *Myxobolus* Butschli, 1882. The following is a brief account on their description and measurements (in  $\mu\text{m}$ , based on five specimens for each parasite species).

***Myxobolus dermatoulcerans* Stilwell, Stilwell, Camus, Ware, Rosser & Griffin, 2020**

Spores of this parasite were found in the smears taken from the skin and gills of the common carp *Cyprinus carpio* Linnaeus, 1758 with a prevalence of 12 %. The following is an account of its description and measurements as shown in Fig. (1).

Spores are large in size, elongated, rounded to tapering anterior end, and rounded posterior, the sutural edge markings are absent and there is no intracapsular process. Length of spores 15.9-16.7 (16.3), width 7.8-8.4 (8.1), and thickness in sutural view 6.0-6.6 (6.3). Polar capsules elongate, equal in size, placed posteriorly from the tip of the spore, length 7.4-8.2 (4.4) and width 2.5-3.3 (2.9). The sporoplasm is granular.

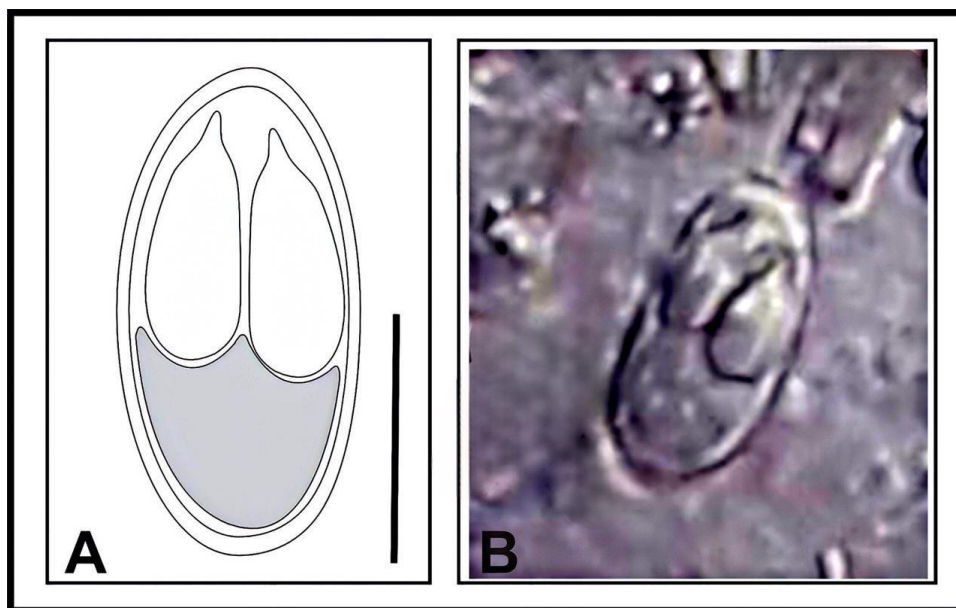


Fig. (1): *Myxobolus dermatoulcerans*: A- Diagrammatic drawing (Scale bar = 8  $\mu\text{m}$ ), Photomicrograph (400 x).

***Myxobolus pharyngobranchialis***  
**Rocha, Casal, Alves, Antunes,**  
**Rodrigues & Azevedo, 2019**

Spores of this parasite were recorded from the gills of the mugilid fish *Planiliza abu* (Heckel, 1843) with a prevalence of 8 %. The following is an account of its description and measurements as shown in Fig. (2).

Spores ellipsoidal in valvular and sutural view with six to eight markings near the suture line and there is no intracapsular process. Length of spores 8.8-9.4 (16.3), width 7.8-8.5 (8.1) and thickness in sutural view 4.8-5.4 (6.3). Polar capsules Pyriform, equally sized, length 4.4-5.0 (4.4) and width 2.8-3.4 (2.9). sporoplasm is granular.

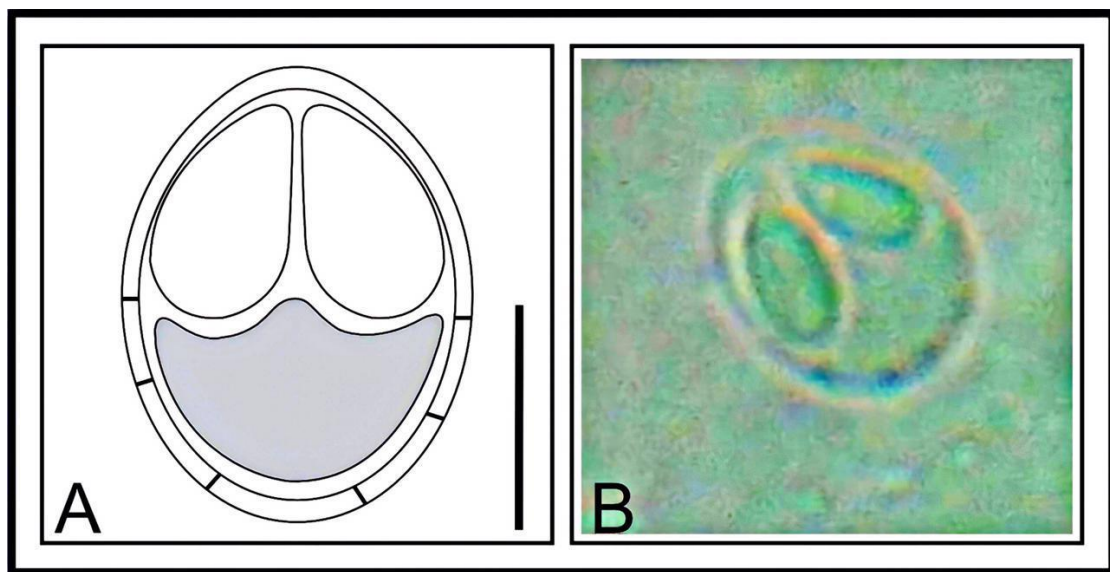


Fig. (2): *Myxobolus pharyngobranchialis*: A- Diagrammatic drawing (Scale bar = 4.5  $\mu$ m), Photomicrograph (400 x).

## Discussion

The descriptions and measurements of the present *M. dermatoulcerans* are in agreement with those reported by (12) in the skin of red-bellied piranha, *Pygocentrus nattereri* Kner from Peru. The descriptions and measurements of the present *M. pharyngobranchialis* are showed agreement with the same parasite reported by (13), in the denticulate pharyngeal pad of the pharyngobranchial organ of the thinlip grey mullet *Chelon ramada* from the Minho River in Portugal.

In Iraq, there was two species of *Myxobolus* was documented by Herzog (5) which are *M. muelleri* and *M. oviformis*. Subsequently, several studies conducted on fish parasites from various Iraqi water bodies revealed that several species of this genus were recorded. So far, a total of 105 species of *Myxobolus* as well as some unidentified species of that genus were reported from fishes of Iraq, including 19 species were reported from the cyprinid fish *Cyprinus carpio* these are: *M. cyprinicola* Reuss, 1906; *M. dispar* Thélohan, 1895; *M. dogieli* Bykhovskaya-Pavlovskaya & Bykhovski, 1940; *M. drjagini* (Akhmerov, 1954) Landsberg & Lom, 1991; *M. gigi* (Fujita, 1927) Shul'man, 1962; *M. insignis* Eiras, Malta, Varella, Pavanelli, 2005; *M. intrachondrealis* Molnár, 2000; *M. koi* Kudo, 1919; *M. muelleri* Bütschli, 1882; *M. musculi* Keysselitz, 1908; *M. oviformis* Thélohan, 1892; *M. parvus* Shul'man, 1962; *M. pfeifferi* Thélohan, 1895; *M. poljanski* Shul'man, 1962; *M. punctatus* Chaudhuri & Chakravarty, 1970; *M. pyramidis* Chen in Chen & Ma, 1998; *M. sphaericus* (Fujita, 1924) Landsberg & Lom, 1991; *M. sprostoni*

Shul'man, 1962; *M. squamae* Keysselitz, 1908 and *Myxobolus* spp.

Among *Myxobolus* species which so far reported from fishes of Iraq, 27 species were documented from the mugilid fish *Planiliza abu* which are: *Myxobolus amurensis* Akhmerov, 1960; *M. bizerti* Bahri & Marques, 1996; *M. bramae* Reuss, 1906; *M. branchialis* (Markewitsch, 1932) Landsberg & Lom, 1991; *M. chuatsi* (Dogiel & Akhmerov in Akhmerov, 1960) Landsberg & Lom, 1991; *M. cyprinicola* Reuss, 1906; *M. dermatobius* (Ishii, 1915) Landsberg & Lom, 1991; *M. dispar* Thélohan, 1895; *M. dogieli* Bykhovskaya-Pavlovskaya & Bykhovski, 1940; *M. drjagini* (Akhmerov, 1954) Landsberg & Lom, 1991; *M. ellipsoides* Thélohan, 1892; *M. episquamalis* Egusa, Maeno & Sorimachi, 1990; *M. infundibulatus* Donec & Kulakovskaya, in Shulman, 1962; *M. karelicus* Petrushevski, 1940; *M. macrocapsularis* Reuss, 1906; *M. mesopotamiae* Molnár, Masoumian & Abbasi, 1996; *M. muelleri* Bütschli, 1882; *M. musculi* Keysselitz, 1908; *M. nemacheili* Weiser, 1949; *M. niei* Shul'man, 1962; *M. oviformis* Thélohan, 1892; *M. parvus* Shul'man, 1962; *M. rotundus* Nemeček, 1911; *M. sandrae* Reuss, 1906; *M. sphaericus* (Fujita, 1924) Landsberg & Lom, 1991; *M. sprostoni* Shul'man, 1962 and *Myxobolus* spp. (Mhaisen, 2023).

With the present record of *M. dermatoulcerans*, the number of *Myxobolus* species from cyprinid fish *Cyprinus carpio* of Iraq so far reaches 20 species, and the number of *Myxobolus* species from the mugilid fish *Planiliza abu* of Iraq so far reaches 28 species with the present record *M. pharyngobranchialis*.

## Conclusion

1- The current work reports the first occurrence of a new host for two parasites in Iraq:

*Myxobolus dermatoulcerans* Stilwell, Stilwell, Camus, Ware, Rosser & Griffin, 2020 from the gills of the common carp *Cyprinus carpio* Linnaeus, 1758

*M. pharyngobranchialis* Rocha, Casal, Alves, Antunes, Rodrigues & Azevedo,

- 2019 was recorded from the gills of the mugilid fish *Planiliza abu* (Heckel, 1843).
- 2- With the present record of these parasites, the number of *Myxobolus* species from cyprinid fish *C. carpio* of Iraq so far reaches 20 species.
- 3- The number of *Myxobolus* species from the mugilid fish *P. abu* reaches 28 species with the present record *M. pharyngobranchialis*.

## Acknowledgement

Thanks and appreciation to Prof. Dr. Furhan T. Mhaisen for providing necessary

information concerning the records of *Myxobolus* species so far known from *C. carpio* and *Planiliza abu* in his index-catalogue of parasites and disease agents of fishes of Iraq.

## References

1- Okamura B, Hartigan A, Naldoni J. Extensive uncharted biodiversity: the parasite dimension. *Integrative and Comparative Biology*. 2018 Dec 1;58(6):1132-45.

2- Fiala I, Bartošová P. History of myxozoan character evolution on the basis of rDNA and EF-2 data. *BMC evolutionary biology*. 2010 Dec;10(1):1-3.

3- Kaur H, Singh R. Observation on one new species of the genus *Myxobolus* (Myxozoa: Myxosporae: Bivalvulida) and redescription of *Myxobolus magauddi* (Bajpai, 1981) Landsberg and Lom, 1991 recorded from freshwater fishes of Kanjali Wetland of Punjab (India). *Proc Natl Congr Parasitol*. 2008:75-9.

4- Ahmad I, Ahmed I, Reshi QM, Jan K, Gupta A, Dar SA, Molnár K, Kaur H, Malla BA, Andrabi SM. Morphological, histopathological and molecular characterization of *Myxobolus szekelyianus* n. sp. (Cnidaria: Myxosporae: Myxobolidae) causing acute gill disease in *Schizothorax esocinus* (Heckel, 1838) from River Jhelum of Kashmir Himalayan region, India. *Aquaculture Research*. 2021 Dec;52(12):6537-49.

5- Herzog, P.H. Untersuchungen über die parasiten der süßwasserfische des Irak. *Arch. Fischereiwiss.*, 1969 20(2/3): 132-147.

6- Mhaisen FT, Al-Jawda JM. Checklists of the species of *Myxobolus* Bütschli, 1882 (Cnidaria: Myxozoa: Myxobolidae) from fishes of Iraq. *Biol. Appl. Environ. Res*. 2020; 4(2):127-66.

7-Mhaisen FT. Checklists of Carp Parasites in Floating Cages of Iraq. *Iraqi Journal of Aquaculture*. 2022;19(2):140-66.

8- Saha M, Bandyopadhyay PK. Parasitological and histological analysis of a new species of the genus *Thalohanellus* and description of a myxozoan parasite (Myxosporae: Bivalvulida) from cultured ornamental goldfish, *Carassius auratus* L. *Aquaculture Reports*. 2017 Nov 1;8:8-15.

9- Lom J, Arthur JR. A guideline for the preparation of species descriptions in Myxosporae. *Journal of Fish Diseases*. 1989 Mar;12(2):151-6.

10- Eiras JC, Cruz CF, Saraiva A, Adriano EA. Synopsis of the species of *Myxobolus* (Cnidaria, Myxozoa, Myxosporae) described between 2014 and 2020. *Folia Parasitologica*. 2021 May 25.

11- Mhaisen, F.T. (2023). Index-catalogue of parasites and disease agents of fishes of Iraq (Unpublished: [mhaisenft@yahoo.co.uk](mailto:mhaisenft@yahoo.co.uk)).

12- Stilwell JM, Stilwell NK, Camus AC, Ware C, Rosser TG, Griffin MJ. Necroulcerative dermatitis associated with *Myxobolus dermatoulcerans* n. sp. (Cnidaria: Myxobolidae) in red-bellied piranha,

*Pygocentrus nattereri* Kner (Characiformes: Serrasalminidae), from Peru. Systematic Parasitology. 2020 Dec; 97:649-59.

13- Rocha S, Casal G, Alves Â, Antunes C, Rodrigues P, Azevedo C. Myxozoan

biodiversity in mullets (Teleostei, Mugilidae) unravels hyperdiversification of *Myxobolus* (Cnidaria, Myxosporea). Parasitology research. 2019 Dec;118:3279-305.