



## A Review of Lip Print as A Tool in Forensic Dentistry

Tamara A. Anai <sup>(1)</sup>

Adnan Abd Alhameed Sulaiman <sup>(2)</sup>

Yasir Nader Hussein <sup>(3)</sup>

<sup>1,2,3</sup> College of Dentistry, Tikrit University, Tikrit, Iraq

### Article Info:

#### -Article History:

-Received: 13/7/2021

-Accepted: 22/8/2021

-Available Online:

Dec, 2021

**Keywords:** Forensic identification, forensic dentistry, grooves, lip print, Cheiloscopy.

#### Corresponding Author:

**Name:** Tamara Afif Anai

**E-mail:**

[tamsamka@tu.edu.iq](mailto:tamsamka@tu.edu.iq)

**Tel:** 07707328026

#### Affiliation:

(1) Asst. Lec., Department of Basic Science, College of Dentistry, Tikrit University, Tikrit, Iraq

### Abstract

**Background:** Forensic dentistry requires interdisciplinary knowledge since the data obtained from the oral cavity can contribute to identify an individual or provide the information needed in a legal process. Identification is a major problem facing forensic practitioners, DNA and fingerprints are highly useful but sometimes are not easily collected from the crime scene. Lip print could be useful in this field the lip prints are unique and distinguishable for every individual like fingerprints. The external surface of lips has many elevations and depressions forming a characteristic pattern called lip prints, examination of which is known as Cheiloscopy. However, there are many well-known implanted methods of human identification. **Historical Background:** The biological phenomenon of systems of grooves on the red part of human lips was first noted by anthropologists, Fischer was the first to describe it in 1902. The use of lip prints in personal identification was first recommended in France by Edmond Locard. **Conclusion:** This literature search covering a part of identifying a person using lip print, lip prints may also be used in detection work, being the source of criminalistic information. A lip print at the scene of a crime can be a basis for conclusions as to the character of the event, the number of the people involved, sexes, cosmetics used, habits, occupational traits, and the pathological changes of lips themselves.

## Introduction:

Lip prints have been with us since the beginning of man. Like the prints on a person's finger, palm, and foot in that individual characters are used for identification, unlike fingerprints however lips also possess grooves that can be classified into various types for identification purposes, though lip prints

have not been as popular. Biometrical methods of human identification have gained much attention recently, mainly because they easily deal with most problems of traditional identification is identified in biometrics human identification systems users are identified by who they are, not by something they

must remember or carry with them <sup>(1)</sup>. Forensic dentistry involves the processing, review, evaluation, and presentation of dental evidence with the purpose of contributing scientific and objective data in legal processes. Forensic dentists require knowledge encompassing several disciplines since the dental records obtained can identify an individual or afford the information needed by the authorities to establish neglect, fraud, or abuse <sup>(2)</sup>. Dental identification can have three different applications <sup>(3)</sup>:

(a) Comparative identification, in which the postmortem dental records are compared with the antemortem records of an individual to establish whether both records correspond to the same person.

(b) The obtainment of dental information to narrow the search for an individual when the antemortem records are not available and there are no possible data referred to the identity of the subject.

(c) Identification of victims following mass disasters or catastrophes.

Traditionally, comparisons have been made between postmortem dental records and the antemortem (living) records (presence of dental fillings, endodontic treatments, crowns or bridges, radiological studies to verify the clinical findings, the presence of malocclusions or dental fractures, etc.) to determine whether both records correspond to the same individual. Such techniques are now less widely used, however, due to the increased efficiency and availability of molecular biological techniques <sup>(4)</sup>. However, 'human lip recognition' also known as Cheiloscopy, is one of the most interesting emerging fields which find its roots in criminal and forensic practices <sup>(5-7)</sup>. Previous studies have shown to establish the fact that lip prints can positively distinguish individuals and hence have potential use in human identification <sup>(8,9)</sup>. The term "Cheiloscopy" is derived from the Greek words cheilos meaning 'lips' and e skopein meaning 'to see' and is defined as the study of the characteristic patterns of the wrinkles and grooves present on the labial mucosa (sulci laborium), called as lip prints <sup>(10,11)</sup>. Establishing a person's identity can be a very difficult process.

Dental, fingerprint, and DNA comparisons are probably the most common techniques used in this context, allowing fast and secure identification processes. However, since they cannot always be used, sometimes it is necessary to apply different and less known techniques. Today, however, investigators can also rely on lip prints to identify possible suspects or to support evidence gained in specific investigations. As the available literature is scanty, this review was considered to throw some light on lip prints and this review for research from the last 10 years.

### Historical Overview

Fischer in 1902 was the first anthropologist to describe the grooves on the red part of the human lips <sup>(12)</sup>. However, in 1932, Edmond Locard, one of France's greatest criminologists, recommended the use of lip prints in personal identification and criminalization <sup>(13)</sup>. In 1950, Synder reported in his book Homicide Investigation that the characteristics of the lips formed by lip groove areas individually distinctive from the ridge characteristics of fingerprints <sup>(14)</sup>. Suzuki, in 1967, made detailed investigations of the measurement of the lips, the use and color of rouge, and the method for its extraction to obtain useful data for practical forensic application <sup>(15)</sup>. Later in 1970, Suzuki and Tsuchihashi conducted a study on 107 Japanese families and named the grooves on labiorum rutorum as sulci laborium and the lip prints consisting of these grooves <sup>(16)</sup>. Mc Donell in 1972 conducted a study on lip prints between two identical twins and reported that two identical twins seemed to be indistinguishable by every other means, but their lip prints were different <sup>(13)</sup>. Cottone, in 1981, reported in his book Outline of Forensic Dentistry, that Cheiloscopy is one of the special techniques used for personal identification <sup>(17)</sup>. In 1990, Kasprzak researched for a period of five years on 1500 persons to elaborate the practical use of Cheiloscopy <sup>(12)</sup>. Recently, Vahanwala in 2000 conducted a study of lip patterns

to promote the importance of Cheiloscopy in forensic science identification <sup>(18)</sup>.

### Lip Anatomy

The upper lip lies between the nose and the orifice of the oral cavity. Laterally the lips are separated from the cheeks by the nasolabial grooves that extend from the nose and pass approximately 1 cm lateral to the angles of the mouth. These grooves or folds are easier to observe when smiling. The upper lip has an intranasal depression, the philtrum, that extends from the external nasal septum, separating the nostrils, to the vermilion border – the sharp demarcation between the colored edge of the lip and surrounding skin. The lower lip lies between the mouth and the labiodental groove, which separates the lower lip from the chin <sup>(19)</sup>. The upper and lower lips are continuous at the angles of the mouth or oral commissures.

In adults, the outer lip skin is thicker and contains hair, sweat glands, and sebaceous glands. The edges of the lips are covered with reddish skin, called the vermilion that contains many grooves, and are abundantly provided with sensitive nerve endings. The vermilion is a transition layer between the outer, hair-bearing tissue and the inner mucous membrane. As shown in Fig. (1).

### Recording lip prints

Lip prints can be recorded in several ways.

1. Photographing the suspect's lips.
2. Applying lipstick, lip rouge, or other suitable transfer mediums to the lips and then having the individual press his or her lips to a piece of paper or cellophane tape or similar surface <sup>(21)</sup>.
3. Using a fingerprinter, preferably a roller fingerprinter <sup>(22)</sup>.
4. (Without lipstick or another recording medium) against a suitable surface and then processing these prints with either conventional fingerprint developing powder or with a Magna brush and magnetic powder <sup>(21)</sup>.

### Analysis of the Lip Print:

The lip print was divided into six topographic areas (each lip was divided into three areas) and each area was studied alone to determine the type of the grooves.

A transverse line between the two highest points of the philtrum angles was drawn, and then two perpendicular lines were drawn on that transverse line. The perpendicular lines were extended to cut the upper and lower lips. Therefore, each lip print was divided into the following six areas: upper right (UR), upper middle (UM), upper left (UL), lower right (LR), lower middle (LM) and lower left (LL) as shown in Fig.(2) <sup>(23)</sup>.

### Classification Used:

In this review, we followed Fig. (3) the classification of patterns of the lines on the lips proposed by Suzuki and Tsuchihashi <sup>(24,25)</sup>.

- \_ **Type I:** Long vertical (Clear-cut vertical grooves that run across the lips).
- \_ **Type I':** Short vertical (Partial length groove of type I).
- \_ **Type II:** Branched grooves (Branching Y-shaped pattern).
- \_ **Type III:** Intersected grooves (Criss-cross/'x' pattern grooves).
- \_ **Type IV:** Reticular pattern (Grooves that form rectangular shape).
- \_ **Type V:** Mixed/Indefinite (Grooves that do not fall into any of the above categories, the combination of two or more patterns and/or cannot be differentiated morphologically/undetermined).

### Literature Review:

Personal identification is necessary for the unknown deceased persons in homicide, suicide, accident, mass disaster, etc., and for living individual who is missing or culprits hiding their identity. Usually, the personal identification is made by comparing the antemortem record with that of the postmortem record. It was noticed from the current studies that no similar pattern was shown between any two individuals, and this was in coincidence with Suzuki et al. <sup>(16)</sup> and Kumar et al. <sup>(1)</sup>, which supports the role of lip print in personal identification being unique to each person.

Sivapathasundharam et al. <sup>(26)</sup> reached the same result in the study, confirming that the most prominent pattern was IV. Contrasting a study by Kapoor and

Badiye<sup>10</sup> showed that the predominant the pattern in an Indian sample population of 200 persons was pattern I, this could be attributed to the fact of the different location and races of involved populations that might be related to genetic factors.

Prabhu et al. <sup>(27)</sup> explained that this variation could be due to geographical variation or strict standards of different pattern identification.

Kasprzak <sup>(28)</sup> gave a classification that has been proven in practice, in which he determined the pattern based on the numerical superiority of properties of the lines on the fragment. After the patterns of lines had been established, the first catalog of individual features was prepared, and 23 types of individual properties were differentiated.

Research studies and information regarding the use of lip prints as evidence in personal identification and criminal investigation in forensic dentistry are very much scanty.

Caldas et al. (2007) Established identity using Cheiloscropy. The author presented the importance of Cheiloscropy is linked to the fact that lip prints are unique to a person, lip grooves are permanent and unchangeable. It is possible to identify lip patterns as early as the sixth week of for baby's life in the uterine. From that moment on, lip groove patterns rarely change, resisting many afflictions, such as herpetic lesions. In fact, only those pathologies that damage the lip subtract like burns. Processing lip prints depends on the anatomical, morphological, and histological tissue features of lips. Nowadays, new research allows for Cheiloscropy use in a court of law in the USA <sup>(5)</sup>.

Prabhu, et al. (2012), presented a published manuscript on the Cheiloscropy revisit. The authors show if the investigators can rely on Cheiloscropy as supportive evidence in specific investigations or not. The first research in Europe Hungary during 1961 was carried out about lip prints. The examination started after lip traces had been found on a glass door at the scene of a murder. At this time, the usefulness of the lip traces for criminalistic identification was proven. The first cheiloscopic expertise was made

in Poland in 1966 when a lip print was revealed on window glass at the scene of a burglary. The examination was carried out and the expert concluded that the trace of lips revealed at the scene did not belong to the suspect. Since the end of 1985, the Dactyloscopy Division of the Department of Criminalistics of the Civic Militia Headquarters has initiated elaborate methods, previously checked in laboratory conditions, and proved their usefulness in court proceedings. In the year 1986–1987, two methods of Cheiliscropy expertise were performed with positive, categorical opinions <sup>(29)</sup>.

Girish et al. (2013) presented a study to ascertain whether the lip prints behold the potential for the determination of the identity and sex of the person. The authors have used 40 subjects, which include 20 males and 20 females. Lip prints obtained on plain glass were retrieved and matched with the first by two examiners to determine the sex and identity of the person, they are found that every lip print is different and unique, no two lip prints were matched with each other, Type I and I' were most common in females; type IV and V were seen most in males. 18 of the actual 20 lip prints of the females and 16 of 20 males were correctly diagnosed as females and males, respectively. The study can convey that lip prints behold the potential of determination of the sex and identity of the person <sup>(30)</sup>.

Ghimire et al. (2013) proposed a study to analyze and compare quadrant-wise and sex-wise predilection of lip print pattern in the Nepali population. The study involved (100 males and 100 females) (18-25 years) Nepalese undergraduate students of BPKIHS were selected. Only middle 10 mm of both upper and lower lips were taken as a study area. Cheiliscropy square test was used to analyze and compare the lip print patterns in all the quadrants of males and females. So, lip print pattern can be used as an additional tool for personal identification and sex determination <sup>(31)</sup>.

Vikash et al, (2014), studied the lip groove patterns in all the quadrants of both male and female subjects to identify the sex, based on the patterns of the grooves of the lip prints. lip prints were collected

from 300 volunteers (150 males, 150 females) of D. J. College of Dental Sciences and Research, Modinagar (UP). Lip prints were recorded with lipstick and transferred onto a glass slide. They are used statistical analysis to calculate the results, the authors investigated, there are none of the lip prints were identical, thus confirming the role of lip prints in individual identification. According to Suzuki's classification, Type I, II, III, and IV patterns were significant in gender classification<sup>(32)</sup>.

Ganapathy et al. (2018) presented a published manuscript on gender determination and personal identification using Cheiloscopy. The authors have used a study by Vahanwala - Parekh to determine the gender of the individual using the following pattern in the first pattern clear-cut grooves, and vertically across patterns are dominant in females in the third and fourth quadrants, i.e., lower lip, while in the second pattern straight grooves pattern is common in males in the second quadrant, i.e., upper lip left side. Each lip print was measured for its length and then divided into six equal parts as upper right, upper middle, upper left, lower left, lower-middle, and lower right. Based on the classification, only a 10 mm portion of the middle part of the lower lip is used. In which they commented critically that no two lip print patterns matched each other, thus establishing the uniqueness of lip prints. Cheiloscopy is determined to aid in forensic sex determination and a tool in crime investigation for personal identification<sup>(33)</sup>.

Karamustafić et al. (2020) explained the records of lip prints are non-invasive processes and could help in the identification process. Because of this, it would be recommended to think about the introduction of new records into the standard dental procedures. The authors have validated the uniqueness of lip print according to the analysis of the system of grooves which are located at the vermillion of lips, determine the predominant patterns at all participants, as well as the predominant patterns separately at the male and at female participants and to identify the existence

of individual morphological characteristics at lip prints. The researchers have recorded the results using 40 participants, including 20 male and 20 female participants. They are decided of important soft tissues of the oral cavity may help for personal identification. Among the soft tissues, lip prints can be recorded and used as evidence in personal identification and criminal investigation<sup>(34)</sup>.

### **Conclusion:**

This study for A review for using lip print as a tool in forensic dentistry, lip print analysis is a process that provides both qualitative and quantitative results thus its application in the forensic field should be widely accepted by both law enforcement and legal professionals. The positive identification of living or deceased persons using the unique traits and characteristics of the teeth and jaws is a corner a stone of forensic dentistry. A series of forensic dentistry studies on the morphology of the lips and the pattern produced additional weapons for personal identification. Some researchers are trying to relate characteristic lip patterns with person gender and detected DNA in latent lip prints. In addition to the fact that the lip prints identify the gender and the person, it is also used to identify populations from each other through the lip prints. In fact, there have been convictions of perpetrators who were positively identified via the analysis of their known lip prints to those found at the crime scene. There is a need to develop one cohesive Cheiloscopy system, practicable in forensic odontology. A lip print at the scene of a crime can be a basis for conclusions as to the character of the event, the number of the people involved, sexes, cosmetics used, habits, occupational traits, and the pathological changes of lips themselves. Research studies and information regarding the use of lip prints in forensic dentistry are very much scanty but exist as a methodology in forensic dentistry. Studying in-depth and establishing further facts and truth in lip prints will certainly help as useful evidence in forensic dentistry.

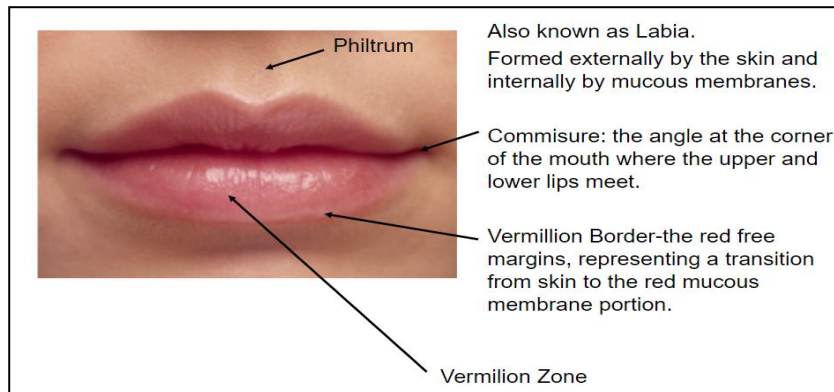


Fig. (1): A lip anatomy <sup>(20)</sup>.

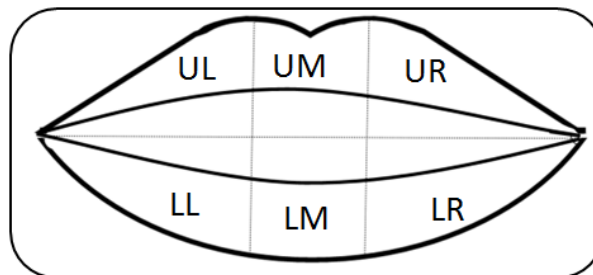


Fig. (2): A diagram showing the compartmental areas of the lip. upper right (UR), upper middle (UM), upper left (UL), lower right (LR), lower middle (LM) and lower left (LL).

<b>Lip Print</b>	<b>Type</b>
	Type I Long Vertical
	Type I' Short Vertical
	Type II Branched
	Type III Intersecting
	Type IV Reticulate
	Type V Indefinite/Mixed

Fig. (3): Photographs showing all the patterns of the lip prints.

## References

- 1- Kumar LB, Jayaraman V, Mathew P, Ramasamy S, Austin RD. Reliability of lip prints in personal identification: an inter-racial pilot study. *J Forensic Dent Sci.* 2016; 8:178. DOI: 10.4103/0975-475.195115.
- 2- Sukul B, Deb U, Ghosh S. Why a “dental surgeon” for identification in forensic science? *Journal of the Indian Medical Association.* 2010; 108(11): 769-775.
- 3- Sweet D, DiZinno JA. Personal identification through dental evidence tooth fragments to DNA. *J Calif Dent Assoc.* 1996;24:35-42.
- 4- Girish K, Rahman FS, Tippu SR. Dental DNA fingerprinting in identification of human remains. *J Forensic Dent Sci.* 2010; 2(2):63–68.
- 5-Caldas I, Magalhaes T, Afonso A. Establishing identity using Cheiloscopy and palatoscopy. *Forensic Sci. Int.,* 2007; 165 (1):1–9.
- 6-Sharma P, Saxena S, Rathod V. Comparative reliability of Cheiloscopy and palatoscopy in human identification. *Indian J. Dent. Res.,* 2009;20 (4):453–457.
- 7-Reddy L, Reddy, Vamsi Krishna. Lip prints: an overview in forensic dentistry. *JADR II;* 2011.
- 8-Venkatesh R, DavidM.P. Cheiloscopy: an aid for personal identification. *J. Forensic Dent. Sci.,* 2011;3:67–70.
- 9-Prabhu R.V, Dinkar A, Prabhu V. Digital method for lip print analysis: a new approach. *J. Forensic Dent. Sci.,* 2013;5:96–105.
- 10-Sivapathasundharam B, Prakash P.A, Sivakumar G. Lip prints (Cheiloscopy). *Indian Dent. Res.,*2001;12:234–237.
- 11-Shafer, Hine, Levy. *Shafer’s Textbook of Oral Pathology,* sixth ed. Elsevier, Noida, India, 2009; 871–897.
- 12- Kasprzak J. Possibilities of Cheiloscopy. *Forensic Sci Int ,*1990;46:145-151.
- 13- Aggarwal A. The importance of lip prints (Forensic Files). Available from: <http://lifeloom.com/II2Aggarwal.htm>. 24th Oct 2008.
- 14- Synder LM. *Textbook of Homicide investigation. Identification of dead bodies.* 1950:65.
- 15- Suzuki K, Suzuki H, Tsuchihashi Y. On the female lips and rouge. *Jpn J Leg Med,* 1967:167-471.
- 16- Suzuki K, Tsuchihashi Y. A new attempt of personal identification by means of lip print. *J Indian Dent Assoc ,*1970; 42:8-9.
- 17- Cott one JA, Standish SM. *Textbook of outline of forensic dentistry. Special Tech (Cheiloscopy),* 1981:135.
- 18- Vahanwahal SP, Parekh DK. Study of lip prints as an aid to forensic methodology. *J Indian Dent Assoc,* 2000; 71:269-271.
- 19- Moore KL, Dalley AF. *Clinically Oriented Anatomy.* 4th Edition. Lippincott Williams & Wilkins; 1999.
- 20- <https://slideplayer.com/slide/10447339/>
- 21-Williams TR. Lip prints – Another means of identification. *J Forensic Ident,* 1991; 41 (3):190-194.
- 22- Prabhu RV, Dinkar AD, Prabhu VD. Collection of lip prints as a forensic evidence at the crime scene: An insight. *J Oral Health Res ,*2010;1:129-135.
- 23-Dina A, Naglaa F, Mostafa M. A Study of Morphological Patterns of Lip Prints in Relation to Gender and Blood Groups Among Egyptian Population. *Egypt J. Forensic Sci. Appl. Toxicol,* 2017; 17 (1):232-236.
- 24-Suzuki K, Tsuchihashi Y. A new attempt of personal identification by means of lip print. *Can. Soc. Forensic Sci. J.,* 1971;4:154–158.
- 25-Tsuchihashi Y. Studies on personal identification by means of lip prints. *Forensic Sci. Int.,* 1974; 3:233–248.
- 26- Sivapathasundharam B, Prakash PA, Sivakumar G. Lip prints (Cheiloscopy). *Indian J Dent Res.,* 2001;12:234–237.
- 27-Prabhu RV, Dinkar A, Prabhu V. A study of lip print pattern in Goan dental students – a digital approach. *J Forensic Leg Med,* 2012;19:390–395.
- 28-Kasprzak J. Cheiloscopy. *Encyclopedia of forensic sciences.* In: Siegal JA, Saukko PJ, Knupfer GC, editors. London: Academic Press, 2000;1:358-361.
- 29-Prabhu RV, Dinkar AD, Prabhu VD, Rao PK. Cheiloscopy: Revisited. *J Forensic Dent Sci* 2012; 4:47-52.
- 30-Girish R, Rahul R, Shirish S, Cheiloscopy-Method of Person Identification and Sex Determination, *Open Access Scientific Reports,* 2013; 2(1):1-4, doi:10.4172/scientificreports.612.
- 31- Ghimire N, Nepal P, Upadhyay S, Budhathoki SS, Subba A, Kharel B. Lip print pattern: an identification tool .*Health Renaissance,* 2013;11(3):229-233.
- 32-Vikash R, Mysore K Sunil, Raghav K. Study of lip prints: A forensic study. *Journal of Indian Academy of Oral Medicine & Radiology ,*2014; 26(1):50-54.
- 33-Ganapathy N, Maheshwari U, Yamunadevi A, Maheswaran T, Ilayaraja V, Tamil Thangam P. Cheiloscopy: An Evolving Tool in Forensic Identification”, *Journal of Indian Academy of Dental Specialist Researchers,* 2018; 5(2):37-41.
- 34-Karamustafić V, Zukić S, Bajzman A, Vuković A. Forensic Cheiloscopy in the Process of Individual Identification, *Acta Scientific Dental Sciences,* 2020; 4(3):81-84.