

## Impact of Suturing Techniques on the Periodontal Health Status of Mandibular Second Molar After Extraction of Fully Impacted Third Molars

Jabbar J. kareem BDS, MSc. <sup>(1)</sup>

Kadhim Jawad BDS, MSc. <sup>(2)</sup>

Raed A. Badiea BDS, MSc. <sup>(3)</sup>

Muthenna Sh. Rajab BDS, MSc. <sup>(4)</sup>

### Key words

suture, extraction, third molars.

### Abstract

Mandibular third molars are appeared to be the most common congenitally impacted teeth the fact that may cause many problems in different fields of dentistry. surgical removal of the impacted tooth seems to be the only solution for these problems. An important complication to address is the risk of developing periodontal breakdown ( loss of attachment) and deep periodontal pocket on the distal aspect of the adjacent mandibular second molar after surgical removal of third molar. The aim of the present study is to evaluate and compare the effect of 4 suturing techniques: (Simple loop , Figure 8 suture, Anchor suture and Closed anchor suture) on the periodontal health status on the distal aspect of the adjacent mandibular second molar after surgical removal of lower impacted third molar. Forty patients having fully impacted mandibular third molars were enrolled in this study and divided to 4 groups (Group A: Simple loop , Group B: Figure 8 suture, Group C: Anchor suture and Group D: Closed anchor suture), each group consisted of 10 patients. Surgical extraction of impacted third molars were carried out for them. Probing pocket depth (PPD) and clinical attachment level (CAL) were recorded preoperatively and 6 months after surgery. On 6 months after surgery the mean values of PPD and CAL were significantly increased on the distal surface of the adjacent mandibular second molar in simple loop & figure 8 techniques. On the other hand, no significant difference has been noticed between anchor & closed anchor techniques in comparison with preoperative values. After 6-months, PPD and CAL values of were significantly higher in the simple loop and figure 8 techniques compared to anchor and closed anchor techniques. The present study concluded that closed anchor suture & anchor suture techniques are preferable to close the flaps in surgical removal of impacted mandibular third molars to maintain a good health status on the distal side of the adjacent mandibular second molar.

### Introduction

Third molars are the most frequently impacted teeth among the whole human

dentition <sup>(1-3)</sup>. In many studies, the frequency of mandibular third molar (M3) in the present study for simplification of reading & writing) impaction has found to be 20% to 30% of population ,with females showing , M3 impaction significantly more often than males <sup>(4)</sup> .In

(1)Lecturer, Department of Oral Surgery & Periodontics, College of Dentistry, Al-Mustansiria University.

(2)Ass. Professor, Department of Oral Surgery & Periodontics, College of Dentistry , Al-Mustansiria University.

(3)Ass. Professor, Department of Oral Surgery & Periodontics, College of Dentistry ,Al-Mustansiria University.

(4)Ass. Professor, Department of Conservative Dentistry, College of Dentistry, University of Tikrit.

developing countries, the occurrence of the M3 impaction appears to be significantly lower, with frequencies ranging from 2% to 9%, the possible explanation for this low impaction frequency is proximal attrition of the dentition<sup>(5,6)</sup>. The etiology of M3 impaction has focused on number of factors, based on several long term clinical studies, the main causes of M3 impaction appears to be related to conditions as lack of space in the M3 region, M3 angulations, ectopic position, obstruction of the eruption pathway and late M3 mineralization / early physical maturity<sup>(7-9)</sup>. The impaction of M3 causes many problems and a variety of complications, as root resorption of adjacent tooth, pericoronitis and even cystic & neoplastic changes and temporomandibular joint disorders<sup>(10,11)</sup>. Commonly, in the distal side of mandibular second molar (M2), the probing pocket depth (PPD) or clinical attachment level (CAL) either remain unchanged or impaired after surgical removal of impacted M3. For subjects with healthy M2 periodontium preoperatively, the indication for M3 removal needs to be evaluated carefully as these subjects have an increased probability for worsening of PPD and attachment levels after surgical removal of M3<sup>(12)</sup>. Another important complication to address is the risk of the developing periodontal defects of distal side of (M2) after extraction of M3 as reported by many studies<sup>(13-15)</sup>. Several studies have been demonstrated the occurrence, frequency and risk factors for increasing M2 periodontal pocket, loss of attachment and bone resorption, these risk factors were represented as the inclination of M3, age of the subject, large contact area, poor oral hygiene (visible plaque distal to the M2 and widened follicle of M3 after its surgical removal<sup>(16-18)</sup>). Many reports were performed to overcome this problem, such as the studies that investigated different incisions and flap techniques used in surgical removal of M3 and their effect in reduction the postoperative discomfort and to decrease or prevent the mentioned periodontal problems on the distal aspect of M2<sup>(19,20)</sup>, however, studies have

revealed conflicting results. It is well known that primary closure of the flap avoids suture dehiscence and improves wound healing<sup>(21)</sup>. The simple loop suture is a very widely used suturing technique usually preferred by the surgeons evaluating the effect of M3 removal on the periodontal health of the adjacent M2<sup>(22,23)</sup>. The anchor suture is another suturing technique to close the flap located in an edentulous area mesial or distal to a tooth. It is best used in mesial or distal wedge procedure. This suture closes the facial and lingual flaps and adapts them tightly against the tooth<sup>(24)</sup>. From this point of view, it was hypothesized that anchor suture might provide better periodontal health of the adjacent M2 after M3 removal. According to our knowledge, very limited trials (may be only one study) in which Burcu et al (2009) had assessed the effect of two suturing techniques (simple loop and anchor) in relation to periodontal health of the adjacent M2 after M3 removal. This study suggested and recommended performing more studies to confirm the reported findings and called also for testing more suturing techniques. Based on these recommendations, the present study was conducted to compare the efficacy of 4 different suturing techniques (Simple loop, Figure 8, Anchor and Closed anchor suturing techniques) for better periodontal health status of the distal aspect of second molar after surgical removal of the adjacent third molar, and it is considered as the first study that evaluated the efficacy of 4 techniques of suturing. These 4 suturing techniques are well mentioned and described in the text book of periodontology 10<sup>th</sup> edition (Carranza's clinical periodontology) Neoman et al 2006<sup>(24)</sup>.

## Materials and Methods

Population sample included in this research were randomly selected from patients attended the teaching dental hospital of the college of dentistry/ Almustansyria university seeking dental treatment. Forty patients (20 females & 20 males). The age of these patients ranged from 17-22 years. The patients

who included in the study must have the following criteria: (Totally bone impacted mandibular third molar requiring ostectomy and odontomy, non smoker patients, no history of systemic diseases, and the reason for surgical removal of impacted M3 for all the study patients was for prophylactic or orthodontic demands). Panoramic radiographs were taken for assessment of bony coverage and angulation of M3 with its relationship with adjacent M2. The 40 cases that included in the study were approximately identical (in bony coverage and angulation of M3). The M3 teeth were impacted horizontally with their crowns faced the distal side of the M2 with similar bone coverage thickness on the impacted M3. The patients were divided to 4 groups, each one consisted of 10 patients with equal gender distribution. After surgical removal of impacted M3, patients in each group have been sutured by one of the proposed four suturing techniques. Those groups were represented as following:

**(Group A: Simple loop , Group B: Figure 8 suture, Group C: Anchor suture and Group D: Closed anchor suture).**

Illustrations of these suturing techniques are shown in figures (1–4). The periodontal parameters of the participant including measurement of probing pocket depth (PPD) and clinical attachment level (CAL) were recorded once preoperatively and another time six months after surgery. These examinations were carried out by the researchers themselves after being pass calibration test successfully. These examinations were conducted on dental chair using plane dental mirrors and color coded WHO periodontal probes.

#### **Surgical procedure:**

All operations were done under local anesthesia by the same oral surgeon in the same operating room and under similar conditions. Local anesthesia was achieved by an inferior alveolar nerve block, together with infiltration of the mucosa of the buccal nerve with (Septodont) lidocain hydrochloride 2% and adrenaline 1:80 000

A full thickness incision was made to prepare the flap. It consisted of a

horizontal incision starting near the mesiobuccal edge of the second molar and extending to its distal surface. A relieving incision was made in the mesial region without cutting the interdental papilla. The horizontal incision was terminated at mandibular second molar. Minimum ostectomy and tooth sectioning were performed with a rotary instrument under constant irrigation with sterile saline. After removal of the tooth, the extraction socket was cleansed carefully, including removal of follicular remnants. Then, the opened flap was closed by one of the 4 types of the study suturing techniques. No subgingival scaling or root planing on distal surface of the second molar was attempted after extraction. All patients received postoperative instruction (ice packs for 6 hours after surgery, alternating 30 min of application with 30 min pause, soft warm diet for the first 24 hours, normal oral hygiene from the day after surgery, mouthwash with 0.2% chlorhexidine twice daily). Patients were given antibiotics (amoxicillin 750 mg per day 5 days) and analgesic drugs (flurbiprofen 200 mg per day for 3 days). The length of the operation was also noted.

#### **Statistical analysis**

Mean values, standard deviations and standard error mean for both study parameters were calculated and represented. Student-t test were used to determine the level of significance of difference recorded between different study groups.

#### **Results**

Forty patients completed the postoperative follow-up without any significant complication. A total of 40 mandibular impacted molar were surgically removed. The mean age of the patients was 19.3 (SD=2.56) years. The mean surgical time was 19.34 (SD=4.12) minutes. The time range was (14-23) minutes and was similar for the 4 suturing techniques of the study. Table 1 shows the Mean values, standard deviation and standard error and level of significance for PPD and CAL before

surgery and six months later for the 4 suturing techniques. The PPD and CAL before surgery were similar in all suturing techniques with no statistical difference. On 6 months after surgery the mean values of PPD and CAL were significantly increased in simple loop and figure 8 techniques in comparison with preoperative values. On the other hand, no significant difference has been noticed in anchor and closed anchor techniques preoperatively and postoperatively. Intergroup comparisons ( table 2 & 3) demonstrated that after 6-months, PPD and CAL values of the distal surface of M2 were significantly higher in the simple loop and figure 8 techniques compared to anchor and closed anchor techniques.

## Discussion

Several conflicting findings have been published in previous literature regarding the effects of impacted third molar extraction on the periodontal health of the adjacent second molar; some authors have shown improvement of periodontal health distal to the adjacent second molar, whilst others have demonstrated loss of attachment increased PPD and reduction of alveolar bone height <sup>(1,2,25)</sup>.

The periodontal problems in the second molars are still considered as important complications after the extraction of the impacted third molars; therefore the optimal surgical approach to prevent these defects is still under investigation. The present study is considered as one of the clinical trials that carried out to prevent the anticipated periodontal problems in M2 as a result of surgical removal of fully impacted M3. The unique feature of our study is the comparison for the first time the efficacy of 4 suturing techniques in maintaining the periodontal health of the mandibular second molar after removal of the adjacent impacted third molar in younger patients. In statistical comparisons of the present study ,closed anchor suture & anchor techniques provided a better spontaneous periodontal healing of the second molar without any periodontal treatment. There is only one study documented the effect of those 2

suturing techniques (simple loop & anchor) in third molar removal surgery and this study showed that the anchor suture technique gave better results of reducing the amount of PPD and CAL of the distal surface of M2 after surgical removal of fully impacted M3 and this study recommended performing necessary furthermore comprehensive studies about this subject <sup>(26)</sup>. Stephens et al. <sup>(27)</sup> reported an improvement in PPD after 3 months without documentation of the 6-months results. On the other hand , in a recent clinical study , the measurements of PPD ,CAL, and BL (bone level) were found to be greater at 6 months after procedure compared to 3 months , suggesting that the periodontal health of second molars tends to deteriorate with time ,therefore ,it is important to perform clinical examination at 6 months to enable sufficient time for post-extraction hard and soft tissue healing to have occurred. Karaca et al <sup>(28)</sup> and Woolf et al <sup>(29)</sup> reported the effect of flap design in terms of periodontal status of the preceding second molar after lower third molar surgery. Moreover , some authors believe that patient's age might have also effects on the second molar periodontal status. Several publications showed an enhanced regrowth of the alveolar bone crest in young patients when the development of the removed third molar was not yet complete. likewise, in another clinical studies patients age was reported to be an important factor for periodontal complications after extraction of impacted third molar , with younger patients healing better than older patients <sup>(18)</sup>. Kugelberg et al, <sup>(30)</sup> found that deeper periodontal pocket depth after third molar surgery is 3 times more frequent in people who are >25 years old. Also, it has been suggested that generalized inflammation due to periodontal disease can complicate the postoperative periodontal healing of the second molar after third molar extraction <sup>(31)</sup>. On the other hand, it is also important to discuss clinically significant differences as well as statistical ones. although the 6 months PPD and CAL values were found to be statistically higher in the simple suture group, the actual measured differences, suggesting that the effects of the 4 suturing techniques on the

periodontal health of the second molar after third molar removal might not be accepted as clinically significantly different. Although, we can conclude that the closed anchor and anchor suture

techniques might be used as an alternative technique to maintain the healthy periodontium and prevent the periodontal problems after the extraction of the impacted third molars.

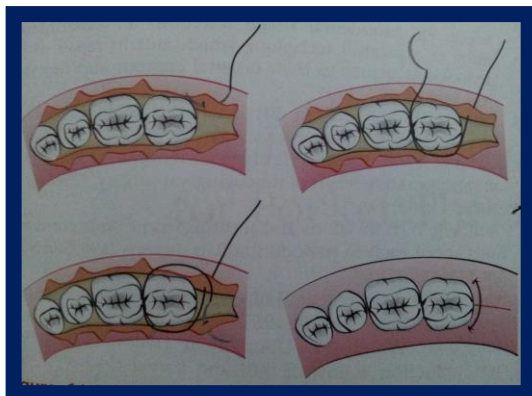


Fig.(1):- Anchor suturing technique.

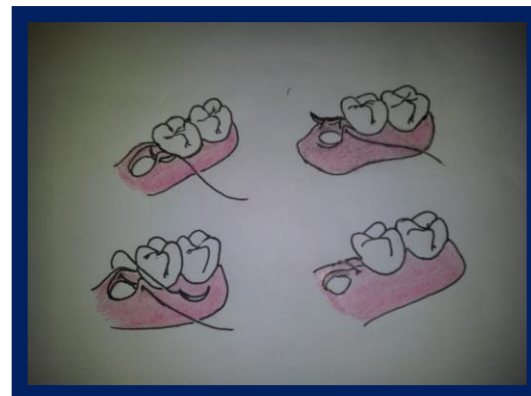


Fig.(3):- Simple loop suturing technique.

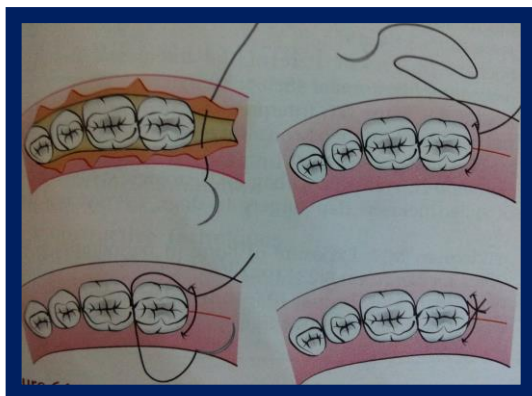


Fig.(2):- Closed anchor suturing technique.

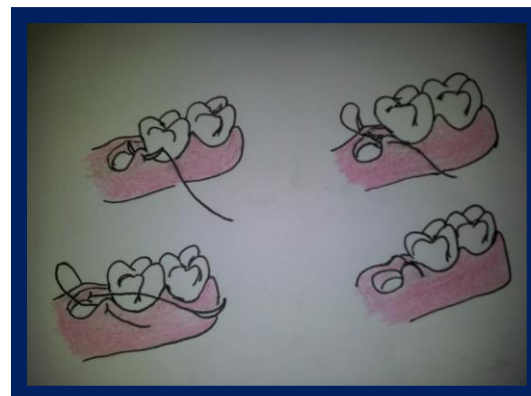


Fig.(4):- Figure 8 suturing technique.

( Schematic illustrations from Carranza's clinical periodontology text book 2006)

Table (1):- Means , std. deviation, std. error and level of significance for PPD and CAL before surgery and 6 months later.

PPD (mm)	Preoperative *		Postoperative		Sig.
Technique (group)	Means & SD	S.Error	Means & SD	S.Error	
Closed anchor suture (D)	2.78 + 0.4	0.0634	3.0 + 0.73	0.0355	NS
Anchor suture (C)	2.91 + 0.63	0.0459	3.27 + 0.68	0.0398	NS
Simple loop suture (A)	2.69 + 0.67	0.0336	4.10 + 0.65	0.0632	S
Figure 8 suture (B)	2.75 + 0.49	0.0363	3.97 + 0.59	0.0311	S
CAL (mm)	Preoperative *		Postoperative		Sig.
Technique (group)	Means & SD	S.Error	Means & SD	S.Error	
Closed anchor suture (D)	4.65 + 0.73	0.0923	4.97 + 0.46	0.0897	NS
Anchor suture (C)	4.47 + 0.55	0.0769	4.58 + 0.64	0.0763	NS
Simple loop suture (A)	4.57 + 0.62	0.0590	5.81 + 0.78	0.0671	S
Figure 8 suture (B)	4.70 + 0.39	0.0755	5.77 + 0.65	0.0776	S

\* no significant difference among all groups in preoperative comparison.

Table (2):- The comparison of mean PPD among the 4 groups at 6 months after surgery.

Technique (groups)	Mean values	T. values	P. values	Sig.
D / C	3.0 / 3.27	1.5	0.14	NS
D / A	3.0 / 4.10	6.2	0.011	S
D / B	3.0 / 3.97	5.7	0.022	S
C / A	3.27 / 4.10	4.8	0.004	S
C / B	3.27 / 3.97	4.3	4 x 10 <sup>-5</sup>	S
B / A	3.97 / 4.10	0.8	0.4	NS

Table (3):- The comparison of mean CAL among the 4 groups at 6 months after surgery.

Groups	Mean values	T. values	P. values	Sig.
D / C	4.97 / 4.58	1.6	0.14	NS
D / A	4.97 / 5.81	2.6	0.009	S
D / B	4.97 / 5.77	10.1	0.003	S
C / A	4.58 / 5.81	3.4	0.001	S
C / B	4.58 / 5.77	7.2	0.01	S
B / A	5.77 / 5.81	1.7	0.09	NS

## References

- 1-Briguglio F, Zenobio EG, Isola G, Briguglio R, Briguglio E, Farronato D, Shibli JA. Complications in surgical removal of impacted mandibular third molars in relation to flap design: clinical and statistical evaluations. *Quintessence Int.* 2011;42(6):445-53.
- 2-Montero J, Mazzaglia G. Effect of removing an impacted mandibular third molar on the periodontal status of the mandibular second molar. *J Oral Maxillofac Surg.* 2011 Nov;69(11):2691-7.
- 3-Shantipriya Reddy: *Essentials of clinical periodontics and Periodontology.*; japee ; 2011.
- 4-Hugosun A, Kugeleberg CF. The prevalence of third molars in a Swedish population. An epidemiological study. *Community dent health* 1988;5:121-38.
- 5-Guthua SW, Mwaniki DL. A retrospective study of characteristics of impacted mandibular wisdom teeth in 110 patients treated in Nairobi, Kenya. *Afr dent J* 1992;6:30-33.
- 6-Odusanyasa DU, Abayomi IO. Third molar eruption among rural Nigerians. *Oral Surg Oral Med Oral Pathol* 1991;71:151-154.
- 7-Aloy-Prósper A, García-Mira B, Larrazabal-Morón C, Peñarrocha-Diago M. Distal probing depth and attachment level of lower second molars following surgical extraction of lower third molars: a literature review. *Med Oral Patol Oral Cir Bucal.* 2010 Sep 1;15(5):e755-9.
- 8-Sammartino G, Tia M, Bucci T, Wang HL. Prevention of mandibular third molar extraction-associated periodontal defects: a comparative study. *J Periodontol.* 2009 Mar;80(3):389-96.
- 9-Sewerin I, Wowern N. A radiographic four-year follow-up study of asymptomatic mandibular third molars in young adults. *Int Dent J* 1990;40:24-30.
- 10-Chaves AJ, Nascimento LR, Costa ME, Franz-Montan M, Oliveira-Júnior PA, Groppo . Effects of surgical removal of mandibular third molar on the periodontium of the second molar. *Int J Dent Hyg.* 2008 May;6(2):123-8.
- 11-MG. Neoman, H.H. Takei, F.A. Carranza : *Carranza's clinical periodontology*; Saunders , 11<sup>th</sup> edition. 2012; pp: 568-571
- 12-Richardson DT, Dodson TB. Risk of periodontal defects after third molar surgery: An exercise in evidence-based clinical decision-making. *Oral Surg Oral Med Oral Pathol Oral Radiol Endod.* 2005 Aug;100(2):133-7.
- 13-Montero J, Mazzaglia G. Effect of removing an impacted mandibular third molar on the periodontal status of the mandibular second molar. *J Oral Maxillofac Surg.* 2011 Nov;69(11):2691-7. Epub 2011 Aug 23.

- 14-Peng K, Tseng Y, Shen E, Chiu S, Fu E, Huang Y. Mandibular second molar periodontal status after third molar extraction. *J Periodontol.* 2001;72(12):1647-51.
- 15-Kan KW, Liu JK, Lo EC, Corbet EF, Leung WK. Residual periodontal defects distal to the mandibular second molar 6-36 months after impacted third molar extraction. *J Clin Periodontol.* 2002 Nov;29(11):1004-11.
- 16-Khalid S, Hassan, Hesham F, Marei, Adel S, Alagl. Composite bone graft for treatment of osseous defects after surgical removal of impacted third and second molars: case report and review of the literature *Oral Surgery, Oral Medicine, Oral Pathology, Oral Radiology and Endodontology* Volume 112, Issue 6, Pages e8-e15, December 2011
- 17-Kugelberg CF, Ahlstrom U, Ericson S, Hugoson A. Periodontal healing after impacted lower third molar surgery. A retrospective study. *Int J Oral Surg* 1985;14:29-40.
- 18-Kugelberg CF, Ahlstrom U, Ericson S, Hugoson A, Thilander H. The influence of anatomical, pathophysiological and other factors on periodontal healing after impacted lower third molar surgery. A multiple regression analysis. *J Clin Periodontol* 1991;18:37-43.
- 19-Rosa AL, Carneiro MG, Lavrador MA, Novaes AB Jr. Influence of flap design on periodontal healing of second molars after extraction of impacted mandibular third molars. *Oral Surg Oral Med Oral Pathol Oral Radiol Endod.* 2002 Apr;93(4):404-7.
- 20-Panagiotis S., Michalis M., Constantinos K., Savas T., Evaggelia S: Cysts and tumors associated with impacted third molars: is prophylactic removal justified? *Association of Oral and Maxillofacial Surgeons* (2011) Volume: 69, Issue: 2, Pages: 405-408
- 21-Jakse N, Bankaoglu V, Wimmer G, Eskici A, Pertl C. Primary wound healing after lower third molar surgery: evaluation of 2 different flap designs. *Oral Surg Oral Med Oral Pathol Oral Radiol Endod* 2002;93:7-12.
- 22-Kirtiloglu T, Bulut E, Sumer M, Cengiz I. Comparison of 2 flap designs in the periodontal healing second molars after fully impacted mandibular third molar extractions. *J Oral Maxillofac Surg* 2007;65:2206-10.
- 23-Pasqualini D, Cocero N, Castella A, Male L, Bracco P. Primary and secondary closure of surgical wound after removal of impacted mandibular third molar : a comparative study . *Int J Oral Maxillofac Surg* 2005;34:52-7.
- 24-MG. Neoman, H.H. Takei, F.A. Carranza : *Carranza's clinical periodontology*; Saunders ,10<sup>th</sup> edition. 2006;
- 25-Krausz AA, Machtei EE, Peled M. Effects of lower third molar extraction on attachment level and alveolar bone height of the adjacent second molar. *Int J Oral Maxillofac Surg.* 2005 Oct;34(7):756-60.
- 26-Burcu Ozkan Cetinkaya, Mahmut Sumer, Ferda Tutkun, Elif Ozen Sandikci, Ferhat Misir, Influence of different suturing techniques on periodontal health of the adjacent second molars after extraction of impacted mandibular third molars received in revised form 15 February 2009; accepted 11 March 2009.
- 27-Stephens RJ, App GR, Foreman DW .Periodontal evaluation of two mucoperosteal flaps used in removing impacted mandibular third molars . *J Oral Maxillofac Surg* 1983;41:719-24.
- 28-Karaca I, Simşek S, Uğar D, Bozkaya S. Review of flap design influence on the health of the periodontium after mandibular third molar surgery. *Oral Surg Oral Med Oral Pathol Oral Radiol Endod.* 2007 Jul;104(1):18-23. Epub 2007 Apr 20.
- 29-Woolf RH, Malmquist JP, Wright WH. Third molar extractions: periodontal implications of two flap designs. *Gen Dent* 1978;26:52-6.
- 30-Kugelberg CF, Ahlstrom U, Ericson S, Hugoson A, Kvint S. Periodontal healing after impacted lower third molar surgery in adolescents and adults. A prospective study. *Int J Oral Maxillofac Surg* 1991;20:18-24.
- 31-Marmary Y, Brayer L, Tzukert A, Feller L. Alveolar bone repair following extraction of impacted mandibular third molars. *Oral Surg Oral Med Oral Pathol Oral Radiol Endod* 1986;61:324-6.