



## Schistosomus Reflexus Combination with Hydrocephalic Fetus in Local Iraqi Dairy Cow: Case Report

Ali Ghazi Atiyah, Maythem A. Ismaeel

Department of Medicine, Surgery and Obstetrics – Veterinary College – Tikrit University – Iraq.

### ARTICLE INFO.

#### Article history:

-Received: 26/ 4/ 2023

-Accepted: 18/ 6/2023

-Available online:

#### Keywords

Fetal anomalies,  
Schistosomus Reflexus,  
hydrocephalus, cesarean  
section.

#### Corresponding Author:

Name: Maythem A. Ismaeel

E-mail:

[dr.maythem.ir.78@tu.edu.iq](mailto:dr.maythem.ir.78@tu.edu.iq)

Tel: :

### ABSTRACT

Congenital abnormalities in Iraqi cow fetuses can occur due to various genetic, environmental, and infectious factors. These abnormalities can affect the development of different organs and systems in the fetus, resulting in structural or functional abnormalities that may affect the survival and health of the newborn calf. The Frisian cow at full term of pregnancy as per proprietor is given the historical backdrop of stressing and unfit to go through the ordinary physiological course of calving, vaginal assessment uncovers a twisted embryo in the pelvic hole that leaves lacking space for fetal control with some of fetal layer project outside from the vulva. Caesarean section relieves dystocia, and physical examination of the defective fetus confirms a case of genuine Schistosomus reflexus (SR) in a cow. The presence of hydrocephalic fetus in combination with anomalies (SR) has not been previously reported in dairy cattle from Iraq.

### 1. Introduction

Spinal inversion, exposure of the abdominal viscera due to a fissure in the ventral abdominal wall, limb ankylosis, positioning of the limbs adjacent to the skull, and lung and diaphragm hypoplasia in ewes are the defining characteristics of Schistosomus reflexus (SR), a rare and fatal congenital disorder [1]. Variable parts of SR incorporate scoliosis, split sternum, openness to the thoracic viscera, and anomalies of the stomach related and

urogenital frameworks [2]. Hydrocephalus is a drop-like condition characterized by significant cranial enlargement caused by an imbalance in the formation and drainage of cerebrospinal fluid (CSF) in the ventricular system or subarachnoid space. [3]. These congenital defects may be caused by teratogens that cause abnormalities in the developing. Teratogens include drugs, hormones,

chemicals, viruses, toxic plants, air pollutions, high body temperature etc [4]. Shanmuganathan et al. [5] reported that the causes of congenital anomalies can be linked to genetic factors (anomalies in chromosome and mutations), environmental factors and infectious agents.

## **2. History and Clinical Observation**

An adult dairy cow was presented with a history of continuous straining and was unable to undergo the normal physiological process of calving. According to the owner, this was the cow's second lambing at full term. On clinical assessment the cow was viewed as in standing position and in great physiological condition. Heart rate and respiration rate were within normal limits. Pink mucous membranes were visible on the conjunctiva. Congested intestinal loops protruded from the vagina on closer inspection, and a digital vaginal examination confirmed that they belonged to a fetus. On uterine assessment, the fetal head, ribs, some of appendages and fetal viscera were touched inside the uterus. As a result, a possible diagnosis of dystocia caused by fetal malformation was made. Due to the fetus's misalignment with the birth canal and a lack of space in the pelvic cavity, attempts to manipulate the fetus and relieve dystocia with traction were unsuccessful, and a cesarean section was planned [6].

## **3. Surgical approach**

operation was performed in standing position. The desensitization of the left flank area while animal in standing

position can be achieved by Inverted 'L' block by using local anesthetic drug (Lidocaine- Hydrochloride) . Cesarean section is done according to [7] . After complete removal of fetus, suture the uterine incision with two rows inversion suture pattern. Then complete the suturing of all muscles separately with simple continuous suture patterns, and the skin incision was closed with a simple interrupted suture pattern. The animal is given antibiotic systemically and locally within the uterus immediately after surgery and continues for five days post operatively.

## **4. Fetal Description and discussion**

The eliminated hatchling was twisted with stamped ventral arch of the spine, sidelong bowing of fetal body and chest wall uncovering the stomach viscera, with distorted pelvis and ankylosis of the appendages, the enlargement of head that was indicated the present of hydrocephalus. It was diagnosed as a case of true schistosomus reflexus with hydrocephalic fetus (Figure 1). Same case were reported in many species, equine [8], buffalo [9], caprine [5] and ewes [10]. but all these cases were occur alone without combined with other anomalies like current case report in which the anomalies combined with Hydrocephalus. An imbalance between the formation and drainage of cerebrospinal fluid either in the ventricular system or subarachnoid space, characterized by a marked enlargement of the cranium, results in the accumulation of excessive fluid in the durameter or ventricles of the brain, which is the definition of hydrocephalus [1].

The reasons for hydrocephalus is known to be acquired in steers and exacerbated in its sign by a coinciding hypovitaminosis A. Pressure of the mind happens in calves with hypovitaminosis A, because of

disappointment of development and molding of the cranial vault to oblige the developing cerebrum [11].

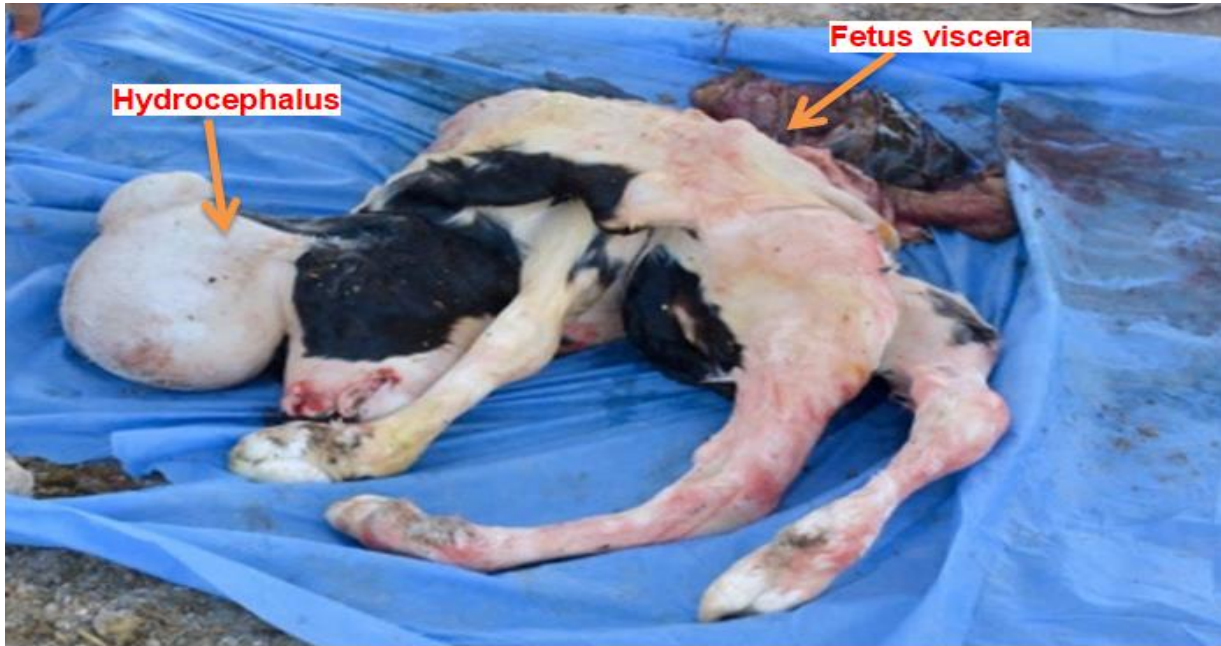


Figure 1: schistosomus reflexus in a calve notice ankyloses of spinal cord, exposed abdominal viscera and present of hydrocephalice fetus.

### Conclusion:

Animals born with Schistosomus reflexus typically have their internal organs exposed and visible on the outside of their body. The spine is often twisted, causing the head and limbs to be positioned in abnormal ways. hydrocephalus is a rare

condition that can result from genetic mutations, viral infections, or other environmental factors that disrupt the normal development of the central nervous system. The accumulation of excess CSF in the brain causes increased pressure inside the skull, which can result in an enlarged and misshapen head.

### References

1. Selvaraju, M., Prakash, S., Varudharajan, V., Ravikumar, K., Palanisamy, M., Gopikrishnan, D., ... & Manokaran, S. (2020). Obstetrical disorders in farm animals: A review. *The Pharma Innovation J*, 65-74.
2. Laughton, K. W., Fisher, K. R. S., & Halina Partlow, W. G. (2005). Schistosomus reflexus syndrome: a heritable defect in ruminants. *Anatomia, histologia, embryologia*, 34(5), 312-318.
3. Purohit, G. N., Gaur, M., & Sharma, A. (2006). Dystocia in Rathi cows due to congenital hydrocephalus. *Indian J Anim Reprod*, 27(1), 98-99.
4. Dutt, R. (2019). Dystocia due to dicephalic fetus in a cross bred Jersey cow. *International Journal of*

- Agriculture Sciences, ISSN, 0975-3710.
5. Shanmuganathan, S., Manikandan, R., & Praveen, V. (2022). Schistosoma Reflexus in Non-Descriptive Doe: A Rare Case Report. Indian Journal of Veterinary Sciences & Biotechnology, 18(3), 143-144.
  6. Acharya, C., Kalita, M. K., Mahanta, C. N., & Barman, U. (2019). Dystocia due to a Dicephalus Monster Fetus in Holstein Friesian Cow. Int. J. Curr. Microbiol. App. Sci, 8(2), 3024-3027.
  7. Schultz, L. G., Tyler, J. W., Moll, H. D., & Constantinescu, G. M. (2008). Surgical approaches for cesarean section in cattle. The Canadian Veterinary Journal, 1, 49(6), 565.
  8. Azizi, S., Morteza, K. U. H. I., Kheirandish, R., Salarpoor, M., & Fatemi, H. (2019). Schistosomus (Fissura abdominalis), atresia ani and arthrogryposis in a Turkoman foal. Ankara Üniversitesi Veteriner Fakültesi Dergisi, 66(2), 217-220.
  9. Balamurugan, B., Reddy, Y. P., & Jyothi, K. (2020). Successful pervaginal delivery of schistosoma reflex foetal monster in a nondescript buffalo-A case report. The Pharma Innovation Journal, 9(4), 57-58.
  10. Periyannan, M., Senthilkumar, K., & Gawhane Abhishek Subhash, S. (2022). Rare incidence of schistosomus reflexus and its successful pervaginal delivery in a Mecheri ewe.
  11. Roberts, S.J. (1986). Diagnosis and treatment of Dystocia, veterinary obstetrics and genital diseases. CBS Publishers, New Delhi. 283.

## حالة *Schistosomus Reflexus* مترافقة مع استسقاء رأس الجنين في ابقار الحليب العراقية

### المحلية : تسجيل حالة

علي غازي عطية, ميثم عبد الاله اسماعيل

فرع الطب الباطني والجراحة والتوليد، كلية الطب البيطري، جامعة تكريت، تكريت، العراق

### الملخص

تحدث التشوهات الخلقية في الأجنة العراقية بسبب عوامل وراثية وبيئية ومعديّة مختلفة. يمكن أن تؤثر هذه التشوهات على نمو أعضاء وأنظمة مختلفة في الجنين ، مما يؤدي إلى تشوهات هيكلية أو وظيفية قد تؤثر على بقاء وصحة العجل حديث الولادة. تُعطى البقرة الفريزية في فترة الحمل الكاملة وفقاً لمالكها الخلفية التاريخية المتمثلة في الإجهاد وعدم صلاحيتها للاستمرار في المسار الفسيولوجي الطبيعي للولادة ، ويكشف التقييم المهبل عن جنين ملتوي في تجويف الحوض الذي يؤدي الى ضيق المساحة للسيطرة على الجنين مع بروز بعض اجزاء الجنين خارج الفرج. تعالج العملية القيصرية عسر الولادة ، ويؤكد الفحص البدني للجنين المشوه وجود حالة *Schistosoma reflexus* (SR) في بقرة. لم يتم التسجيل سابقاً عن وجود حالة استسقاء الرأس في الجنين مع *Schistosoma reflexus* في الأبقار الحلوب في العراق.