

The Incidence of Two Root Canals in the Mesial Root of the Extracted Permanent Maxillary First Molars Among a Sulaimani-Iraq Population (Ex Vivo Study)

Bestoon M. Faraj BDS, H.D.D., MSc., Ph.D. ⁽¹⁾

Key words

incidence, MB2, Sulaimani-Iraq population.

Abstract

The aim of this study was to assess the incidence of two root canals in the mesial root of the extracted permanent maxillary first molars of a Sulaimani population. An ex vivo study on 180 extracted permanent maxillary first molars was conducted. The teeth were examined clinically and radiographically. The results showed that 23.3 % of the examined teeth had two canals in the mesial root (17.0 % with one apical foramen and 6.3 % with two separate foramens).

Introduction

A thorough knowledge of the anatomy of root canal systems is required to achieve successful root canal treatment. Extra roots or root canals if not detected are a major reason for failure ^(1,2). Smadi and Khraisat ⁽³⁾ reported that the maxillary first molar has some of the highest failure rates in endodontic treatment. The failure often is due to the presence of a second canal in the mesiobuccal root that the clinician fails to detect, debride and obturate. Maxillary first molar largest in volume and most complex in root and root canal anatomy, and possibly the most treated least understood posterior teeth, and unquestionably one of the most important teeth. The mesiobuccal root of the first molar has generated more research, clinical investigation, and pure frustration than has probably any other root in the mouth ⁽⁴⁾. The incidence of having two canals in the mesial root of the maxillary first molar has been well established by several authors using different approaches, such as radiographs, decalcification, sectioning, ultrasonics, lousps and dental operating microscope as illustrated in Table(1) ⁽⁵⁻¹⁹⁾. The mesiobuccal root of the

first maxillary molar can be challenging due to the high incidence of two MB canals ⁽¹⁶⁻¹⁸⁾. The orifice for the MB2 usually lies lingual to the mesiobuccal canal toward the palatal canal. The effective way for exploration of MB2 clinically is to sweep mesially from the mesiobuccal canal toward the lingual ⁽⁵⁾. The purpose of the present study was to report the incidence of two root canals in the mesial root of the extracted permanent maxillary first molars of a Sulaimani population.

Materials and Methods

A total of 180 badly carious extracted permanent maxillary first molar teeth of Sulaimani patients were collected from clinical procedures performed in different hospitals and private clinics of Sulaimani between May-2010 and October -2010. The extracted teeth had been cleaned with ultrasonic scaler and stored in 50% ethanol for a maximum of 6 months. Teeth were subjected to visual examination and digital radiography, after that and by using a diamond disk with a straight hand piece, the coronal portion of each tooth was removed to the level of the roof of the pulp chamber, and the floor of the pulp

(1)Lecturer, Department of Conservative Dentistry, School of Dentistry, Faculty of Medical Sciences, University of Sulaimani.

chamber clearly exposed as showing in Figure (1). Patency of each canal was established by passing a no.10 k-type file through the apical foramen and canal orifices. A bubble test with sodium hypochlorite in the pulp chamber and chelating agents (EDTA) was occasionally used for removing the smear layer and softening calcifications inside the pulp chamber, allowing for easier access to canal openings, and the following features were evaluated by the aid of a magnifying lens:

(1) number of root canals in mesiobuccal root, (2) number of apical foramen of mesiobuccal root canal(s).

Results

Of the 180 extracted maxillary first molar teeth were collected for this study, 116 teeth (64.4%) had one root canal in mesiobuccal root and the remaining 64 teeth (35.6%) had two root canals. The two root canals in the mesial roots were mostly confluent in the apical third, ending in one foramen (32.2%), and only (3.3%) ending in two apical foramen. Results are summarized in table (2).

Discussion

The incidence of two root canals in the mesial root of the permanent maxillary first molar has been well established in the literature, without adequate information regarding the races, so it was designed to conduct this investigation. This study could very well be the first research which assesses the incidence of two root canals in the mesial root of the permanent maxillary first molars of a Sulaimani population. An examination of the floor of the pulp chamber offers clues to the type of canal configuration present. When there is only one canal, it is usually located rather easily in the centre of the access preparation. If only one orifice is found and it is not in the centre of the tooth, it is probable that another canal is present and the operator should search for it on the opposite side⁽²⁰⁾. The morphology of canal systems in maxillary molars varies by definition according to the method and criteria used to detect it⁽⁵⁻²¹⁾. In vitro studies show more fourth canals than do in

vivo studies^(21,22). It is generally accepted that the maxillary first molar has three canals with an MB2 canal seen in 56.8%-80.9% of the cases^(23, 24); similar finding were recorded in this study. The closer the orifices are to each other, the greater are the chances that the two canals join at some point within the body of the root. In this study most of the located two canals were joined in the apical 1 to 4mm of the root canal and exited through one foramen. This is similar to the findings of Neaverth et al⁽¹²⁾. Saad Al-Nazhan,⁽¹⁵⁾ and Kulild and Peters⁽²¹⁾. In this study magnifying lens were used during the exploration of canal orifices, since magnification has been found to increase the detection rate of MB2 canals from 17.2% with the naked eye, to 62.5% with loupes and 71.1% using the surgical operating microscope⁽²⁵⁾. The use of radiograph to study the canal morphology might appear to have certain limitations, since it's a two dimensional image of a three dimensional object. In the present study only a small number of second MB canals were detected during the interpretation of the diagnostic radiographs taken. In the present study more than 16 teeth presented with different quantity of pulp chamber and/or canals orifice calcification. For easier access to canal openings a bubble test with sodium hypochlorite in the pulp chamber and chelating agents (EDTA) was occasionally used for removing the smear layer and softening calcifications. Ibarrola et al. suggested the use of chelating agents and ultrasonic instrumentation to remove debris and anatomical irregularities that interfere with negotiation of the MB and ML canals⁽¹³⁾. In this study the orifice of the second mesiobuccal root canal was commonly located lingual to the main mesiobuccal canal orifice. Similar finding has been reported by other investigators^(6,14). In the present study, mesiolingual canal was found in 64(35.5%) of 180 cases this percentage is much lower than the range reported of other in vivo and in vitro studies,^(12,13,16,17,19) and slightly higher than results recorded in other researches^(5,7-9,11,15,18).

Conclusion

The occurrence, location and apical foramina of second MB canals in the

mesial root of the permanent maxillary first molar of a Sulaimani population were within the normal range.

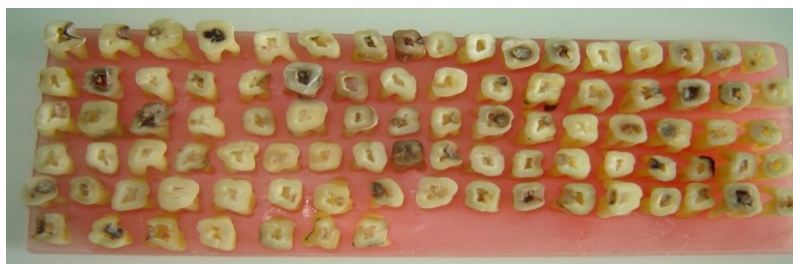


Fig.(1):- Crown sectioning procedure.

Table (1):-Root canals and apical foramina in mesiobuccal root of maxillary first molar ⁽⁵⁻¹⁹⁾.

Investigator(s)	Teeth sample	Method	One canal & one foramen (%)	Two canals & one foramen (%)	Two canals & two foramen (%)
Weine et al .1969	208	In vitro sections	48.5	37.5	14.0
Pineda and Kuttler 1972	262	In vitro radiographs	39.0	12.5	48.5
Pineda F.1973	245	In vitro radiographs	41.0	17.0	42.0
Seidberg et al 1973	100 201	In vitro sections In vivo	38.0 66.7	37.0 33.3	25.0
Pomeranze and Fishelberg 1974	71	In vivo	72.0	17.0	11.0
Hartwell and bellizzi 1982	538	In vivo	80.7	18.6	
Vertucci 1984	100	In vitro clear and dyed sections	45.0	37.0	18.0
Neaverth et al.1987	228	In vivo	19.3	16.7	60.0
Ibarrola et al.1997	87	In vitro clearing	23.0	77.0	
Tam and Yu 2002	50	In vitro sections	36.0	40.0	24.0
Saad Al-Nazhan 2005	352	In vivo	76.7	17.0	6.3
Gary Hartwell et al. 2007	121	In vivo	29.76	70.2	
Alacam et al. 2008	100	In vitro dental operating microscope and ultrasonics.	18	53	29
Emel et al. 2008	202	In vivo	29.8	20.2	14.3
Tuncer et al. 2010	110	In vitro unaided vision ,dental louns and dental operating microscope	22	78	

Table(2):-Percentages of root canals and apical foramina in mesiobuccal root of maxillary first molar.

No. of teeth	One canal & one foramen (%)	Two canals & one foramen (%)	Two canals & two foramen (%)
180	116 (64.4%)	58 (32.2%)	6 (3.3%)

References

- 1- Slowey R. Radiographic aids in the detection of extra root canals. *Oral Surg Oral Med Oral Pathol.* 1974; 37: 762-772.
- 2-Karthikeyan K. and Mahalaxmi S. New nomenclature for extra canals based on four reported cases of maxillary first molars with six canals. *J Endod.* 2010; 36:1073-1078.
- 3-Smadi L. and Khraisat A. Detection of a second mesiobuccal canal in the mesiobuccal roots of maxillary first molar teeth. *Oral Surg Oral Med Oral Pathol Oral Radiol Endod.* 2007;103(3):e77-81.
- 4- Cohen S. and Burns C. *Pathways of the pulp* 6th Ed. Harcourt Brace and Company, Asia PTE Ltd, 1997.
- 5-Weine F. Healey H. Gerstein H. and Evanson L. Canal configuration in the mesiobuccal root of the maxillary first molar and its endodontic significance. *Oral Surg.* 1969; 28: 419-425.
- 6-Pineda F. and Kuttler Y. Mesiodistal & buccolingual roentgenographic investigation of 7,275 root canals. *Oral Surg.* 1972; 33: 101-110.
- 7-Pineda F. Roentgenographic investigations of the mesiobuccal root of the maxillary first molar. *Oral Surg.* 1973; 36: 253-260.
- 8- Seidberg B. Altman M. Guttuso J. and Suson M. Frequency of two mesiobuccal root canals in maxillary permanent first molar. *J. Am. Dent. Assoc.* 1973; 87: 852- 856.
- 9-Pomeranz H. and Fishelberg G. The secondary mesiobuccal canal of maxillary molars. *J. Am. Dent. Assoc.* 1974; 88: 119-124.
- 10-Hartwell G. and Bellizzi R. Clinical investigation of in vivo endodontically treated mandibular and maxillary molars. *J Endod.* 1982; 8:555-557.
- 11- Vertucci F. The endodontic significance of the mesiobuccal root of the maxillary first molar. *Navy Med.* 1984; 63: 29.
- 12- Neaverth E. Kutler L. and Kalten B. Clinical investigation (in vivo) of endodontically treated maxillary first molars. *J Endod.* 1987; 13:506-512.
- 13-Ibarrola J. Knowles K. Ludlow M. and Mickinley B. Factors affecting the negotiability of second mesiobuccal canals in maxillary molars. *J Endod.* 1997; 23: 236-238.
- 14-Tam A. and Yu D. Location of canal isthmus and accessory canals in the mesiobuccal root of maxillary first permanent molars. *J Can Dent Assoc.* 2002; 68: 28-33.
- 15- Saad Al-Nazhan. The prevalence of two canals in mesial root of endodontically treated maxillary first molars among a Saudi Arabian sub-population. *Saudi Dental Journal.* 2005; 17: 15-21.
- 16- Gary H. Crig M. Appelstein W. Lyous W. and Mary E. The incidence of four canals in maxillary first molars. *J Am Dent Assoc.* 2007; 138: 1344-1346.
- 17- Alaçam T. Tinaz A. Genç Ö. and Kayaoglu G. Second mesiobuccal canal detection in maxillary first molars using microscopy and ultrasonics. *Aust Endod J.* 2008; 34: 106-109.
- 18-Emel O. Mete Ü. and Ersin Ö. Canal Configuration of the Mesiobuccal Root of Maxillary Molars. *Hacettepe Diş Hekimliği Fakültesi Dergisi.* 2008; 32: 2-9.
- 19-Tuncer A. Haznedaroglu F. and Sert S. The Location and Accessibility of the Second Mesiobuccal Canal in Maxillary First Molar. *Eur J Dent.* 2010; 4: 12-16.
- 20-Acosta V. and Trugeda B. Anatomy of the pulp chamber floor of the permanent maxillary first molar. *J Endod.* 1978; 4: 214-219.
- 21-Wolcott J. Ishley D. Kennedy W. Johnson S. Minnich S. and Meyers J. A 5 yr clinical investigation of second mesiobuccal canals in endodontically treated and retreated maxillary molars. *J Endod.* 2005; 31: 262-264.
- 22-Kulild J. and Peters D. Incidence and configuration of canal systems in the mesiobuccal root of maxillary first and second molars. *J Endod.* 1990; 16: 311-317.
- 23- Cleghorn B. Christie H. and Dong C. Root and root canal morphology of the human permanent maxillary first molar: a literature review. *J Endod.* 2006; 32; 9: 813-820.
- 24-Imura N. Hata G. Toda T. Otani S. and Fagundes M. Two canals in mesiobuccal roots of maxillary molars. *Int End J.* 1998; 31; 6: 410-414.
- 25-Buchrley L. Barrows M. BeGole E. and Wenckus C. Effect of magnification on locating the MB2 canal in maxillary molars. *J Endod.* 2002; 28: 324-327.