

## Effect of Gentamicin on common carp Fish *Cyprinus carpio* on Diyala province (Histopathological study)

Mohammed Abed Mahmood

Department of Pathology, Faculty of Veterinary Medicine, University of Diyala, Iraq  
Correspondence E-mail: [mohammedvet87@gmail.com](mailto:mohammedvet87@gmail.com)

### Abstract

Different types of antibiotics are found in water due to water waste excreted by fish, which poses a threat to the public health system, especially human health. Gentamicin is one of the important antibiotics used to treat many bacterial infections in veterinary medicine, so it is widely present in the fishes aquatic environment. The current study aim to identify the effect of gentamicin on the juveniles of common carp (*Cyprinus carpio*) and reported histopathological changes on gills and liver of it. Fish exposed for 72 h to different concentration of gentamicin. The gills lesions were recorded In control group showed normal histological morphology. Exposed of fish gill to 0.01mg/L and 0.1mg/L of gentamicin showed epithelial cell hyperplasia in addition to hyperplasia of mucous cells, fusion of lamellae, exposed to 1mg/L of gentamicin showed lifting of gill lamella and desquamation and exposed to 10 mg/L, the gill showed aneurysm. Liver histopathology of fish control group not exposed to gentamicin and not showed any histological changes which characterized by presences of normal hepatocytes and hepatocytic nucleus. Exposed to 0.01 not showed any abnormal tissue structure, Fish liver exposed to 0.1mg/L showed only vacuolation, dilation in space between sinusoids and pyknosis, exposed to 1mg/L showed hepatocyte hyper atrophy and degeneration, exposed to 10µg/L showed inflammatory cells infiltration. This study observed the increase doses of gentamicin conjugate with increase severity of lesions in gill and liver especially when not reported any signs in control group for both organ. In addition to that there is circulatory signs such as congestion and dilation of sinusoids in liver. The doses which used in this study consider sub lethal doses, here it must be taken into consideration that doses higher than those used in this current study could cause severe pathological effects in fish.

**Key word :** Fish, gentamicin, *Cyprinus carpio*, gill, Liver.



This is an open access article licensed under a [Creative Commons Attribution-NonCommercial 4.0 International License](https://creativecommons.org/licenses/by-nc/4.0/).

### Introduction

Gentamicin is antibiotic belong to aminoglycosides, it is used for prevent of several bacterial infection in body as ear infection, endocarditis, bone infection and nephritis [1]. Gentamicin have uses in

veterinary medicine, for the treatment of ear infection in dogs and cats, bacterial uterine infections mare and to aid in successful the conception in mares with endometritis, gentamicin sulfate solution is advised [2],[3]. In fish farm, high stocking densities for fish rearing come with an increase of risk bacterial

infections, which are often treated with other antibiotics. Gentamicin was used to farm animals as preventative medicine or growth enhancers [4]. According to a prior literature review, gentamicin is found in surface of water at values approximately a few ng/L and g/L, indicating the environmental importance of this particular molecule and appears to be excreted intact in significant proportions, highlighting the chemical's importance for the environment [5]. Gentamicin has been recognized as an antibiotic that poses a particular threat to aquatic life because of its consumption pattern, ongoing excretion, environmental perseverance, in addition to toxic characteristics [6]. Additionally, gentamicin is a class I high priority medicine that has to be monitored in the future and has specific ecotoxicological research being developed to address its toxic effects [7]. Additionally, gentamicin-treated fish displayed hyperglycemia, decreased total protein and cholesterol levels, decreased salt, chloride, calcium, and iron levels, and raised levels of aspartate aminotransferase, alanine aminotransferase and creatine kinase, gentamicin may harm wildlife by causing negative effects even at residual quantities, according to several research evaluating the drug's effects on fish [8]. Some study mentioned the gentamicin causes

hepatotoxicity and nephrotoxicity in fish [9]. Fish exposed to environmental stresses like antibiotics may experience a complicated web of biochemical reactions. Histological analysis makes it simple to determine whether tissue damage has occurred as a result of molecular interfaces between cellular components and contaminants [10]. A developed level of biological microorganization in reaction to a preceding biochemical and/or physiological error is known as a histological abnormality. Additionally, the observed morphological alterations in some *Cyprinus carpio* tissues may be adaptive mechanisms for preserving homeostasis of body [11]. *Cyprinus carpio* as a fish water species has important economy [12]. Because of sensitivity of fish to many antibiotic, this study aimed to study of histopathological effect of liver and gills of common carp species *Cyprinus carpio* which exposed to antibiotic gentamicin.

## Material and methods

### Chemicals

Gentamicin (Indian pharmaceutical company) stock solutions (3 g/L) were prepared used for each bioassay by dilution in

dechlorinated tap water. Study solution prepared from one of experimental study and solution change by suitable dilutions of solution [13]. Common carp juvenile were purchased at an aquaculture facility in the province of diyala and shipped there in plastic boxes that were both air-conditioned and refrigerated. For three weeks, individuals were kept in tightly regulated lab environments. 500-liter tanks with recirculated aerated and tap water without chlorine, photoperiod (12Light:12Dark), and continuous temperature relatively (15°C) were used for the experimental procedures. Every two days, commercial pellets were provided to the fish at no restriction. Every day, fish were inspected, and any that were dead or diseased were immediately discarded. 24 hours before to the experiments, feeding was stopped. The same lab-controlled settings as those used for the quarantine period were used for the exposures. First control group and other experimental group according to different gentamicin concentrations (0.01, 0.1, 1 and 10 mg/L) were administered to fish. Gentamicin exposure took place course of four days. In a nutshell, 36 individuals were divided into six group, each group divided equally and randomly into 6 fishes, 50 L aquaria, each containing six fish. Fish aquaria were placed randomly, and 90% of the

medium concentration was changed every 24 hours. [14].

## Histopathological preparation

Fish anaesthetized and killed [15]. In Bouin solution, a part of the liver and gills were fixed for 30 hours before being decalcified of gills for another 30 hours. Following that, samples were dried using ethanol solutions that increased in strength (50%, 75%, 85%, 90%, 100% and 100%). The samples were subsequently cleared with a xylene solution in two steps for 2 hours, imbedded in paraffin wax at a temperature of 57–59 °C, and manually sectioned (5-7 μm) with a microtome. Finally, conventional (hematoxylin-eosin, HE) staining was applied to the sections [16],[17].

## Results

### Gills histopathology

In control group, the gill showed normal histological morphology (figure 1). Fish gill when treated with dose 0.01mg/L, 0.1mg/L of gentamicin showed epithelial cell hyperplasia in addition to hyperplasia of mucous cells, fusion of lamellae (figure 2), exposed to 1mg/L of gentamicin showed lifting of gill lamella and desquamation (figure 3) and exposed to 10 mg/L, the gill showed aneurysm (figure 4).

**Liver histopathology**

Liver consider main organ of antibiotic excretion, control group not exposed to gentamicin not showed any histological changes which characterized by presences of normal hepatocytes and hepatocytic nucleus (figure 5). Exposed to 0.01 not showed any

abnormal tissue structure, Fish liver exposed to 0.1mg/L showed only vacuolation (figure 6), dilation in space between sinusoids and cloudy swelling (figure7), exposed to 1mg/L showed hepatocyte hyper atrophy and degeneration (figure 8), exposed to 10µg/L showed inflammatory cells infiltration. All histopathological lesion observed in Table 1.

**Table 1.** showed the doses of gentamicinwith pathological changes of it on gills and liver.

Dose of gentamicin	Histopatological changes on gills	Histopathological changes on liver
Control group without gentamycin	No	No
Second group with 0.01 mg/L	Epithelial cells hyperplasia & hyperplasia of mucus cells	NO
third group with 0. 1 mg/L	Epithelial cells hyperplasia & hyperplasia of mucus cells	Vacuolation & sinusoidal dialation & cloudy swelling
fourth group with 1 mg/L	Lifting of gill lamellae & desquamatio	hyperatrophy of hepatocytes & degeneration
fifth group with 10 mg/L	Aneurysm	Inflammatory cells infiltration

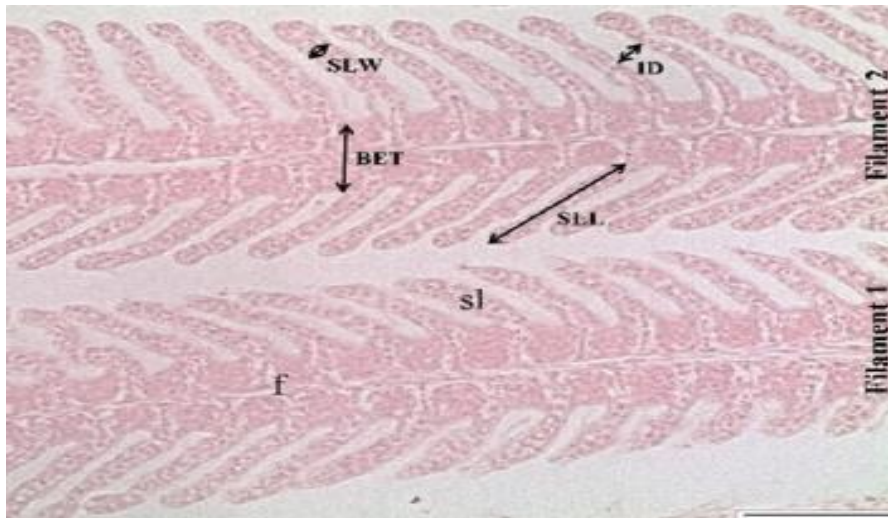


Figure 1. Microphotograph of *Cyprinus carpio* gill showed normal structure of gill filament and secondary lamellae (H&E stain 40X).

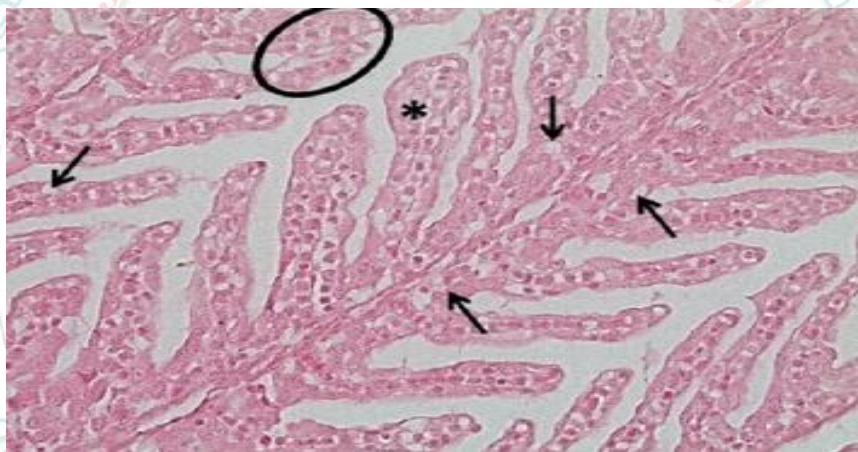


Figure 2. Microphotograph of *Cyprinus carpio* gill showed hyperplasia of epithelia (solid circle) and hyperplasia of mucosa cells (arrow) ,(H&E stain 40X).

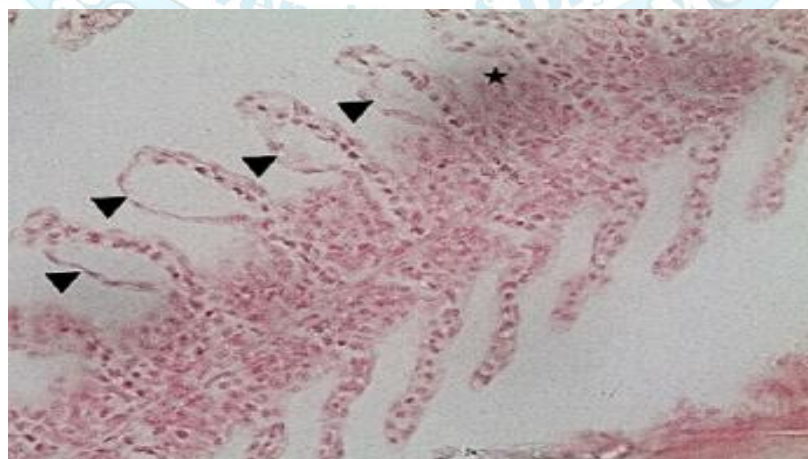


Figure3. Microphotograph of *Cyprinus carpio* gill showed lifting of gill lamellae (arrow head) and desquamation (star),(H&E stain 40X).

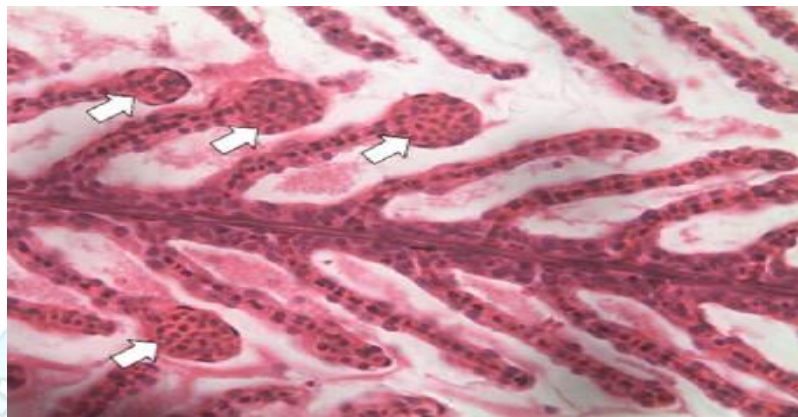


Figure 4. Microphotograph of *Cyprinus carpio* gill showed aneurysm of gill (white arrow),(H&E stain 40X).

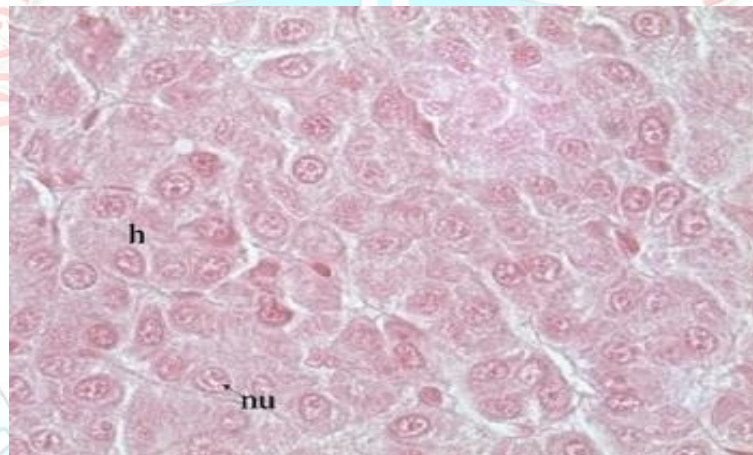


Figure 5. Microphotograph of *Cyprinus carpio* liver showed normal hepatocytes (h) and nucleus of it (nu),(H&E stain 40X).

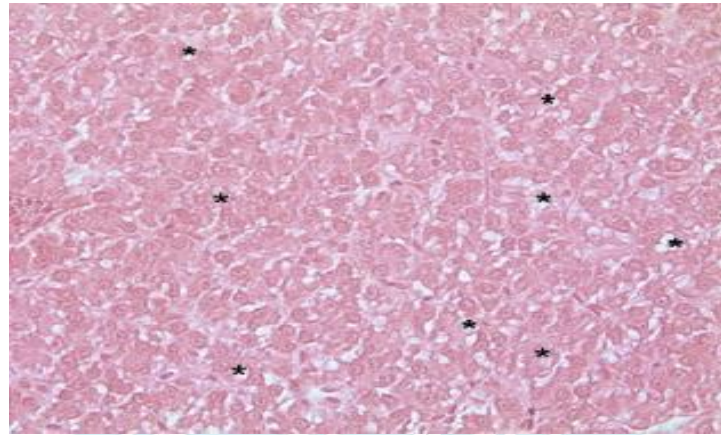


Figure 6. Microphotograph of Cyprinus carpio liver showed only vacuolation (star), (H&E stain 40X).

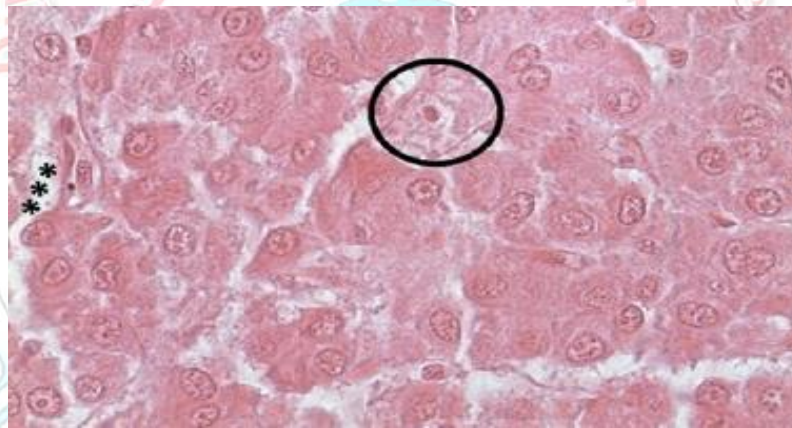


Figure 7. Microphotograph of Cyprinus carpio liver showed dilation of sinusoids (stars) and cloudy swelling (circle),(H&E stain 40X).

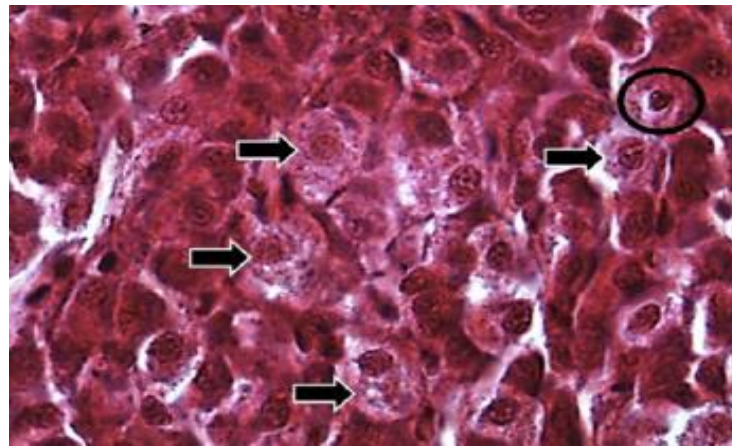


Figure 8. Microphotograph of *Cyprinus carpio* liver showed hepatocyte hypertrophy (arrow head) and degeneration of hepatocytes (circle) ,(H&E stain 40X).

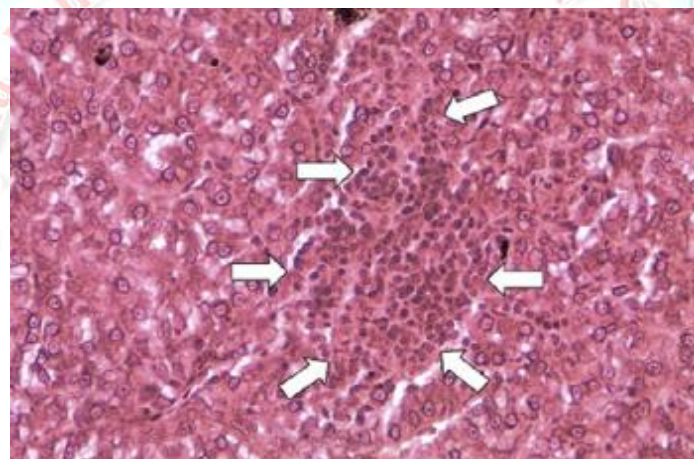


Figure 9. Microphotograph of *Cyprinus carpio* liver showed inflammatory cells infiltration ,(H&E stain 40X).

## Discussion

Gill are important fish organ which responsible of breathing under water, gases exchange, ions balance and nitrogen excretion, also control physiological function of fish in water [18]. The absorption and toxication occur by gill which provide

available area when contact with different water condition [19]. Infected of gill and or damage by contamination or toxic compounded lead to effect on gill function [20]. In current study the tissue damage of gill induced by gentamicin similar to other study reported because of exposed of *Cyprinus*



carpio to different metals by pollution [21] and insecticide [22]. Lesion recorded in this study may be classify into two types, firstly induced by direct exposure to heavy damage such as aneurisms while the second types induced by inflammatory reactions which including congestion and thickening of blood capillary. The presences of aneurisms caused by weakens of blood capillary integrity and push of highly blood which causes collapse of pillar cells and formation of abnormal blood collection vessels [23]. Some of pathological disorder in this study like congestion consider low important because of reversible condition of it. The important lesion which recorded in the gills including epithelial cells lifting, desquamations in addition to changes in gills structures [24]. The hyperplasia of mucus cells act as protective layer over the epithelium of gills and present of mucus secretion lead to movement of operculum which result in improve the breathing [25]. The increase histopathological lesions with increased doses of gentamicin represent influence of gills function by gentamicinin addition to that , the increase doses of gentamicin lead to increase in severity of lesions which present particular highest doses of gentamicin followed by other low acute lesions. The gentamicin causes decrease intake of oxygen from water and distribution

of ions changes which result from damage of the gills [26]. Lastly, the gentamicin causes production of free radicles which effect on cellular and tissue structures of gills [9]. In fish, the liver consider main organ of storage, metabolism and revel general health of it and effect by surrounding environment [27]. In current study, the liver of fish in control group showed normal histological structures, but when exposed to the different doses of gentamicin showed physiological abnormalities and this may be belong to histopathological changes, this changes include hepatocellular hyperplasia, hypertrophy, vacuolation and cloudy swelling. Liver of fish exposed to gentamicin showed inflammatory cells infiltration duo to immunological reaction which associated with degeneration of hepatocytes [28]. Deposition of glycogen or lipid causes presence of vacuolation that suggested accumulation of phospholipids by action of gentamicin which causes alteration in cell membrane and entrance of it inside the cells [29]. Some study mention the hepatocyte vacuole store insoluble polluted material lead to failure lipid metabolism, Metabolism of gentamicin product free radicle, lipid peroxidation causes destruction of cell membrane and hepatocellular degeneration [30]. Other changes reported in this study

were cloudy swelling which consider important sign of reversible injury duo to environmental disturbance and stress [31]. Sinusoidal dilation also reported in this study and similar to other study that said the liver is organ with high blood [32]. The degeneration of hepatocytes occurs as result of insufficient oxygen duo to distraction of gill epithelia [33]. Exposed of liver to gentamicin result in formation of free radicles [34]. In control group the liver not showed any histopathological lesions but when exposed to gentamycin, the different lesion are present which become severity by increased of doses such as vacuolation, hyperplasia, hypertrophy and cloudy swelling and this lead to effect on physiological activities of *Cyprinus carpio*.

## Conclusion

Gentamicin have beneficial influence in the common carp (*Cyprinus carpio*), Gentamicin histopathological effect increased with increase doses and period of exposure, Gill damage more than liver damage and the lesions were between reversible and irreversible injury comparative control group.

## References

[1] S. Jamaran and B. R. Zarif, "Synergistic effect of silver nanoparticles with neomycin or gentamicin antibiotics on mastitis-

causing *Staphylococcus aureus*," *Open J. Ecol.*, vol. 6, no. 7, pp. 452–459, 2016.

[2] K. R. Ball, J. E. Rubin, M. Chirino-Trejo, and P. M. Dowling, "Antimicrobial resistance and prevalence of canine uropathogens at the Western College of Veterinary Medicine Veterinary Teaching Hospital, 2002–2007," *Can. Vet. J.*, vol. 49, no. 10, p. 985, 2008.

[3] H. K. Streppa, M. J. Singer, and S. C. Budsberg, "Applications of local antimicrobial delivery systems in veterinary medicine," *J. Am. Vet. Med. Assoc.*, vol. 219, no. 1, pp. 40–48, 2001.

[4] R. Hari, S. Taherunnisa, S. Y. Raut, S. Mutalik, and K. B. Koteswara, "Challenges in the development of analytical test procedure for aminoglycosides: A critical review," *J. Appl. Pharm. Sci.*, vol. 9, no. 11, pp. 145–152, 2019.

[5] M.-L. Soran, I. Lung, O. Opris, V. Floare-Avram, and C. Coman, "Determination of antibiotics in surface water by solid-phase extraction and high-performance liquid chromatography with diode

- array and mass spectrometry detection,” *Anal. Lett.*, vol. 50, no. 7, pp. 1209–1218, 2017.
- [6] W. J. Van Trump, S. Coombs, K. Duncan, and M. J. McHenry, “Gentamicin is ototoxic to all hair cells in the fish lateral line system,” *Hear. Res.*, vol. 261, no. 1–2, pp. 42–50, 2010.
- [7] L. Liu, W. Wu, J. Zhang, P. Lv, L. Xu, and Y. Yan, “Progress of research on the toxicology of antibiotic pollution in aquatic organisms,” *Acta Ecol. Sin.*, vol. 38, no. 1, pp. 36–41, 2018.
- [8] X. Sun, Y. Yang, Q. Tian, D. Shang, J. Xing, and Y. Zhai, “Determination of gentamicin C components in fish tissues through SPE-Hypercarb-HPLC-MS/MS,” *J. Chromatogr. B*, vol. 1093, pp. 167–173, 2018.
- [9] E. Kondera, B. Bojarski, K. Ługowska, B. Kot, and M. Witeska, “Effects of oxytetracycline and gentamicin therapeutic doses on hematological, biochemical and hematopoietic parameters in *Cyprinus carpio* juveniles,” *Animals*, vol. 10, no. 12, p. 2278, 2020.
- [10] S. Rodrigues, S. C. Antunes, B. Nunes, and A. T. Correia, “Histopathological effects in gills and liver of *Sparus aurata* following acute and chronic exposures to erythromycin and oxytetracycline,” *Environ. Sci. Pollut. Res.*, vol. 26, pp. 15481–15495, 2019.
- [11] V. F. Samanidou and E. N. Evaggelopoulou, “Analytical strategies to determine antibiotic residues in fish,” *J. Sep. Sci.*, vol. 30, no. 16, pp. 2549–2569, 2007.
- [12] L. Vilizzi, “The common carp, *Cyprinus carpio*, in the Mediterranean region: origin, distribution, economic benefits, impacts and management,” *Fish. Manag. Ecol.*, vol. 19, no. 2, pp. 93–110, 2012.
- [13] K. kh Mustafa, S. Q. Maulud, and P. A. Hamad, “Antimicrobial Resistance of *Aeromonas salmonicida* Isolated From Common carp (*Cyprinus carpio*) Fishes in Erbil City/Iraq,” *Baghdad Sci. J.*, vol. 16, no. 3 Suppl., pp. 713–718, 2019.
- [14] L. Tong, S. Huang, Y. Wang, H. Liu, and M. Li, “Occurrence of

- antibiotics in the aquatic environment of Jiangnan Plain, central China,” *Sci. Total Environ.*, vol. 497, pp. 180–187, 2014.
- [15] G. D. Readman, S. F. Owen, T. G. Knowles, and J. C. Murrell, “Species specific anaesthetics for fish anaesthesia and euthanasia,” *Sci. Rep.*, vol. 7, no. 1, p. 7102, 2017.
- [16] M. Slaoui and L. Fiette, “Histopathology procedures: from tissue sampling to histopathological evaluation,” *Drug Saf. Eval. Methods Protoc.*, pp. 69–82, 2011.
- [17] M. A. Mahmood, “Effect of Ascorbic Acid on Hemato-Histopathological changes induced by Diclofenac Sodium in local Male Rabbits,” *Diyala J. Vet. Sci.*, vol. 1, no. 2, pp. 23–37, 2023.
- [18] A. K. Dymowska, P.-P. Hwang, and G. G. Goss, “Structure and function of ionocytes in the freshwater fish gill,” *Respir. Physiol. Neurobiol.*, vol. 184, no. 3, pp. 282–292, 2012.
- [19] S. F. Perry, A. Esbaugh, M. Braun, and K. M. Gilmour, “Gas transport and gill function in water-breathing fish,” *Cardio-respiratory Control Vertebr. Comp. Evol. Asp.*, pp. 5–42, 2009.
- [20] A. Taheri Mirghaed, M. Ghelichpour, S. S. Mirzargar, H. Joshaghani, and H. Ebrahimzadeh Mousavi, “Toxic effects of indoxacarb on gill and kidney histopathology and biochemical indicators in common carp (*Cyprinus carpio*),” *Aquac. Res.*, vol. 49, no. 4, pp. 1616–1627, 2018.
- [21] M. Forouhar Vajargah, A. Mohamadi Yalsuyi, A. Hedayati, and C. Faggio, “Histopathological lesions and toxicity in common carp (*Cyprinus carpio* L. 1758) induced by copper nanoparticles,” *Microsc. Res. Tech.*, vol. 81, no. 7, pp. 724–729, 2018.
- [22] I. Z. Qureshi, A. Bibi, S. Shahid, and M. Ghazanfar, “Exposure to sub-acute doses of fipronil and buprofezin in combination or alone induces biochemical, hematological, histopathological and genotoxic damage in common carp (*Cyprinus carpio* L.),” *Aquat. Toxicol.*, vol. 179, pp. 103–114, 2016.
- [23] S. Rajeshkumar, Y. Liu, J. Ma, H.

- Y. Duan, and X. Li, "Effects of exposure to multiple heavy metals on biochemical and histopathological alterations in common carp, *Cyprinus carpio* L.," *Fish Shellfish Immunol.*, vol. 70, pp. 461–472, 2017.
- [24] J. Blahova *et al.*, "Evaluation of biochemical, haematological, and histopathological responses and recovery ability of common carp (*Cyprinus carpio* L.) after acute exposure to atrazine herbicide," *Biomed Res. Int.*, vol. 2014, 2014.
- [25] J. A. C. Roques, W. Abbink, F. Geurds, H. van de Vis, and G. Flik, "Tailfin clipping, a painful procedure: studies on Nile tilapia and common carp," *Physiol. Behav.*, vol. 101, no. 4, pp. 533–540, 2010.
- [26] D. H. Evans, P. M. Piermarini, and K. P. Choe, "The multifunctional fish gill: dominant site of gas exchange, osmoregulation, acid-base regulation, and excretion of nitrogenous waste," *Physiol. Rev.*, vol. 85, no. 1, pp. 97–177, 2005.
- [27] J. Bruslé and G. G. i Anadon, "The structure and function of fish liver," in *Fish morphology*, Routledge, 2017, pp. 77–93.
- [28] S. A. Hedayati, R. Sheikh Veisi, S. P. Hosseini Shekarabi, S. Shahbazi Naserabad, D. Bagheri, and H. Ghafarifarsani, "Effect of dietary *Lactobacillus casei* on physiometabolic responses and liver histopathology in common carp (*Cyprinus carpio*) after exposure to iron oxide nanoparticles," *Biol. Trace Elem. Res.*, vol. 200, no. 7, pp. 3346–3354, 2022.
- [29] R. Vinodhini and M. Narayanan, "Heavy metal induced histopathological alterations in selected organs of the *Cyprinus carpio* L.(Common Carp)," 2009.
- [30] H. Xing, S. Li, Z. Wang, X. Gao, S. Xu, and X. Wang, "Oxidative stress response and histopathological changes due to atrazine and chlorpyrifos exposure in common carp," *Pestic. Biochem. Physiol.*, vol. 103, no. 1, pp. 74–80, 2012.
- [31] S. Sharmin, M. Shahjahan, M. A. Hossain, M. A. Haque, and H. Rashid, "Histopathological changes in liver and kidney of common carp exposed to sub-lethal doses of malathion.," *Pak. J. Zool.*, vol. 47,

- no. 5, 2015.
- [32] A. Modaberi, S. Kakoolaki, A. E. Khajeh-Rahimi, I. Sharifpour, and S. Safi, "Histological effects of water-soluble fraction of diesel (WSFD) on liver, gill, and kidney of common carp (*Cyprinus carpio*)," *Iran. J. Fish. Sci.*, vol. 21, no. 4, pp. 1064–1084, 2022.
- [33] A. J. Al-Rudainy and H. A. Khalel, "Histopathological changes (gills and liver) and clinical signs of common carp, *Cyprinus carpio* L. exposed to graphene nanoparticles.," *Iraqi J. Agric. Sci.*, vol. 50, no. 3, 2019.
- [34] M. Talat Abbas, M. Mustafa HashimZayni, and N. Ali Al-Kadhi, "Effect of GarlicOil on Gentamicin InducedHepatorenal Toxicity in rats," *J. kerbala Univ.*, vol. 9, pp. 109–117, 2013.
- [33] A. J. Al-Rudainy and H. A. Khalel, "Histopathological changes (gills and liver) and clinical signs of

