

Study The Effects of 5 Selenocyanotouracil Compound on The liver and Kidney of Male Rats After Acetaminophen-Induced Liver Injury

Sahar Muayad Noori^{*1}, Nadheerah Falih Neamah¹, Shaker A.N. Al-Jadaan²

¹ Department Pharmacology and Toxicology, College of Pharmacy, University of Basrah, Basrah, Iraq.

² Department Pharmaceutical Chemistry, College of Pharmacy, University of Basrah, Basrah, Iraq.

Abstract

Selenium compounds have long been assumed to protect organs against inflammation and cancer development by reducing oxidative stress and organ injury. Drug-induced liver injury is a common side effect of many medications such as acetaminophen, with main symptoms ranging from an increase in asymptomatic liver enzymes to liver failure. The main objective of the present work is to evaluate the possible protective effect of 5 selenocyanotouracil against liver and kidney damage induced by acetaminophen. Forty male rats were divided into 4 groups: **Group A:** rats were freely excess to food and water (negative control). **Group B:** rats were treated with acetaminophen (500mg/kg) (positive control). **Group C:** rats were given acetaminophen in the preceding dose, and 5 selenocyanotouracil (50 mg/kg). **Group D:** rats were treated with acetaminophen orally at the prior dose, and 5 selenocyanotouracil (100mg/kg) orally once daily for 21 days. According to biochemical data on alanine aminotransferase, aspartate aminotransferase, and creatinine serum level of 5 selenocyanotouracil-treated groups significantly decreased when compared to AAP-treated groups, but no significant differences were observed when compared to the negative control group. Histopathological examinations confirm such results. As a conclusion, 5 selenocyanotouracil compound has a protective activity against acetaminophen -induced tissue damage.

Keywords: 5-selenocyanotouracil, 5SeU, Acetaminophen, ALT, AST, Creatinine, Urea, Histopathology

دراسة آثار مركب ٥ سيليناسيانوتوراسيل على الكبد والكلية عند ذكور الجرذان بعد إصابة الكبد التي يسببها عقار الاسيتامينوفين

سحر مؤيد نوري^{*}، نظيرة فالح نعمه^١ و شاكرا عبد السالم الجدعان^٢

^١ فرع الادوية والسموم، كلية الصيدلة، جامعة البصرة، البصرة، العراق.
^٢ فرع الكيمياء الصيدلانية، كلية الصيدلة، جامعة البصرة، البصرة، العراق.

الخلاصة

منذ فترة طويلة يفترض أن مركبات السيلينيوم تحمي الأعضاء من الالتهاب وتطور السرطان عن طريق تقليل الإجهاد التأكسدي وإصابة الأعضاء. تعد إصابة الكبد الناتجة عن الأدوية من الآثار الجانبية الشائعة للعديد من الأدوية مثل عقار الاسيتامينوفين، وتتراوح الأعراض الرئيسية من زيادة إنزيمات الكبد بدون أعراض إلى فشل الكبد. الهدف الرئيسي من العمل الحالي هو تقييم التأثير الوقائي المحتمل لـ ٥ سيليناسيانوتوراسيل ضد تلف الكبد والكلية الناتج عن عقار الاسيتامينوفين. تم تقسيم أربعين من ذكور الجرذان إلى ٤ مجموعات: المجموعة أ: كانت الجرذان تتغذى بحرية على الطعام والماء (تحكم سلبية). المجموعة ب: عولجت الجرذان بأسييتامينوفين (٥٠٠ مجم / كجم) (تحكم إيجابي). المجموعة ج: أعطيت الجرذان اسيتامينوفين في الجرعة السابقة). المجموعة د عولجت الجرذان باستخدام عقار الاسيتامينوفين عن طريق الفم بجرعة سابقة، و ٥ سيليناسيانوتوراسيل (١٠٠ مجم / كجم) عن طريق الفم مرة واحدة يوميًا لمدة ٢١ يومًا. وفقا لبيانات الكيمياء الحيوية على ألانين أمينوترانسفيراز، أسبارتات أمينوترانسفيراز، ومستوى مصل الكرياتينين ٥ مجموعات سيلينوسيانوتوراسيل انخفض بشكل ملحوظ بالمقارنة مع المجموعات المعالجة بـ AAP، ولكن لم تلاحظ فروق ذات دلالة إحصائية عند مقارنتها بمجموعة التحكم السلبية. تؤكد فحوصات الأنسجة المرضية هذه النتائج. في الختام، مركب ٥ سيليناسيانوتوراسيل له نشاط وقائي ضد تلف الأنسجة الناتج عن عقار الاسيتامينوفين.

الكلمات المفتاحية: ٥ سيليناسيانوتوراسيل، 5SeU، أسيتامينوفين، ALT، AST، الكرياتينين، اليوريا، علم أمراض الأنسجة.

Introduction

Selenium (Se) has a vital physiological role as a potent antioxidant ⁽¹⁾. Se is required by living organisms because it is a part of the compound selenocysteine (Sec), which can be found in a number of selenoproteins ⁽²⁾. Se is found in at least 25 different selenoproteins ⁽³⁾. These proteins play several roles, the most important of which is redox homeostasis. Thirteen selenoproteins are oxidoreductases, with selenocysteine as the catalytic redox-active residue. The remaining twelve selenoproteins either have no known function or

have just a limited understanding of their functions ⁽⁴⁾. However, because of dietary and environmental factors as well as Se's limited safety range, diseases brought on by Se excess or deficiency have become much more prevalent in recent years ⁽⁵⁾. In humans, Se deficiency is a very common condition all around the world. It occurs when dietary intake is less than 40µg per day. Se deficiency has been linked to higher exposure to viral RNA infections ⁽⁶⁾.

*Corresponding author E-mail: saharalshemary@gmail.com

Received: 8/12/2022

Accepted: 6/2/2023

severe Se deficiency causes Keshan disease (cardiomyopathy) and Kashin–Beck disease (osteocondropathy) ⁽²⁾.

Antioxidants are compounds that have the ability to scavenge free radicals and decrease damage to biological tissues by lowering cellular oxidative stress ⁽⁷⁾. Due to the antioxidant characteristics of most selenoproteins, selenium has long been assumed to protect organs against inflammation and cancer development by reducing oxidative stress ⁽⁸⁾. Artificial selenium-containing compounds can be used to treat a variety of diseases, including cancer and infections due to their antioxidant properties ⁽⁹⁾. When the balance between reactive oxygen species (ROS) generation and elimination favors an elevation in ROS levels, oxidative stress occurs, causing cellular function to be disrupted ⁽¹⁰⁾. ROS are a group of radicals or ions created when oxygen is added, they are characterized by their high capacity for oxidation and instability ⁽¹¹⁾. Drug-induced liver injury is a common side effect of many medications, with main symptoms ranging from an increase in asymptomatic liver enzymes to liver failure ⁽¹²⁾. For many years, paracetamol has been widely used as an analgesic and antipyretic throughout the world ⁽¹³⁾. In our study, acetaminophen (AAP) was used as an oxidative stress inducer to cause liver injury. Many studies have found that oxidative stress is associated with various toxicities with AAP, and numerous antioxidants have been studied to see if they can protect against AAP-induced liver toxicity ⁽¹⁴⁾.

Laboratory testing is essential for identifying and monitoring liver disease and injury. Plasma markers of injury the aspartate and alanine aminotransferases (AST and ALT, respectively) are the most commonly used injury markers ⁽¹⁵⁾. So It is commonly accepted that the serum level of ALT/AST ratio is a better indicator of liver damage ⁽¹⁶⁾. The ALT enzyme is found in serum and organ tissues, especially liver, although significant concentrations are also found in kidney, skeletal muscle, and myocardium, whereas AST is produced in the liver, heart and muscles ⁽¹⁷⁾. AST concentrations in the human plasma range from 5 to 40 U/L, while ALT concentrations range from 5 to 35 U/L. In cases of heart, liver or muscle disease or injury, the levels of AST or ALT increase ⁽¹⁸⁾. Another enzyme found in the liver, kidneys, intestines, and bone is called ALP. primarily used for cholestasis diagnosis ⁽¹⁹⁾. Renal function test evaluation is now used as an indicator in the long-term treatment of a variety of disorders because it is quick, easy - to - understand, accurate, relatively inexpensive, and precise ⁽²⁰⁾. Two crucial parameters, serum creatinine and urea, are used to diagnose and treat kidney diseases and modify drug doses. Since creatinine is thought to be a more accurate indicator of kidney function than urea, the requirement for a perfect filtration indicator is

justified ⁽²¹⁾. Urea is a metabolic waste product excreted in urine by the kidneys ⁽²²⁾, while creatinine is derived from the breakdown of creatine and phosphocreatine in muscle ⁽²³⁾.

Material and Method

Materials

Drugs and chemicals that are used in this study are: Acetaminophen powder from (SAMA AL FAYHAA for Pharmaceutical Industries), 10% formalin solution (SDFCL, India) 5 Selenocyanatouracil (5SeU) (a novel synthesized compound newly prepared from the reaction of KSeCN with 5-Iodouracil in an aqueous medium, in the central lab/College of Pharmacy/University of Basrah), 0.9% normal saline (pioneer, Iraq)

Animals

Forty male albino rats were purchased from a pet vet clinic in Erbil, in the north of Iraq. The rats (150-250g) in weight were housed in polypropylene cages (5 rats per cage). Rats were fed commercial pellets with distilled water. The rats were first housed under the natural lighting and temperature of the laboratory (21±4°C).

Experimental design

Forty male albino rats were randomly allocated into (4) groups, each group with (10) rats: **Group A:** rats were freely excess to food and water (negative control). **Group B:** rats were given acetaminophen (500mg/kg dissolved in 2 ml of DW) once per day for three weeks) ⁽²⁴⁾ (positive control). **Group C:** rats were given acetaminophen in the preceding dose, and 30 minutes later, they were given 5SeU (50 mg/kg dissolved in 2 ml of DW) orally once daily for 21 days. **Group D:** rats were given acetaminophen orally at the prior dose, and 30 minutes later, they were given 5SeU (100mg/kg dissolved in 2ml DW) orally once daily for 21 days. After a 21-day of treatment, the rats were anesthetized for blood drawing (about 3ml) from the heart, blood samples were collected in gel tubes and centrifuged for 10 minutes at 4000 rpm and stored at -20 °C until biochemical parameters were assessed (liver enzymes (ALT, AST), urea, and creatinine). The liver and kidneys were removed and washed with 0.9% saline solution. After being preserved in 10% formalin then embedded in paraffin wax, the samples were cut into 5 µm slices, and Hematoxylin and eosin staining were applied to the slices (H and E) in Al BASMA Lab in Baghdad. The result was discussed by a specialist histopathologist at the College of Veterinary Medicine/Basrah University.

Statistical analysis

Results are expressed as the mean± S.D. Statistical analysis was performed using the SPSS statistical package. One-way ANOVA comparisons were used to examine differences between test groups. Differences with p<0.05 were regarded as statistically significant.

Results

Effect of 5 selenocyanotouracil on liver enzymes Alanine aminotransferase (ALT)

Alanine aminotransferase serum level increased significantly (p<0.05) in B group when compared with A group after AAP treatment. While ALT serum levels decreased significantly (p<0.05) in C group in comparison with B group. Serum ALT levels were significantly (p<0.05) lower in D group when compared with B group as shown in the Figure (1) and Table (1) below.

Aspartate aminotransferase (AST)

Aspartate aminotransferase serum level increased significantly (p<0.05) in B group when compared with A group. While AST serum levels in C group decreased significantly (p<0.05) when compared with B group. D group reported significantly (p<0.05) lower serum AST levels when compared to B group as shown in Figure (2) and Table (1).

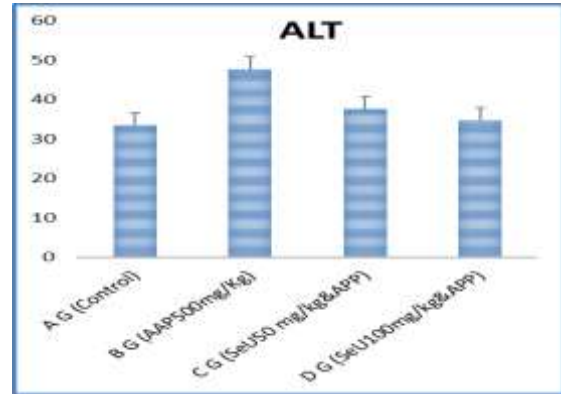


Figure1. ALT serum level in A, B, C and D groups.

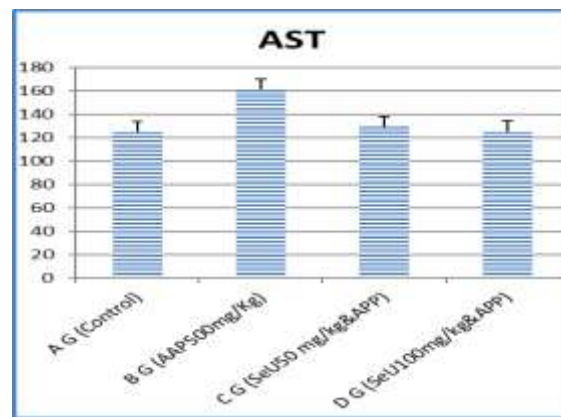


Figure2. AST serum level in A, B, C and D groups

Table 1. Liver functions enzymes of experiment groups.

Liver function test Groups	ALT (IU/L)	AST (IU/L)
A (Control)	34.625 ± 2.499	125.37 ± 15.023
B (AAP 500mg/Kg)	47.625 ± 1.812 a	157.98 ± 15.508 a
C (5SeU 50 mg/kg+ AAP 500mg/Kg)	37.125 ± 5.249 b	129.07 ± 9.220 b
D (5SeU 100mg/kg+ AAP 500mg/Kg)	35.3750 ± 4.718 b	125.00 ± 25.929 b
LSD	10.50	28.91

Values are expressed as mean + standard deviation. a –refer to significant differences with the control group, b- refer to mean significant differences with the AAP group. p<0.05. The reference ranges of AST, ALT are 50 to 150 IU/L, 10 to 40 IU/L respectively (25)

Effect of 5 selenocyanotouracil on Renal Functions Serum creatinine

The difference between the serum creatinine levels of C, and D groups were significantly decreased than in B group, only B group increased significantly than A group as shown in Figure (3) and Table (2).

Serum Urea

The difference between the serum urea levels of C, and D groups were not statistically significant either with A group (negative control) or with B group (positive control), as shown in Figure (4) and Table (2).

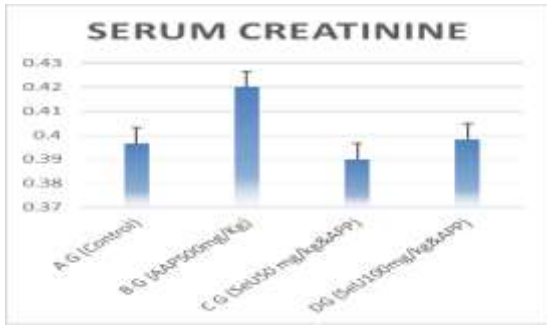


Figure 3. Creatinine serum level in A, B, C and D groups.

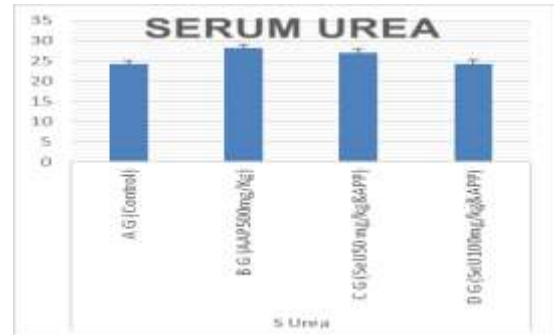

Figure 4 . Urea level in serum of the rats in A, B, and D groups

Table 2. Renal functions parameters of experiment groups.

Renal function test Groups	Urea (mg/dl)	Creatinine (mg/dl)
A (Control)	24.3750 ± 3.24863	0.3975 ± 0.01488
B (AAP 500mg/Kg)	27.1250 ± 6.62112	0.425 ± 0.02268 a
C (5SeU 50 mg/kg+ AAP 500mg/Kg)	25.7500 ± 4.06202	0.3937 ± 0.01923 b
D (5SeU 100mg/kg+ AAP 500mg/Kg)	24.5000 ± 6.32456	0.395 ± 0.02268 b
LSD	NS	0.027

a –refer to significant differences with control group, b-refer to mean significant differences with positive group. p<0.05.

Histopathological Examination

Effects on Liver

A group (Control group)

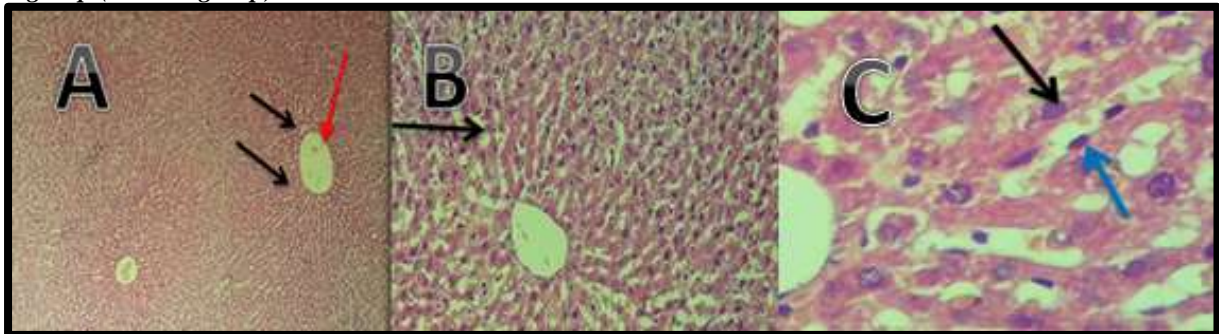


Figure 5. Liver sections of rats in control group showing normal hepatic architecture. Intact blood vessels (red arrows), normal hepatocytes (black arrows) and Kupffer cells (blue arrows), no signs of congestion. Harris' hematoxylin and eosin stain, A : 4x; B: 10x; C:40x.

B group (Paracetamol group 500mg/kg).

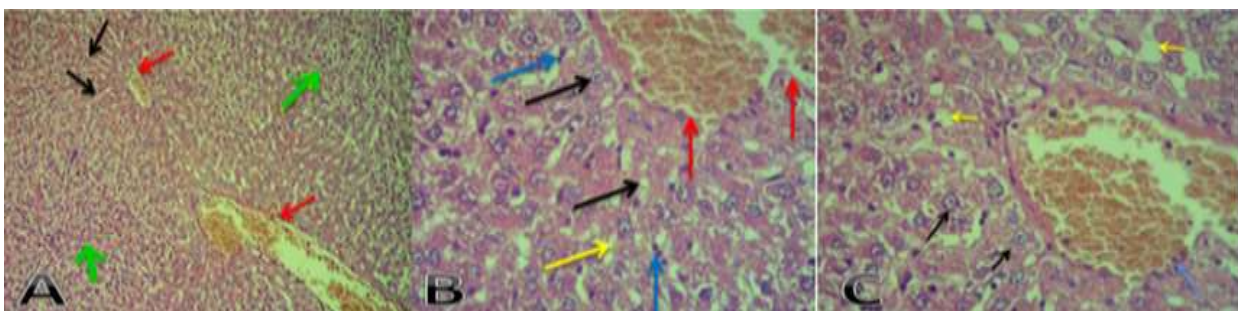


Figure 6. Liver sections of rats in AAP group showed abnormal trabecular structure (black arrows), fatty degeneration of hepatocytes (yellow arrows), inflammatory cells and necrotic debris (green arrows), a large number of Kupffer cells (blue arrows). Harris' hematoxylin and eosin staining, A : 4x, B: 10x, C:40x.

C group (5SeU 50mg/kg+paracetamol 500mg/kg)

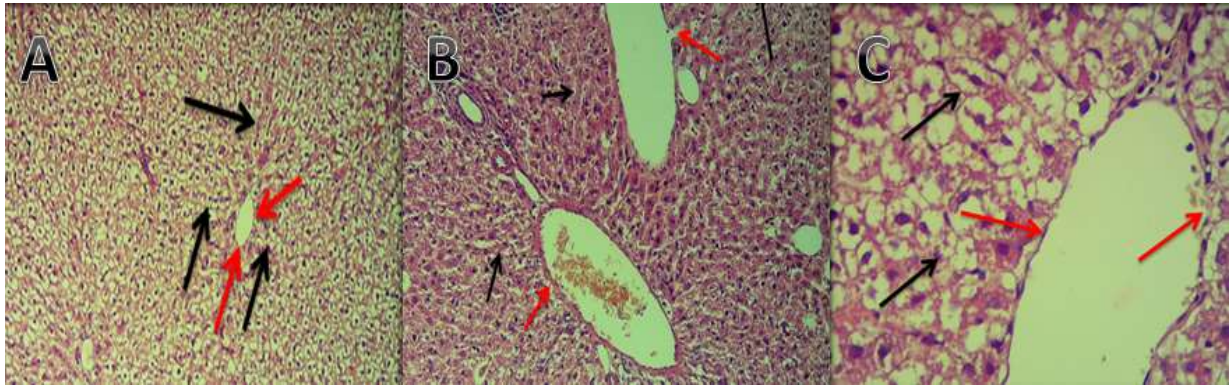


Figure 7. Liver sections of rats in 5SeU&AAP group, showed regular hepatic cell and intact central vein with disappearing of congestion. A: 4x, B:10x, C:40X (Harris' hematoxylin and eosin stain).

D group (5SeU100mg/kg+paracetamol 500mg/kg)

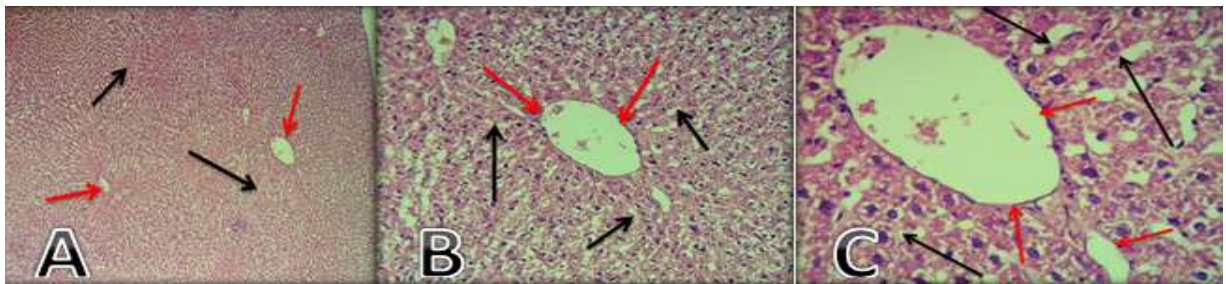


Figure8. Liver sections of rats in 5SeU(100mg/kg)&AAP group, showed normal hepatic cell, normal hepatic architecture and normal central vein with no signs of congestion. (Harris' hematoxylin and eosin stain).

Effects on Kidney

A group (Control group)

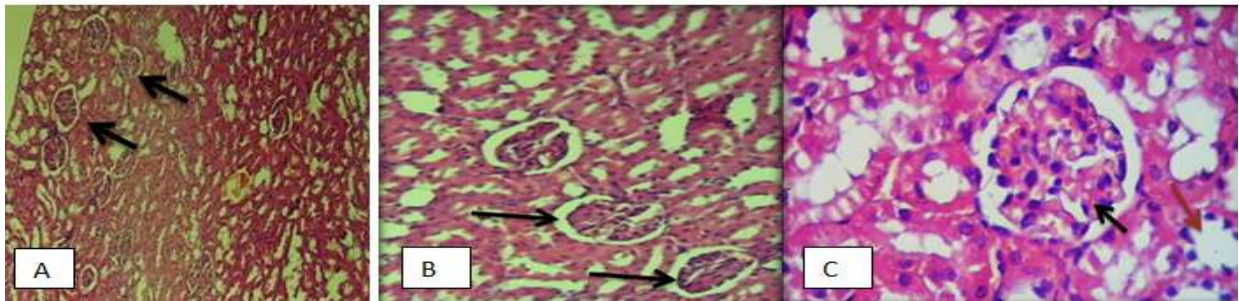


Figure9. Kidney section of rats in control group. A: at 4x, B :at 10x and C: at 40x.

B group (Paracetamol group 500mg/kg)

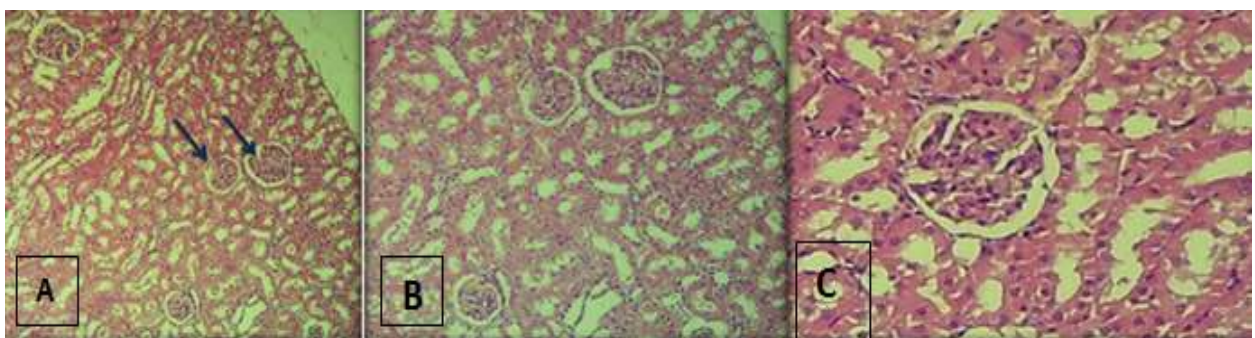


Figure10. Kidney section of rats in AAP group. A: at 4x, B :at 10x and C: at 40x.

C group (5SeU 50mg/kg+paracetamol 500mg/kg)

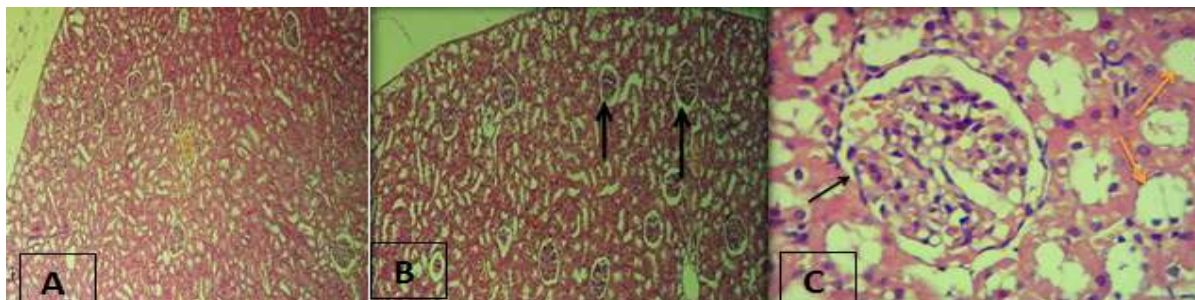


Figure11. Kidney section of rats in 5SeU(50mg/kg)&AAP group. A: at 4x, B :at 10x and C: at 40x.

D group (5SeU100mg/kg+paracetamol 500mg/kg)

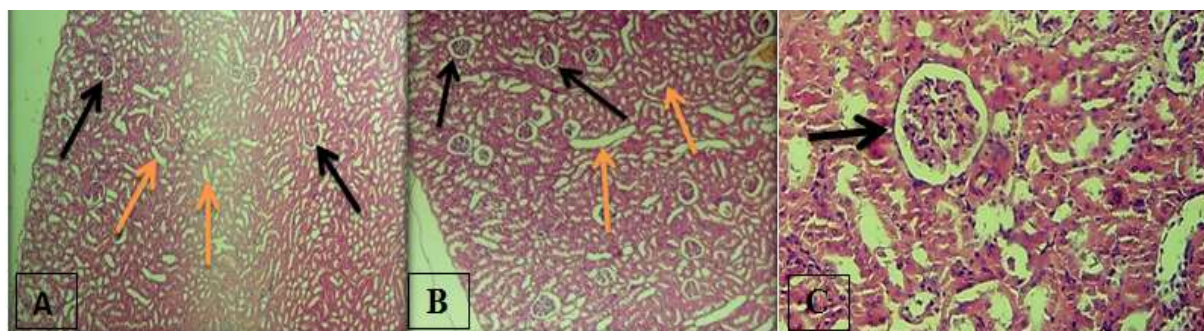


Figure12.Kidney section of rats in 5SeU(100mg/kg)&AAP group. A: at 4x, B :at 10x and C: at 40x.

Discussion

Effect of 5 Selenocyanotouracil on liver enzymes

In general, liver enzymes are used in both humans and animals to diagnose liver diseases and monitor how the liver reacts to toxic drugs ⁽²⁶⁾. As a result of AAP overdose, variations in serum AST, ALT levels regarded as vital signs of hepatocyte physical injury. Liver enzymes play a role in energy metabolism involving the transamination of amino acids proceeding at many tissues, such as liver, cardiac muscle, and brain. AST, ALT can overflow into the circulation in cases of cellular damage, resulting in elevated activity ⁽²⁷⁾. According to the results of our study, selenium has been shown to enhance liver function by reducing serum AST and ALT levels. The study's findings agree with those of Reja et al. 2020 and Ozardali et al. 2004. Therefore, selenium supplementation may be useful in the treatment of severe liver disease. So because of their higher antioxidant properties, selenium may have hepatoprotective activity^{(28),(29)}. The National Academy of Sciences (NAS) suggests dietary intake of about 55 µg of Se/day for adults for maximum glutathione activity ⁽³⁰⁾.

Effect of 5 Selenocyanotouracil on renal parameters

The kidneys are crucial for the removal of wastes and toxins like urea, creatinine, and uric acid in addition to performing other functions. Renal function tests are essential for determining the occurrence of renal disease and for monitoring the progression of the kidneys' recovery by observing

how they react to treatment ⁽³¹⁾. In clinical findings, urea and creatinine are key indicators of renal dysfunction. Thus, serum urea and creatinine levels were measured to determine kidney damage ⁽³²⁾. The liver produces urea, a nitrogenous waste product that is dispersed throughout both intracellular and extracellular fluid as a result of the catabolism of protein and amino acids. The kidneys' glomeruli eliminate urea from the blood, and some of it is then partially reabsorbed. Based on muscle mass, the body creates creatinine at a consistent rate as a byproduct of the breakdown of creatine phosphate in muscle ⁽³³⁾.

In the present study, urea levels of positive control group (B group) and negative control (A group), showed no significant altered by Se treatment, while creatinine levels increased significantly in positive group in comparison with negative control group, but 5SeU treated group revealed no significant changes compared to control, so our findings are in agreement with Omrani et al.2016, who found that in, selenium supplementation seemed to have no effect on blood urea nitrogen (BUN) or creatinine levels ⁽³⁴⁾. El-Shenawy and Hassan's 2008 findings were also in agreement with our results that rats given selenium orally did not show any significant changes in serum levels of BUN or creatinine ⁽³⁵⁾. Another study (Musik, Kieczkowska, and Donica 2013) found that cyclic selenoorganic compounds didn't result in many significant changes in the studied parameters, so the results of selenium on biochemistry

parameters of blood revealed that urea remained unchanged, as in our research ⁽³⁶⁾. Our findings contradict those of Hasanvand et al. 2017, who discovered that in the ischemia-reperfusion injury group (which resulted in renal dysfunction) the levels of urea and serum creatinine (Cr) increased significantly more than in the control group, and that Se treatment significantly reduced these indicators. Finally, selenium protects against ischemia-reperfusion injury. This effect could be believed to be due to selenium's antioxidant properties ⁽³⁷⁾. Another study, Nadheerah et al. 2019, which presupposed that synthetically produced novel selenadiazole derivatives have minor effects on the kidney, contradicts our findings ⁽⁹⁾.

Histopathological examination

Effect on liver

The liver is the primary organ of metabolism and detoxification of many drug and toxin. AAP administration has caused parenchymal cell necrosis as well as cholestatic injury, as demonstrated by increased serum liver injury biomarkers and decreased protein synthesis from the liver ⁽³⁸⁾. Hepatocytes are quiescent, nonproductive for the cell cycle (G0 phase). Following AAP induced liver injury induction, cells begin to arrive the cell cycle and restart other phases, G1 mitosis process and S phase, when replication of DNA arises, followed by means of G2 in which the cell is divided ⁽³⁹⁾. When paracetamol is consumed in large amounts, the P-450-dependent metabolism creates the reactive product N-acetyl-p-benzoquinone imine (NAPQI), this excess NAPQI causes liver necrosis by depleting glutathione resulting in release of hepatocellular content into the blood ⁽⁴⁰⁾. The inflammatory response, which may be a cellular factor in healing, is primarily cause the death of necrotic cells. Prior to the onset of cellular mitosis, the two main inflammatory cells involved in AAP-induced liver damage are neutrophils and macrophages. By removing injured tissues that will be replaced with new cells, macrophage activation has been shown to aid hepatocyte proliferation ⁽³⁹⁾.

As shown in fig.5 above, a control rats liver, it consists of outer hepatic triplets or tetrads embedded in the connective tissue and hexagonal or pentagonal lobules with central veins, hepatocytes are organized into bands that radiate from the central vein, and Kupffer cells-containing sinusoids serve as the dividers between the bands. They have a regular shape, a sizable spheroidal nucleus, a well-defined nucleolus, and a dispersion of chromatin along the periphery. Some cells each contain two nuclei. Liver slices photographed under a microscope after taking paracetamol concurrently, the trabecular structure is blurred in the majority of hepatic lobules, sinusoid congestion and dilated central veins. Empty regions resembling vacuoles of cytoplasmic fatty changes can be observed in the hepatocytes and pyknotic

nuclei. In the sinusoid walls, a sizeable number of Kupffer cells, sinusoid congestion, and dilated central veins are seen. Also, rat's liver in positive control group exhibits a focal area of a microabscess made up of inflammatory cells and necrotic debris as shown in fig.6 above. Rat's liver following a three-week exposure to AAP (500 mg/kg) and 5SeU (50 mg/kg) was examined. There are usually no evidence of blood vessel dilation and mostly intact epithelium in most hepatic lobules, trabecular structures are slightly distorted and divided by sinusoids containing Kupffer cells. Occasionally, cells with empty areas resembling vacuoles can be seen in the cytoplasm. In the sinusoid walls, there are slightly more Kupffer cells than elsewhere. Hepatocytes are regular and have a big spheroidal nucleus as shown in fig.7 above. The section in the liver from 5SeU (100mg/kg)&AAP group, showed hepatocytes are arranged into stripes that spread beginning from central vein, and the bars separated via sinusoids that have Kupffer-cells. In most hepatic lobules, they have a regular shape, a large spheroidal nucleus, an obviously identified nucleolus, no signs of blood vessel dilation, and largely intact epithelium as shown in fig.8 above. Similar to our study, studies of Nadheerah et al. 2019 and Sabah Ansar et al. 2017 discovered minor differences in liver physiology between control and Se treated groups. Histopathological investigation revealed that selenium has a protective effect against AAP-induced liver damage ⁽⁴¹⁻⁴²⁾.

Effects on kidney

As shown in the fig.9 above, a control rat's kidney (cortical portion). The structure of the renal glomeruli is normal. The usual thick cubic epithelium that lines the renal tubules is present. The cubic epithelium density, and the lumen of the tubules are quite uniform and distinct. It is possible to see the glomerule's lobular arrangement, the flat epithelium liner the glomerular capsule. Regarding the kidney section, Typical histological features of the kidney followed AAP alone or in combination with 5SeU (50mg or 100)mg/kg BW (H&E staining). Renal tissue slices photographed under a microscopic examination showed normal glomerular structure, and renal tubules. No signs of congestion or necrosis or glomerular atrophy as shown in the fig. (10, 11 and 12) above. The kidney is involved in the elimination of many drugs and their metabolites ⁽³⁸⁾. The nephrotoxic effects of AAP overdose are caused by complex events. In most cases, AAP-induced nephrotoxicity appears after hepatotoxicity, Some of the possible mechanisms of nephrotoxicity identified in clinical and animal studies include the cytochrome P-450 pathway, N-deacetylase enzymes, and prostaglandin synthesis ⁽⁴⁰⁾. Selenium works as a cofactor for an antioxidant enzyme, but it is not a pure antioxidant. The effects of selenium on chronic kidney disease may be related to the following

factors. The first effect of selenium is an increase in Glutathione peroxidase 3 activity, which may protect kidney function by preventing mitochondrial damage caused by high oxidative stress⁽⁴³⁾. Second, selenium influences phagocytes, immunoglobulin, and T cells to enhance human immunity. Third, selenium is crucial for thyroid function, which affects renal hemodynamics⁽⁴⁴⁾. In a study with 1,871 participants, Hiragi et al. (2018) provided epidemiological data on the relationship between AAP overdose and the frequency of acute renal damage. The outcomes revealed no association between AAP and acute renal damage, confirming general physicians' assumptions that AAP is less harmful to the kidneys and agree with our study⁽⁴⁵⁾. A study by Tsekhmistrenko et al. 2021 found that giving albino rats selenium for 30 days did not significantly alter their weights in the kidneys. In agreement with the findings, there were no detectable variations among the selenium groups and control group⁽⁴⁶⁾.

Conclusion

In a dose-dependent manner, 5 SeU exhibits good antioxidant and anti-inflammatory effects. (5SeU) has a protective effect against paracetamol damage effect on the liver, and kidney. Histopathological study confirms such results can be concluded that 5SeU has a protective effect against acetaminophen -induced liver damage.

Acknowledgment

This work developed from a master's thesis presented to the University of Basrah/ College of Pharmacy. The authors would like to thank the Department of Pharmacology and Toxicology at Al-Basrah University's College of Pharmacy.

Conflict of Interest

The are no conflict of interest.

Funding

Nil.

Ethics Statement

The study was approved by the college of pharmacy /University of Basrah.

Author Contribution

Sahar Muayad Noori: Animals data collection and analysis, writing the thesis and research ,preparation of manuscript to publication .Nadheerah Falih Neamah: Preparation of 5 Selenocyanotouracil compound, supervision the work and anatomy of animals.Shaker A.N. Al-Jadaan: Preparation 5 Selenocyanotouracil compound and supervision the research and thesis.

References

1. Series C. In Vitro and in Vivo Measurements of ROS Scavenging Activity and White Blood Cells Activity by Chemiluminescence of a New Selena- Diazole Derivative Compare to Dipyrone Activity In Vitro and in Vivo Measurements of ROS Scavenging Activity and White Blood . 2021;
2. Minich WB. Selenium Metabolism and Biosynthesis of Selenoproteins in the Human Body. *Biochemistry (Moscow)*. 2022;87:S168–77.
3. Hosny NS, Hashem NM, Morsy AS, Abo-elezz ZR. Effects of Organic Selenium on the Physiological Response, Blood Metabolites, Redox Status, Semen Quality, and Fertility of Rabbit Bucks Kept Under Natural Heat Stress Conditions. *Frontiers in Veterinary Science*. 2020;7(June):1–14.
4. Regina BF, Gladyshev VN, Arnér ES, Berry MJ, Bruford EA, Burk RF, et al. Selenoprotein gene nomenclature. *Journal of Biological Chemistry*. 2016;291(46):24036–40.
5. Huang X, Dong YL, Li T, Xiong W, Zhang X, Wang PJ, et al. Dietary selenium regulates micromnas in metabolic disease: Recent progress. *Nutrients*. 2021;13(5):1–14.
6. Gorini F, Sabatino L, Pingitore A, Vassalle C. Selenium: An element of life essential for thyroid function. *Molecules*. 2021;26(23):1–14.
7. MUHAMMAD-ALI MA, HAMZA SALMAN H, JASIM E. Antioxidant Activity of Some Newly Prepared Symmetrically Azo Dyes Derived From Sulfa Drugs. *Asian Journal of Pharmaceutical and Clinical Research*. 2019;12(2):479–83.
8. Liu Q, Du P, Zhu Y, Zhang X, Cai J, Zhang Z. Thioredoxin reductase 3 suppression promotes colitis and carcinogenesis via activating pyroptosis and necrosis. *Cellular and Molecular Life Sciences*. 2022;79(2).
9. Neamah NF, Naaem Khudair AR, Al-Jadaan SAN. Comparative evaluation of biochemical profiling of 4', 4"- (4, 5, 6, 7-TETRAHYDRO-[1, 2, 3-] SELENADIAZOLO [4, 5e] PYRIDINE-4, 6-DIYL) BIS (BENZENE-1, 3-DIOL) and dipyrone on female rat's. *Journal of Physics: Conference Series*. 2019;1279(1).
10. Elsayed Azab A, A Adwas Almokhtar, Ibrahim Elsayed AS, A Adwas A, Ibrahim Elsayed Ata Sedik, Quwaydir FA. Oxidative stress and antioxidant mechanisms in human body. *Journal of Applied Biotechnology & Bioengineering*. 2019;6(1):43–7.
11. AL-Aloosy YAM, AL-Tameemi AJH, Jumaa SS. The role of enzymatic and non-enzymatic antioxidants in facing the environmental stresses on plant: A review. *Plant Archives*. 2019;19(June):1057–60.
12. MAYSAA BANAY ZUBAIRI. Metoprolol-Induced Liver Injury and the Hepatoprotective Role of Vitamin E in Rabbits. *Asian Journal of Pharmaceutical and Clinical Research*. 2019;12(4):145–8.
13. Jaccob AA, Ahmed ZH, Aljasani BM. Vitamin C, omega-3 and paracetamol pharmacokinetic

- interactions using saliva specimens as determiners. 2019;30(5). Available from: <https://doi.org/10.1515/jbcpp-2019-0011>
14. Wang X, Wu Q, Liu A, Anadón A, Rodríguez J-L, Martínez-Larrañaga M-R, et al. Paracetamol: overdose-induced oxidative stress toxicity, metabolism, and protective effects of various compounds in vivo and in vitro. *Drug metabolism reviews*. 2017 Nov;49(4):395–437.
 15. McGill MR. The past and present of serum aminotransferases and the future of liver injury biomarkers. *EXCLI Journal* [Internet]. 2016; 15 : 817–28. Available from: <http://dx.doi.org/10.17179/excli2016-800> ; <http://creativecommons.org/licenses/by/4.0/>
 16. Chen SL, Li JP, Li LF, Zeng T, He X. Elevated preoperative serum alanine aminotransferase/aspartate aminotransferase (ALT/AST) ratio is associated with better prognosis in patients undergoing curative treatment for gastric adenocarcinoma. *International Journal of Molecular Sciences*. 2016;17(6):1–11.
 17. Yokoyama M, Watanabe T, Otaki Y, Takahashi H, Arimoto T, Shishido T, et al. Association of the aspartate amino-transferase to alanine aminotransferase ratio with BNP level and cardiovascular mortality in the general population: The Yamagata study 10-year follow-up. *Disease Markers*. 2016;2016.
 18. Wang HL, Chu CH, Tsai SJ, Yang RJ. Aspartate aminotransferase and alanine aminotransferase detection on paper-based analytical devices with inkjet printer-sprayed reagents. *Micromachines*. 2016 ;7 (1) :1–10.
 19. Kasarala G, Tillmann HL. Standard liver tests. *Clinical Liver Disease*. 2016 ;8(1) :13–8.
 20. Bamanikar S, Bamanikar A, Arora A. Study of Serum urea and Creatinine in Diabetic and non-diabetic patients in a tertiary teaching hospital. *The Journal of Medical Research*. 2016;2(1):12–5.
 21. Lalla P, Banu Pathan S, Jawade P. Correlation of Serum Urea and Serum Creatinine in Diabetics patients and normal individuals. *International Journal of Clinical Biochemistry and Research*. 2020;7(1):45–8.
 22. Higgins C. Urea and the clinical value of measuring blood urea concentration. *Radiometer Medical ApS* [Internet]. 2016; (August):1–6. Available from: <https://acutecaretesting.org/~media/acute-caretesting/files/pdf/urea-and-the-clinical-value-of-measuring-blood-ans-approved.pdf> ; <https://acute-caretesting.org/~media/acute-caretesting/files/pdf/urea-and-the-clinical-value-of-measuring-blood-ans-approved.pdf>
 23. Sahi DN. A Comparative Study of Serum C-Reactive Protein, Urea and Creatinine Levels in Chronic Kidney Disease Patients with Normal Subjects. *Journal of Medical Science And Clinical Research*. 2019 ;7(3) :1480–3.
 24. Majeed SK, Ramadhan MA, Monther W. Long-term toxicological effects of paracetamol in rats. *Iraqi Journal of Veterinary Sciences*. 2013 ;27(1):65–70.
 25. Hasan KMM, Tamanna N, Haque MA. Biochemical and histopathological profiling of Wistar rat treated with Brassica napus as a supplementary feed. *Food Science and Human Wellness* [Internet]. 2018;7 (1):77–82. Available from: <https://doi.org/10.1016/j.fshw.2017.12.002>
 26. Alahmadi BA, El-Alfy SH, Hemaïd AM, Abdel-Nabi IM. The protective effects of vitamin E against selenium-induced oxidative damage and hepatotoxicity in rats. *Journal of Taibah University for Science* [Internet]. 2020;14(1):709–20. Available from: <https://doi.org/10.1080/16583655.2020.1769256>
 27. Łanocha-Arendarczyk N, Baranowska-Bosiacka I, Kot K, Pilarczyk B, Tomza-Marciniak A, Kabat-Koperska J, et al. Biochemical profile, liver and kidney selenium (Se) status during acanthamoebiasis in a mouse model. *Folia Biologica (Poland)*. 2018;66(1):33–40.
 28. Reja M, Makar M, Visaria A, Marino D, Rustgi V. Increased serum selenium levels are associated with reduced risk of advanced liver fibrosis and all-cause mortality in NAFLD patients: National Health and Nutrition Examination Survey (NHANES) III. *Annals of Hepatology*. 2020;19(6):635–40.
 29. Ozardali I, Bitiren M, Karakilçik AZ, Zerim M, Aksoy N, Musa D. Effects of selenium on histopathological and enzymatic changes in experimental liver injury of rats. *Experimental and toxicologic pathology: official journal of the Gesellschaft für Toxikologische Pathologie*. 2004 Oct;56(1–2):59–64.
 30. Zwolak I. The Role of Selenium in Arsenic and Cadmium Toxicity: an Updated Review of Scientific Literature. *Biological Trace Element Research*. 2020;193(1):44–63.
 31. Gounden V, Bhatt H, Jialal I. Renal Function Tests [Internet]. University of KwaZulu Natal: StatPearls Publishing, Treasure Island (FL); 2021. Available from: <http://europepmc.org/abstract/MED/29939598>
 32. Reshi MS, Yadav D, Uthra C, Shrivastava S, Shukla S. Acetaminophen-induced renal toxicity: preventive effect of silver nanoparticles. *Toxicology Research*. 2020;9(4):406–12.
 33. Refaie AAER, Ramadan A, Mossa ATH. Oxidative damage and nephrotoxicity induced by prallethrin in rat and the protective effect of *Origanum majorana* essential oil. *Asian Pacific*

- Journal of Tropical Medicine. 2014;7(S1):S506–13.
34. Omrani H, Golmohamadi S, Pasdar Y, Jasemi K, Almasi A. Effect of selenium supplementation on lipid profile in hemodialysis patients. *Journal of Renal Injury Prevention*. 2016;5(4):179–82.
35. El-Shenawy SMA, Hassan NS. Comparative evaluation of the protective effect of selenium and garlic against liver and kidney damage induced by mercury chloride in the rats. *Pharmacological Reports*. 2008;60(2):199–208.
36. Musik I, Kielczykowska M, Donica H. The influence of selenium compounds of different structure on morphology, blood biochemistry and phagocytic capability of granulocytes in rats. *Roczniki Państwowego Zakładu Higieny*. 2013;64(2):117–22.
37. Hasanvand A, Abbaszadeh A, Darabi S, Nazari A, Gholami M, Kharazmkia A. Evaluation of selenium on kidney function following ischemic injury in rats; protective effects and antioxidant activity. *Journal of Renal Injury Prevention [Internet]*. 2017; 6(2) :93 – 8. Available from: [http:// dx.doi. org /10. 15171 /jrip.2017.18](http://dx.doi.org/10.15171/jrip.2017.18)
38. Krishnan V, Loganathan C, Thayumanavan P. Green synthesized selenium nanoparticles using *Spermatoce hispida* as carrier of s-allyl glutathione: to accomplish hepatoprotective and nephroprotective activity against acetaminophen toxicity. *Artificial Cells, Nanomedicine and Biotechnology [Internet]*. 2019;47(1):56–63. Available from: <https://doi.org/10.1080/21691401.2018.1543192>
39. Muhammad-Azam F, Nur-Fazila SH, Ain-Fatin R, Noordin MM, Yimer N. Histopathological changes of acetaminophen-induced liver injury and subsequent liver regeneration in BALB/C and ICR mice. *Veterinary World*. 2019;12(11):1682–8.
40. Canayakin D, Bayir Y, Kilic Baygutalp N, Sezen Karaoglan E, Atmaca HT, Kocak Ozgeris FB, et al. Paracetamol-induced nephrotoxicity and oxidative stress in rats: the protective role of *Nigella sativa*. *Pharmaceutical Biology*. 2016;54(10):2082–91.
41. Neamah NF, Al-jadaan SAN. Diol) on female rats in comparison with Dipyrone . 2019;(April).
42. Ansar S, Alshehri SM, Abudawood M, Hamed SS, Ahamad T. Antioxidant and hepatoprotective role of selenium against silver nanoparticles. *International Journal of Nanomedicine*. 2017;12:7789–97.
43. Data C. Association between Selenium Status and Chronic Kidney Disease in Middle-Aged and Older Chinese Based on. 2022;
44. Neamah NF, Al-Jadaan SAN, Al-Ali AM. Study of some of novel seleno-diazole derivative activities on hematological parameters, differentiate lymphocytes cells in addition to thyroid hormones levels in female rats (One of the series of studies on the impact of the new compound). *Systematic Reviews in Pharmacy*. 2020;11(11):975–80.
45. Hiragi S, Yamada H, Tsukamoto T, Yoshida K, Kondo N, Matsubara T, et al. Acetaminophen administration and the risk of acute kidney injury: A self-controlled case series study. *Clinical Epidemiology*. 2018;10:265–76.
46. Tsekhmistrenko SI, Bityutskyy VS, Tsekhmistrenko OS, Kharchishin VM, Tymoshok NO, Demchenko AA, et al. nanocompounds. 2021;11(3):199–204.

