

Nephroprotective effect of Dapsons against Gentamicin-Induced Acute Nephrotoxicity in Rats

Uday Abdul-Reda Hussein^{*1}, Naseer M. Mohammed², Haider F Al-Saedi¹ and Mukhallad A Ramadhan³

¹Department of Pharmacology and Toxicology, College of Pharmacy, University of Al-Ameed, Karbala, Iraq.

²Department of Pharmacy, Mazaya University College, Thi-Qar, Iraq.

³Department of Pathology, College of Medicine, University of Misan, Misan, Iraq.

Abstract

Nephrotoxicity is one of the major complications and clinical limitations of gentamicin. Dapsons is an antibiotic commonly used to treat leprosy and also used to treat acne vulgaris and dermatitis herpetiformis. This study aimed to evaluate the nephroprotective effect of dapsons against gentamicin-induced nephrotoxicity in rats.

Twenty-four healthy male rats, weighing between 250-300g, were equally divided into three groups, eight rats in each group: control group received normal saline (2mL/kg/day I.P.) for 10 days, gentamicin group received (100 mg/kg/day I.P.) for 10 days, and dapsons group received (5 mg/kg/day p.o) concomitantly with gentamicin (100 mg/kg/day I.P.) for 10 days. At the end of experiment, blood and kidney tissue samples were collected from all animals for biochemical and histopathological examination.

Dapsons exhibited nephroprotective effect manifested by a significant decrease in serum levels of blood urea nitrogen (BUN), creatinine and kidney injury molecules-1 (KIM-1) with a significant increase total protein serum level. Besides, it improved tissues oxidative and inflammatory biomarkers ("myeloperoxidase (MPO), reduced glutathione (GSH), malondialdehyde (MDA) tumor necrosis factor alpha (TNF- α), interleukin-1 beta (IL-1 β), and nuclear Factor kappa-B (NF- κ B)", which was demonstrated by improving histological changes when compared to the gentamicin group. In conclusion, dapsons has a nephroprotective effect by counteracting the renal deleterious effect of gentamicin.

Keywords: Nephrotoxicity, Gentamicin, Dapsons, Nephroprotective, Kidney.

التأثير الوقائي الكلوي للدابسون ضد السمية الكلوية الحادة المستحثة بالجنتاميسين في الجرذان عدي عبد الرضا حسين^{1*}، نصير مهدي محمد²، حيدر فالح الساعدي¹ و مخلد عبد الكريم رمضان³

¹ فرع الادوية والسموم، كلية الصيدلة، جامعة العميد، كربلاء، العراق.

² قسم الصيدلة، كلية مزايا الجامعة، ذي قار، العراق.

³ فرع الامراض، كلية الطب، جامعة ميسان، ميسان، العراق

الخلاصة

تعتبر السمية الكلوية احد المضاعفات الرئيسية والقيود السريية للجنتاميسين. الدابسون هو مضاد حيوي يستخدم بصورة شائعة لعلاج الجذام ويستخدم أيضاً لعلاج حب الشباب والتهاب الجلد الحلثي الشكل. تهدف هذه الدراسة إلى تقييم التأثير الوقائي للدابسون ضد السمية الكلوية التي يسببها الجنتاميسين في الجرذان.

تم تقسيم 24 جرذاً تتراوح اوزانها بين (250-300) غراماً الى ثلاث مجاميع متساوية، ثمانية في كل مجموعة: مجموعة السيطرة تم حقنها بالمحلول الملحي الطبيعي داخل الغشاء البريتوني (2 مل / كغم / يوم) لمدة 10 أيام، مجموعة الجنتاميسين تم حقنها بعقار الجنتاميسين داخل الغشاء البريتوني (100 مجم / كغم / يوم) لمدة 10 أيام، مجموعة الدابسون تم تجربتها فموياً بعقار الدابسون (5 مجم / كغم / يوم) بالتزامن مع حقنها بعقار الجنتاميسين داخل الغشاء البريتوني (100 مجم / كغم / يوم) لمدة 10 أيام. في نهاية التجربة تم جمع عينات الدم والكلية من جميع الحيوانات للفحص البيوكيميائي والنسجي.

أظهر الدابسون تأثيراً وقائياً للكلية يتجلى في انخفاض معنوي في مستويات نيتروجين اليوريا في الدم والكرياتينين و جزيء إصابة الكلى (KIM-1) كما أدى الى زيادة معنوية في مستوى البروتين الكلى. إلى جانب ذلك، فقد أدى الى تحسين المؤشرات الحيوية المؤكدة والالتهابية للأنسجة، و تم إثبات ذلك من خلال تحسين التغيرات النسيجية عند مقارنتها بمجموعة الجنتاميسين. ويمكن الاستنتاج بان للدابسون تأثير وقائي للكلية من خلال منع التأثير الكلوي الضار للجنتاميسين.

الكلمات المفتاحية: التسمم الكلوي، جنتاميسين، دابسون، حماية الكلية، الكلى.

Introduction

Nephrotoxicity is one of the major complications of medications resulting in acute or chronic deterioration in the renal function, which may be relatively related to the drug concentration and duration of therapy⁽¹⁾. One of these medications is gentamicin (GNT) which is a bactericidal aminoglycoside antibiotic that is

effectively used in the treatment of severe infections caused by Gram-negative bacteria. Nevertheless, the frequent clinical use of GNT may be limited due to its detrimental effect on the kidney and subsequent susceptibility to induce nephrotoxicity⁽²⁾. Gentamicin nephrotoxicity is triggered due to its accumulation in the proximal convoluted tubules

*Corresponding author E-mail: ud.rikaby@alameed.edu.iq

Received: 16/12 /2022

Accepted: 16/3 /2023

leading to oxidative stress and generation of reactive oxygen species (ROS), causing lipid peroxidation, DNA damage, protein denaturation, cell injury, inflammation, tubular cell apoptosis and necrosis, and ultimately renal failure⁽³⁾. Notably, several studies showed that compounds with anti-inflammatory and/ or antioxidant activities are able to prevent or at least attenuate drug-induced nephrotoxicity^(2,4).

Dapsone (DPS) is a sulfonamide antibiotic that inhibits the synthesis of bacterial dihydrofolic acid. Because of its anti-inflammatory effects, DPS is widely used to treat several skin diseases, such as leprosy, acne vulgaris and dermatitis herpetiformis^(5,6). Moreover, DPS is utilized for treating *Pneumocystis carinii* pneumonia, malaria, and cerebral toxoplasmosis. Besides the anti-inflammatory effect, DPS has antioxidant, antiapoptotic, neuroprotective, cytoprotective, cardioprotective, and anticonvulsive effects^(7,8). The objective of the current study is to evaluate the possible nephroprotective effect of DPS against GNT-induced nephrotoxicity in rats.

Materials and Methods

Drugs, kits and chemicals

Gentamicin (80mg/2ml) ampoule and dapsone (50 mg) Tablets were obtained from A.Menarini (Italy) and Domina Pharmaceuticals (Syria) companies respectively. ELISA kits (MB - assay-kit; MyBioSource, Inc., San Diego, CA, USA) were used for the estimation of "kidney injury molecules-1, tumor necrosis factor alpha, interleukin-1 beta, and nuclear Factor kappa-B activities". All the reagents used were of analytical grade.

Experimental animal and study design

Twenty-four healthy domestic male rats weighing (250-300) g and aged (5-6) months were housed and acclimatized in cages under good conditions with free access to food and water. "The study has been approved by the Institutional Animal Ethical Committee in the Pharmacy Department, College of Mazaya University". After acclimatization, rats were randomly separated into three groups (n=8) as follows:

Group 1 (Control group): received (2mL/kg /day I.P.) of normal saline for 10 days.

Group 2 (Gentamicin group): received (100 mg/kg/day I.P.) of gentamicin for 10 days.

Group 3 (Dapsone group): received (5 mg/kg/day p.o) of dapsone concomitantly with gentamicin (100 mg/kg/day I.P.) for 10 days⁽⁹⁾.

Serum and renal tissues biochemical measurements

At the end of 10 days, blood samples were taken out from the rat heart and centrifuged for fifteen minutes at 3000 rpm, and the supernatant was used for estimating the biomarkers of renal

function including "blood urea nitrogen (BUN), creatinine, and total protein were measured by spectrophotometer using auto-analyzer instrument at wavelengths of 580 nm, 500 nm, and 280 nm respectively, while kidney injury molecules-1 (KIM-1) were measured using ELISA kits" according to the manufacturer's instructions⁽¹⁰⁾.

Later, the kidneys were excised from all rats after they were sacrificed. Right kidney was weighed, homogenized and centrifuged to obtain supernatants for measuring inflammatory markers "tumor necrosis factor alpha (TNF- α), interleukin-1 beta (IL-1 β), and nuclear Factor kappa-B (NF- κ B)" using ELISA kits according to the manufacturer's instructions⁽⁴⁾, as well as for measuring oxidative stress markers "myeloperoxidase (MPO), reduced glutathione (GSH) and malondialdehyde (MDA)" according to Barone, Ellman's and Ohkawa methods respectively^(11,12,13).

Histological examination

The left kidney of each rat was fixed in 10% formalin then embedded in paraffin and cut into 5 μ m sections then stained with hematoxylin and eosin for histological examination⁽¹⁴⁾.

Statistical analysis

Data were expressed as mean \pm S.E.M. using Statistical Package for Social Sciences (SPSS, version 20) and analyzed by one-way analysis of variance (ANOVA) and Tukey's test. Differences between groups were considered significant at $P \leq 0.05$.

Results

Effects of dapsone on serum and renal tissues biomarkers

The results of this study showed that the GNT-treated group produced nephrotoxicity manifested by a significant increase ($P = 0.02$) in serum levels of BUN, creatinine and KIM-1, with a significant increase ($P \leq 0.05$) in tissue levels of MPO, MDA, TNF- α , IL-1 β , and NF- κ B, accompanied by a significant decrease ($P \leq 0.05$) in the levels of total protein and GSH when compared to that of control group (Table 1 & 2).

Dapsone-treated group significantly ameliorated the nephrotoxicity induced by GNT as indicated by improving of renal dysfunction through reduction serum levels of BUN, creatinine and KIM-1, with a significant increase ($P \leq 0.05$) total protein serum level. It also improved the tissue oxidative (MPO, MDA, GSH) and inflammatory (TNF- α , IL-1 β , NF- κ B) markers when compared to GNT group. In addition, it produced a non-significant difference in most biomarkers (BUN, creatinine, total protein, MPO, MDA, GSH, and NF- κ B) except a significant increase ($P \leq 0.05$) in KIM-1, TNF- α and IL-1 β levels when compared to the control group (Table 1 & 2).

Effects of dapsone on renal histopathology

Histopathological study revealed that the control group had normal renal glomeruli and tubules (Figure 1A). Whereas, the GNT group exhibited severe renal damage ,interstitial hemorrhage, congestion , inflammation, tubular sloughing ,vacuolation and necrosis, along with

hyaline deposition in the tubular lumen (Figure 1B&C). While the DPS-treated group showed significant reduction in the corresponding renal pathological lesions with improvement in renal function to an extent almost identical to that of the control group. (Figure 1D).

Table 1. Effect of dapsone on renal function biomarkers.

Groups (n=8)	Serum			
	BUN (mg/dl)	Creatinine (mg/dl)	KIM-1 (g/dl)	Total protein (mg/dl)
Control group	25.01±1.2	0.65±0.2	35.05±2.5	8±0.256
GNT group	65.1±0.95 c *	2.1±0.25 c *	120.1±0.5 c *	4±0.12 c *
DPS + GNT group	30±0.735 g *	0.7±0.031 g *	56.2±0.4 c *, g *	7.6±0.15 g *

Data are expressed as mean ± S.E.M, n = no. of animals, GNT= gentamicin, DPS= dapsone c *, g * Significantly different (P≤0.05) from the control, and gentamicin groups respectively

Table 2. Effect of dapsone on renal oxidative stress and inflammatory markers.

Groups (n=8)	Tissue					
	MPO (U/g)	MDA (nmol/g)	GSH (nmol/g)	TNF-α (pg/g)	IL-1β (pg/g)	NF-κB (ng/g)
Control group	7±0.2	40±0.32	1.5±1.5	50±0.55	25±0.18	3.5±0.66
GNT group	20±1.05 c *	72±0.41 c *	0.75±0.33 c *	135±0.52 c *	80±1.03 c *	7±0.44 c *
DPS + GNT group	10±0.62 g *	45±0.71 g *	1.2±0.34 g *	70±0.88 c *, g *	40±0.92 c *, g *	4±0.78 g *

Data are expressed as mean ± S.E.M, n =no. of animals, GNT= gentamicin, DPS= dapsone c *, g * Significantly different (P≤0.05) from the control, and gentamicin groups respectively

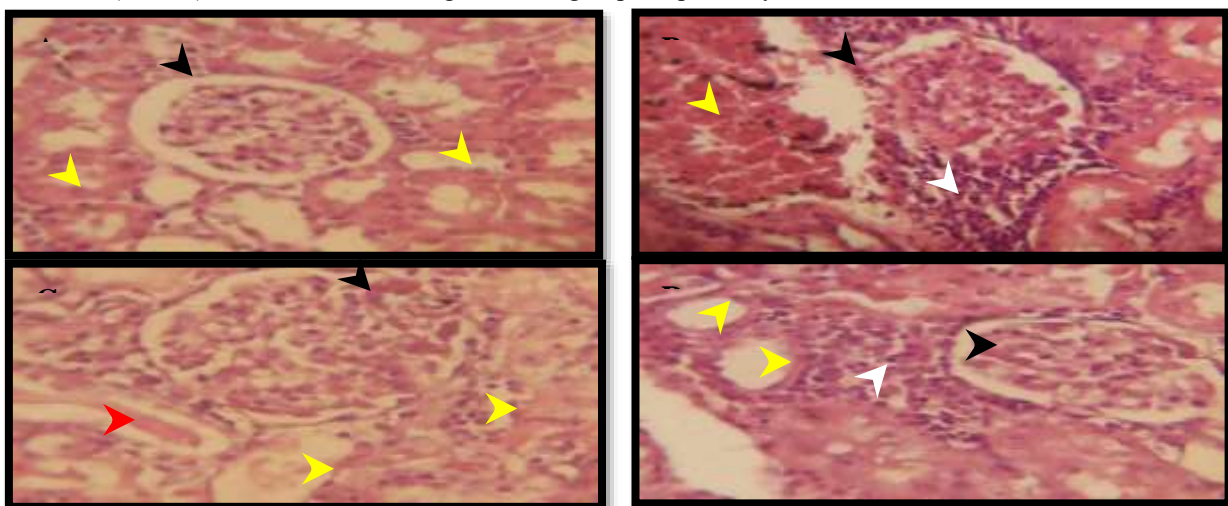


Figure 1. Photomicrographs of rats kidney sections (H&E 40X). (A) Control group: Black arrowhead shows the normal glomerulus, Yellow arrowhead shows the normal renal tubular lumen, (B) Gentamicin group: Black arrowhead shows damage of Bowman's capsule, Yellow arrowhead shows interstitial hemorrhage, White arrowhead shows sever inflammation, (C) Gentamicin group: Black arrowhead shows glomerular congestion, Yellow arrowhead shows tubular damage and sloughing, Red arrowhead shows hyaline deposition in tubular lumen., (D) Dapsone group: Black arrowhead shows the normal glomerulus, Yellow arrowhead shows the normal renal tubular lumen, White arrowhead shows mild periglomerular inflammation.

Discussion

Nephrotoxicity is one of the major complications of GNT which may end in acute renal failure as demonstrated in this study by producing a significant increase in serum levels of BUN, creatinine and KIM-1. The GNT –nephrotoxicity may be mediated by free radicals production and oxidative stress induction⁽²⁾. These lead to lipids peroxidation and direct damages to some macromolecules and bringing cellular injury. Besides, they causes an increase in monocyte/macrophages infiltration followed by apoptosis and necrosis^(3,4). This can be evidenced in the current study by producing a severe kidney damage and a significant elevation in renal tissue levels of oxidative stress and inflammatory markers associated with decreased levels of total protein and GSH. These results are consistent with those reported in previous studies which indicated that GNT causes renal dysfunction and damage through several mechanisms, mainly oxidative stress and inflammation^(2,15).

In the current study, DPS significantly ameliorated the nephrotoxic effect of GNT, as indicated by the significant decrease in nephrotoxic biomarkers and maintenance of kidney pattern, which could be credited to its anti-inflammatory and anti-apoptotic effects through suppressing neutrophils infiltration and recruitment, as well as reducing the release of pro-inflammatory cytokines and prostaglandins^(9,16), this has been proven in our study by improvement of renal damage and dysfunction along with reducing TNF- α , IL-1 β , and NF- κ B. These findings are consistent with previous studies showing that the anti-inflammatory and anti-apoptotic effects of DPS could be helpful in the management of inflammatory diseases of the lung, gastrointestinal tract, skin, and nervous system by modulating inflammatory and apoptotic cascades via reducing pro-inflammatory, Caspase-3, and other pro-apoptotic factors^(17,18).

DPS exhibited nephroprotective effect, and subsequently improved renal function due to inhibition of MPO and oxidative stress as seen in present study by reducing the MPO and MDA levels when compared to GNT group. This is consistent with a previous studies that considered MPO and its related oxidation products to be serious causative factors in the development of several renal diseases and damages^(19, 20, 21).

On the other hand, DPS improved the renal functional and histological alterations with alleviating GNT-induced necrosis. These effects could be due to inhibition of calcium influx, thereby decreasing its accumulation in tubular cells which induced by GNT^(22,23). This can be confirmed by using calcium channel blockers in treatment of GNT-nephrotoxicity⁽²⁴⁾.

This study showed that DPS effectively attenuates GNT- nephrotoxicity and consequently renal damage, which may be attributed to its antioxidant activity as presented by reducing MDA and raising GSH levels which plays a crucial role in renal protection through the suppression of oxidative stress and scavenging free radicals⁽⁸⁾. This is compatible with other studies demonstrated that oxidative damage to be the main cause of aminoglycosides nephrotoxic effects^(4, 25).

Conclusion

This study found that dapsone has a nephroprotective effect through counteracting the renal deleterious effect of gentamicin by suppressing oxidative stress and inflammation.

Conflicts of Interest

The authors have no conflict of interest.

Funding

The paper was not funded.

Ethics Statements

This study was approved by the scientific and ethical committees of University of Al-Ameed.

Author Contribution

The authors confirm contribution to the paper as follows: study conception and design: Uday Abdul-Reda Hussein, Naseer M. Mohammed; data collection: Uday Abdul-Reda Hussein, Naseer M. Mohammed; analysis and interpretation of results: Haider F Al-Saedi, Mukhallad A Ramadhan. Author; draft manuscript preparation: Uday Abdul-Reda Hussein, Naseer M. Mohammed, Haider F Al-Saedi, Mukhallad A Ramadhan. All authors reviewed the results and approved the final version of the manuscript.

References

1. Abd MR, Hassan AF. The Ameliorative Effect of Fimasartan against Methotrexate-Induced Nephrotoxicity in Rats. *Iraqi J Pharm Sci.* 2022;31(1):87-94.
2. Al Shawoush AM, Mohamed AS, Soliman AMA, Fahmy SR. Protective effect of *Anodonta cygnea* hemolymph against acute kidney injury induced by gentamicin in rats. *GSC Biological and Pharmaceutical Sciences.* 2022;19(1): 326-334.
3. Randjelović P, Veljković S, Stojiljković N, Sokolović D, Ilić I. Gentamicin nephrotoxicity in animals: Current knowledge and future perspectives. *EXCLI Journal.* 2017;16:388-399.
4. Mishra P, Mandlik D, Arulmozhi S, Mahadik K. Nephroprotective role of diosgenin in gentamicin-induced renal toxicity: biochemical, antioxidant, immunological and histopathological approach. *Futur J Pharm Sci.* 2021 ;7:169.
5. Ghaoui N, Hanna E, Abbas O, Kibbi AG, Kurban M. Update on the use of dapsone in

- dermatology. *Int. J. Dermatol.* 2020; 59(7) : 7787–7795.
6. Wu Z, Wang C, Wang Z, Shi Y, Jiang H, Wang H. Risk factors for dapsone resistance in leprosy patients: a systematic meta-analysis. *J Glob Antimicrob Resist.* 2022;30:459-467.
 7. Zhan R, Zhao M, Zhou T, Chen Y, Yu W, Zhao L, Zhang T, Wang H, Yang H, Jin Y, He Q, Yang X, Guo X, Willard B, Pan B, Huang Y, Chen Y, Chui D, Zheng L. Dapsone protects brain microvascular integrity from high-fat diet induced LDL oxidation. *Cell Death Dis.* 2018;9(6):683.
 8. Diaz-Ruiz A, Nader-Kawachi J, Calderón-Estrella F, Mata-Bermudez A, Alvarez-Mejia L, Ríos C. Dapsone, More than an Effective Neuro and Cytoprotective Drug. *Curr Neuropharmacol.* 2022;20(1):194-210.
 9. Khalilzadeh M, Shayan M, Jourian S, Rahimi M, Sheibani M, Dehpour AR. A comprehensive insight into the anti-inflammatory properties of dapsone. *Naunyn Schmiedebergs Arch Pharmacol.* 2022;395(12):1509-1523.
 10. Alkuraishy HM, Al-Gareeb AI, Rasheed HA.. Nephroprotective effect of Curcumin (Curcuma Longa) in acute nephrotoxicity in Sprague-Dawley rats. *Journal of Contemporary Medical Sciences.* 2019; 5(2): 122–124.
 11. Barone FC, Hillegass LM, Price WJ, White RF, Lee EV, Feuerstein GZ, Sarau HM, Clark RK, Griswold DE. Polymorphonuclear leukocyte infiltration into cerebral focal ischemic tissue: myeloperoxidase activity assay and histologic verification. *J Neurosci Res.*1991; 29(3):336–345.
 12. Ellman GL. Tissue sulfhydryl groups. *Arch Biochem Biophys.*1959; 82(1):70-77.
 13. Ohkawa H, Ohishi N, Yagi K. Assay for lipid peroxides in animal tissues by the thiobarbituric acid reaction. *Anal Biochem.* 1979; 95(2):351–358.
 14. Hussein UA. Role of Eruca sativa in prevention of induced nephrocalcinosis in rabbits. *Kerbala Journal of Pharmaceutical Sciences* 2018.; 14: 65-73.
 15. Abdelrahman R. Protective effect of apocynin against gentamicin-induced nephrotoxicity in rats. *Human & experimental toxicology* .2018;37(1): 27-37.
 16. Abdelzaher WY, Ahmed SM, Welson NN, Alsharif KF, Batiha GE, Labib DAA. Dapsone Ameliorates Isoproterenol-Induced Myocardial Infarction via Nrf2/ HO-1; TLR4/ TNF- α Signaling Pathways and the Suppression of Oxidative Stress, Inflammation, and Apoptosis in Rats. *Front Pharmacol.* 2021;12:1-12.
 17. Jafari RM, Shayesteh S, Ala M, Yousefi-Manesh H, Rashidian A, Hashemian SM, Sorouri M, Dehpour AR. Dapsone Ameliorates Colitis through TLR4/NF-kB Pathway in TNBS Induced Colitis Model in Rat. *Archives of Medical Research.*2021;52(6): 595-602.
 18. Mahale A, Kumar R, Sarode LP, Gakare S, Prakash A, Ugale RR. Dapsone prolong delayed excitotoxic neuronal cell death by interacting with proapoptotic/survival signaling proteins. *J Stroke Cerebrovasc Dis.* 2020;29(8):104848.
 19. Bozeman PM, Learn DB, Thomas EL. Inhibition of the human leukocyte enzymes myeloperoxidase and eosinophil peroxidase by dapsone. *Biochem Pharmacol.* 1992;44:553–563.
 20. Ndrepepa G. Myeloperoxidase—A bridge linking inflammation and oxidative stress with cardiovascular disease. *Clin Chim Acta.* 2019; 493:36–51.
 21. Ramadhan MA, Al-Saedi HF, Ismaeel GL, Hussein UA. The Possible Nephroprotective Effect of Roflumilast Ameliorating Glycerol-Induced Myoglobinuric Acute Renal Injury in Rabbits Model. *Indian Journal of Forensic Medicine & Toxicology* .2020;14(4): 3327-3332.
 22. Ríos C, Orozco-Suarez S, Salgado-Ceballos H, Mendez-Armenta M, Nava-Ruiz C, Santander I, Barón-Flores V, Caram-Salas N, Diaz-Ruiz A. Anti-Apoptotic Effects of Dapsone After Spinal Cord Injury in Rats. *Neurochem Res.* 2015;40(6):1243-51.
 23. Shayesteh S, Khalilzadeh M, Takzaree N, Dehpour AR. Dapsone improves the vincristine-induced neuropathic nociception by modulating neuroinflammation and oxidative stress. *DARU J Pharm Sci.*2022; 30(2), 303–310.
 24. Gandhi KC , Shahani SR, Dhar R, Gawali SS. Comparative study of Verapamil, Diltiazem, and Amlodipineon on Gentamicin induced nephrotoxicity in rats. *Asian J of Pharmacy and Pharmacology.*2020;6(3):210-216.
 25. Ali ARA , Ismail SH. The Protective Effect of Honey Against Amikacin-induced Nephrotoxicity in Rats. *raqi J Pharm Sci.*,2012;21(2):85-93.

