

## Serological Survey of Newcastle Disease in Layer Chickens in Diyala Governorate

Ammar Talib Nasser<sup>1</sup>, Akram Ahmed Hassan Al-Khalidi<sup>2</sup>, Marah Salim Hameed<sup>3</sup>

<sup>1</sup> Department of Microbiology, College of Veterinary Medicine, University of Diyala, Iraq

<sup>2</sup> Department of Pathology and Poultry Disease, College of Veterinary Medicine, University of Diyala, Iraq

<sup>3</sup> Department of Physiology, College of Veterinary Medicine, University of Diyala, Iraq

### ARTICLE INFO.

Article history:

-Received:

-Accepted:

-Available online:

Keywords:

Newcastle disease, Antibody titer, Layers, ELISA, Diyala Governorate.

Corresponding Author:

Name:

Ammar Talib Nasser

E-mail:

Tel:

### ABSTRACT

**Background :** One of the most deadly diseases affecting chickens is Newcastle disease. Both the poultry industry and household village hens suffer severe losses of Diseases. Due to the free-ranging nature of domestic chickens in villages, there is a significant likelihood that they may come into touch with wild birds, which may serve as a reservoir for numerous viral infections .

**Aims:** The current study was conducted to clarify the real evidence that the Layer chickens play important role in the epidemiology source of NDV.

**Methods :** Group of Layer chickens were used at 50 and 150 day old for identification of the NDV. Antibody Rapid Test Kit (BIO-TEK Instruments Inc., USA) used to identify the positive cases, all positive cases by this kit were tested by Enzyme- Linked Immunosorbent Assay (ELISA) to determine the antibody titers against NDV in all study groups.

**Results :** Current study revealed that antibodies against NDV were detected with the mean titer of  $11286.42 \pm$  and  $2232.391$  to each age groups respectively. In 90 serum samples taken from hens without a history of Vaccination from five districts in the Diyala province between September and October 2023, the ELISA test was performed to look for antibodies against the Newcastle disease virus.

Post-mortem lesions in the nervous, digestive, and reproductive systems have been documented. The severe alterations has appeared in the female reproductive system, such as hemorrhagic stigmata on the ovarian follicles. Proventricular mucosal bleeding and necrotic hemorrhage areas on the mucosal surface of the gut, particularly the cecal tonsils, were found in the digestive system. Proventriculus liver, cecal tonsils, spleen, kidney, brain, and heart all underwent histopathological alterations. The ELISA test result during the study period showed high levels during and after 7 days after infection NDV. By ELISA 97% of sera were found to be positive

### Conclusions

Infectious Newcastle Disease virus infection was endemic in layer chickens of Diyala Governorate regardless of the control program using commercial vaccines. It seems the maternal antibodies and

vaccination did not protect chickens against NDV infection, which might indicate the virus circulation in industrial farms in the study area. Therefore, it is recommended to conduct more Serological studies for local detection of the viruses and the preparation of NDV vaccine from local isolates.

## Introduction

Newcastle disease (ND) is a serious viral illness that affects poultry and is very costly. It affects numerous avian species and is widespread throughout the planet. A notable range in morbidity and Mortality is a feature of the illness [1]. In 1926, Newcastle-upon-Tyne, England, and Java, Indonesia, both experienced the first known ND outbreaks [2]. Avian paramyxovirus serotype-1 (APMV-1), a virus belonging to the family Paramyxoviridae and the genus Avulavirus, is the cause of Newcastle disease [3]. A single-stranded, non-segmented, enveloped RNA virus with negative sense is known as an avian paramyxovirus [4]. There is a fecal-oral route of transmission, with the respiratory route contributing where there are close bird-to-bird relationships contact [5]. Newcastle disease virus (NDV) infects chickens, guinea fowls, turkeys, and a there are 250 species of domestic and wild birds, The severity of the sickness that the various APMV-1 strains produce in birds and its clinical symptoms vary greatly [7]. Lentogenic, mesogenic, and velogenic strains are differentiated based on their pathogenicity in chickens. While mesogenic strains primarily produce acute respiratory symptoms, lentogenic strains can also cause moderate respiratory or gastrointestinal illnesses [8]. As vaccines, lentogenic and mesogenic strains are used [9]. The cause of severe illness and high mortality in poultry is velogenic strains. These velogenic viruses are further separated into viscerotropic and neurotropic strains based on the primary clinical symptoms [10]. With the fewest eggs produced 2 to 3 weeks after infection, layers infected with NDV may only show a drop in egg production during the first week after infection. Thereafter, the number of eggs produced will start to increase. The mutant strains of NDV known as pigeon paramyxovirus type 1 (PPMV-1) viruses, which are linked to illnesses in pigeons, have a global distribution [11]. whilst others have widened their host range and can even infect geese [12]. Ducks were also the source of NDV strains that were pathogenic for chickens [13]. It was discovered that quails were susceptible to ND virus infection of the velogenic pathotype [14]. Human welfare is

significantly impacted by poultry diseases, particularly in rural regions where village or backyard chickens are a major source of income and food [15]. A lot of money is also spent by nations with industrialized poultry production to stop ND, stop ND-related losses, keep ND-free statuses, or eradicate ND following an outbreak [16]. Newcastle disease virus, also known as avian paramyxovirus-1, is a member of the genus Avulavirus. This genus was categorized under the paramyxovirus subfamily. This subfamily and the subfamily of pneumovirinae were assigned to the order Mononegavirales' paramyxoviridae family [17]. This serotype was determined using hemagglutination inhibition (HI) and neuraminidase inhibition (NI) assays [18]. Following aerosol infection and digestive tracts, NDV begins to replicate in the mucosa of the superior respiratory system. The virus moved from cell to cell, and the ciliary movement of the host assisted the infection [19]. The viraemia transports the virus to the parenchymal organs the spleen, liver, lungs, kidney, and bone marrow shortly after infection and amplification. Within 22 to 44 hours of infection, the virus can be identified in nearly all bodily tissues. Birds start to die when the virus enters the brain after no longer replicating in non-nervous tissues [20, 21]. Generally, the sickness is more severe in younger chickens. with a dangerous virus on the move. Young chicks may die suddenly and without any clinical symptoms. Natural entry points for infection include the Nostril and mouth cavity, and eyes. For the quick serological detection of NDV antibodies in serum samples, there is the ELISA test. The purpose of the test is to determine how well NDV antibody binds antigen coated plates. For the detection of antibodies to NDV, numerous ELISA tests have been created, and various commercial ELISA kits are readily available. principal benefit of ELISA above other traditional tests [22]. Numerous serological tests, such as single radial immunodiffusion, single radial hemolysis, agar gal immune diffusion, virus neutralization in chick embryos plaques, hemagglutination inhibition (HI), and enzyme linked immune sorbent assays (ELISA), have been used to detect NDV antibodies [23]. The obtained NDV

ELISA titre values show a comparison between the NDV antibody level in each field chicken serum tested and the NDV ELISA kit positive.

## Materials and Methods

### Study Design and Sample Collection

#### Methods: Study Area:

Serological detection of this experiment was carried out in the Virology Laboratory, College of Veterinary Medicine, Diyala University, Diyala, Iraq, while the practical experiment was carried out in Canaan, Baladruz, Shahrban, Buhris, Diyala Governorate.

#### Experimental Birds

A total number of 90 layer chickens at 50 and 150 days-old were distributed into two groups of 22 birds for each group. The 90 from each group were used for the serological identification. All the birds were housed in cages supplied with water and feed offered *ad Libitum*. The diet based on corn and soybean meal and formulated as balanced ration according to [24]. Also gathered were tissue samples from birds that had clinical signs appeared of NDV. Spleen, liver, lung, and trachea samples were obtained during the immediate post-mortem examination. These samples were placed in labeled flasks and kept at a temperature of 70°C.

#### ELISA Test:

The NDV ELISA kit was used to monitor NDV antibody levels in affected flocks. ELISA - Synbiotics Corporation, United States, used the Windows computer application Profile 2.0 to carry out the ELISA monitoring tests. Using (BIO-TEK, Newcastle disease virus antibody test kit) the ELISA kits were applied in accordance with the manufacturer's instructions. Using the manufacturer-provided software, the antibody titer in each sample was determined. The same program was also used to determine the geometric mean titer for each group of serum samples. The processing of serum samples for the ELISA test was carried out in accordance with the manufacturer of the aforementioned ELISA kit's instruction manual.

#### Collection Of Specimens: Blood Sampling

From each group, 3-5 ml blood samples were collected from 90 birds from the wing by vein puncture by using disposable syringe (Terumo, Japan). The blood was collected from the two groups of layer chickens at different age into sterile tubes without anticoagulants. The blood was allowed to clot at room temperature for 45 minutes then centrifugation at 3000rpm for 5 minutes (Hettich Centrifuge, Germany), after that the serum was transferred into new tubes,

and stored frozen in plastic vials at -20°C until use.

#### Monitoring Antibodies Titer By ELISA

Collected of blood samples from laying hens are taken from wing vein, collected by ependroff tube and left for a period at room temperature after then the blood was deposited and the serum separated from blood, was stored in a (-20) degree and send to laboratory for ELISA tests. A commercial ELISA kit (BIO-TEK, Newcastle disease virus antibody test kit) was performed according to manufactures direction to determine Ab levels against ND vaccine.

#### Statistical analysis

Statistical analysis program SPSS was used to analysis the data, by using chi-square test and frequency. P value at the 95% confidence level was computed for significant result.

#### Results and discussion

##### Monitoring antibodies titer by ELISA:

The results of antibody titers to NDV measured by Elisa test at 50 and 150 days old are shown in table, 1 and 2. The measurement of antibodies against NDV that collected from 90 layer chicken (as indicated by ELISA test) at 50 days old for the group 2, showed a marked elevation 11286.42 with 2232.391 for Mean respectively, for the first collected serum when it was compared to the findings in the first group of the same age .125 with 130 for St. Deviation and Std. Error respectively (Tables, 1). On the other hand, the measurement of antibodies titers against NDV on day 150 showed also non-significant elevation in the mean antibody titer of layer chickens With fewer than three groups, linearity measures for Age /days \* result cannot be computed.

**Table 1: Means of antibody titer against NDV on layer chickens as measured by ELISA test.**

NDV INFECTION	N	NDV titer	
		Mean	Std. Deviation
Negative	23%	2232.391	3673.39
Positive	67%	11286.42	4645.602
Total	90	8972.611	5925.427

**Table 2: Means of antibody titer against NDV on 50 and 150 days layer chickens as measured by ELISA test**

Age /days	NDV antibody titer		Total
	Positive	Negative	
(50-59) days	6%	29%	35%
(60-69) days	2%	10%	12%
(70-79)days	6%	9%	15%
(80-89) days	0%	6%	6%
(90-99) days	2%	2%	4%
(100-150) days	7%	11%	18%
Total	23	67	90



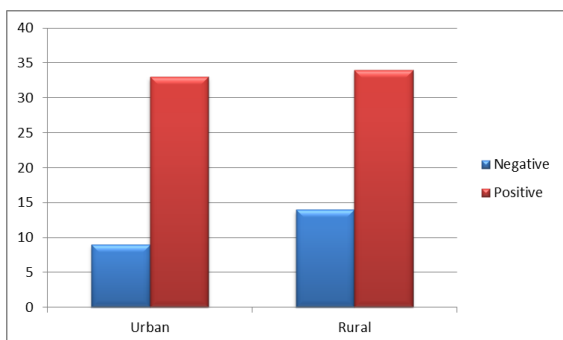
Figure 1: Effect of age in distribution of antibody titer against NDV infection.

**Monitoring antibodies titer are Region Urban and Rural by ELISA**

On the other hand, the measurement of antibodies titers against NDV showed also non-significant elevation in the mean antibody titer Region Urban and Rural showed a marked (Tables.3 ).

**Table 3: Means of antibody titer against NDV layer chickens as measured by ELISA test.**

NDV INFECTION	Region		Total
	Urban	Rural	
Negative	9%	14%	23%
Positive	33%	34%	67%
Total	42	48	90



**Figure 1: Effect of Region Urban and Rural in distribution of antibody titer against NDV infection.**

**Post mortem**

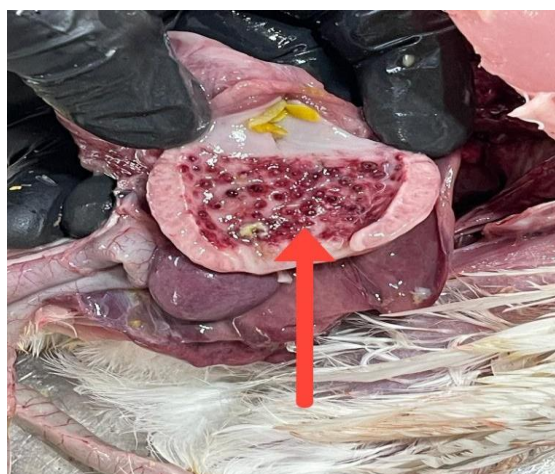
Some chickens that were displaying clinical symptoms were put to death. nerves signs of torticollis (Figure 2). Destructions appear after infection DNV in chickens. (figure3) Proventricular mucosal bleeding was observed in the digestive system (figure 4), as well as necrotic hemorrhage areas on the mucosal surface of the colon, particularly the cecal tonsils (figure5).



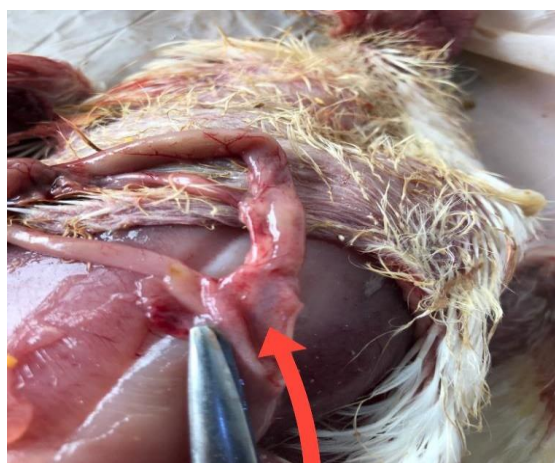
**Figure 2 nerves signs of torticollis.**



**Figure 3 Destructions appear after infection NDV in chickens.**



**Figure 4: Experimental infection of chickens showed petechiae and small ecchymoses on the tips of proventricular glands.**



**Figure 5: Peyer patches cecal Postmortem lesions**

**Discussion**

These findings are crucial for comparing the many NDV strains responsible for outbreaks in commercial poultry from various nations and assessing their pathogenicity to various avian species. For the planning of control strategies and understanding of NDV epidemiology, the

finding that NDV was excreted for up to 20 days (24 dpi) without any clinical indications of the disease is particularly significant [25]. These findings highlight the value of researching viral-host interactions while concentrating on each distinct virus strain.

Clinical manifestations of NDV included nervous system tremors, paralyzed limbs, and digestive symptoms of greenish-dark diarrhea. Reproductive systems were also affected, with dramatic drops in egg production and eggs that were deformed and bleached two weeks after infection. Returning gradually, the quality of the egg and shell gradually improved, confirming the NDV infection [26, 27] These results are noted by other publications. Post-mortem examination revealed a variety of lesions in severely afflicted layer hens, including

hemorrhagic lungs, a trachea with congestion, pin-point hemorrhages at the tips of proventriculus glands, hemorrhagic ulcers in the intestinal wall and cecal tonsils, necrosis, and focal ulceration of intestinal lymphoid aggregates [28]. These findings are in line with.

### Conclusions

Infectious Newcastle Disease virus infection was endemic inlayer chickens of Diyala Governorate regardless of the control program using commercial vaccines. It seems the maternal antibodies and vaccination did not protect chickens against NDV infection, which might indicate the virus circulation in industrial farms in the study area. Therefore, it is recommended to conduct more Serological studies for local detection of the viruses and the preparation of NDV vaccine from local isolates.

### References

- [1] Ahmed AI and Odisho ShM (2018). Isolation identification and pathotyping of Newcastle disease viruses from naturally infected chickens in Iraqi Kurdistan region. *The Iraqi Journal of Agricultural Sciences*, 49(1): 132-141.
- [2] Alazawy AK and Al Ajeeli KS (2020). Isolation and molecular identification of wild Newcastle disease virus isolated from broiler farms of Diyala Province, Iraq. *Veterinary World*, 13(1): 33-39.
- [3] Al-Shammari A.M. Hamad, M.A. AL-Mudhafar, M.A, Raad, K. and Ahmed, A. (2020). Clinical, molecular and cytopathological characterization of a Newcastle disease virus from an outbreak in Baghdad, Iraq. *Veterinary Medicine and Science*, 6: 477-484.
- [4] Ali A.A.H, Abdallah F.M, Farag GK, and Fatehi S (2022). An overview on virological pathogenesis, clinical manifestation, and molecular studies on newcastle disease virus. *European Journal of Molecular & Clinical Medicine*, 9(4): 2807-2824.
- [5] Aldous, E.W. and Alexander, D.J. (2001). Detection and differentiation of Newcastle disease virus (avian paramyxovirus type 1). *Avian pathology*, 30(2), 117-128.
- [6] Aldous, E. W., and Alexander, D. J. (2008). Newcastle disease in pheasants (*Phasianus colchicus*): a review. *The Veterinary Journal*, 175(2), 181-185.
- [7] Alexander, D.J. and Senne, D.A. (2008) Newcastle disease, other avian paramyxoviruses, and pneumovirus infections. In: Saif, Y.M., Fadly, A.M., Glisson, J.R., McDougald, L.R., Nolan, N.K. and Swayne, D.E., editors. *Diseases of Poultry*. 12th ed. Blackwell Publishing, Ames, IA. p75-115.
- [8] Alexander, D.J. (2003). Newcastle disease, other aviparamyxoviruses, and pneumovirus infections. In: (eds) *Diseases of poultry*, 11th edn. Ames, Iowa, pp 63–99.
- [9] Karamendin, K. and Kydyrmanov, A. (2021). Cormorants as a Potentially Important Reservoir and Carrier of Newcastle Disease Virus on the Asian Continent. *Front. Vet. Sci.* 8:648091. doi: 10.3389/fvets.2021.648091
- [10] Alexander, D. J. (1998). Newcastle disease and other avian Paramyxovirus. In: *A laboratory manual for the isolation and identification of avian pathogens*, 4th ed. 10. University Press: Ames, USA, pp 452-470.
- [11] Bouzari, M. and P. Spradbrow. (2006). Early events following oral administration of Newcastle disease virus strain V4. *J Poult Sci.* 43:408–414.
- [12] Brown, C. C. King, D. J. and Seal, B. S. (1999). Comparison of pathology-based techniques for detection of viscerotropic velogenic Newcastle disease virus in chickens. *Journal of Comparative Pathology*, 120(4), 383-389.
- [13] Brown, C. King, D. J., and Seal, B. S. (1999). Pathogenesis of Newcastle disease in chickens experimentally infected with viruses of different virulence. *Veterinary Pathology*, 36(2), 125-132.
- [14] Cattoli, G. Susta, L. Terregino, C., and Brown, C. (2011). Newcastle disease: a review of field recognition and current methods of

laboratory detection. *Journal of veterinary diagnostic investigation*, 23(4), 637-656. .

[15] Chen X, Jia Y, Wei N, Ye C, Hao H, Xiao S, Wang X, Liu H, and Yang Z (2021). Identification of a new amino acid mutation in the HN protein of NDV involved in pathogenicity. *Veterinary Research*, 52: 147.

[16] Czeglédi, A. Ujvári, D. Somogyi, E. Wehmann, E. Werner, O. and Lomniczi, B. (2006). Third genome size category of avian paramyxovirus serotype 1 (Newcastle disease virus) and evolutionary implications. *Virus research*, 120(1-2), 36-48.

[17] Quinn, P.J. Markey, B.K. Carter, M.E, Donnelly WJ, Leonard FC (2002). *Veterinary Virology Methods Manual Academic Press*, London, 1996, pp. 25-46.

[18] Lamb, R. and Parks, G.D.( 2007). *Paramyxoviridae: The viruses and their replication*. In: *Fields Virology*, Vol. Philadelphia. 1449–1496.

[19] Li, S.Y., You, G.J., Du, L.J., Li, W.W., Liu, Y.Y., Du, J.T. and Huang, Y. (2019) Complete genome sequence of a class I Newcastle disease virus strain isolate from a breeding chicken flock in Sichuan, China. *Microbiol. Resour. Announc.*, 8(18): e00337-e00419..

[20] OIE. (2009). *Manual of diagnostic tests and vaccines for terrestrial animals: mammals, birds and bees*. Biological Standards Commission, Vol. 1, Part 2, Chapter 2.3.14. OIE, Paris. 576–589.

[21] van Boven, M., Bouma, A. Fabri, T. H. Katsma, E. Hartog, L. and Koch, G. (2008). Herd immunity to Newcastle disease virus in poultry by vaccination. *Avian pathology*, 37(1), 1-5.

[22] Pandarangga, P. McAllister, M.M. Peaston, A.E. Ngai, Y.T. Cahyono, M.I. and Hemmatzadeh, F. (2022). Performance

comparison of homologous and heterologous Newcastle disease virus in vaccines and antibody tests. *Research in Veterinary Science*, 149: 82-89. DOI:

<https://www.doi.org/10.1016/j.rvsc.2022.06.014>.

[23] Pfaffl, M. W. (2012). *Quantification strategies in real-time polymerase chain reaction. Quantitative real-time PCR. Applied Microbiology*, Caister Academic Press, Norfolk, United Kingdom, PP.53-62.

[24] Pantua, H. D. McGinnes, L. W. Peeples, M. E. and Morrison, T. G. (2006). Requirements for the assembly and release of Newcastle disease virus-like particles. *Journal of virology*, 80(22), 11062-11073.

[25] Hewson, K., Noormohammadi, A. H., Devlin, J. M., Mardani, K., and Ignjatovic, J. (2009). Rapid detection and non-subjective characterisation of infectious bronchitis virus isolates using high-resolution melt curve analysis and a mathematical model. *Archives of Virology*, 154(4), 649.

[26] Lima, F. S., Santin, E. Paulillo, A. C., Doretto Jr, L., De Moraes, V. R. M. and Schocken, R. P. (2004). Japanese quail (*Coturnix coturnix japonica*) as Newcastle disease virus carrier. *International Journal of Poultry Science*, 3(7), 483-484.

[27] Khan, T. A. Rue, C. A., Rehmani, S. F. Ahmed, A., Wasilenko, J. L., Miller, P. J. and Afonso, C. L. (2010). Phylogenetic and biological characterization of Newcastle disease virus isolates from Pakistan. *Journal of Clinical Microbiology*, 48(5), 1892-1894.

[28] Ullah, S. Ashfaque, M. Rahman, S. U., Akhtar, M., and Rehman, A. (2004). Newcastle disease virus in the intestinal contents of broilers and layers. *Pakistan Veterinary Journal*, 24(1), 28-30.



## المسح المصلي لمرض النيوكاسل في الدجاج البياض في محافظة ديالى

عمار طالب ناصر

فرع الأحياء المجهرية، كلية الطب البيطري، جامعة ديالى، العراق

أكرم أحمد حسن الخالدي

فرع الأمراض وأمراض الدواجن، كلية الطب البيطري، جامعة ديالى، العراق

مرح سالم حميد

فرع الفسلجة والكيمياء الحياتية والادوية، كلية الطب البيطري، جامعة ديالى، العراق

### خلاصة

من أخطر الأمراض التي تصيب الدجاج هو مرض نيوكاسل. وتتكبد صناعة الدواجن والدجاج القروي المنزلي خسائر فادحة نتيجة لذلك. نظرًا لطبيعة الدجاج المنزلي في القرى، هناك احتمال كبير أنها قد تتلامس مع الطيور البرية، والتي قد تكون بمثابة مستودع للعديد من الالتهابات الفيروسية.

الأهداف: تقييم دور الدجاج البياض في انتشار فيروس مرض النيوكاسل.

الطرق: تم فحص الدجاج البياض عند عمر خمسين إلى مائة وخمسين يوماً للكشف عن فيروس نيوكاسل. تم استخدام اختبار سريع للكشف عن الأجسام المضادة لفيروس NDV. تم تأكيد الحالات الإيجابية بواسطة ELISA لتحديد عيار الأجسام المضادة. وقد تم توثيق التغيرات بعد الوفاة في الجهاز العصبي والهضمي والإنجابي.

النتائج: تم الكشف عن الأجسام المضادة لفيروس NDV بمتوسط عيار  $(1.83118 \pm 2.6750)$  ملغم/ديسيليتر في 44 عينة مصلة مأخوذة من دجاج بدون تاريخ تحصين من خمس مناطق في محافظة ديالى.

التغيرات الشديدة في الجهاز التناسلي الأنثوي، وخاصة الندبات النزفية على بصيلات المبيض. نزيف الغشاء المخاطي البطني ونزيف اللوزتين الأعور. تم الإبلاغ عن التغيرات المرضية في الكبد Proventriculus واللوزتين الأعور والطحال والكلى والدماغ والقلب. تم تسجيل مستويات عالية من الأجسام المضادة لفيروس NDV أثناء وبعد 7 أيام من الإصابة. إجمالي 96% من الأمصال كانت إيجابية لفيروس نيوكاسل. ولوحظ وجود ارتباط جيد بين عيارات الاليزا وكان هناك فروق ذات دلالة إحصائية بين اختبار الاليزا عند مستوى ثقة 95% ( $P > 0.05$ ). 4% من دجاج القرية المنزلية لديه أجسام مضادة وقائية و96% من الدجاج عرضة للإصابة بفيروس نيوكاسل.

الاستنتاجات: تم توزيع عدوى فيروس نيوكاسل على نطاق واسع في الدجاج البياض في محافظة ديالى. ليس للأجسام المضادة للألم والتطعيم أي دور في الحماية من الإصابة بفيروس نيوكاسل، وهو ما يعكس انتشار الفيروس في المزارع الصناعية في محافظة ديالى.

الكلمات المفتاحية: مرض نيوكاسل، عيار الأجسام المضادة، الطبقات، الإليزا، ديالى