



ISSN:2073-1213  
Tikrit Journal  
for  
Dental Sciences  
<https://tjds.tu.edu.iq>



## Immunohistochemical Localization of Substance P in Pulp Tissue After In-Office Bleaching Technique in Rats

Rusul J. Hadi <sup>(1)\*</sup>

Nada M. H. AL-Ghaban <sup>(2)</sup>

Ammar A.Fadhil <sup>(3)</sup>

<sup>(1,2)</sup> Department of Oral Diagnosis, College of Dentistry, University of Baghdad, Iraq.

<sup>(3)</sup> Department of Pharmacology and Toxicology, College of Pharmacy, University of Baghdad, Iraq

### Article Info:

**-Article History:**

**-Received:** 6/6/2022

**-Accepted:** 4/9/2022

**-Available Online:**

**Dec, 2022**

### Keywords:

Substance P, Dental pulp,  
Rats, Tooth bleaching.

©2022 COLLEGE OF DENTISTRY TIKRIT UNIVERSITY. THIS IS AN OPEN ACCESS ARTICLE UNDER THE CC BY LICENSE

<https://creativecommons.org/licenses/by/4.0/>



**\*Corresponding Author:**

**Email:**

[russal.j@codental.uobaghdad.edu.iq](mailto:russal.j@codental.uobaghdad.edu.iq)

Department of Oral  
Diagnosis, College of  
Dentistry, University of  
Baghdad, Iraq.

### Abstract

Currently in-office bleaching procedure is the most frequently used in dentistry which represents the most traditional way to modify the color of teeth. The objective of the study is to investigate the pulp response to in-office bleaching procedure with two different concentration of bleaching products by immunohistochemical assessment for Substance P which represent main neuropeptide located in the sensory nerves of the pulp. Twenty four male albino rats were randomly divided equally into two groups. The right maxillary molars were subjected to a single in-office bleaching session with 40% of hydrogen peroxide (Opalescence Boost, UT, USA) (group A) and with 30% of hydrogen peroxide (Philips Dash, USA) (group B). The left maxillary molars in both groups received no treatment used as (negative control). the pulp response were evaluated in 1<sup>st</sup> day (n=6) and 7<sup>th</sup> day (n=6) after bleaching procedure. The upper jaws were processed for H&E stain and immunohistochemical localization of substance P. At 1<sup>st</sup> day there was high mean value of dental pulp cells that positively expressed for substance P antibody in both bleached groups and mostly in 40% bleached group (group A 30.133, group B 27.267) than control group (10.358) with significant p value (0.013) while at 7<sup>th</sup> day this expression was reduced in both groups(mean value of group A was 15.300 while the group B was 11.400). In conclusion the higher the concentration of hydrogen peroxide in bleaching products the further damage to the pulp represents in neurogenic inflammation which explain the increasing in substance P expression.

### Introduction

The dental bleaching is a treatment used to restore the definite natural color of teeth or to accomplish a whiter color and represents a prevalent treatment in

dentistry. The dental bleaching is oxidizing agent, mainly constituting from hydrogen peroxide (H<sub>2</sub>O<sub>2</sub>). It removes the coloring substances by diffusion through

the dental enamel and dentin until reaching the pulp (1). The penetration of H<sub>2</sub>O<sub>2</sub> into dental pulp initiating cellular damage, inflammatory response and vascular permeability causing increase in the pressure inside the pulp resulting in activation of sensory nerve fibers (2). Neurogenic inflammation is speculative to be mediated by releasing many neuropeptides from sensory nerves upon its activation at the site of inflammation (3). Substance P (SP) it is the first neuropeptide to be recognized in the dental tissue and represents the most important neuropeptide among the others. Its main function is to induce vasodilation, increasing pulpal blood flow permitting rapid and large entrance of inflammatory cells and mediators diffuse into the inflammatory site and contributing to the transmission and keep of noxious stimuli and inflammation (4,5). The chief pathway for SP mediated inflammatory reactions is mast cells, which undergo degranulation in response to SP, and releasing of large amounts of pro-inflammatory cytokines and vasoactive mediators; therefore it represents a fundamental mediator of inflammatory progressions and pain in the dental pulp (6). Different methods have been used to study the effects of tooth bleaching on dental pulp up to this point, but nothing is known about the neuropeptide that is released after bleaching. PCR (polymerase chain reaction)(7), radioimmunoassay testing (8), and ELISA (enzyme-linked immunosorbent assay) (9) were among the precise methods used to assess these neuropeptides. These results, however, do not show where these neuropeptides are located in tissue, so for the present study, immunohistochemistry analysis was used to conduct a quantitative inquiry and pinpoint SP neuropeptide's position in the tooth pulp following the bleaching operation.

### **Materials and Methods:**

All experimental procedures were carried out according to the ethical principles of animal research of College of Dentistry, University of Baghdad. Twenty four male Wistar albino rats, each weighing between

250 and 350 gm, were aged between 3 and 4 months. At the University of Baghdad's College of Pharmacy, the animals were housed in an animal house. The rats were kept in groups of six per cage in polycarbonate cages covered in wood shavings, kept in typical laboratory conditions at 25°C, fed regular rat chow pellet meal, and given free access to tap water. The procedure was accomplished in a standard sterilized condition. In order to achieve the bleaching treatment, each animal was weighted to evaluate the dosage of general anesthesia, the general anesthesia was made by Intramuscular injection of xylazine 2% (0.4 mg/kg B.W.), plus ketamine HCL 10% (15 mg/kg- B.W.) to prevent the movement of the rat through the bleaching session.

The rats were randomly divided into two equal groups, the first group (group A):The right maxillary molars in each rat were treated with single in-office bleaching session using 40% of hydrogen peroxide(Opalescence Boost, UT, USA) (2×20min) and the left maxillary molars kept without treatment used as (negative control).The second group ( group B): The right maxillary molars in each rat were treated with single in-office bleaching session using 30% of hydrogen peroxide(Philips Dash, USA) (3×15min) and the left maxillary molars kept without treatment (negative control).

Then each group was divided into two sub groups (6 rats for each) consistent with the time of scarification (1st day and 7th day) after the bleaching session. At the end of each interval, the animals were sacrificed with over dose of ketamine and posterior maxillary segments with three molar teeth were used as specimens.

All tissue specimens were fixed in 10% neutral formalin and processed in a standard paraffin blocks after complete decalcification. Each paraffin-embedded block from all the studied samples were prepared in a 4µm thickness serial sections and mounted on glass slides for routine H&E staining. For the immunohistochemistry localisation of SP, additional 4 µm thick slices were placed on positively charged slides.. The procedure of the IHC assay was carried out in accordance with the manufacturer

instructions of rabbit polyclonal antibody to SP, from Abcam UK company (ab216414) and expose mouse and rabbit specific HRP/DAB Detection IHC Kit from Abcam UK company(ab80436).

The Immunohistochemical examination of SP was done under light microscope and performed by two calibrated operators to confirm the reliability of the study, For each pulp tissue chamber section 5 microscopical fields were examined at high power (x400 ). The mean value of +ve cells (fibroblasts, odontoblasts, endothelial cells, inflammatory cells, nerve cells) in each field were calculated, dental pulp cells with clear membranous/cytoplasmic staining pattern were considered positive for SP antibody because the cellular localization of the SP antibody that was used in this study was secreted in type.

Statistical analysis for dental pulp cells (DPCs) that positively expressed to SP were analyzed using SPSS software version 25. Data was presented by mean, standard deviation, standard error, minimum and maximum values, and tested for the inferential differences by ANOVA test, Games–Howell post hoc test and Paired sample T- test. The P value was considered less than 0.05.

### Results:

Regarding the immunohistochemical findings the control group showed few DPCs (fibroblast, endothelial cells and nerve cells) positively expressed for SP with normal organized pulp tissue at 1st day and 7th days Fig.(1, 2). Most pulp tissues subjected to 40% bleaching revealed at 1st day showed high expression of SP in DPCs surround the necrotic areas (Fig.3 and 4). at 7th day there was less expression of SP in DPCs like fibroblasts, inflammatory cells, and odontoblast-like cells with more organized pulp tissue (Fig.5). Concerning IHC expression in the pulp tissues chamber in 1st day after the bleaching with 30% H<sub>2</sub>O<sub>2</sub> there was high expression of SP in DPCs including fibroblast, inflammatory cells, and endothelial cells (Fig.6). while at 7th day less expression of SP was observed in DPCs and almost normal pulp

tissue in both periods Fig.(7). As regards the results of statistical analysis revealed significant group difference in dental pulp cells that positively expressed for SP at 1st day duration and non-significant group difference at 7th day duration also higher mean value of the number of the pulp cells that had positive reaction to SP was recorded in 40% bleached group compared with other groups at both periods Table(1). Concerning multiple group comparisons by uses Games–Howell post hoc test of positively expressed DPCs for SP at 1 day duration, the result of this test showed significant difference between control and 30% bleached group Table (2).

About the duration difference by Paired sample T- test for DPCs positively expressed for SP in each group. The result showed significant difference between 1day and 7days duration in 30% bleached group and non-significant difference regarding other groups Table (3).

### Discussion:

Tooth bleaching generates several adverse effects including neurogenic inflammation and pain sensation within the tooth, in which SP neuropeptide plays an important role in developing these conditions (3). Neurogenic inflammation has been defined as the involvement of the nervous system in local inflammatory reactions. This process is described by the stimulation of peripheral neurons and these neurons act as environmental sensors which express numerous receptors that make these cells have the capacity to identify and stimulated by harmful thermal, mechanical and chemical stimuli consequently, they release SP, which is stored in the synaptic vesicle of these neurons, changed the vascular processes by vasodilatation, increased vascular permeability and assist in the accumulation of leukocytes (6).

The SP is found in normal healthy pulp since it is released at a constant level from small vesicles stored in the sensory nerves ending in order to preserve the balance of vascularity to maintain blood flow and nutrient supply to the pulp constantly as well as regulate pressure in the interstitial pulp (10).This clarifies the present study's

result, which revealed that a few DPCs were positively immunostaining for SP in the control group without any significant difference between 1st day and 7th days duration with the lowest mean value at both durations when compared with bleached groups. These findings were in agreement with previous study carried by Caviedes-Bucheli *et al.* (2008) (11).

Concerning the 40% bleached group (group A) at 1 day duration, due to the presence of necrotic areas in most specimens, it was only possible to observe the positive expression of SP in the cells that remain in the pulp chamber also this explain the non-significant difference when compared with control group. These finding agreed with recent studies carried by Gallinari *et al.* (2019) (12) and Hadi and AL-Ghaban (2020) (13) which their results revealed necrosis in 1st day after bleaching procedure. On the other hand, the present study revealed advanced number of DPCs that positively expressed for SP was found in the other specimens in the same group and this reflecting the higher mean value of positively expressed DPCs for SP when compared to other groups.

Regarding the 30% bleached group (group B) at 1st day duration, the immunohistochemical finding revealed high number of DPCs that positively expressed for SP in most specimen with significant difference when compared to the control group. This result was in agreement with recent study carried by da Silva *et al.* (2020) (3).

At 7th day duration after bleaching with 40% hydrogen peroxide the immunohistochemical finding revealed decrease in the mean value of the number of DPCs that positively expressed for SP but still higher than control and 30% bleached group, because the inflammation was still present in most specimens. Generally, the inflammatory process produced after tooth bleaching with a high concentration of H<sub>2</sub>O<sub>2</sub> frequently lasts almost 2 weeks. Throughout this time, releases of proinflammatory cytokine continue, These changes result in SP release for extended periods (11).

Regarding the 30% bleached group, the immunohistochemical results after 7th day

showed a significant reduction in the number of DPCs that positively expressed for SP with significant difference compared with 1st day duration since the pulp on 7th day exhibited almost similar expression that resembled the control group. Therefore the present study showed decrease in SP expression within time and these findings agreed with Ismiyatin *et al.* study (2018) (14) who found significant a decline in SP expression in pulp at 72 hours duration when compared to 24 hours duration.

### **Conclusion:**

It is important to focus that the adverse effect of the in-office bleaching agent on the dental pulp was proportional to the concentrations of hydrogen peroxide, therefore the higher the concentration of hydrogen peroxides in bleaching agent the higher penetration and higher inflammatory response, pressure and irritation of sensory nerve fibers subsequent in more SP releasing, and since the inflammatory response after bleaching was reversible there was a declined in SP expression with time.

### **Acknowledgment:**

The cooperation of the staff at the College of Pharmacy University of Baghdad is appreciated.

### **Authors' declaration:**

Conflicts of Interest: None.

We hereby confirm that all the figures and tables in the manuscript are mine ours.

Authors sign on ethical consideration's approval

Ethical Clearance: The project was approved by the local ethical committee in University of Baghdad.

### **Authors contribution statement**

**Rusul J. Hadi** : Conception, design, acquisition of data, analysis, interpretation and to the writing of the manuscript.

**Nada M. H. AL-Ghaban**: Conception, design, acquisition of data, analysis, revision and proofreading.

**Ammar A.Fadhil**: Conception, design, acquisition of data, analysis, interpretation, and to the writing of the manuscript.

**Funding:** Self-sustained



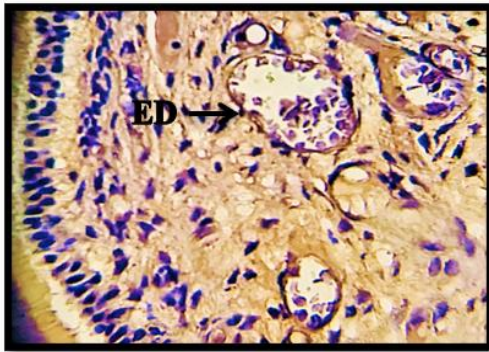


Fig. (1): Microscopical picture of pulp chamber of control group at 1<sup>st</sup> day shows positive expression of SP in endothelial cells (ED) (x400).

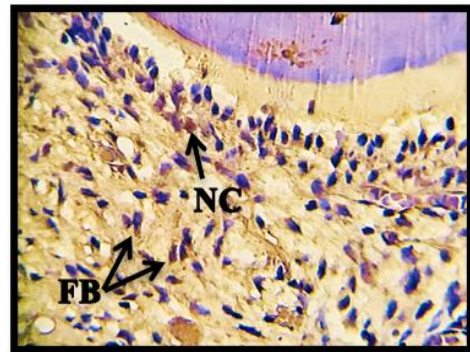


Fig. (2): Microscopical picture of pulp chamber of control group at 7<sup>th</sup> days shows positive expression of SP in nerve cells (NC) and fibroblasts (FB) (x400).

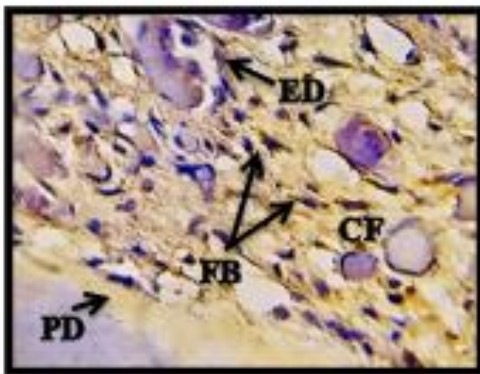


Fig. (3): Microscopical picture of pulp chamber at 1<sup>st</sup> day after subjecting the tooth for 40% of bleaching agent. IHC staining for SP shows positive expression in fibroblast (FB), endothelial cell (ED), collagen fibers (CF) and predentin (PD) (x400).

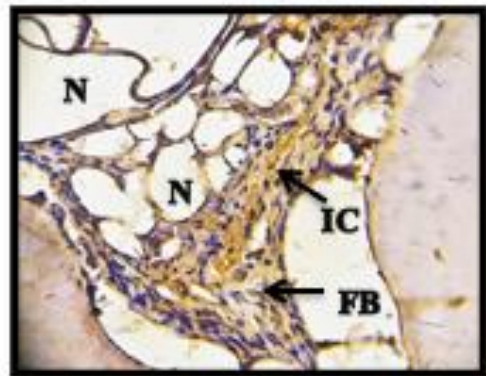


Fig. (4): Microscopical picture of pulp chamber with necrotic areas (N) at 1<sup>st</sup> day after subjecting the tooth for 40% of bleaching agent. IHC staining for SP shows positive expression in fibroblast (FB) and inflammatory cells (IC) (x400).

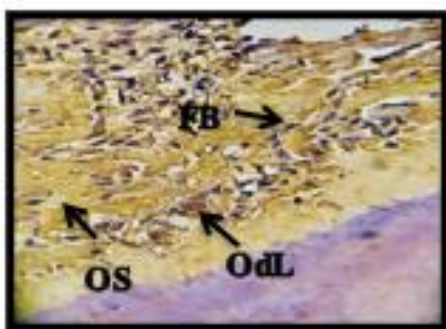


Fig. (5): Microscopical picture of pulp chamber at 7<sup>th</sup> day after subjecting the tooth for 40% of bleaching agent. IHC staining for SP shows positive expression of SP in fibroblasts (FB) and odontoblast-like cells (OdL) that entrapped inside osteodentin (OS) (x400).

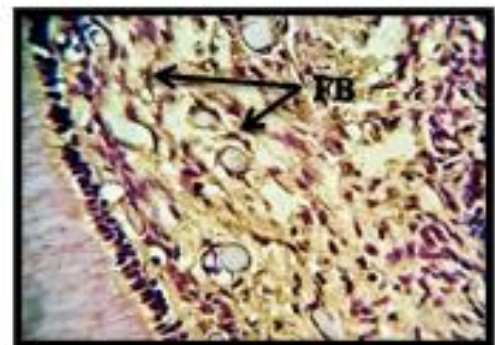


Fig. (6): Microscopical picture of pulp chamber at 1<sup>st</sup> day after subjecting the tooth for 30% of bleaching agent. IHC staining for SP shows positive expression of SP in fibroblasts (FB)(x400).

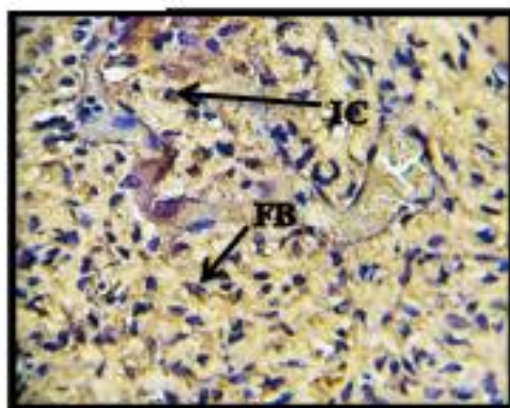


Fig. (7): Microscopical picture of pulp chamber at 7<sup>th</sup> day after subjecting the tooth for 30% of bleaching agent. IHC staining for SP shows positive expression of Substance P in fibroblast (FB) and inflammatory cells (IC) (x400).

Table (1): Descriptive statistics and one way ANOVA test for DPCs positively expressed to Substance P antibody between groups in both periods.

|                         |          | N  | Mean   | ±SD    | ±SE   | Minimum | Maximum | F     | P value    |
|-------------------------|----------|----|--------|--------|-------|---------|---------|-------|------------|
| DPCs1 <sup>st</sup> day | Control  | 12 | 10.358 | 1.368  | .395  | 8.000   | 12.400  | 8.887 | 0.013 Sig. |
|                         | 40% H2O2 | 63 | 30.133 | 22.373 | 9.134 | 13.800  | 61.000  |       |            |
|                         | 30% H2O2 | 67 | 27.267 | 10.679 | 4.360 | 12.600  | 39.400  |       |            |
|                         | Total    | 24 | 19.529 | 14.944 | 3.051 | 8.000   | 61.000  |       |            |
| DPCs7 <sup>th</sup> day | Control  | 12 | 10.550 | .946   | 0.273 | 9.200   | 12.400  | 2.372 | 0.155 NS   |
|                         | 40% H2O2 | 60 | 15.300 | 6.256  | 2.554 | 7.000   | 22.600  |       |            |
|                         | 30% H2O2 | 60 | 11.400 | 3.515  | 1.435 | 5.600   | 15.200  |       |            |
|                         | Total    | 24 | 11.950 | 3.956  | 0.808 | 5.600   | 22.600  |       |            |

DPCs= dental pulp cells  
H2O2= Hydrogen peroxide  
Levene test of DPCs= 33.834, p value is 0.000 HS

Table (2): Multiple group difference by Games–Howell post hoc test for immunohistochemical results in the pulp chamber at 1<sup>st</sup> day duration.

| Multiple Comparisons         |          |                       |            |
|------------------------------|----------|-----------------------|------------|
| Dependent Variable: DPCs1day |          |                       |            |
| Games-Howell                 |          |                       |            |
| (I) Groups                   |          | Mean Difference (I-J) | P value    |
| Control                      | 40% H2O2 | -19.775               | 0.171 NS   |
|                              | 30% H2O2 | -16.908               | 0.026 sig. |
| 40%                          | 30% H2O2 | 2.867                 | 0.957 NS   |

DPCs= dental pulp cells  
H2O2= Hydrogen peroxide

Table (3): Duration difference by Paired sample T- test for DPCs positively expressed for Substance P in each group.

| Paired Samples T Test |   |       |    |            |
|-----------------------|---|-------|----|------------|
| Groups                |   | T     | df | P value    |
| Control group         | DPCs1 <sup>st</sup> day - DPCs7 <sup>th</sup> day | 0.463 | 11 | 0.653 NS   |
| 40% H2O2              | DPCs1 <sup>st</sup> day - DPCs7 <sup>th</sup> day | 2.056 | 5  | 0.095 NS   |
| 30% H2O2              | DPCs1 <sup>st</sup> day - DPCs7 <sup>th</sup> day | 3.250 | 5  | 0.023 sig. |

DPCs= dental pulp cells  
H2O2= Hydrogen peroxide

## References

- Casado BG, Moraes SL, Souza GF, Guerra CM, Souto-Maior JR, Lemos CA, Vasconcelos BC, Pellizzer EP. Efficacy of dental bleaching with whitening dentifrices: a systematic review. *Int J Dent.* 2018 Oct 30;2018.
- Berger SB, Tabchoury CP, Ambrosano GM, Giannini M. Hydrogen peroxide penetration into the pulp chamber and dental permeability after bleaching. *Gen. Dent.* 2013 May 1;61(3):e21-5.
- da Silva LM, Cintra LT, de Oliveira Gallinari M, Benetti F, Rahal V, Ervolino E, de Alcântara S, Briso AL. Influence of pain-relieving therapies on inflammation and the expression of proinflammatory neuropeptides after dental bleaching treatment. *Restor Dent Endod.* 2020 Mar 4;45(2).
- Shida M, Baba T, Taguchi Y, Okamura T, Tanaka A, Ueda M, Hayashi H. Effect of neuropeptides on human dental pulp cells; mRNA expression of proinflammatory cytokines. *J. Osaka Dent. Univ.* 2011;45(1):129-33.
- Suvas S. Role of substance P neuropeptide in inflammation, wound healing, and tissue homeostasis. *J. Immunol.* 2017 Sep 1;199(5):1543-52.
- Caviedes-Bucheli J, Gomez-Sosa JF, Azuero-Holguin MM, Ormeño-Gomez M, Pinto-Pascual V, Munoz HR. Angiogenic mechanisms of human dental pulp and their relationship with substance P expression in response to occlusal trauma. *Int. Endod. J.* 2017 Apr;50(4):339-51.
- Kepler CK, Markova DZ, Hilibrand AS, Vaccaro AR, Risbud MV, Albert TJ, Anderson DG. Substance P stimulates production of inflammatory cytokines in human disc cells. *Spine.* 2013 Oct 1;38(21):E1291-9.
- Caviedes-Bucheli J, Rojas P, Escalona M, Estrada A, Sandoval C, Rivero C, Lombana N, Muñoz HR. The effect of different vasoconstrictors and local anesthetic solutions on substance P expression in human dental pulp. *J Endod.* 2009 May 1;35(5):631-3.
- Bamini L, Anand Sherwood I, Abbott PV, Uthandakalaipandian R, Velu V. Influence of anti-inflammatory irrigant on substance P expression for single-visit root canal treatment of teeth with irreversible pulpitis. *Aust Endod J.* 2020 Apr;46(1):73-81.
- Dennis D, Abidin T, Sumawinata N. Expression of SP and ALP Following the Application of Watermelon Frost in Reversible Pulpitis: An In Vivo Study. *World J. Dent.* 2020 Mar;11(2).
- Caviedes-Bucheli J, Muñoz HR, Azuero-Holguín MM, Ulate E. Neuropeptides in dental pulp: the silent protagonists. *J. Endod.* 2008 Jul 1;34(7):773-88.
- G Gallinari MD, Cintra LT, Benetti F, Rahal V, Ervolino E, Briso AL. Pulp response of rats submitted to bleaching and the use of different anti-inflammatory drugs. *PLoS One.* 2019 Jan 8;14(1):e0210338.
- Hadi RJ, and AL-Ghaban NM. Histological evaluation of pulp response to in-office bleaching technique in rats. *Biochem. Cell. Arch.* 2020; 20(2), pp. 6095-6100.
- Ismiyatin K, Wahlujo S, Adioro Soetojo N, Rahayu RP, Utomo H, Anindya C. The expression of pulpal substance P after dentinal application of Escherichia coli lipopolysaccharide. *Saudi Endod. J.* 2018;9(3):169-72.