

Acetyl Salicylic Acid Improved the Regeneration of the Injured Sciatic Nerve in an Experimental Study

Dr. Ibraheem, A.H * Ph.D.

Dr. TtalibJawad Kazim, T. J. ** Ph.D.

Dr. Mustaf Al-shikh, Y.G, * PHD**

Abstract

A total of thirty-two adult rat (Sprague Dawely) of both sexes weighing 250-350 g were used in this study. These were classified equally and randomly into two groups;

Group (A) and group (B). All the animals were exposed to induction of left sciatic nerve crush injury by using fine forceps after application of surgical procedures. Rats in Group (A) were left to be survive for 15 , 30 , 90 , and 180 days post crush ,p.c (four animals per each period) and considered as control animal. Group (B) were injected by Acetyl Salicylic acid (ASA) 25 mg\kg as anti-inflammatory drug for successive 14 days p.c and left to be survive for 15 , 30 , 90 , and 180 day p.c (four animals per each period) Histological examining and statistical analysis of the nerve specimens for all Survival periods of both groups indicated that application of ASA in case of group (B) gave longer internodes and diameter of the regenerated nerve fibers after 180 day p.c when compared with that of control group at the same period, the mean inter nodal length of the nerve fibers of group (B) after 180 day was 396 μm , and its mean diameter was 8.4 μm while the mean inter nodal length of the nerve fibers of group (A) after 180 day was 277 μm and its mean diameter was 7.2 μm . The result of the present study demonstrated that application of ASA for 14 day intramuscularly and continuously in group (B) improved the regeneration of the injured nerve fibers better than the untreated group (A) and this may reflect the role of ASA to suppress the signs and complication of inflammatory process at the site of sciatic nerve injury , so enhance the re grow of new nerve fibers faster and better than the control group (A).

Introduction

Anatomy/ Dean of College of Veterinary Medicine/ Tikrit university/ Iraq. *

Department of Anatomy/ College of Medicine/ University of Diyala. **

***** Anatomy /WHO/EMRO.**

Peripheral nerve injuries were first described by Waller [1], who described the degenerative change occurring in the distal stump of the crushed peripheral nerve.

Inflammation is a process of tissue damaging, and this process represents a nonspecific response of tissue to immunological and non-immunological reaction [2]. This process requires therapeutic intervention. Ranisford [3] showed that the ability of Acetyl Salicylic Acid (ASA) to suppress the inflammation may develop during the repair of injury in case of experimental rat which can be obtained by repeated doses of (ASA) which significantly inhibits the synthesis of collagen, and decrease the content of RNA in the cell.

The aims of the present study were concerned with the induction of the sciatic nerve crush injury in the rat and then test the effect of (ASA) in the process of nerve repair.

Literature review

Lubinska [4], demonstrated that in the rat phrenic nerve, wallerian degeneration (W.D) begins near the lesion and then spread progressively distal to the lesion, this degeneration advances in less than 5 hours.

Twenty four hours after the injury Schwann cells are hyperactive, the cells become discrete their nuclei, enlarge and develop prominent nucleoli [5]. Seitz et al [6] reported that the site of crush injury associated with breaking down of blood nerve barrier immediately in the distal stump and lead to leakage of serum protein with phagocytic invasion until day 4 after crush, Olsson and Sjosterd [7] observed that a ten fold increase of mast cells on the 4th day at the site of injury of nerve crush was observed.

Therapeutic effect of (ASA) are mainly caused by inhibition of prostaglandin synthesis, these effects are analgesic, antipyretic and anti-inflammatory action. The action and the effect achieved with 30 minutes after I/M administration of ASA [8].

Materials and methods

Thirty-two adult healthy rats (Sprague-Dawley) of both sexes weighing 250-350 gm were used. All were allowed free access to food and water before the experiment, and were divided equally into two groups A and B. The two groups were housed in steel, mesh cages at room temperature. The left sciatic nerve of all animals was subjected to a mechanical crush injury. Group (A) were used to induce nerve crush injury and survived for (15, 30, 90 and 180 days) post injury, (4) animals per period. Anti-inflammatory non-steroidal drug (ASA) was used 25 mg/kg intramuscularly of the group (B) for the first fourteenth day post crush and left to survive for (15, 30, 90 and 180 days) p.c (4) animals per period.

Animals were anaesthetized with intra-peritoneal injection of pentobarbital sodium 2.5 mg /100 gm [9]. An incision was made on the skin over the biceps of the left hind limb. A moderate pressure was applied on the sciatic nerve using sterilized fine forceps for 10 seconds at the level of hip . The muscles were approximated , and the incision was closed carefully by interrupted silk suture.

The rats were killed with over dose of ether after different survival periods (15, 30, 90 and 180 day p.c).

The incision of 1cm was made, muscles were separated to expose the left sciatic nerve 5 mm long of sciatic nerve was removed distal to the site of injury.

Immediately fixed with aldehyde fixative [10] . And post fixed in osmic acid for 4 hours. Each segment of the nerve subdivided into two segments one for nerve teasing and the another for histological technique [11].

Measurement of the teased nerve fibers included length and fiber diameter measured with 10 X eye piece ocular micrometer .

The mean of four diameter for each inter nodal segment was done , 180 – 200 inter node were measured for each specimen [12].

Statistical analysis for each internodal space of nerve fiber was carried out.

Statistical analysis for each internodes of nerve fibers carried out. Length for each internode was plotted graphically against its mean diameter by an statigraf programmed prepared by (statistical graphics Corporation. EXES *U* STAT, Inc., and Lauer Soft Ware: Version 2.1).

Results

The parameters of the normal un crushed sciatic nerve fibers observed in table (1).

Table (2) showed group (A) which included animals were subjected to left sciatic nerve crush and survived for 15,30,90 and 180 day post crush (p.c) left without treatment (control). 15 day p.c showed numerous ,ovoid debris of myelin and axon fragmentation in the engorged endoneurial tubes which infiltrated by leukocytes and macrophages .the perineurium was also having these types of cell .signs of regenerative fibers were detected which appeared as tortous ,but measuring of length or diameter of nerve was not possible. The nerve specimens 30 day (p.c) degenerative changes of nerve fibers were still present , leakage and infiltration of macrophages , mast cells and other inflammatory cells were detectable (fig.1) .

The mean length of inter nodal length was 223 μm . And the diameter was 3.5 μm . The nerve specimen 90 day (p.c) myelin debris was still occurred with the macrophage in the endoneurium with mast cell , another inflammatory cell were also observed (fig. 2) .Regenerative, remyelinated nerve fibers of variable size were examined.

The mean inter nodal length was 253 μm and the mean diameter was 5.9 μm . The nerve specimens 180 day (p.c) myelin debris , macrophage , mast cells and other inflammatory cells were markedly decreased in comparison with the former period of this group , and the peri-neurial connective tissue sheath was investing regenerated remyelinated nerve fibers which appeared irregular (fig.3).

The mean diameter was 7.2 μm .The group (B) was the treated group; nerve specimens 15 day (p.c.), myelin degradation products were observed , myelin debris was still contained in phagocytes in the endoneurium regenerative sprouts were found . The nerve specimens 30 day (p.c); debris of myelin sheath and axon were present in a little amount . The mast cell were rarely seen .numerous new nerve fibers were present , exhibited smooth myelin. The mean of inter nodal length was 276 μm . The mean diameter was 6.3 μm .The nerve specimens 90 day (p.c). There was little debris and few macrophages in between nerve fiber myelinated nerve fibers of variable sizes with regular smooth outline of myelin sheath were observed.

The mean length of nerve fibers was 283 μm .The mean diameter was 6.9 μm . The nerve specimen 180 day (p.c); neither debris nor macrophages were seen; nodes of Ranvier were easily recognized. Fibers were present with regular outlines and thick myelin around it(fig 4). The variable sizes of myelinated nerve fibers were invested by a thick connective tissue of epineurium. The mean length of nerve fiber was 396 μm . The mean diameter of nerve fiber was 8.4 μm .

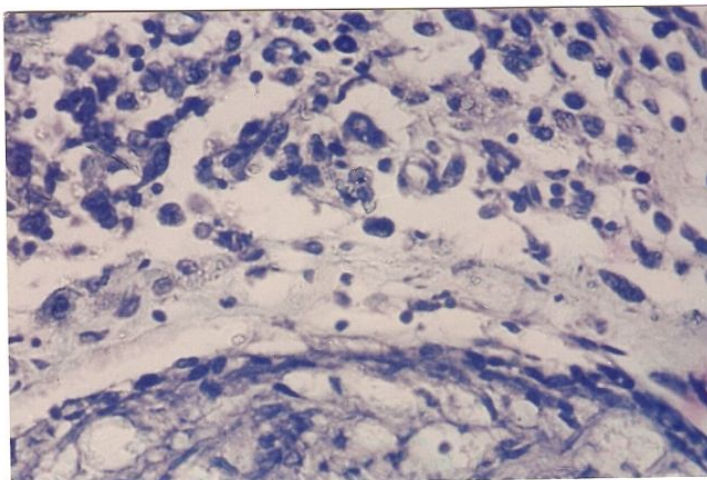


Figure (1): Showing the degenerative changes of nerve fibers and the presence of the inflammatory cells. Control group (A) 30 day (p.c).(Toluidine blue stain.X40).

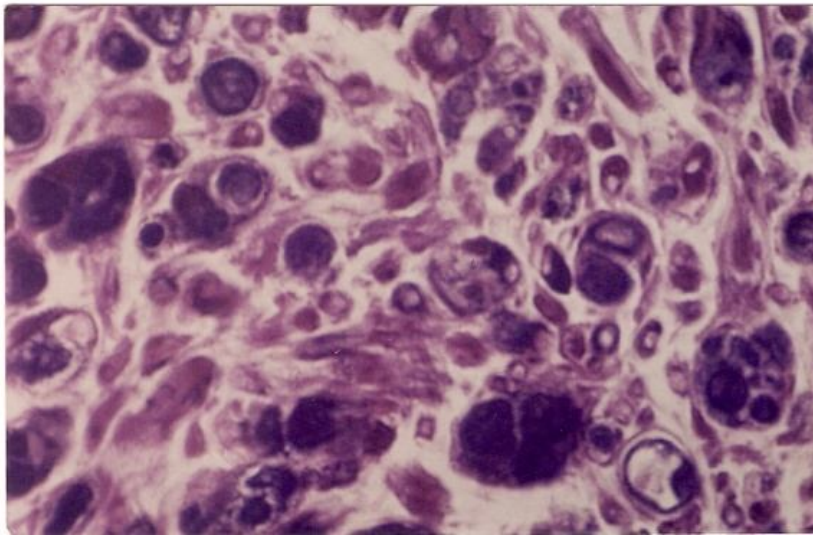


Figure (2): Showing myelin debris in the macrophages of endoneurium, also showing regenerative nerve fiber of variable size after 90 day (p.c) (group A).(Zimmerman stain. X40).

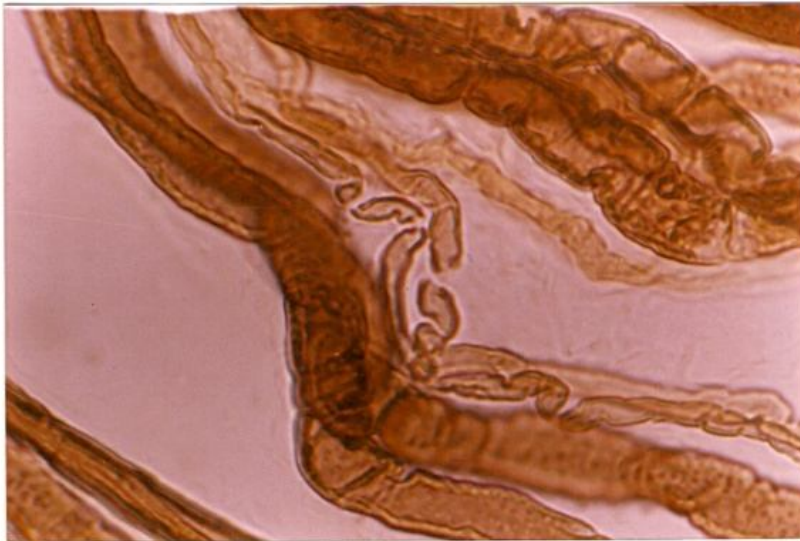


Figure (3): nerve fibers after 180 day (p.c) of control group, showing irregular nerve fibers ensheathed by myeline (osmic acid. X100).



Figure (4): nerve teasing, showing the nerve fibers after 180 day (p.c) also presence of smooth outlines of myelin sheath (osmic acid.X100).

Discussion

Localized nerve injuries resulting in wallerian degeneration , were those produced experimentally by compressing the nerve fibers [3].

The present study demonstrated that the crush nerve injury of sciatic nerve was associated with the paralysis of left leg of the rat . the signs of paralysis were disappeared from 10-12 day (p.c).

Animals were treated with ASA 25 mg\kg Bwt I\m appeared healthy after injection. There was no signs of loss of weight or appetite (p.c).and after treatment.

Haftak and Thomas [14] observed that the first signs of inflammation was appeared after 1-2 hour post injury , characterized by increased of the permeability of damaged capillaries and presence of the endoneurial odema.

William and Hall [15] demonstrated that after (12-48 hour) p.c there was degenerative change of axon .and Gaster [16] showed that mainly , there was an inflammatory cells of all types seen at the site of injury within 2-3 day.

The present study showed that the presence of inflammatory process was detected in both groups , but the treated group with ASA the signs of inflammation , aggregation of inflammatory cells mainly at the first 14 day (p.c).were lesser than that which is not exposed to any treatment.

Although after 15 day of injury, there was new re growth of nerve sprouts at the site of injury. The inter nodal length of nerve fibers and its diameter of group (B) was better than group (A) (control)

untreated group, this reflects the reaction of ASA to suppress the inflammation when administered to the rats for 14 days continuously p.c and this showed the continuous regenerative process which was ultimately included the elimination from inflammatory cells which consider as suppressive factor to elongate the nerve fibers more and at the same time arrest the remyelination process and this confirm the concept put forward by Hildebrand [17] in which it was stated that regenerated myelinated fibers show slow increase in the nodal spacing with the diameter after the complication of the site of the nerve injury by inflammation.

References

- [1] Waller, A.v(1850): Experiments on the section of the glossopharyngeal nerve of the frog. Cited by Bradly 1974 . 423-29.
- [2] Hughes, R.A: immunological aspects of neurological disease. J.med., 1981,3:1027-31.
- [3] Rainsford, K.D(1984): Aspirin and the salicylates Butherworthes London.
- [4] Lubinska, L: Early course of wallerian degeneration in myelinated fiber of the rat phrenic nerve. Br. Res., 1977,130:47.
- [5] Bradley, W.G and Asbury, A.K: duration of synthesis phase in neurilemma cells in mouse sciatic nerve during degeneration. Exp. Neural. 1970, 26:275-282.
- [6] Seitz, R.J, Reiners, K and Toyka, v: the Blood-nerve barrier in wallerian degeneration. Mus.Ner. 1989,12:627-635.
- [7] Olsson, Y. and sjostrand, J.: proliferation of mast cell in peripheral nerves during wallerian degeneration. Acta. Neuropathol. 1969,13:111.
- [8] Kwo, P.Y and Tremaine, W.J.: Non-steroidal anti-inflammatory drug-induced enteropathy. Mayoclin.proc. 1995,55-61.
- [9] Salonen, V. Roytti á, M and pettonen, J.: the effects of nerve transaction on the endoneurial collagen fibril sheaths. Acta Neuropathol. 1987,73:3-21.
- [10] Karnovsky, M.J.: Formaldehyde Glutral-dehyde Fixation of high osmolarity for use in electron microscopy. J.cell Biol. 1965,27:137-138.
- [11] Hildebrand, C. and Jahansson, C.S.: Nodal Spacing in the developing young adult and ageing rat infection alveolar nerve. Dev.Br.Res. 1991,64:175-181.

[12]Thopson ,S.W.: Selected Histochemical and Histpathological methods by Charles library of congress catalog Card Number. 1976,63-9586.

[13]Schlaepfer,W.W and Myers, F.K.: Relationship of myelin inter node elongation and growth in the rat Sural nerve.J.comp.Neurol. 1973,147:255-86.

[14]Haftek,J.and Thomas, P.K .: Electron-Microscope observations on the effects of localized crush injuries on the connective tissues of peripheral nerve .J. Anat. 1968, 103-233.

[15] William , P.L and Hall , S.M: prolonged in vivo observations of normal peripheral nerve fibers and their acute reactions to crush and deliberate trauma. J.Anat. 1971,108:397-408.

[16] Gaster, R.N.,Davidson,T.M and Rand,R.W. :comparison of nerve regeneration rats following controlled freezing or crushing. Arch. Surg. 1971,103:378

[17] Hildebrand,C.,Mustafa,G.Y and Bowe, C.M.:Nodal spacing along regenerated axon following a crush lesion of the developing rat sciatic nerve. Dev. Br.Res. 1987,32:147-154.