

**Study of Effect of Methomyl on Some Hematological, Biochemical Parameters  
and Histological Changes in Male Albino Rats**

**Kalthum Asaaf Maulood and Gawhar Ahmad Shekha**

**Study of Effect of Methomyl on Some Hematological, Biochemical  
Parameters and Histological Changes in Male Albino Rats**

**Kalthum Asaaf Maulood and Gawhar Ahmad Shekha**

Department of Biology- College of Education- Salahaddin University-Hawler  
Kurdistan region-Iraq

Received 15 November 2016 ; Accepted 17 January 2017

**Abstract**

This study has been designed to study the effect of methomyl on hemodynamic, liver and kidney in rats. Methomyl compound (0.5, 1, and 2 mg/kg. bw) was orally administered once per a day during a period of 28 days of experiment. Results showed a significant ( $P < 0.05$ ) decrease in the level of WBC, HCT, MCHC and a non-significant decrease in the level of RBC, HB, MCV, MCH, was observed in the methomyl group, while the level of PLT significantly increased in Methomyl group in comparison with control group. Non-significant decrease in a level of serum urea in all three groups of Methomyl, while serum creatinine level decreased non-significantly in group1 and group 2, but increased non-significantly in group3 of Methomyl when compared with control group. A Significant decrease in the level of HDL, with significant increase in the level of serum cholesterol, ALT and AST. A non-significant increase in the level of TG, LDL, VLDL and ALP of methomyl group when compared with control group. The Histology of liver of rat treated with 0.5, 1 and 2, mg / kg bw. methomyl showed that dilation of central vein, sinusoids between hypertrophied hepatocytes and cytoplasmic vacuolization with loss of radial arrangement of cells, Meanwhile, kidney showed some changes including glomerular degeneration, tubular degeneration, hemorrhage, infiltration and glomerular shrinkage.

**Keywords:** Methomyl, hematological, biochemical change, lipid profile, histopathology.

Study of Effect of Methomyl on Some Hematological, Biochemical Parameters  
and Histological Changes in Male Albino Rats

Kalthum Asaaf Maulood and Gawhar Ahmad Shekha

تأثير الميثوميل على بعض الصفات الدموية والكيموحيوية والتغير النسيجي في ذكور الجرذان البيض

كوهر احمد شيخه و كلثوم عساف مولود

قسم علوم الحياة - كلية التربية - جامعة صلاح الدين- اربيل - أقليم كردستان -العراق

الخلاصة

صممت هذه التجربة لدراسة تأثير مبيد الميثوميل على بعض مكونات الدم والكبد والكلية في الجرذ . الجرعات المستخدمة كانت (0.5 و 1 و 2 ملغم/كغم وزن الجسم). تم تجريع الجرذان عن طريق الفم يوميا ولمدة 28 يوما. أشارت النتائج ظهور انخفاض معنوي ( $<0.05$ ) في مستوى كريات الدم البيض و حجم خلايا الدم المتراصة ومعدل تركيز خضاب الدم وانخفاض غير معنوي في مستوى كريات الدم الحمر ونسبة خضاب الدم ومعدل حجم الكريات ومعدل خضاب الدم في مجموعة الميثوميل. ارتفع مستوى الصفائح الدموية في مجموعة الميثوميل عند مقارنتها بمجموعة التحكم. بين النتائج انخفاض غير معنوي في مستوى اليوريا في مصل الدم في المجاميع الثلاثة للميثوميل وانخفاض غير معنوي في مستوى الكرياتينين في المجموعة الاولى والثانية وارتفاع غير معنوي في المجموعة الثالثة للميثوميل عند مقارنتها بمجموعة التحكم. انخفض مستوى بروتين دهني عالي الكثافة بشكل معنوي مع ارتفاع معنوي في مستوى مصل الكوليستيرول وانزيم الانين ترانزامينيز واسبارتيت ترانس امينيز وارتفاع غير معنوي في مستوى جليسير ايدات الثلاثية وبروتين دهني منخفضة الكثافة والفوسفاتيز القاعدي في مجموعة الميثوميل عند مقارنتها بمجموعة التحكم. أظهر التغير النسيجي لكبد الجرذان المجرعة ب (0.5 و 1 و 2 ملغم/كغم وزن الجسم ) ميثوميل اتساع في الوريد المركزي و تضخم في الجيوب الدموية بين الخلايا الكبدية مع تلاشي الترتيب الشعاعي للخلايا والتغير النسيجي للكلية شملت انحلال الكبيبات و النبيبات الكلوية ونزف الدم وارتشاح الخلايا وانكماش للكبيبات.

**الكلمات المفتاحية:** الميثوميل، التغير الدموي والكيموحيوي، صورة الدهون، التغير النسيجي

Introduction

People in the life exposed to an environmental stressors as a routine part of their existence, about 95% of all chemical toxicity studies were implement on individual chemicals (1, 2). The biological activity of a chemical may be readjustment through concurrent exposure of a test organism to another chemical agent and such interactions might result in addition, or reduction of the effect of the chemical (3). Methomyl S-methyl N-(methylcarbamoyloxy) thioacetamide

**Study of Effect of Methomyl on Some Hematological, Biochemical Parameters  
and Histological Changes in Male Albino Rats**

**Kalthum Asaaf Maulood and Gawhar Ahmad Shekha**

( $C_5H_{10}N_2O_2S$ ), is one of the most common pesticides which are used in the control of insects. It is used in health programs and agriculture; it causes many toxic effects (4). Animals and human exposure occur during spraying of insecticide and ingestion of food contaminated with methomyl (5). The exposure to this insecticide exerts neurodegenerative with high mortality rates (6). Methomyl insecticides inhibit acetyl cholinesterase enzyme activity in the central and peripheral nervous system when ingested in acute exposure (7). Many authors showed that these compounds in both acute and chronic intoxication disturb the redox processes, changing the activities of antioxidative enzymes and causing enhancement of lipid peroxidation in many organs in the body (8). Methomyl induced toxicity against the treated rats (9), by exerting its toxic effect via peroxidative damage to the liver, kidney and splenic cell membranes and cause DNA damage in these organs (10). The changes in biochemical parameters as measured in various body fluids may be the more sensitive indicators due to exposure to pesticides in the environment (11), and histopathological changes consider as a marker for environmental stress when these pesticides used for a long time (12). The aim of the present study is to assess the effect of methomyl on some hematological, kidney and liver function test with lipid profile parameters and histological changes in treated rat's organ.

### **Materials and Methods**

#### **Chemicals**

Methomyl (Methomex, *S*-methyl *N*-(methylcarbamoyloxy) thioacetamide was obtained from the Central Laboratories of Agricultural Pesticides, as a pure white very small crystal powder, it was dissolved in saline and prepared freshly.

#### **Animals And Housing**

Twenty four adult male albino rats were used, the weight of rats were about 200 -250 g . Animals were housed in plastic cages bedded with wooden chips. They were housed under standard laboratory conditions, 12:12 light/dark photoperiod at  $22\pm 2$  °C. The animals were given tap water and standard rat pellets ad libitum.

**Study of Effect of Methomyl on Some Hematological, Biochemical Parameters  
and Histological Changes in Male Albino Rats**

**Kalthum Asaaf Maulood and Gawhar Ahmad Shekha**

### **Experimental Design**

The rats were divided into four groups, each with six animals and continued for 28 days as follows:

Group 1: Control. The rats were given standard rat chow and ad libitum and 0.5 ml of saline orally.

Group 2: The rats were given standard rat chow with Methomyl by oral gavage (0.5 mg/kg bw) daily

Group 3: The rats were supplied with standard rat chow with Methomyl by oral gavage (1 mg/kg bw) daily

Group 4: The rats were supplied with standard rat chow with Methomyl by oral gavage (2 mg/kg bw) daily

### **Body and Organs Weight**

Initial and final body weights were recorded for the calculation of body weight gain, rats were dissected and the liver and kidney weight were determined by using sensitive balance.

### **Blood Sampling**

ketamine hydrochloride (100mg/ kg bw) used and 5ml of blood samples drawn from the heart puncture for each rat in each group, 2ml of blood collected into heparinized tubes for determination of some hematological parameters such as white blood cell (WBC) count, red blood cell (RBC) count, hemoglobin (Hb) concentration, hematocrite (HCT) level, red blood cell indices Mean corpuscular hemoglobin(MCH), Mean corpuscular volume( MCV) and Mean corpuscular hemoglobin concentration(MCHC) and platelet (PLT) count by using coulter counter (Japan). Other 3ml of blood collected in nonheparinized tubes then centrifuged at 3000 rpm for 15 minutes, the serum was used for determination of biochemical parameters like serum urea, creatinine, lipid profile such as cholesterol, Triglycerides( TG), High density lipoproteins( HDL), Low density lipoprotein(LDL) and Very low density lipoprotein(VLDL), liver function

**Study of Effect of Methomyl on Some Hematological, Biochemical Parameters  
and Histological Changes in Male Albino Rats**

**Kalthum Asaaf Maulood and Gawhar Ahmad Shekha**

test Alanine transaminase (ALT), Aspartate transaminase (AST) and Alkaline phosphatase (ALP) using kit for each test by Cobas E411.

### **Histological Examination**

The kidney and liver were removed and fixed in 10% neutral buffered formalin solution, after preparation the sections were stained with hematoxylin and eosin (13) and examined using a light microscope.

### **Statistical Analysis**

Data were expressed as mean  $\pm$  standard error (SE), and were analyzed using Statistical Package for Social Science (SPSS/ Version 20) software. Significance between experimental groups was determined using one way analysis of variance (ANOVA) followed by least significant difference (LSD) test for comparison between two groups. P values less than 0.05 were considered statistically significant.

### **Results**

There was no death during the experimental course (28 days) of the present study. Table (1) shows significant decrease in WBC count ( $9.233 \pm 0.234$ ) in G1, ( $9.200 \pm 0.829$ ) in G2 and ( $9.583 \pm 0.224$ ) in G3 when compared with control group ( $12.400 \pm 0.436$ ), RBC count in G1 was ( $6.878 \pm 0.126$ ), G2 ( $6.772 \pm 0.204$ ) and G3 ( $6.917 \pm 0.183$ ) and Hb level in G1 was ( $13.262 \pm 0.122$ ), G2 ( $13.150 \pm 0.226$ ) and G3 ( $13.067 \pm 0.271$ ) which was decreased non significantly when compared with control group for RBC count was ( $7.163 \pm 0.116$ ) and Hb level was ( $13.717 \pm 0.079$ ) respectively. Level of HCT was decreased significantly in G1 ( $36.733 \pm 0.684$ ) and G3 ( $36.800 \pm 0.301$ ) and increased significantly in G2 ( $37.900 \pm 0.323$ ) compared with control group ( $37.750 \pm 0.224$ ). MCV was decreased non-significantly in methomyl group which were ( $53.17 \pm 0.477$ ) in G1, ( $53.17 \pm 0.601$ ) in G2 and ( $51.50 \pm 0.342$ ) in G3 when compared with control group ( $53.50 \pm 0.563$ ). MCH was decreased non-significantly in G1 ( $18.50 \pm 0.224$ ) and G3 ( $18.67 \pm 0.211$ ) and increased non-significantly in G2 ( $19.17 \pm 0.167$ ) when compared with control group ( $19.00 \pm 0.365$ ). While MCHC was decreased significantly

**Study of Effect of Methomyl on Some Hematological, Biochemical Parameters  
and Histological Changes in Male Albino Rats**

**Kalthum Asaaf Maulood and Gawhar Ahmad Shekha**

in G1, G2 and G3 ( $35.33 \pm 0.715$ ), ( $35.83 \pm 0.307$ ) and ( $35.67 \pm 0.422$ ) respectively when compared with control group ( $38.17 \pm 0.307$ ). Significant increase observed in PLT count in G1 ( $275.83 \pm 42.040$ ) and G3 ( $229.50 \pm 25.947$ ), and decreased in G2 ( $155.17 \pm 8.392$ ) methomyl in comparison with control group ( $161.83 \pm 7.011$ ).

**Table (1): Effect of Methomyl on Some Hematological Parameters in Male Rats and Control Group after 28 days.**

Group	Control	G1 (0.5 mg/kg bw)	G2 (1 mg/kg bw)	G3 (2 mg/kg bw)	P- value
WBC $\times 10^3/\text{mm}^3$	$12.400 \pm 0.436$	$9.233 \pm 0.234$	$9.200 \pm 0.829$	$9.583 \pm 0.224$	0.000
RBC $\times 10^6/\text{mm}^3$	$7.163 \pm 0.116$	$6.878 \pm 0.126$	$6.772 \pm 0.204$	$6.917 \pm 0.183$	0.159
Hb g/dl	$13.717 \pm 0.079$	$13.262 \pm 0.122$	$13.150 \pm 0.226$	$13.067 \pm 0.271$	0.191
HCT%	$37.750 \pm 0.224$	$36.733 \pm 0.684$	$37.900 \pm 0.323$	$36.800 \pm 0.301$	0.002
MCV fl	$53.50 \pm 0.563$	$53.17 \pm 0.477$	$53.17 \pm 0.601$	$51.50 \pm 0.342$	0.885
MCH pg	$19.00 \pm 0.365$	$18.50 \pm 0.224$	$19.17 \pm 0.167$	$18.67 \pm 0.211$	0.206
MCHC %	$38.17 \pm 0.307$	$35.33 \pm 0.715$	$35.83 \pm 0.307$	$35.67 \pm 0.422$	0.023
PLT $\times 10^3/\text{mm}^3$	$161.83 \pm 7.011$	$275.83 \pm 42.040$	$155.17 \pm 8.392$	$229.50 \pm 25.947$	0.000

Table(2) exhibits the serum concentration of urea, creatinine, Cholesterol, TG, HDL, LDL, VLDL, ALT, AST and ALP after 28 days of the oral administration of Methomyl at three different dose levels. According to the kidney function test, serum urea was decreased non-significantly in all three groups which was ( $20.350 \pm 0.888$ ) in G1, ( $18.416 \pm 0.808$ ) in G2 and ( $17.600 \pm 0.524$ ) in G3 in comparison with control group ( $21.261 \pm 0.299$ ). Serum creatinine was decreased non-significantly in G1 and G2 which were ( $0.480 \pm 0.022$ ) and ( $0.483 \pm 0.01$ ) in G1 and G2 respectively, but increased non-significantly in G3 ( $0.545 \pm 0.015$ ) when compared with control group ( $0.540 \pm 0.025$ ). Significant increase were observed in the concentration of Cholesterol in all three groups of Methomyl ( $65.500 \pm 1.335$ ,  $79.000 \pm 1.861$  and  $69.833 \pm 3.590$ ) in G1, G2 and G3 respectively in comparison with control group ( $62.000 \pm 0.862$ ), and non-significant increase in triglyceride concentration which was ( $41.166 \pm 4.206$ ) in G1,

**Study of Effect of Methomyl on Some Hematological, Biochemical Parameters  
and Histological Changes in Male Albino Rats**

**Kalthum Asaaf Maulood and Gawhar Ahmad Shekha**

(49.833±5.940) in G2 and (43.000±4.618) in G3 when compared to control group value (34.333±3.382). HDL decreased significantly, in G1 was (24.133±0.717), in G2 was (24.567±1.322) and in G3 was (20.933±0.581) in comparison with control group which was (28.900±2.487). LDL, VLDL these two parameters increased non-significantly in Methomyl groups, about LDL in G1 was (31.666±1.666), in G2 was (44.266±1.150), in G3 was (38.666±2.691), VLDL in G1 was (8.333±0.881), in G2 was (8.500±1.118) and in G3 was (7.833±0.872) when compared with control group of LDL (26.833±2.358) and VLDL (6.666±0.666). Generally, liver function test (ALT and AST) increased significantly in male rats treated with three dose of Methomyl during 28 days. ALT level in G1 was (139.333±5.931), in G2 was (134.500±3.461) and in G3 was (125.166±9.775) when compared to the control group (119.000±2.542). AST level was (41.500±1.431) in G1, (40.666±1.763) in G2 and (50.166±4.860) in G3 when compared with control group (37.450±3.471). On the other hand, the level of ALP was found to be non-significantly increased in three dose Methomyl administration (287.333±22.340, 306.166±16.541 and 309.000±28.183) in G1, G2 and G3 respectively when compared to the control group (160.833±10.581).

**Table (2): Effect of Methomyl on the Lipid Profile in Male Rats and Control Group after 28 days.**

Group	Control	G1 (0.5 mg/kg bw)	G2 (1 mg/kg bw)	G3 (2 mg/kg bw)	P- value
Serum Urea (mg/dl)	21.261±0.299	20.350±0.888	18.416±0.808	17.600±0.524	0.096
Serum Creatinine (mg/dl)	0.540±0.025	0.480±0.022	0.483±0.01	0.545±0.015	0.739
Cholesterol (mg/dl)	62.000±0.862	65.500±1.335	79.000±1.861	69.833±3.590	0.001
TG(mg/dl)	34.333±3.382	41.166±4.206	49.833±5.940	43.000±4.618	0.269
HDL(mg/dl)	28.900±2.487	24.133±0.717	24.567±1.322	20.933±0.581	0.009
LDL(mg/dl)	26.833±2.358	31.666±1.666	44.266±1.150	38.666±2.691	0.246
VLDL(mg/dl)	6.666±0.666	8.333±0.881	8.500±1.118	7.833±0.872	0.876
ALT (U/L)	119.000±2.542	139.333±5.931	134.500±3.461	125.166±9.775	0.009
AST (U/L)	37.450±3.471	41.500±1.431	40.666±1.763	50.166±4.860	0.000
ALP(U/L)	160.833±10.581	287.333±22.340	306.166±16.541	309.000±28.183	0.099

**Study of Effect of Methomyl on Some Hematological, Biochemical Parameters  
and Histological Changes in Male Albino Rats**

**Kalthum Asaaf Maulood and Gawhar Ahmad Shekha**

The effect of repeated doses of Methomyl insecticide on body weight gain of the male rats was recorded in Table (3) The findings indicated that male rats before treated was (313.00±1.612, 361.33±1.145 and 380.00±2.708) for G1, G2 and G3, after treated with three dose Methomyl for 28 days showed significant increase in their final body weights, in G1 was (363.17±4.743), in G2 was (428.00±2.098) and in G3 was (436.00±6.465) as compared with control group (350.67±9.383).

**Table (3): Effect of Methomyl on Body Weight gain of The Male Rats after 28 Days.**

Body Weight (g)	Control	G1 (0.5 mg/kg bw)	G2 (1 mg/kg bw)	G3 (2 mg/kg bw)	P value
Before	289.67±1.687	313.00±1.612	361.33±1.145	380.00±2.708	0.439
After	350.67±9.383	363.17±4.743	428.00±2.098	436.00±6.465	0.034

Table (4) show the effects of methomyl administration for 28 days on organs weight (liver and kidney), weight of liver increased significantly in all three groups (11.498±0.112, 13.370±0.317 and 13.615±0.722) in G1, G2 and G3 respectively as compared to control group (11.036±0.206). According to kidney weight, the right and left part increase in the weight which were (1.363±0.062) in G1, (1.598±0.080) in G2 and (1.583±0.0187) in G3, but left part was (1.475±0.060) in G1, (1.591±0.106) in G2 and (1.580±0.034) in G3 in comparison with control group for right and left part (1.320±0.062 and 1.420±0.057) respectively.

**Table (4): Effect of Methomyl on Organ Weight of the Male Rats and Control Group after 28 Days.**

Group	Control	G1 (0.5 mg/kg bw)	G2 (1 mg/kg bw)	G3 (2 mg/kg bw)	P value	
Liver (g)	11.036±0.206	11.498±0.112	13.370±0.317	13.615±0.722	0.000	
Kidney (g)	Right	1.320±0.062	1.363±0.062	1.598±0.080	1.583±0.0187	0.002
	Left	1.420±0.057	1.475±0.060	1.591±0.106	1.580±0.034	0.001

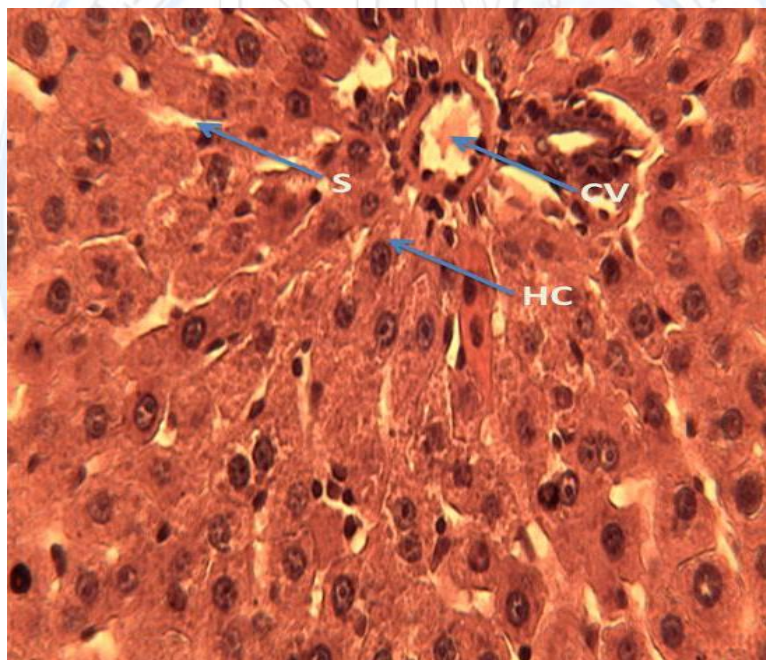


**Study of Effect of Methomyl on Some Hematological, Biochemical Parameters  
and Histological Changes in Male Albino Rats**

**Kalthum Asaaf Maulood and Gawhar Ahmad Shekha**

**Histopathological Changes In Liver And Kidney**

Normal liver structure appeared in the form of hepatic lobules in which there were centrally located central veins, which were surrounded by hepatocytes arranged in the form of hepatic cords separated from each other by hepatic sinusoids (Fig. 1A). The liver of rats treated with methomyl at dose level 0.5 mg/kg bw, after 28 days of treatment was normal as control (Fig. 1B). However, the liver of rats treated with methomyl at dose level 1 and 2 mg/kg bw, after 28 days of treatment showed degenerative changes in the liver including dilation of central vein, congestion blood vessels, infiltration and vasodilatation (Fig. 1C and 1D).



**Figure.1.a. Photomicrograph of normal architecture with normal hepatocytes central vein (cv), hepatic cells (hc) sinusoids(s). Control group. Haematoxylin/eosin staining; 400**

**x.**

Study of Effect of Methomyl on Some Hematological, Biochemical Parameters  
and Histological Changes in Male Albino Rats

Kalthum Asaaf Maulood and Gawhar Ahmad Shekha

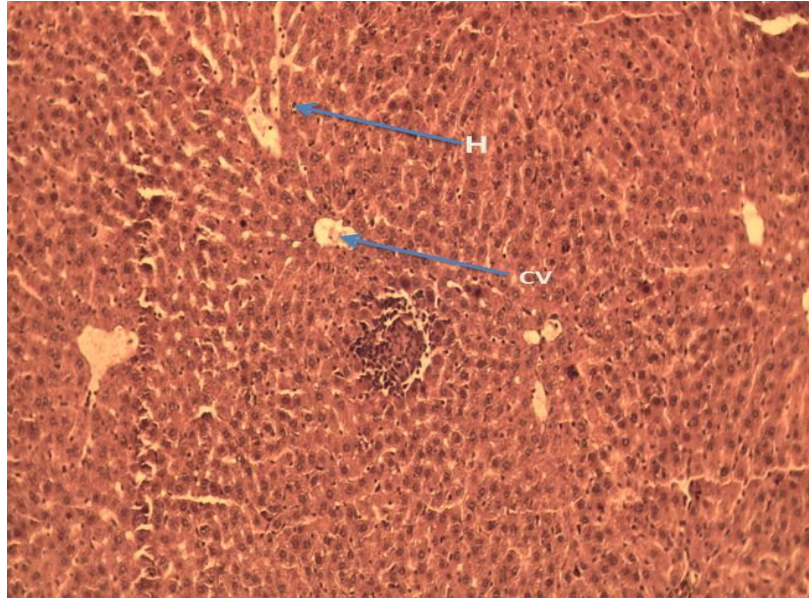


Figure.1.b. Photomicrograph of rats treated with 0.5 mg/kg bw methomyl showing normal histological structure . Normal hepatocytes, central vein (cv), hepatic cells (hc) haematoxylin/eosin staining; 100 x.

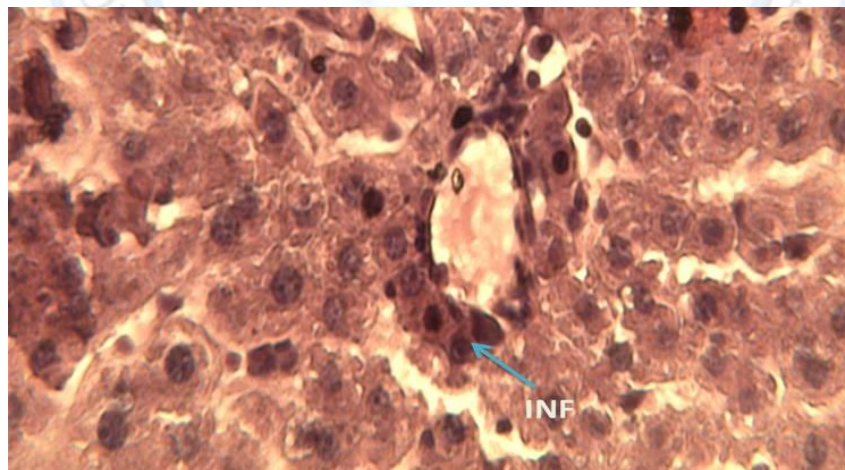
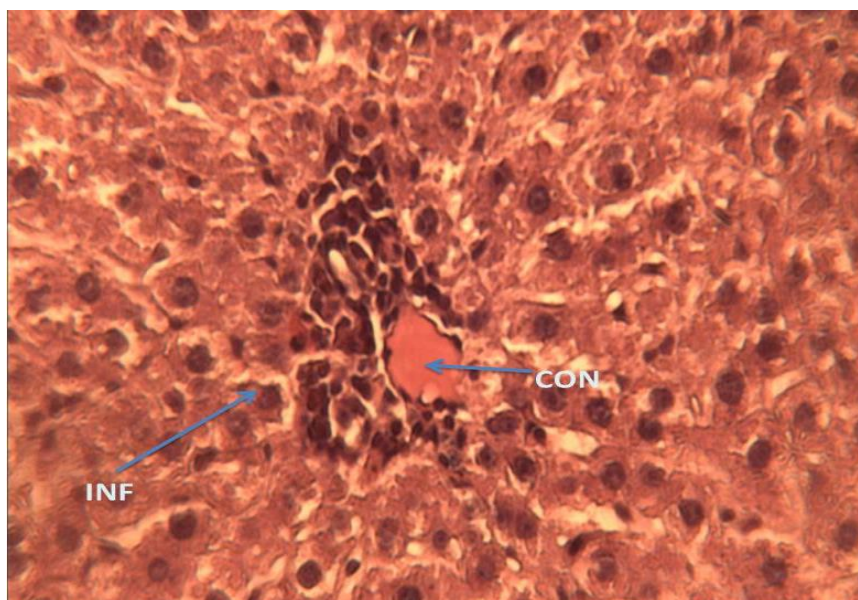


Figure.1.c. Photomicrograph of treated rats with 1 mg/kg bw methomyl showing dilation of central vein, infiltration (inf) , vasodilatation . Haematoxylin/eosin staining;4100 x.

Study of Effect of Methomyl on Some Hematological, Biochemical Parameters  
and Histological Changes in Male Albino Rats

Kalthum Asaaf Maulood and Gawhar Ahmad Shekha



**Figure.1.d. Photomicrograph of rats treated with 2 mg/kg bw methomyl showing dilation of central vein, congestion blood vessels(con) ,advanced infiltration(inf) and vasodilatation. Haematoxylin/eosin staining; 400x .**

In normal histologic structure of the kidney, the cortex contains glomerular tufts scattered in between proximal and distal convoluted tubules (Fig.2A). Kidney of rats treated with Methomyl at dose level 0.5 mg/kg bw, after 28 days of treatment showed no changes (Fig. 2B). However, for rats treated with Methomyl at dose 1 and 2 mg/kg bw, after 28 days of treatment caused destruction of the normal pattern of the renal tissue. These damages were encountered by the presence of shrinkage of glomerular tuft, thickening of parietal layer of Bowman's capsule, glomerular degeneration as well as cellular infiltration is clearly seen and renal medulla showed dilated collecting tubules stuffed with R.B.Cs. (Fig.2 C, D and E).

Study of Effect of Methomyl on Some Hematological, Biochemical Parameters  
and Histological Changes in Male Albino Rats

Kalthum Asaaf Maulood and Gawhar Ahmad Shekha

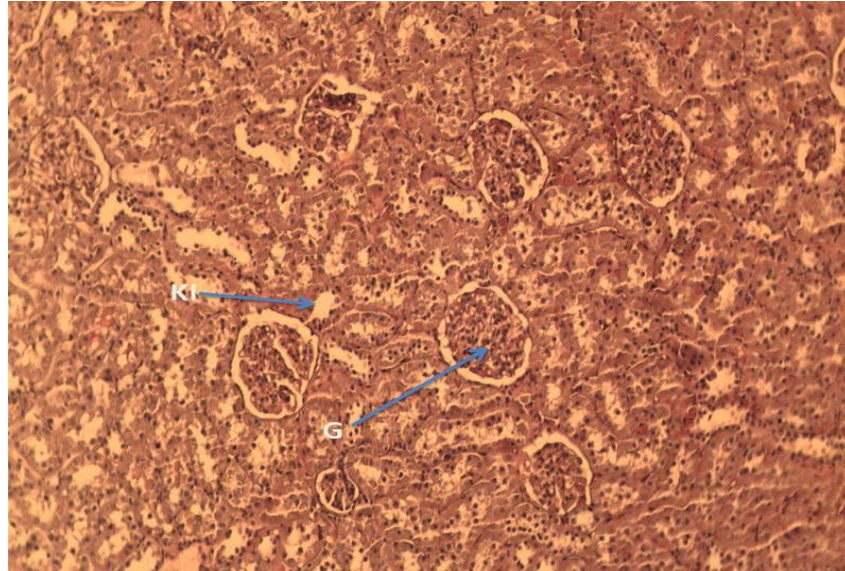


Figure.2.a. Photomicrograph of the kidney from control rat, showing the normal histological structure of renal parenchyma, rounded glomerulus (g), normal kidney tubules (kt) with narrow lumen lined by cuboidal epithelium. Haematoxylin/eosin staining; x100.

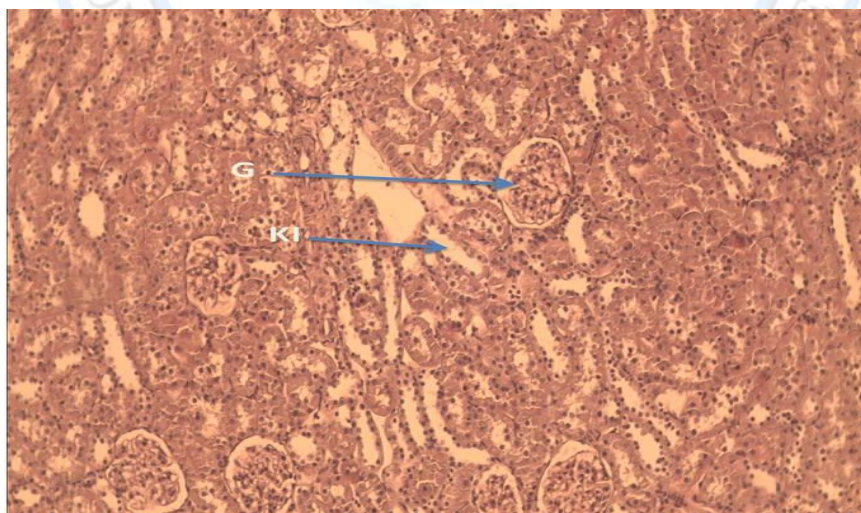


Figure.2.b. Photomicrograph of rats treated with 0.5 mg/kg bw methomyl showing normal histological structure . Glomerulus (g), normal kidney tubules (kt) haematoxylin/eosin staining; x100 .

Study of Effect of Methomyl on Some Hematological, Biochemical Parameters  
and Histological Changes in Male Albino Rats

Kalthum Asaaf Maulood and Gawhar Ahmad Shekha

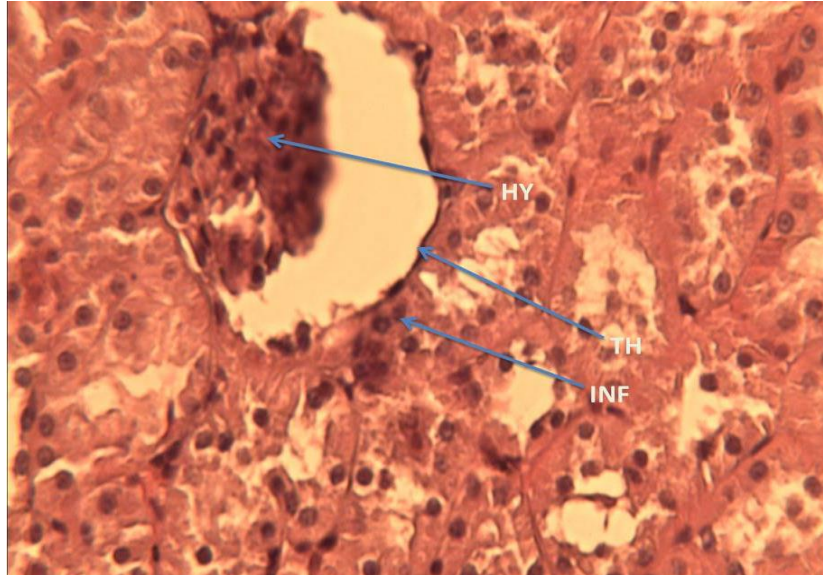


Figure.2.c. Photomicrograph of treated rats with 1mg/kg bw methomyl from renal cortex showing hypertrophy of glomerular tuft(hy), thickening of parietal layer of bowman's capsule(th) and infiltration(inf) . Haematoxylin/eosin staining. 400x.

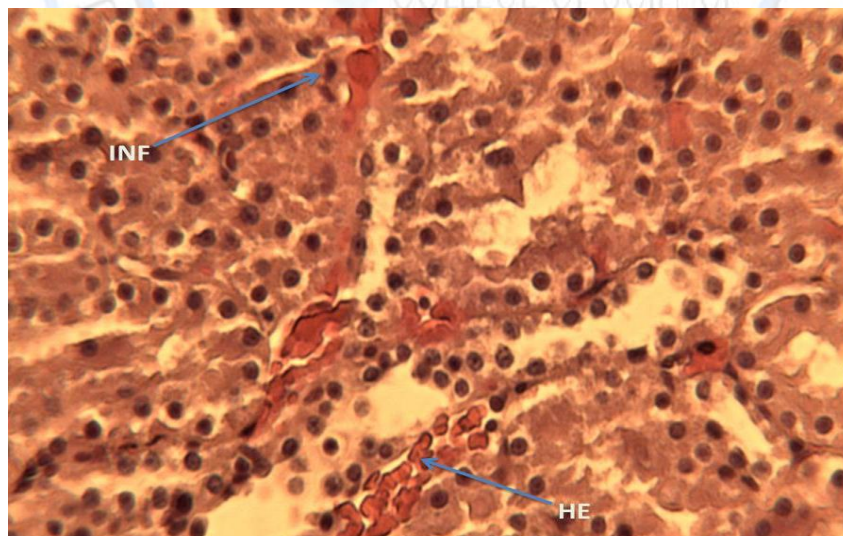
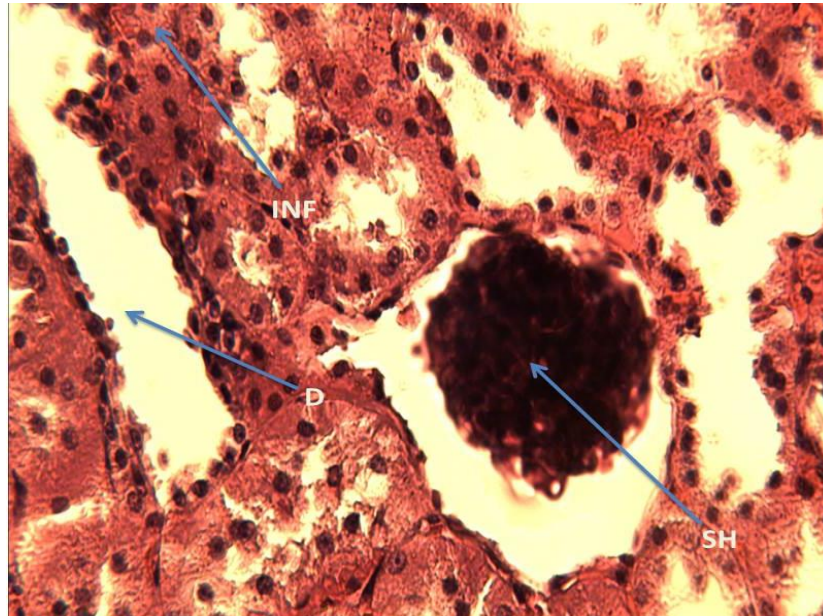


Figure.2.d. Photomicrograph of rats treated with 2 mg/kg bw methomyl from the renal cortex showing focal area of mononuclear cellular infiltration (inf), hemorrhage in the lumen of renal tubules (he). Haematoxylin/eosin staining; 400x..

**Study of Effect of Methomyl on Some Hematological, Biochemical Parameters  
and Histological Changes in Male Albino Rats**

**Kalthum Asaaf Maulood and Gawhar Ahmad Shekha**



**Figure.2.e. Photomicrograph of treated rats with 2 mg/kg bw methomyl from kidney showing shrinkage of glomerular tuft(sh), infiltration(inf) and dilation of the lumen of renal tubules(d) . Haematoxylin/eosin staining; 400x .**

### **Discussion**

In the present study, the RBC's count, Hb concentration and PCV were decreased with MCV, MCH and MCHC in methomyl treatment. The anemia observed might have been due to the ability of the methomyl to cause acute hemolysis or it might be due to cause oxidative stress, these changes due to an increase rate of breakdown of red cells and/or the toxic effect of methomyl on bone marrow. (14). The reduction in Hb content may be due to increased rate of breakdown of red cells and/or reduction in the rate of formation of RBC's. The present result is similar to that of (15) who observed a decrease in RBC's count, Hb concentration and PCV in rats exposed to methomyl (1.70 mg/kg bw) for 90 day. Creatinine is excreted completely in urine via glomerular filtration, an elevation of its level in the blood is indicator for impaired kidney function (16). When liver cell plasma membrane is damaged, a variety of enzymes normally located in the cytosol are released into the blood stream. Their estimation in the serum

**Study of Effect of Methomyl on Some Hematological, Biochemical Parameters  
and Histological Changes in Male Albino Rats**

**Kalthum Asaaf Maulood and Gawhar Ahmad Shekha**

is a useful quantitative marker of the extent and type of hepatocellular damage. One of the most sensitive indicators of hepatocyte injury is the release of intracellular enzymes, such as AST, ALT and ALP in the circulation when methomyl used(17). The present results showed a significant increase in the activities of AST, ALT and ALP in the serum of treated rats suggesting that methomyl might cause critical injury to the liver. The increased levels of serum enzymes indicate an improvement of permeability, hepatocyte damage or necrosis (18). AST and ALT are important and critical enzymes in the biological processes, these enzymes are involved in the breakdown of amino acids into  $\alpha$ -keto acids which are coursed for complete metabolism through the Krebs's cycle and electron transport chain (19) The histopathological examination results in this study demonstrated that 28 day the oral intake exposure of rat to methomyl at the tested dose 1 and 2 mg/kg bw. resulted in degenerative changes in the liver including congestion blood vessels, infiltration ,vasodilatation and hemorrhage. The liver recognized as a target organ of the toxic impact regarding its function in biotransformation and excretion of xenobiotic (20). These present results are in agreement with (21) who reported similar histopathological changes including mononuclear cell infiltration, congestion, hydropic degeneration and hepatocellular damage in the liver of male rats treated with dimethoate, endosulfan and carbaryl. Also (22) who found that a 30-day exposure of male rats to dimethoate at doses of 6 and 30 mg/kg caused portal inflammation, centrizonal congestion and focal hepatocyte necrosis in the liver of rats. Nephrotoxicity can result in systemic toxicity causing decreased ability to excrete body wastes, inability to maintain body fluid and electrolyte balance and decreased synthesis of essential hormones (23), the result in this study come in accordance with the results obtained by (24) who reported that exposure of rats to methomyl (2 mg/kg) noticeably affected glomeruli, tubules and interstitium. Glomeruli appeared swollen bowman's spaces. Glomerular swelling was primarily caused by congestion of glomerular capillaries and thickening of glomerular basement membranes (25) and( 26) observed proliferation and swelling of glomerular endothelial cells and tubular degeneration, mononuclear cell infiltration and fibrosis in thiodicarb and carbendazim treated rats, respectively . also the results in this

**Study of Effect of Methomyl on Some Hematological, Biochemical Parameters  
and Histological Changes in Male Albino Rats**

**Kalthum Asaaf Maulood and Gawhar Ahmad Shekha**

study agree with the findings of (27) and(28) they reported kidney damage such marked tubular dilation, hydropic degeneration in tubular lining epithelium, moderate congestion and hemorrhage in the cortical male Wistar rats exposed some organophosphate pesticides.

**Conclusion**

The results of the present study suggest that Methomyl has the capability to change the hematological and physiological parameters, in addition dysfunction and tissue degeneration in liver and kidney of treated rats, and the effect was pronounced with the long time exposure. Therefore, the application of the Methomyl should be limited to a designed program with special care in handling to limit or minimize its hazards.

**References**

1. Simmons JE.1995. Chemical mixtures. Challenge for toxicology and risk assessment. J Toxicol.105: 111-9.
2. Groten JP, Cassee FR, Van Bladeren, PJ, Rosa C De. and Feron VJ,.1999. In Mixtures: Marguardt H, Schafer SG, McClellan R, Welsch F. (eds.) Toxicology. Academic Press, NY; 257-70.
3. Eaton DL, Klaassen CD. Principles of toxicology.2001. In: Klaassen CD (eds.) Casarett and Doull's toxicology. The basic science of poisons. New York: McGraw-Hill: 11-4.
4. Djefal A, Messarah M, Boumendjel A, Kadeche L. and Feki AE.2015. Protective effects of vitamin C and selenium supplementation on methomyl-induced tissue oxidative stress in adult rats. Toxicol. and Indust Health. 31: 31-43.
5. Gil HW, Jeong MH, Park JS, Choi HW, Kim SY. and Hong SY. 2013..An outbreak of food borne illness due to methomyl pesticide intoxication in Korea. J Korean Med Sci. 28: 1677-1681.



**Study of Effect of Methomyl on Some Hematological, Biochemical Parameters  
and Histological Changes in Male Albino Rats**

**Kalthum Asaaf Maulood and Gawhar Ahmad Shekha**

6. Lee BK, Jeung KW, Lee HY. and JungYH.2011. Mortality rate and pattern following carbamate methomyl poisoning. Comparison with organophosphate poisoning of comparable toxicity. *Clinic Toxicol.* 49: 828-833.
7. Vidyasagar J ,Karunakar N, Reddy M S , Rajnarayana K , Surender T and Krishna D R. 2004.Oxidative stress and antioxidant status in acute organo phosphorous insecticide poisoning. *Indian J. Pharmac.* 36: 76–79.
8. Costa LG. 2006. Current issues in organophosphate toxicology. *Clin. Chim. Acta.* 306: 1–13.
9. El-Fakharany II, Massoud AH, Derbalah AS. and SaadAllah MS.2011 .Toxicological effects of methomyl and remediation technologies of its residues in an aquatic system. *J. Environ. Chem. Ecotoxicol.* 3(13): 332-339.
10. El-Khawaga OA.2005. Role of selenium on antioxidant capacity in methomyl-treated mice. *J. Physiol. Biochem;* 61(4): 501-506.
11. WHO.1992. Our Planet, Our Health, Report of WHO Commission on Health and Environment. World Health Organization, Geneva .
12. Hinton DE, Baumann, PC, Gardner, G R, Hawkins, WE, Hendricks, JD, Murchelano, RA, RA, RA, RA and Okihiro MS.1992. Histopathologic biomarkers: In Biomarkers, Biochemical, Physiological, and Histological Markers of Anthropogenic Stress; Lewis Publishers: BocaRaton. 155-209.
13. Bancroft J D, Stevans A. and Turnes D R.1996. Theory and Practice of Histological Techniques 4th ed, Edinburgh.
14. Garg DP, Kiran R, Bansal AK, Malhotra A, Dhawan DK.2008 .Role of vitamin E in mitigating methomyl induced acute toxicity in blood of male wister rats. *Drug Chem Toxicol;* .31: 487-499.
15. Mossa A-TH.and Abbassy MA. 2012.Adverse haematological and biochemical effects of certain formulated insecticides in male rats .*Research J of Environm Toxicol.* 6: 160-168.

**Study of Effect of Methomyl on Some Hematological, Biochemical Parameters  
and Histological Changes in Male Albino Rats**

**Kalthum Asaaf Maulood and Gawhar Ahmad Shekha**

16. Lu FC.1996. Basic Toxicology: Fundamental Target, Organs, and Risk Assessment. 3rd ed. Washington. Taylor & Francis.358p
17. Patil JA, Patil AJ, Sontakke AV. and Govindwar SP.2008. Effect of methomyl on hepatic mixed function oxidases in rats. Indian J Pharmacol. 40:158-163.
18. Zeb Shah T, Ali AB, Ahmad Jafri S. and Qazi MH.2013. Effect of Nicotinic Acid (Vitamin B3 or Niacin) on the lipid profile of diabetic and non- diabetic rats. Pak J Med Sci; 29: 1259-1264
19. Harper HA, Rodwell VW, Mayes PA, Cochrum KC; Grodsky GM; Martin DW; Tyler DD, and Wallin JD.1979. Review of Physiological Chemistry.17 th ed; California Lange Medical Publications.. 401-404.
20. Roganovic, Z D and Jordanova M.1998."Liver lesions in bleak (*Alburnus alburnus* alborella Filippi) collected from some contaminated sites on lake Ohrid. Ahistopathological evidence,"Ekol. Zast.Zivot.Sred. 6: 11-18.
21. Selmanoglu G. and Akay, MT.2000. Histopathological effects of the pesticide combinations on liver, kidney and testis of male albino rats. Pesticides. 15: 253-262.
22. Sharma Y, Bashir S, Irshad M, Nage TC and Dogra T.2005. Dimethoate-induced effects on antioxidant status of liver and brain of rats following sub chronic exposure. Toxicology. 215:173-181.
23. Massoud AA, Derbalah AS, Iman A, Abd-Elaziz IA.and Ahmed MS.2010. Oral Toxicity of Malathion at Low Doses in Sprague-Dawley Rats: A Biochemical and Histopathological Study. Monofyia Vet. J.; 7: 1:183-196.
24. Laurent G, Toubreau G, Heuson-Steinnon JA, Tulkens P. and Maldauge P.1988 .Kidney tissue repair after nephrotoxic injury: biochemical and morphologic characterization. CRC Crit. Rev. Toxicol. 19: 147-183.
25. Nariman AR, Ahmed AR, Amira HM. and Dessouky MI.1995. Serum bio-chemical and histopathological changes associated with repeated exposure of rats to Thiodicarb insecticide. Egypt. J. Comp. Pathol. Clin. Pathol. 8: 79-85.

## Study of Effect of Methomyl on Some Hematological, Biochemical Parameters and Histological Changes in Male Albino Rats

**Kalthum Asaaf Maulood and Gawhar Ahmad Shekha**

26. Selmanoglu G, Barlas N, Songür S. and Koçkaya EA.2001 .Carbendazim-induced hematological, biochemical and histopathological changes to the liver and kidney of male rats. Hum. Exp. Toxicol. 20: 625-630.
27. Kerem, M, Bedirli N , Gurbus N, .Ekinçi N. N, Bedirli A, Akkaya T, and Pasaoglu H. 2007. "Effects of acute fenthion toxicity on liver and kidney function and histology in rats," Turk. J. Med.Sci. 37: 281-288.
28. Afshar S A, Farshid R, Heidari and Ilkhanipour M.2008. changes in the liver and kidney tissues of wister albino rat exposed to fenitrothion Toxicol Ind Health .24. (9):581-586.

