



## Tikrit Journal of Pharmaceutical Sciences

Available online at: <https://tjphs.tu.edu.iq>

ISSN: 1815-2716(print); ISSN: 2664-231X (online)



### Nephroprotective effect of vinpocetine against vancomycin-induced nephrotoxicity in rats

Hassanen Ayad Abdulameer<sup>1</sup>, Adeb Ahmed Al-Zubaidy<sup>2</sup>

<sup>1</sup>Laboratories Department, Medico-legal Directorate, MOH, Baghdad, Iraq

<sup>2</sup>Department of Pharmacology, College of Medicine, University of Warith Al-Anbiyaa, Karbala, Iraq

#### ARTICLE INFO.

##### Article history:

-Received: 26/07/2023  
 -Received in revised: 17/08/2023  
 -Accepted: 30/08/2023  
 -Available online: 15/12/2023

##### Keywords:

*Nephrotoxicity, Oxidative stress, Vancomycin, Vinpocetine*

##### \*Corresponding author:

Hassanen Ayad Abdulameer  
[tox0849@gmail.com](mailto:tox0849@gmail.com)

© 2023

COLLEGE OF PHARMACY,  
 TIKRIT UNIVERSITY.

THIS IS AN OPEN ACCESS  
 ARTICLE UNDER THE CC BY  
 LICENSE

<https://creativecommons.org/licenses/by/4.0/>



##### Citation:

Abdulameer H. A .and Al-Zubaidy A. A. Nephroprotective effect of vinpocetine against vancomycin-induced nephrotoxicity in rats. Tikrit Journal of Pharmaceutical Sciences. 2023;17(2):1-12.  
<http://doi.org/10.25130/tjphs.2023.17.2.1.1.12>

#### Abstract

**Background:** The kidney is a vital organ for the body and is vulnerable to drug toxicity. For methicillin-resistant Staphylococcus aureus, vancomycin is the antibiotic of choice. It has been accompanied by nephrotoxicity, which restricts its use. Numerous studies have reported that nephrotoxicity was linked to oxidative stress and inflammatory response. Vinpocetine is a derivative of vincamine alkaloid used to treat some neurological disorders and has antioxidant and anti-inflammatory effects. **The objective of the study:** To evaluate the nephroprotective effect of vinpocetine against vancomycin-induced nephrotoxicity in rats. **Methods:** Twenty-four albino male rats were randomly selected and divided into three groups (n = 8): (1) Normal group: apparently healthy rats. (2) Induction group: treated with vancomycin (200mg/kg) twice daily intraperitoneally for 14 days. (3) Vinpocetine group: As the group (2) and treated with vinpocetine (2.5mg/kg) twice daily orally, an hour before vancomycin administration. **Results:** Vinpocetine group demonstrated a significant decrease in urea, creatinine, and cystatin C serum levels compared to the induction group. Also, it showed a significant reduction in the renal tissue level of malondialdehyde and a significant elevation in the renal tissue level of glutathione as compared to the induction group. Furthermore, the vinpocetine group showed a significant decrease in the renal tissue levels of tumour necrosis factor-alpha and neutrophil gelatinase-associated lipocalin. Histologically, all rats in vinpocetine group showed a significantly reduced level of renal tissue damage. **Conclusion:** The present study shows that vinpocetine exhibited nephroprotective due to its antioxidant and anti-inflammatory effects.

## التأثير الوقائي الكلوي للفينبوسيتين على السمية الكلوية التي يسببها الفانكوميسين في الجرذان

اديب احمد الزبيدي

حسنين اياد عبد الامير

### الخلاصة

**نبذة:** تعد الكلى عضواً حيوياً في الجسم وهي عرضة للتسمم بالادوية. للمكورات العنقودية الذهبية المقاومة للميثيسيلين، فإن الفانكوميسين هو المضاد الحيوي المفضل. لقد كان استخدام الفانكوميسين مصحوباً بالسمية الكلوية، مما يحد من استخدامه. لقد أفادت العديد من الدراسات أن السمية الكلوية مرتبطة بالإجهاد التأكسدي والاستجابة الالتهابية. ان الفينبوسيتين هومشتق من فلويد الفينكامين. وهو مثبط النوع الأول من أنزيم الفوسفودايستيريز، يستخدم لعلاج بعض المشاكل العصبية وله تأثيرات مضادة للأكسدة ومضادة للالتهابات. **الهدف من الدراسة:** لتقييم التأثير الوقائي للفينبوسيتين ضد السمية الكلوية التي يسببها الفانكوميسين في الجرذان. **طريقة العمل:** تم اختيار أربعة وعشرين من ذكور الجرذان البيضاء وقسمت عشوائياً إلى ثلاثة مجموعات (عدد الحيوانات في كل مجموعة 8): (1) المجموعة الضابطة السالبة السليمة: جرذان تبدو سليمة. (2) المجموعة الضابطة الموجبة: تم اعطاء الفانكوميسين (200 مجم/كغم) مرتان يومياً داخل الصفاق لمدة 14 يوماً. (3) مجموعة الفينبوسيتين: عولجت مثل المجموعة الثانية مع اعطاء الفينبوسيتين (2.5 مجم/كغم) مرتان يومياً عن طريق الفم، بساعة واحدة قبل اعطاء الفانكوميسين لمدة 14 يوماً. **النتائج:** أظهرت مجموعة الفينبوسيتين إنخفاضاً معنوياً في مستويات مصّل اليوريا، الكرياتينين، والسيستاتين سي مقارنة بالمجموعة الضابطة الموجبة. كما أظهرت نماذج الأنسجة الكلوية لمجموعة الفينبوسيتين إنخفاضاً معنوياً في مستوى ألمانودايلديهايد وارتفاعاً كبيراً في مستوى ألبوتاتيون عند مقارنتها بالمجموعة الضابطة الموجبة. علاوة على ذلك، كانت مستويات عامل نخر الورم ألفا و البيوكالين المرتبط بالجيلاتينيزالعدلة منخفضة معنوياً في نماذج الأنسجة الكلوية لمجموعة الفينبوسيتين. نسيجياً، أظهرت جميع الجرذان في مجموعة الفينبوسيتين إنخفاضاً معنوياً في مستوى إصابة الأنسجة الكلوية. **الاستنتاج:** أثبتت الدراسة الحالية أن الفينبوسيتين أظهر تأثير وقائي للكلية بسبب تأثيره المضادة للأكسدة وللألتهابات.

## Introduction

Nephrotoxicity is a deterioration in kidney functions<sup>(1)</sup> due to endogenous or exogenous toxicants<sup>(2)</sup>. Myoglobinuria, hemoglobinuria, and hyperuricosuria are examples of endogenous nephrotoxins. Exogenous nephrotoxins have a broader spectrum, including heavy metals like mercury; organic vehicles like carbon tetrachloride; phytochemicals like aristolochic acid; contrast dye<sup>(3)</sup>; and medications like aminoglycosides, vancomycin, amphotericin B, colistin, cidofovir, and platin-containing chemotherapeutics<sup>(4)</sup>. Vancomycin is a glycopeptide antibiotic naturally separated from the soil *Amycolatopsis orientalis* bacteria and was approved by the FDA in 1958<sup>(5)</sup>. Vancomycin stays the first-line antibacterial drug for managing infection caused by methicillin-resistant strains of *Staphylococcus aureus* (MRSA), such as endocarditis, osteomyelitis, pneumonia, bacteremia, and meningitis<sup>(6)</sup>. Many randomised clinical trials subsequently proved that vancomycin induces a higher nephrotoxicity risk than the majority of other antibiotics. The recorded incidence of vancomycin-induced nephrotoxicity was 9.4%<sup>(7)</sup>. The criteria of nephrotoxicity induced by vancomycin were defined by the guideline as an increase in the serum creatinine level of  $\geq 0.5$  mg/dL or a 50% increase the baseline in successive daily readings<sup>(8)</sup>. Vancomycin is highly concentrated in the proximal convoluted tubule cells. It is endocytosed from the proximal tubular lumen into the cell by megalin and dehydropeptidases. In addition, vancomycin is transferred from the peritubular circulation through the basolateral membrane by the organic cation transporter-2 into proximal epithelial cells. The two-way influx of the drug into the renal tubular epithelial cells increases its accumulation<sup>(9)</sup>. Acute tubular necrosis (ATN) is the main pathophysiological mechanism of intracellular damage, which result from oxidative stress. Vancomycin induces

mitochondrial oxidative phosphorylation in proximal convoluted tubule cells and promotes reactive oxygen species (ROS) generation, resulting in lipid peroxidation and caspases chain stimulation to cause cell apoptosis<sup>(10)</sup>. Furthermore, ROS cause damage to DNA and stimulates poly-adenosine diphosphate ribose polymerase 1 (PARP-1), an enzyme implicated in DNA restoration, to consume more ATP for the repair process. PARP-1 overstimulation after great DNA breakdown causes depletion of ATP, and necrosis of the cell occurs<sup>(5)</sup>. Vinpocetine was first produced in Hungary and sold with the generic name Cavinton® in 1978 as a derivative of vincamine alkaloid, which is extracted from the periwinkle plant<sup>(11)</sup>. Vinpocetine acts on a variety of distinct cellular targets, like inhibition of phosphodiesterase type 1 enzyme<sup>(12)</sup> and blocking voltage-sensitive Na<sup>+</sup> channels<sup>(13)</sup>. Additionally, vinpocetine was recorded to be an enhancer of I $\kappa$ B (Inhibitory kappa B) level, which is responsible for inhibiting NF- $\kappa$ B (Nuclear factor kappa B), a transcriptional factor accountable for the expression of different pro-inflammatory mediators, including chemokines and cytokines, by inhibition of I $\kappa$ B kinase, which phosphorylates and degrade I $\kappa$ B molecules<sup>(14)</sup>. Vinpocetine has been used clinically for different conditions; it has been used in Europe and Asia in the prevention and management of some neurological problems such as stroke, dementia, and memory impairment<sup>(11)</sup>. Vinpocetine oral formulation has good GIT absorption, and its peak plasma concentration could be reached within one hour. It has a volume of distribution of  $3.2 \pm 0.9$  L/kg<sup>(15)</sup>. Vinpocetine is metabolized into apovincaminic acid, the main active metabolite<sup>(16)</sup>, and other metabolites within the liver, then undergo renal excretion. Additionally, it has a first-order pharmacokinetic profile with short elimination half-life (1-2) hours and can be given three times a day<sup>(15)</sup>. Vinpocetine has been found to have many

unique effects, notably antagonising injury-induced vascular remodelling, anti-inflammatory, attenuating atherosclerosis due to a diet rich with fat, and reducing pathological cardiac remodelling, according to numerous research <sup>(12)</sup>. Furthermore, previous animal studies have shown that vinpocetine can significantly improve renal injury due to different nephrotoxic agents <sup>(17-19)</sup>. These discoveries may help vinpocetine be repositioned for the prevention or management of relevant diseases in humans <sup>(12)</sup>. Therefore, the purpose of the current study was to look into any potential protective effects of vinpocetine on rat nephrotoxicity brought on by vancomycin. To our knowledge, this study is the first to demonstrate vinpocetine's nephroprotective effect against vancomycin-induced nephrotoxicity.

## **Materials and Methods**

### **Chemicals**

Vancomycin vial (Gulf pharmaceutical industries, UAE), vinpocetine powder (Hangzhou hyper chemical market, China), carboxymethyl cellulose powder (Avonchem, England), ketamine hydrochloride vial 10% (Alfasan, Holland), xylazine vial 10% (Bimeda/Canada), neutral buffered formalin powder (Leica biosystem, Germany), phosphate buffer saline (Chemical point, Germany).

### **Preparation of drugs**

Vancomycin vial (1 gm) dissolved in 20 ml of sterile distilled water according to the manufacturer's instructions. The induction of significant nephrotoxicity in the rat model was achieved by the injection of vancomycin (200mg/kg) twice daily intraperitoneally for fourteen consecutive days <sup>(20)</sup>. Vinpocetine powder suspended in 0.5% carboxymethyl cellulose (CMC) <sup>(21)</sup>. Vinpocetine was given orally, an hour before vancomycin administration, in a dose of 5mg/kg <sup>(18,22)</sup> divided into two equal doses due to its short half-life <sup>(15)</sup>.

### **Animals**

The protocol of the present study was approved by the Institutional Review Board (IRB) of the College of Medicine / Al-Nahrain University (#178 on 23/8/2022). Twenty-four male Wistar albino rats aged 16-20 weeks and weighing 175–285g were kept for two weeks for acclimatization in separated cages under 12 light/dark cycles and controlled temperature with free access to standard food and water.

### **Experimental design**

The rats were divided into three groups, eight in each, as follows: Apparently healthy group: Rats were maintained on standard food and water only. Induction group: Treated with vancomycin (200mg/kg) twice daily intraperitoneally. Vinpocetine group: Treated with vinpocetine (2.5mg/kg) twice daily orally and vancomycin (200mg/kg) twice daily intraperitoneally. All rats were treated for 14 days and sacrificed on the 15th day.

### **Samples collection**

At the end of the experiment, the animals were anaesthetized by intramuscular injection of xylazine (10mg/kg) and ketamine hydrochloride (90mg/kg) combination <sup>(23)</sup>. Then animals were euthanized by decapitation <sup>(24)</sup>, and the blood sample was collected from the trunk <sup>(25)</sup>. Bilateral kidneys were removed quickly. One of the kidneys was placed in a 10% neutral buffered formalin for histopathological examination using the paraffin section technique <sup>(26)</sup>. The other kidney was homogenized in phosphate buffer saline (PBS) to produce 10% renal homogenate <sup>(27,28)</sup>.

### **Outcome measurement**

#### **Biochemical analysis**

The serum level of urea was detected using the colourimetric urease-modified Berthelot method <sup>(29)</sup> and the serum level of creatinine was detected using the colourimetric Jaffe method <sup>(30)</sup> by ready-

made kits (Linear Chemicals, Spain). The serum level of cystatin C and renal tissue levels of MDA, GSH, TNF- $\alpha$ , and NGAL were detected using sandwich Enzyme-Linked Immunosorbent Assay (ELISA) method <sup>(31)</sup>, by sandwich ELISA kits (My BioSource, USA).

**Histopathological analysis**

Histopathological examination was done without knowledge of the treatment protocol. The changes seen were observed in the tubulointerstitial areas of the renal cortex and graded as follows: 0 for normal tissues, 1 for mild (including regions of tubular epithelial cell enlargement, desquamation, necrosis, cast deposition, and interstitial inflammation involving less than 25% of the tubulointerstitial areas of renal cortex), 2 for moderate (similar changes involving 25% but less than 50% of the tubulointerstitial areas of renal cortex), 3 for severe (similar changes involving 50% but less than 75% of the tubulointerstitial areas of renal cortex), 4 for very severe (similar changes involving 75% and more of the tubulointerstitial areas of renal cortex).

**Statistical analysis**

Statistical analysis was performed with the statistical package for social sciences (SPSS-version 26) and Excel 2017. Descriptive statistics for the numerical

data were formulated for all groups and are expressed as the mean and standard error of the mean (Mean  $\pm$  SEM). Numerical data were analyzed using one-way ANOVA with least significant differences (LSD) post hoc test for comparison among groups. Mann-Whitney U test was used for comparison of histopathological scores. The difference was considered significant when p value was below 0.05.

**Results**

**Effects of vinpocetine on serum renal function biomarkers**

(Table 1) demonstrated that the serum levels of urea, creatinine, and cystatin C were significantly higher in the induction group as compared to their corresponding levels in the apparently healthy group. On the other hand, the vinpocetine group showed significantly lower serum levels of urea, creatinine, and cystatin C as compared with their corresponding levels in the induction group. Meanwhile, serum levels of urea and cystatin C were significantly higher in the vinpocetine group than that of the healthy group, while the level of serum creatinine was not significantly different from that of the healthy group.

**Table (1): Effects of vinpocetine on serum renal function biomarkers**

Groups	Urea (mg/dl)	Creatinine (mg/dl)	Cystatin C (ng/ml)
Apparently healthy	28.68 $\pm$ 1.29	0.49 $\pm$ 0.03	269.62 $\pm$ 10.43
Induction	42.28 $\pm$ 1.69*	1.30 $\pm$ 0.21*	553.15 $\pm$ 27.82*
Vinpocetine	36.03 $\pm$ 1.77*#	0.54 $\pm$ 0.02#	347.38 $\pm$ 11.16*#

Data are presented as mean  $\pm$  standard error of mean; \*: means  $p < 0.05$  when compared to apparently healthy group; #: means  $p < 0.05$  when compared to Induction group.

**Effects of vinpocetine on renal tissue oxidative stress biomarkers**

(Table 2) demonstrated that the level of renal tissue malondialdehyde (MDA) was significantly higher, while renal tissue glutathione (GSH) level was significantly lower in the induction group as compared to their corresponding levels in the apparently healthy group. On the other

hand, the vinpocetine group showed significantly lower level of MDA and a significantly higher level of GSH in renal tissue as compared to the induction group. However, the vinpocetine group had a significantly higher level of renal tissue MDA and a significantly lower level of renal tissue GSH as compared to that of the apparently healthy group.

**Table (2): Effects of vinpocetine on renal tissue oxidative stress biomarkers**

Groups	MDA (nmol/ml)	GSH (µg/ml)
Apparently healthy	1.17±0.04	38.14±1.08
Induction	4.04±0.10*	10.83±0.23*
Vinpocetine	2.84±0.09 *#	19.10±0.16 *#

Data are presented as mean ± standard error of mean; MDA: malondialdehyde; GSH; glutathione; \*: means  $p < 0.05$  when compared to apparently healthy group; #: means  $p < 0.05$  when compared to Induction group.

**Effects of vinpocetine on renal tissue levels of inflammatory biomarkers**

Renal tissue levels of inflammatory biomarkers, tumour necrosis factor-alpha (TNF-α) and Neutrophil gelatinase-associated lipocalin (NGAL) were significantly higher in the induction group than in the healthy group. More interestingly, the vinpocetine group showed significantly lower renal levels of

inflammatory biomarkers TNF-α and NGAL if compared with the vancomycin group. However, renal levels of inflammatory biomarkers were significantly higher in the vinpocetine group as compared with the healthy group (Table 3)

**Table (3): Effects of vinpocetine on renal tissue inflammatory biomarkers**

Groups	TNF-α (pg/ml)	NGAL (pg/ml)
Apparently healthy	870.43 ± 50.93	254.02±12.41
Induction	1761.96±46.4 *	1269.73±62.24*
Vinpocetine	1249.67±92.16*#	567.34±19.45*#

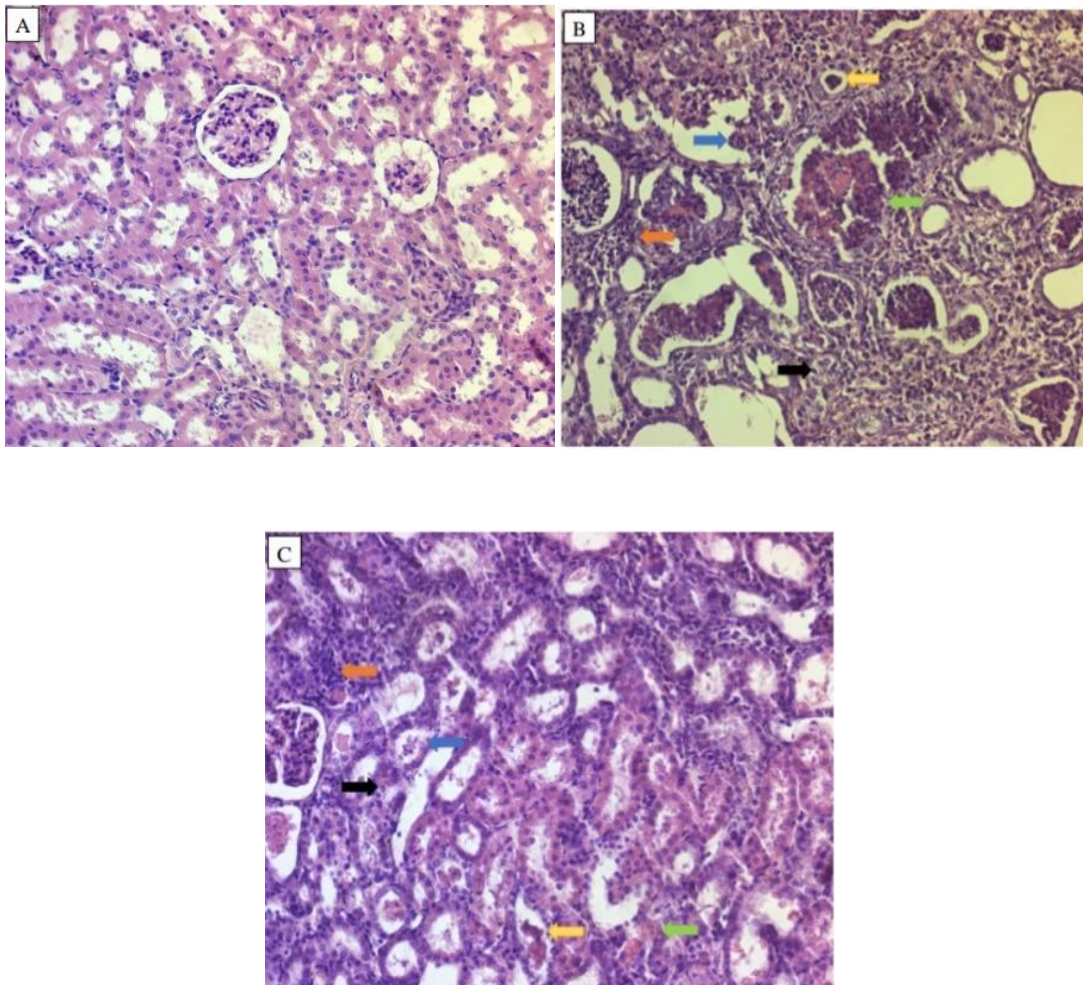
Data are presented as mean ± standard error of mean; TNF: tumour necrosis factor-alpha; NGAL: Neutrophil gelatinase-associated lipocalin; \*: means  $p < 0.05$  when compared to apparently healthy group; #: means  $p < 0.05$  when compared to Induction group.



### **Histopathological analysis**

Kidney tissue of the induction group demonstrated significant damage as compared to the apparently healthy group with tubular epithelial cell enlargement, desquamation, interstitial inflammation, hyaline cast, necrosis, and interstitial inflammation (Figure 3B). This group had 12.5% severe and 87.5% highly severe histopathological changes when being

compared to normal kidney tissue. The vinpocetine group showed a significant reduction in kidney injury as compared to the induction group (Figure 3C). Regarding histopathological changes in comparison to those of normal kidney tissue, the vinpocetine group showed 50% moderate and 50% severe changes.



**Figure (1): Histopathological sections of rats' kidney [H&E, 20X], (A): represent the histopathological findings of normal group, (B): represent the histopathological findings of induction group, (C): represent the histopathological findings of vinpocetine group, orange arrow: interstitial inflammation, black arrow: tubular epithelial cell enlargement, blue arrow: desquamation, green arrow: necrosis, yellow arrow: hyaline cast deposition.**

## Discussion

The present study showed the dose of 200mg/kg/twice daily of vancomycin for 14 days intraperitoneally could induce an animal model of nephrotoxicity by a dramatic increase in the serum levels of urea and creatinine as compared with the healthy group, which is consistent with a previous study<sup>(20)</sup>. Furthermore, the better and more sensitive biomarker for renal function, serum cystatin C level<sup>(32)</sup>, was highly elevated in the induction group in accordance with a previous study<sup>(33)</sup>. Deterioration of renal function biomarkers may be attributed to oxidative stress that causes severe damage to proximal convoluted cells associated with acute tubular necrosis<sup>(9)</sup>. Subsequently, loss of the ability of these cells to reabsorb sodium and water stimulates macula densa to trigger tubuloglomerular feedback by adenosine action, which cause vasoconstriction of the afferent arteriole resulting in decreased GFR<sup>(34)</sup>. The most sensitive compounds to ROS are lipids. During lipid peroxidation, MDA is generated by ROS as the end product<sup>(35)</sup>. In agreement with other studies, the renal tissue MDA levels increased due to vancomycin nephrotoxicity<sup>(20,35)</sup>. GSH is generally an accepted line of defence against oxidative kidney injury<sup>(36)</sup>. Exhaustion of renal tissue GSH is one of the main factors which permit lipid peroxidation. Thus, the amount of intracellular GSH is considered a determinant key of the extent of vancomycin nephrotoxicity<sup>(37)</sup>. According to previous studies, vancomycin administration decreased renal tissue GSH levels<sup>(38-40)</sup>. The result of the present study was consistent with these previous findings; the lowest levels of renal tissue GSH were observed in the induction group. Also, renal tissue levels of TNF- $\alpha$  and NGAL were significantly higher in the induction group in line with previous studies<sup>(36,41)</sup> and could be attributed to the activation of NF- $\kappa$ B by high ROS<sup>(42)</sup>. Furthermore, necrotic cells liberate danger-associated molecular patterns (DAMPs) from different compartments

inside the cell that cause more inflammation<sup>(43)</sup> by binding with pattern recognition receptors such as toll-like receptors (TLR). This binding will initiate the signalling pathway of TLRs and protein kinases activation, then nuclear factors activation, followed by gene expression and production of inflammatory cytokines<sup>(44)</sup>. Histologically, the induction group showed marked renal tissue damage compared to the healthy group, consistent with a previous study<sup>(40)</sup>. On the other hand, co-administration of vinpocetine with vancomycin improved renal function as reflected by a significant reduction in serum levels of urea, creatinine, and cystatin C when compared to the vancomycin group, in accordance with a previous study<sup>(45)</sup>. More interesting, a previous study by Fattori *et al.* showed that vinpocetine improves renal function deterioration due to diclofenac-induced nephrotoxicity in mice model through regulation of oxidative stress, NF- $\kappa$ B pathway, apoptosis, and inflammatory cytokine productions<sup>(17)</sup>. The Vinpocetine group showed a significantly lower renal tissue level of MDA and higher renal GSH, in agreement with a previous study<sup>(46)</sup>. The antioxidant role of vinpocetine can probably be attributed to the activation of the Nrf-2-mediated antioxidant pathway<sup>(47,48)</sup>. The vinpocetine group showed a significant reduction in inflammatory biomarkers in accordance with previous studies<sup>(19,49)</sup>. The anti-inflammatory role of vinpocetine can probably be attributed to two reasons, the first is due to the effect of vinpocetine as a PDE-I inhibitor via inhibition of NF- $\kappa$ B activation through an increased intracellular level of cGMP and cAMP<sup>(50)</sup>, and the second reason is expected to suppress the process of monocyte adhesion and chemotaxis<sup>(11)</sup>. Histopathological examination showed a significant reduction in renal tissue damage in vinpocetine group. These outcomes go with the recent study done by Song *et al.* showed that vinpocetine reduces renal tissue damage due to



cisplatin-induced nephrotoxicity in rats by activating the Nrf2 pathway and inhibiting the NF- $\kappa$ B pathway<sup>(18)</sup>.

### **Conclusion**

According to this research's findings, the protective effect of vinpocetine against vancomycin-induced nephrotoxicity could be concluded. This effect is attributed to the antioxidant and anti-inflammatory properties of vinpocetine.

### **Acknowledgment**

The presented data were abstracted from the M.Sc. thesis submitted to the Department of Pharmacology, College of Medicine, Al-Nahrain University. The authors thank Al-Nahrain University for supporting the project.

**Conflict of interest:** No conflict of interest associated with this work.

**Funding:** Nil.

### **References**

1. Al-Naimi MS, Rasheed HA, Hussien NR, Al-Kuraishy HM, Al-Gareeb AI. Nephrotoxicity: Role and significance of renal biomarkers in the early detection of acute renal injury. *J Adv Pharm Technol Res.* 2019;10(3):95.
2. Abd AH, Qasim BJ, Sahib HB, Raheem H. Nephroprotective effect of vitamin E and *Origanum vulgare* extracts against vancomycin induced nephrotoxicity in rats. *Int J Pharmaceut Sci Rev Res.* 2016;36:89–96.
3. Xiang X, Guo C, Tang C, Cai J, Dong Z. Epigenetic regulation in kidney toxicity: insights from cisplatin nephrotoxicity. In: *Seminars in nephrology.* Elsevier; 2019. p. 152–8.
4. Gray MP, Barreto EF, Schreier DJ, et al. Consensus obtained for the nephrotoxic potential of 167 drugs in

adult critically ill patients using a modified Delphi method. *Drug Saf.* 2022;45(4):389–98.

5. Pais GM, Liu J, Zepcan S, et al. Vancomycin-induced kidney injury: animal models of toxicodynamics, mechanisms of injury, human translation, and potential strategies for prevention. *Pharmacotherapy: The Journal of Human Pharmacology and Drug Therapy.* 2020;40(5):438–54.

6. Brown NM, Goodman AL, Horner C, Jenkins A, Brown EM. Treatment of methicillin-resistant *Staphylococcus aureus* (MRSA): updated guidelines from the UK. *JAC Antimicrob Resist.* 2021;3(1):dlaa114.

7. Jorgensen SCJ, Murray KP, Lagnf AM, et al. A multicenter evaluation of vancomycin-associated acute kidney injury in hospitalized patients with acute bacterial skin and skin structure infections. *Infect Dis Ther.* 2020;9:89–106.

8. Rybak M, Lomaestro B, Rotschafer JC, et al. Therapeutic monitoring of vancomycin in adult patients: A consensus review of the American Society of Health-System Pharmacists, the Infectious Diseases Society of America, and the Society of Infectious Diseases Pharmacists. *American Journal of Health-System Pharmacy.* 2009 Jan 1;66(1):82–98. Available from: <https://doi.org/10.2146/ajhp080434>

9. Kan W-C, Chen Y-C, Wu V-C, Shiao C-C. Vancomycin-Associated Acute Kidney Injury: A Narrative Review from Pathophysiology to Clinical Application. *Int J Mol Sci.* 2022;23(4):2052.

10. Kwiatkowska E, Domański L, Dziedziejko V, Kajdy A, Stefańska K, Kwiatkowski S. The mechanism of drug nephrotoxicity and the methods for

preventing kidney damage. *Int J Mol Sci.* 2021;22(11):6109.

11. Zhang C, Yan C. Updates of recent vinpocetine research in treating cardiovascular diseases. *J Cell Immunol.* 2020;2(5):211.

12. Zhang Y, Li J, Yan C. An update on vinpocetine: new discoveries and clinical implications. *Eur J Pharmacol.* 2018;819:30–4.

13. Gutiérrez-Farfán I, Reyes-Legorreta C, Solís-Olguín M, Alatorre-Miguel E, Verduzco-Mendoza A, Durand-Rivera A. Evaluation of vinpocetine as a therapy in patients with sensorineural hearing loss: A phase II, open-label, single-center study. *J Pharmacol Sci.* 2021;145(4):313–8.

14. Jeon K-I, Xu X, Aizawa T, et al. Vinpocetine inhibits NF- $\kappa$ B-dependent inflammation via an IKK-dependent but PDE-independent mechanism. *Proceedings of the National Academy of Sciences.* 2010;107(21):9795–800.

15. Zigam QA, Al-Zubaidy AA, Sami Z, Raheem AK. Vinpocetine attenuates sepsis-induced cardiotoxicity in mice model. *teikyo medical journal.* 2022;45(2):5917–28.

16. Wang M, Wang L, Sun J, Zhang L, Zhao L, Xiong Z. Simultaneous determination of vinpocetine and its major active metabolite apovincaminic acid in rats by UPLC-MS/MS and its application to the brain tissue distribution study. *J Chromatogr Sci.* 2018;56(3):225–32.

17. Fattori V, Borghi SM, Guazelli CFS, et al. Vinpocetine reduces diclofenac-induced acute kidney injury through inhibition of oxidative stress, apoptosis, cytokine production, and NF- $\kappa$ B activation in mice. *Pharmacol Res.* 2017;120:10–22.

18. Song W, Yin W, Ding L, et al. Vinpocetine reduces cisplatin-induced acute kidney injury through inhibition of

NF- $\kappa$ B pathway and activation of Nrf2/ARE pathway in rats. *Int Urol Nephrol.* 2020;52(7):1389–401.

19. Al-Kuraishy HM, Al-Gareeb AI, Al-Nami MS. Vinpocetine improves oxidative stress and pro-inflammatory mediators in acute kidney injury. *Int J Prev Med.* 2019;10.

20. Uhuo EN, Egba SI, Nwuke PN, Odinamadu H. Renoprotective effects of *Adansonia digitata* leaf extract on renal function and histopathological changes in vancomycin-induced nephrotoxicity in Wistar rats. *Comp Clin Path.* 2022;31(2):229–42.

21. Habib SA, Abdelrahman RS, Abdel Rahim M, Suddek GM. Anti-apoptotic effect of vinpocetine on cisplatin-induced hepatotoxicity in mice: The role of Annexin- V, Caspase- 3, and Bax. *J Biochem Mol Toxicol.* 2020;34(10):e22555.

22. Ahmed D, Jasim GA. Renoprotective effect of vinpocetine and cilostazol on glycerol induced renal injury in male rats. *Al Mustansiriyah Journal of Pharmaceutical Sciences.* 2022;22(4):1–8.

23. Dalaklioglu S, Tekcan M, Gungor NE, et al. Role of the poly (ADP-ribose) polymerase activity in vancomycin-induced renal injury. *Toxicol Lett.* 2010;192(2):91–6.

24. Underwood W, Anthony R. AVMA guidelines for the euthanasia of animals: 2020 edition. Retrieved on March. 2020;2013(30):2020–1.

25. Pena-Leon V, Folgueira C, Barja-Fernández S, et al. Prolonged breastfeeding protects from obesity by hypothalamic action of hepatic FGF21. *Nat Metab.* 2022;4(7):901–17.

26. Mescher A. L. *Histology & Its Methods of Study.* In: Junqueira's Basic Histology Text and Atlas. 14th edition.

- New York: McGraw-Hill Education; 2016. p. 1–15.
27. Al-Saedi HF, Al-Zubaidy AA, Khattab YI. The possible effects of montelukast against doxorubicin-induced nephrotoxicity in rabbits. *Int J Adv Res.* 2014;2(11):723–9.
28. Noori HY, Abd AH. Protective effect of Melatonin, Rosuvastatin and their combination against Amikacin induced nephrotoxicity in rats. *Ann Trop Med Public Health.* 2019;22:98–107.
29. Fawcett J, Scott J. A rapid and precise method for the determination of urea. *J Clin Pathol.* 1960;13(2):156–9.
30. Heinegård D, Tiderström G. Determination of serum creatinine by a direct colorimetric method. *Clinica chimica acta.* 1973;43(3):305–10.
31. Aydin S. A short history, principles, and types of ELISA, and our laboratory experience with peptide/protein analyses using ELISA. *Peptides (NY).* 2015;72:4–15.
32. Murty MSN, Sharma UK, Pandey VB, Kankare SB. Serum cystatin C as a marker of renal function in detection of early acute kidney injury. *Indian J Nephrol.* 2013;23(3):180.
33. Khalaf MM, Hassan SM, Sayed AM, Abo-Youssef AM. Carvacrol mitigates vancomycin-induced nephrotoxicity via regulation of I $\kappa$ B $\alpha$ /p38MAPK and Keap1/Nrf2 signaling pathways: an experimental study with in silico evidence. *Eur Rev Med Pharmacol Sci.* 2022;26(23):8738–55.
34. Ho KM, Morgan DJR. The proximal tubule as the pathogenic and therapeutic target in acute kidney injury. *Nephron.* 2022;146(5):494–502.
35. Sadeghi H, Karimizadeh E, Sadeghi H, et al. Protective effects of hydroalcoholic extract of *rosa canina* fruit on vancomycin-induced nephrotoxicity in rats. *J Toxicol.* 2021;2021:5525714.
36. Kandemir FM, Yildirim S, Kucukler S, Caglayan C, Mahamadu A, Dortbudak MB. Therapeutic efficacy of zingerone against vancomycin-induced oxidative stress, inflammation, apoptosis and aquaporin 1 permeability in rat kidney. *Biomedicine & Pharmacotherapy.* 2018;105:981–91.
37. Ahmida MHS. Protective role of curcumin in nephrotoxic oxidative damage induced by vancomycin in rats. *Experimental and Toxicologic Pathology.* 2012;64(3):149–53.
38. Basarslan F, Yilmaz N, Ates S, et al. Protective effects of thymoquinone on vancomycin-induced nephrotoxicity in rats. *Hum Exp Toxicol.* 2012;31(7):726–33.
39. Guzel S, Sahinogullari ZU, Canacankatan N, Antmen SE, Kibar D, Coskun Yilmaz B. Potential renoprotective effects of silymarin against vancomycin-induced nephrotoxicity in rats. *Drug Chem Toxicol.* 2020;43(6):630–6.
40. Uckun Z, Guzel S, Canacankatan N, Yalaza C, Kibar D, Coskun Yilmaz B. Potential protective effects of naringenin against vancomycin-induced nephrotoxicity via reduction on apoptotic and oxidative stress markers in rats. *Drug Chem Toxicol.* 2020;43(1):104–11.
41. Yu P, Luo J, Song H, et al. N-acetylcysteine Ameliorates Vancomycin-induced Nephrotoxicity by Inhibiting Oxidative Stress and Apoptosis in the in vivo and in vitro Models. *Int J Med Sci.* 2022;19(4):740.
42. Alsawaf S, Alnuaimi F, Afzal S, et al. Plant Flavonoids on Oxidative Stress-Mediated Kidney Inflammation. *Biology (Basel).* 2022;11(12):1717.

43. Hosohata K. Role of oxidative stress in drug-induced kidney injury. *Int J Mol Sci.* 2016;17(11):1826.
44. Kusiak A, Brady G. Bifurcation of signalling in human innate immune pathways to NF- $\kappa$ B and IRF family activation. *Biochem Pharmacol.* 2022;115246.
45. Wadie W, Abdel-Razek NS, Salem HA. Phosphodiesterase (1, 3 & 5) inhibitors attenuate diclofenac-induced acute kidney toxicity in rats. *Life Sci.* 2021;277:119506.
46. Azouz AA, Hersi F, Ali FEM, Hussein Elkelawy AMM, Omar HA. Renoprotective effect of vinpocetine against ischemia/reperfusion injury: Modulation of NADPH oxidase/Nrf2, IKK $\beta$ /NF- $\kappa$ B p65, and cleaved caspase-3 expressions. *J Biochem Mol Toxicol.* 2022;36(7):e23046.
47. Abdelzaher WY, Ahmed SM, Welson NN, Marraiki N, Batiha GE-S, Kamel MY. Vinpocetine ameliorates L-arginine induced acute pancreatitis via Sirt1/Nrf2/TNF pathway and inhibition of oxidative stress, inflammation, and apoptosis. *Biomedicine & Pharmacotherapy.* 2021;133:110976.
48. Abdelmageed N, Twafik WA-A, Seddek A, Morad SA-RF. Vinpocetine-based therapy is an attractive strategy against oxidative stress-induced hepatotoxicity in vitro by targeting Nrf2/HO-1 pathway. *EXCLI J.* 2021;20:550.
49. Abbas WJ, Altemimi ML, Al-Mudhafar RH, Zigam QA, Hadi NR. Effects of vinpocetine on renal ischemia reperfusion injury in a male rat model. *Systematic Reviews in Pharmacy.* 2020;11(12):2380–9.
50. He Y, Huang Y, Mai C, et al. The immunomodulatory role of PDEs inhibitors in immune cells: Therapeutic implication in rheumatoid arthritis. *Pharmacol Res.* 2020;161:105134