

The study of histopathological changes for the eye of *Ruttus norvegicus* L. Poured by hydatid cyst fluid

Zahraa Sadoon Hadi

Department of Biology/ College of Education/ Thi-Qar University

Mohammed Hasan Fleih

Technical institute in nassyria/ community health department

Hameed Naeem Mosa

FIBMS /Department of Pathology/ College of Medicine/ Thi-Qar University

Summary

The incidence of hydatid cyst formation in the eye is extremely low in all hydatid cysts so that done this study for getting information about histopathological changes in eye of *Ruttusnorvegicus* L. that was included group poured with hydatid cyst fluid and control group poured with normal saline, both groups were examined eyes sections for observed histological changes after passage limited periods (1 day,3 days,6 days,10 days). Histopathological examination was not discovered found histological changes in all their eyes, histological layers such as lens, retina, vitreous, conjunctiva and lacrimal gland were normal. Hydatid cyst was not seen in the eye or round tissues of examined animals. After 10 days, necropsy of a specimen for anyone of *Ruttusnorvegicus* L. that poured by hydatid cyst fluid , observed found the minimum hydatid cyst in liver.

Keywords: histopathological changes, hydatid cyst, *Ruttus norvegicus*

الخلاصة

تكون الأكياس العدرية في العيون نسبة قليلة مقارنة مع الأكياس العدرية التي تتكون في أماكن مختلفة من الجسم، لذلك أجريت الدراسة الحالية لمعرفة التغيرات النسيجية المرضية في عيون الحيوانات المختبرية التي سكب بها سائل الأكياس العدرية. تضمنت الدراسة الحالية مجموعة من الجرذان المختبرية سكب السائل العدري في عيون هذه الحيوانات وتمت المقارنة مع مجموعة من الجرذان المختبرية (مجموعة سيطرة) سكب في عيون هذه المجموعة المحلول الملحي الاعتيادي. تم فحص المقاطع النسيجية لعيون المجموعتين لملاحظة التغيرات المرضية بعد مرور فترة زمنية محددة (1يوم,3 يوم, 6 يوم, 10 يوم). لم يلاحظ وجود أي تغيرات نسيجية في المقاطع المدروسة حيث وجد التركيب النسيجي للعين بشكل طبيعي مثل العدسة وشبكية العين والزجاجي وملتحمة العين والغدة الدمعية دون حدوث تغيرات نسيجية, كما لوحظ عدم تكون الأكياس العدرية في العيون أو المناطق المحيطة بها ضمن انسجة الحيوانات المفحوصة. بعد الفترة 10 يوم تم تشريح الحيوانات المختبرية (عينة الدراسة) التي سكب السائل العدري في عيون تلك الحيوانات وجد تكون أكياس عدرية صغيرة في أكبادها.

Introduction

Cystic echinococcosis/Hydatidosis , the most common form of the disease in human and domesticated animals, is caused by *Echinococcus granulosus* ,Because the larvae of this organism develop as discrete single cysts, it is the least severe and most treatable form (Dalimi *et al.*, 2002;Craig *et al.*, 2003). Nevertheless, large or multiple cysts may cause irreversible damage to organs, and the rupture or puncture of the cyst can seed multiple organs with larvae or cause anaphylactic reactions (Deutz *et al.*, 2000;Yang *et al.* ,2005). In addition, The disease has a considerable economic and public health problem in many regions of the world and its global distribution is partly due to the ability of the parasite to adapt to a wide variety of domestic and wild intermediate and definitive hosts (Al- Shammary , 2002 ; Eckert and Deplazes ,2004 ; Al-Ghezi, 2008).

Humans act as intermediate hosts for *Echinococcus* spp., and are infected when they ingest parasite eggs from the definitive host, the eggs may be eaten in foods such as vegetables, or drunk contaminated water. They can also touch contaminated soil and vegetation. Uninfected pets may carry the eggs on their fur if they contact the feces of infected definitive hosts (Morar and Feldman, 2003; Thompson and Macmanus, 2001). The symptoms of echinococcosis depend on the size, number and the location of the metacestodes. Until the cysts become large enough to damage adjacent tissues and organs, they are usually asymptomatic (Forzan *et al.*, 2006). Cysts can remain asymptomatic for many years. They are usually well tolerated until they cause pressure on surrounding tissues. The symptoms resemble those of a slowly growing tumor (Sayek and Onat, 2001). Although most people have only one cyst, multiple cysts can be found. Approximately 60-70% of *E. granulosus* cysts occur in the liver and 20-25% in the lungs. The remaining cysts can be found almost anywhere in the body including the bones, eye, kidneys, spleen, muscles, nerve system, etc. (Ramos *et al.*, 2001; Arbabi and Hooshyar, 2006).

Echinococcosis is not transmitted from person to person. Humans can transmit the infection to the definitive hosts if affected tissues are eaten, but this does not occur in most societies due to cultural practices (Torgerson and Heath, 2003; Anadol *et al.*, 2001).

The growth and development of the hydatid cyst in laboratory animals after the injection of components of the hydatid cyst fertility derived from the natural host infection called secondary hydatid cyst and occurs when a cyst leaks or ruptures then dissemination is seen mainly in the abdominal cavity (Eckert *et al.*, 2001; Ammori *et al.*, 2002). The mice and rats more mammals appropriate to monitor the development and growth of the secondary hydatid cysts, also found that hydatid cyst in rat grow faster than the growth in the rest of the laboratory animals was and noted that the percentage of growth secondary hydatid cyst in rat infected with protoscolices from *Echinococcus granulosus*, 90% (Diker *et al.*, 2008).

The Histopathological changes for any organ depends on the nature of the user itself and the growth and development of the hydatid cyst, which is determined by interaction of immune system of the host (Al-Sultan and Al-Kanary, 2000; Aygun *et al.*, 2001; Abbu, 2005), which inhibits the growth of larva, or overcome the growth of parasitic larvae to inflammation reaction of infected tissue for hydatid cyst formation or exposed larvae to necrosis and death as a result of overcoming the immune reaction of the host on growth and development of parasitic larvae (Kim *et al.*, 2001; Campos-Bueno *et al.*, 2000).

Considering the fact that hydatid cyst can be ruptured easily so that protoscolices can be spread all over the operating room including surgeons face and cloth, the personnel thought that the fluid of the cyst can cause ocular hydatid cyst in them is a main problem in surgery rooms. It can be a source of anxiety to the personal of operating room (Zaidi, 1999). It must be known that the risk of eye splash injury in surgery is much greater than that perceived by most surgeons and trainees. Routine eye protection should be mandatory for all personnel in the operating theatre, in particular for emergency and prolonged elective procedures (Jimenez-Mejios *et al.*, 2000; Aldemir *et al.*, 2004).

In this study, *Rattus norvegicus* L. were infected by spreading protoscoleces suspension into the rat eyes for the study Histopathological changes in infected eye tissue and possibility formed hydatid cyst in their eyes.

Material and methods

Hydatid cyst samples were collected from individuals infected with hydatidosis, confirmed by surgery in the Al-Hussain Teaching Hospital, Thi-Qar, Iraq. Samples were transferred to laboratory of Biology / College of Education. The hydatid cyst fluid was aspirated and examined for presence of protoscolices. The viability of protoscolices was determined by put 0.02 ml of 0.1% eosin stain mixed with same volume of protoscolices suspension on the clean slide and examined under a light microscope. The live protoscolices take bright green color while the dead protoscolices take red color (Smyth and Barrett, 1980).

The concentration of protoscolices was 200 protoscolices /0.2 ml in hydatid cyst fluid. *Rattus norvegicus* L. maintained in the animal house of College of Education were used for the study. *Rattus norvegicus* L. were divided into two groups (every group was included twelve rats) divided to sub group according to time period that examined rats:

(sub group A): include 3 rat examined after 1 day

(sub group B): include 3 rat examined after 3 day

(sub group C): include 3 rat examined after 6 day

(sub group D): include 3 rat examined after 10 day

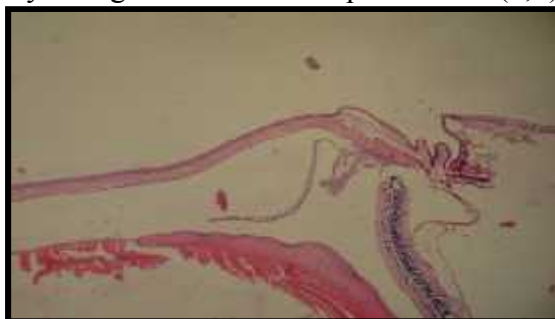first group was poured with normal saline (0.2ml) on eye (control group) and second groups were poured with hydatid cyst fluid (0.2 ml) on eye (study group).

After one days, three days, six days and ten days, rat were anesthetize by diethyl-ether and their eyes were enucleated by surgical scissors and saved of formaline 10%. All specimens were transferred to histological section unit in laboratory of Al-Hussain teaching hospital. The specimens were stained by used hematoxyline-eosin stain for study histopathology changes in eyes of *Rattus norvegicus* L.

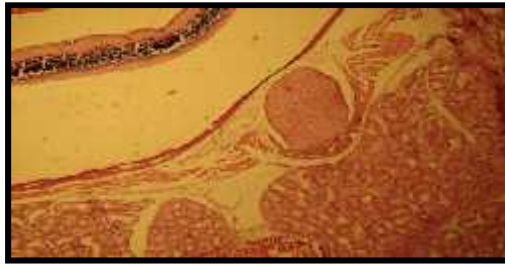
Results

The current study showed at poured of hydatid cyst fluid in the eyes of rats and after the specific time periods, no seen hydatid cyst in the eye or around tissues of examined animals and no notice any histopathological change in their eyes, histological layers such as lens, retina, vitreous, conjunctiva and lacrimal gland were normal. As in picture No. (1,2,3,4) but seen minimum hydatid cyst in liver for anyone second group (subgroup D). As in picture No. (7,8).

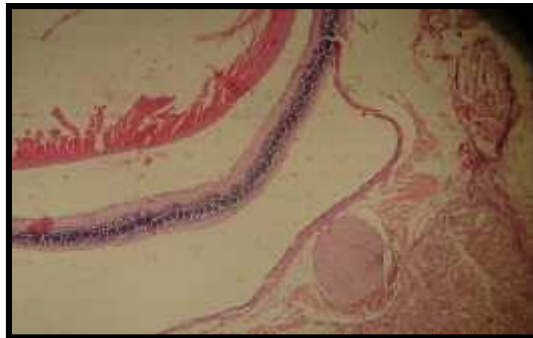
Also conducted in the present study poured the eyes of rates (control group) with normal saline solution after specific time periods and the study of histological changes observed no found any hydatid cyst in the eye or around tissues of examined animals and non-appearance any change in tissue. As in picture No. (5,6).



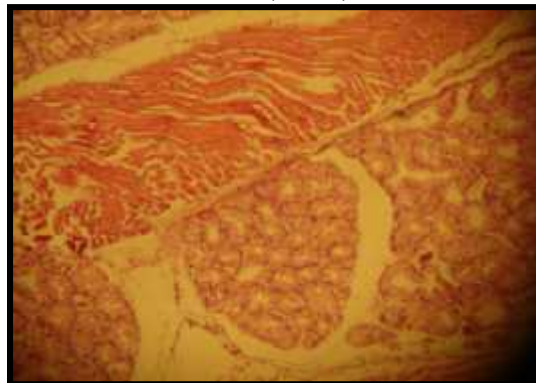
Picture(1) show lens, retina, vitreous and conjunctiva normal without present histopathological changes in eye *Rattus norvegicus* L. 40X (H&E)



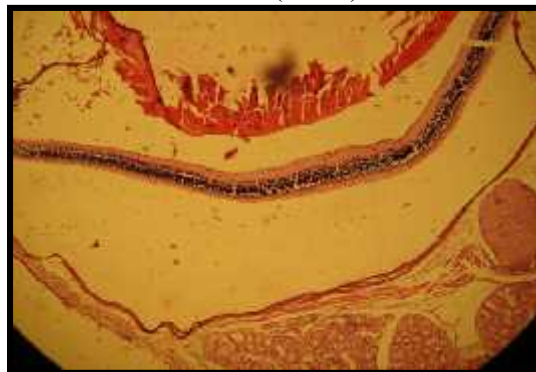Picture(2) show lacrimal gland and vitreous normal in eye of *Ruttusnorvegicus* L.
40X (H&E)



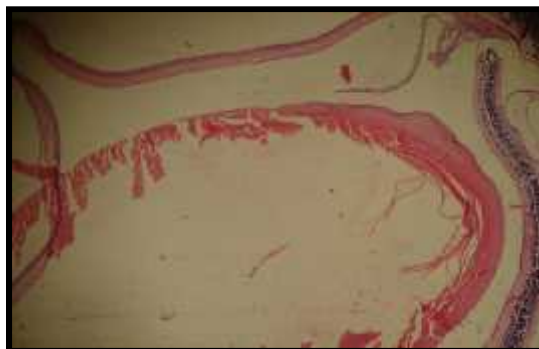
Picture(3) show no found histological changes in eye of *Ruttusnorvegicus* L.
40X (H&E)



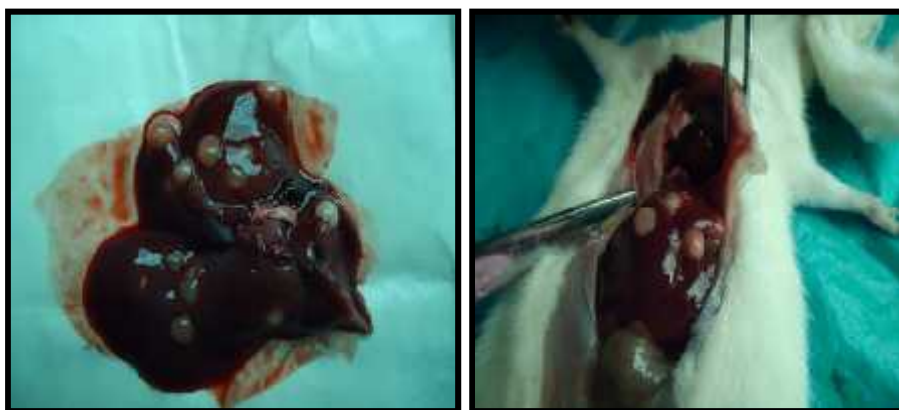Picture (4) show lacrimal gland normal of *Ruttusnorvegicus* L.
100X (H&E)



Picture(5) show vitreous and lacrimal gland normal in control group of
Ruttusnorvegicus L. 40X (H&E)



Picture(6) show lens, retina, vitreous and conjunctiva normal in control group of *Rattus norvegicus* L. 40X (H&E)



Picture(7,8) Show formation hydatid cyst in liver of *Rattus norvegicus* L.

Discussion

Inexperience of the surgeons about the fragility of the cystic tissues and application of blunt dissection instead of sharp dissection may be the causes of eye splash injuries with echinococcal fluid (Sharma and Gupta ,2000). The rupture of a hydatid cyst is well known in surgical practice. It can occur spontaneously (Bedirli *et al.*, 2002), as a result of trauma or surgery (Eval *et al.*, 1991). Echinococcal fluid splash into the eye as a result of iatrogenic hydatid cyst rupture was not reported so far (Pedrosa *et al.*, 2000).

Anaphylactic reactions or allergic conjunctivitis can be seen, if the surgeon already exposed to hydatid fluid via the eye is sensitive to hydatid fluid previously. However, anaphylactic reactions due to echinococcal fluid have not been reported so far (Eval *et al.*, 1991).

The infection human with eye hydatid cyst considerable few and rare therefore also studies about its were few .Gomez *et al.*,(1988) reviewed 35 cases of orbital hydatid cyst,which represented 5% of orbital surgical cases .Slowly progressive unilateral exophthalmoses ,with or without pain ,was the most frequent clinical manifestation. Mousavi and Tappeh (2010) used different concentrations of protoscoleces were prepared and injected into the eyes of 60 mice .After 20 weeks ,10 of 60 mice of this group died .The remaining 50 mice were examined by a surgeon under the anesthesia .there weren't any symptoms of hydatid cyst in the eyes and around it.

There is study includes two different surgeons exposed themselves to iatrogenic splashing of echinococcal fluid into their eyes intraoperatively in Dicle University Faculty of Medicine, General Surgery Department in 1996 and 2002 (Aldemir *et al.*, 2004), this study agree with the current study that may not be any infection to the eye upon the arrival of the hydatid cyst fluid, as a result of splashing echinococcal fluid into the eye, the scolices (or daughter hydatids) can cause dacryocystitis or ductal echinococcosis if it is located into the ductus nasolacrimalis and although their entrance to oropharyngeal cavity and consequently to gastrointestinal system is possible, any clinical experience about it has not been reported so far, this agree with the present study, that may be the arrival of the protoscolices to the liver and are formed hydatid cyst in them.

Reference

- * **Abbu, O.A.N. (2005).** Pathological changes in liver, spleen and lymphnodes in mice treated with hydatid cyst fluid of human origin and its toxin fractions. J. Educ. Sci. (In press).
- * **Aldemir ,M.; Çaça, İ.; Akahn, Ş. ; Ali, S. A. and Kaya, Z. (2004).** The eye splash injuries of Echinococcal fluid during surgery of the peritoneal Echinococcosis :our Experiences due to two cases .Eur J Gen Med 2004; 1(3): 43-44.
- * **Al-Ghezi, Z. S. (2008).** Epidemiology and diagnosis of haydatid disease in human and ruminant animals in Thi-Qar governorate. M .Sc .Thesis .Coll .Eud. Univ. Thi-Qar .Iraq.
- * **Al-Shammery, S.Q.J. (2002).** Prevalence of *Echinococcus granulosus* in stray dogs and larval stage in human in Baghdad province. M.S.C. Thesis. Coll. Vet. Med. Univ. Baghdad.
- * **Al-Sultan, I. I.; and Al-Kanary, E. R. (2000)** Experimental study on some protective methods against hydatid cyst infection in mice. The Iraqi. J. Vet. Med. 24(2): 179-195.
- * **Ammori , B . J .; Jenkins , B . L .; Lim , P . C .; Prasad , K . R .; Pollard,S. C .and Lodge ,J.P.(2002).** Surgical strategy for cystic diseases of the liver in awestern hepatobiliary center. World.J.Surg.,26 : 462 -69.
- * **Anadol , D . ; Ozcelik , U . ; Kiper , N . and Gocmen , A . (2001) .** Treatment of Hydatid Disease .Paediatric Drugs .3(2):123-35.
- * **Arbabi , M . and Hooshyar , H . (2006).** Survey of Echinococcosis and Hydatidosis in Kashan Region Central Iran.Iranian ,J. Publ.Health, 35:75-81.
- * **Aygun , E . ; Sahin , M . and Odev , K .(2001) .**The manangement of liver hydatid cysts by percutaneous drainage .Can . J . Surg . , 44:203-09.
- * **Bedirli ,A . ; Sakrak ,O . ;Sozuer, E.M.; Kerek, M. and Ince, O. (2002).** Surgical management ofspontaneous intrabiliary rupture of hydatid liver cysts. Surg Today ;32:594-7.
- * **Campos –Bueno , A . ;Lepez–Abente , G . and Andres – Cereadillo , A . M . (2000) .** Risk factors for *Echinococcus granulosus* infection a case control study . Am.j .Trop . Med . Hyg ., 62:329-334
- * **Craig , P . S . ; Rogan , M . T . and Campos-Ponce ,M . (2003) ."** *Echinococcus* :disease ,detection,and transmission ".Parasitology .,127:S5-S20.
- * **Dalimi , A . ; Motamedi , G . and Hosseini , M . (2002).** Echinococcosis in west Iran. Parasitol. 161-67.
- * **Deutz , A . ; Fuchs , K . ; Auer, H . and Nomotny , N . (2000) .** Echinococcosis An emerging disease in farmers. New.Eng.J.Med.343:783-739.

- * **Diker ,A. I. ; Tinar, R. and Senlik , B. (2008).** Infectivity of *Echinococcus granulosus* protoscolices under different conditions of temperature and humidity . J.Helminth , 82:297-300.
- * **Eckert , J . ; Deplazes , P . and Craig , P. (2001) .** Echinococcosis in animals : clinical aspects ,diagnosis and treatment .In:Eckert ,J.Gemmell, M.Meslin ,F.X.Pawlowski, Z.ed.s.WHO/OIE manual on echinococcosis in humans and animas :apublic health problem of global concern . paris :W.O.A.H. 72-99.
- * **Eckert , J . and Deplazes , P . (2004) .**Biological , Epidemiological and clinical Aspects of Echinococcosis ,a zoonosis of increasing concern . Clin. Microbiol .Rev. 17(1):107-135.
- * **Eval ,I. ; Zveibil, F. And Stamler, B. (1991).** Anaphylatic shock due to rupture of a hepatic hydatid cyst into a pericystic blood vessel following blunt abdominal trauma. J Ped Surg ;26:217-8.
- * **Forzan , M . ; Mortazavi , S . M . J . and Motamedi , M . (2006).**Hydatid Disease of Bone .Acta.Medica.Iranica. Vol.44.No.6.
- * **Moralis, G. A. ; Croxatto,J.O. and Ebner,C.R.(1988).**Hydatid cyst of the orbit ,A review of 35 cases .Ophthalmology ,95(8): 1027-1032.
- * **Jimenez–Mejios , M . E. ; Alarcon–Cruz, J.C.; Marquez–Rivas, F.J.; Palamino–Nicas, J.; Montero ,J.M. and Pachon ,J. (2000).**Orbital hydatid cyst: treatment and prevention of recurrences with albendazole plus praziquantel. *J Infect.*; 41 :105–107.
- * **Kim, E. J.; Cho, D.H.; Howang, S. Y.; and Kim, T. S. (2001).** Interleukin –2 fusion protein with anti-CD₃ single – chain FV (SFV selectively protects T- cell from dexamethasone – induced apoptosis. *Vaccine*, 20: 608-615.
- * **Morar , R . and Feldman ,C .(2003).**Pulmonary echinococcosis . Eur . Respir . J .21:1069-1077.
- * **Mousavi, J. and Tappeh, K.H. (2010).** Production of Experimental Hydatid cyst in the Eye,Peritoneum and Liver of BALB/C Mice .Turkiye parazitoloji Dergisi , 34(1):21-23.
- * **Pedrosa , I . ; Saiz , A . ; Arrazola , F. ;Ferreiros , F. and Pedrosa , C . S .(2000) .**Hydatid disease :radiologic and pathologic features and complications . Radiographics, 20:795-817.
- * **Ramos,G.; Orduna,A. and Garcia-Yuste,M. (2001).**Hydatid cyst of the lung: diagnosis and treatment, *World-J-Surg.* Jan; 25(1): 46-57.
- * **Sayek , I . and Onat , D . (2001).**Diagnosis and treatment of uncomplicated hydatid cyst of the liver .World .J .Surg .,25:21-7.
- * **Sharma, B.G. and Gupta, K.K. (2000).** Spontaneous intraperitoneal expulsion of an unrupturedhydatid cyst. *Saudi Med J* ;21:99-102.
- * **Smyth, J. D. ; and Barrett, N. J. (1980).** Procedure for testing the viability of human hydatid cyst following the surgical removal , especially after chemotherapy . *Trans. Roy. Soc. Trop. Med. Hyg.*, 74 : 649 – 652.
- * **Thompson ,R .C. A. and McManus ,D . P. (2001).**Aetiology :Pawlowski, Z. eds.WHO/OIE manual on echinococcosis in humans and animals :a public health problem of global concern .Paris :World Organisation for Animal Health .1-19.
- * **Torgerson , P. R . and Heath , D . D . (2003).**Transmission dynamics and control options for *Echinococcus granulosus* .*Parasitology* 127(suppl.):S143-S158.
- * **Yang ,Y . R . ; Sun , T . ; Li , Z . ; Li , X . P . ; Zhao , R . and Cheng , L .(2005).** Echinococcosis ,Ningxia ,China .*Emerg Infect Dis* ,11:1314-6.
- * **Zaidi M. (1999).**An unusual case of orbital hydatid cyst: a surgical emergency. *Ann. Plast .Surg.*;42:327–329.