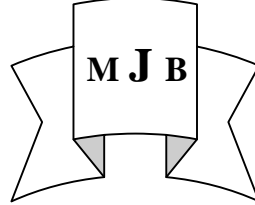


Fine Needle Aspiration Cytology (F.N.A.C.) of Goiter A Comparative Study between F.N.A.C. and Histopathology

Hadi Al-Mosawi Mohammed Al-Taie* Raad Al-Rubaey*
Collage of Medicine, University of Babylon, Hilla, Iraq.
*Hilla teaching Hospital, Hilla, Iraq.



Abstract

The aim of this study to held a comparasim between FNAC and histopathology of patient with nodular goiter.

Methods:- A prospective study of seventy eight patients included through the period between may 2009- October 2009 .All cases presented with multinodular and diffuse goiter, Ultra sound and thyroid function test were done for all them. The aspirated contents of the needle are expelled on to glass slides . two slides were immediately fixed in 95% ethyl alcohol for about 30 minutes and the slides well stained with Haematoxylin and Eosin (HandE).

Results :- The types of thyroid nodule cases which is diagnosed by FNAC are predominant of nodular colloid goiter 52 (66.6%) cases, followed by hyperplastic thyroid nodules 6(7.6%) cases, the thyroid cyst and papillary carcinoma having 4(5.1%) cases, , and finally the follicular tumor and hashimoto's thyroiditis 3(5.1%).

the histopathology results are reveal the nodular colloid goiter is the most common disease 61(78%) cases, hyperplastic thyroid nodule is the second common one, followed by Hashimoto's thyroiditis and follicular adenoma 4(5.1%)cases. the papillary carcinoma represent the last one 2(2.5%) cases. There are three false positive cases and one false negative case. The sensitivity (80%) , specificity (96%) and accuracy (97%) .

Conclusion:-FNA cytology of thyroid goiter are sensitive, specific, accurate and should be done before surgery to decide type of surgery patients needs.

الخلاصة

الأهداف : مقارنة بين تشخيص بواسطة الرشف الابري الدقيق الانسجة العقدة الدرقية وبين نتائج الفحص النسيجي .

الطريقة : هذه الدراسة شملت 78 حالة مرضية يعانون من عقدة الغدة الدرقية وتم اعدادها خلال الفترة من شهر اذار 2009 إلى شهر تشرين الأول 2009 لكل مريض تم سحب بواسطة الرشف الابري ووضع المادة على شرائح زجاجية وضعت بمادة الهيماتوكسين والايوسين ودراسة النتائج ومقارنتها بالزرع النسيجي لنفس المريض.

النتائج : أظهرت الدراسة إمكانية التشخيص بواسطة الرشف الابري الدقيق 72 حالة وعدم التشخيص في 6 حالات حيث 52 حالات عقدة هلامية و 4 حالات كيس داخل الدرقية ، 6 حالات عقدة سامة الغدة الدرقية، 7 حالات ورم الغدة الدرقية السرطاني و 3 حالات التهاب الغدة الدرقية نوع هوشموتو

نسبة حساسية الفحص 80% وخصوصية في التشخيص 95% ودقة 97%.

الاستنتاج : اعتماداً على نتائج الدراسة نستنتج ان فحص الرشف الابري الدقيق لعقدة الغدة الدرقية هو حساس ومتخصص ودقيق ويجب أن يعمل قبل إجراء العملية الجراحية ويفضل إجراء الفحص تحت توجيه بواسطة ويفضل إجراء المقارنة بين الفحص الرشف الابري الدقيق والفحص النسيجي بنفس اخصائصي الفحص النسيجي .

Introduction

Fine needle aspiration cytology (FNAC) is a well established

technique for pre-operative investigation of thyroid disease[1,2].

(FNAC) is widely accepted as the most accurate, sensitive, specific and

cost-effective diagnostic procedure in the assessment of thyroid nodules [3,4]. It is the primary diagnostic procedure in diagnosis of thyroid malignancy [5]. Numerous studies have shown it is high sensitivity and specificity in diagnosing malignancy of the thyroid especially papillary carcinoma [2,6]

In general FNAC are reported as clearly malignant, clearly benign, suspicious or non diagnostic. A non diagnostic results should never be interpreted as benign [7]

Papillary thyroid carcinoma is the easiest to diagnose microscopically with evidence of papillary fronds, monolayered sheets of cells with dense cytoplasm and distinct intracellular borders and pale nuclei, indistinct nucleoli[8] , Anaplastic carcinoma is also easy to identify due to its high degree of cellular atypia, multinucleated malignant cells, malignant spindle cells with mesenchymal appearance and necrotic cell fragments [9].

Follicular adenoma and carcinomas have similar cytological appearance with diagnosis of malignancy requiring demonstration of capsular or vascular invasion, cellular smear with equal sized cell clusters derived from follicles and often have rosette-like or acinar appearance , scanty colloid^[10,11]

The criteria for diagnosis of Hashimoto thyroiditis are Askanazy cells, moderate numbers of lymphocytes mainly of small mature type and scattered plasma cells[7,12]

In thyroid cyst during aspiration there is brown fluid, numerous foamy cells , many with ingested debris and spare epithelium showing degenerative features[13]

In hyperplastic nodule the cells are enlarged cells with more abundant vacuolated cytoplasm, variation in nuclear size and little colloid[14]

Most patients suffering some discomfort in the area for few hours the bleeding, infection and cyst formation but these complications are rare . Abundant colloid is the most characteristic finding in nodular goiter and fragility of the follicular cells, foamy cells [15].

The patient should be aspirated in the supine position placing a pillow under the neck tends to expose the gland more, bringing it away anteriorly from the sternomastoids this is particularly useful when a small, diffuse goiter [16], we use 23 gauge needles and 2-4 aspirations may be performed. in diffuse goiters both sides are sampled and in large nodules material from several areas should be aspirated, the needle is moved to and fro for several millimeters in the same needle track, this must be performed rapidly because of the vascularity of the thyroid , the aspiration is stopped if any material appears in the barrel of the needle or in the syringe, [17]

Patients and Method

A prospective study of seventy eight patients included through the period between may 2009- October 2009 . the case notes were retrieved and information about the age and sex.

All cases presented with multinodular and diffuse goiter, Ultra sound and thyroid function test were done for all them.

Each patients had one or two aspirate obtained using a 10 ml plastic syringe fitted with a 23-25 gauge disposable needle 1 1/2 inch long.

The procedure took a fraction of minutes. The aspirated contents of the needle are expelled on to glass slides . two slides were immediately fixed in 95% ethyl alcohol for about 30 minutes and the slides well stained with Hamatoxylin and Eosin (HandE) and examined with light microscope

the microscopic interpretation include:-

Benign: this means the nodule is not cancerous.

Malignant: this means nodule is cancerous.

Suspicious: this means diagnosis was not conclusive, but there was possible cancer.

Inconclusive: if the sampling was not sufficient, a diagnosis might be difficult in this case, an additional biopsy might be recommended.

Results

The FNAC results divided to: benign, malignant, suspicious and unsatisfactory according to study of slides

A seventy eight cases in this study, 72 (92%)cases can be diagnosed by the FNAC while 6(8%) cases need to another FNAC assessment table (1) . the types of thyroid nodule cases which is diagnosed by FNAC are illustrated in (table2) , which is shows predominant of nodular colloid goiter 52 (66.6%) cases ,followed by hyperplastic thyroid nodules 6(7.6%) cases, the thyroid cyst and papillary carcinoma having 4(5.1%) cases, , and finally the follicular tumor and hashimoto's thyroiditis 3(5.1%). There is three suspicious cases by FNAC, the histiopathology reveal two benign nodular colloid goiter and one case follicular adenoma. there is three undiagnosed cases by FNAC and the histopathology findings are all of them benign cases . the histopathology results are recorded in(table3) which

True +ve

$$\text{Sensitivity} = \frac{\text{True +ve}}{(\text{False-ve}) + (\text{True + ve})} \times 100$$

Specificity: a measure of the like hood that a patient with a lesion determined to be benign by histopathology will not have an

is reveal the nodular colloid goiter is the most common disease 61 (78%) cases, hyperplastic thyroid nodule is the second common one, followed by Hashimoto's thyroiditis and follicular adenoma 4(5.1%)cases. the papillary carcinoma represent the last one 2 (2.5%) cases

(Table4) shows the difference between the FNAC results and histopathological findings we found three false positive cases, two cases diagnosed by FNAC as papillary carcinoma , the histopathology shows one case colloid goiter and second case is hyperplastic nodule, the last case diagnosed by FNAC as follicular tumor , the histopathology diagnosis is hashimat's thyroiditis, one false negative case diagnosed by FNAC as nodular colloid goiter and the histopathology is follicular adenoma, all the thyroid cysts diagnosed by FNAC are cystic changes in the multinodular goiter

Sensitivity = 80 %

Specificity = 96 %

Accuracy = 97 %

Statistical Analysis

The result were presented by the use of SPSS and analyzed by chi square with probability less than 0.05 to be significant.

The following items were measured after comparing the results of reports of histiopathological with the findings of FNAC technique:-

Sensitivity: a measure of the like hood that a patient with tumor will have abnormal FNAC results express as percent

malignant features by FNAC results and express as well in percent.

$$\text{Specificity} = \frac{\text{True -ve}}{(\text{False +ve}) + (\text{True -ve})} \times 100$$

Positive predictive value: The probability that a thyroid disease with abnormal thyroid FNAC results will prove to be malignant thyroid on histopathology

$$\text{Predictive Value of +ve results} = \frac{\text{True +ve}}{(\text{True +ve}) + (\text{False+ve})} \times 100$$

Negative predictive value: The probability that thyroid disease without an abnormal cytological results will prove to be benign by histopathology

$$\text{Predictive value of -ve results} = \frac{\text{True -ve}}{(\text{True-ve}) + (\text{False-ve})}$$

True negative : FNAC negative for thyroid malignant cells, histopathology reveal no malignancy

False positive: FNAC positive for thyroid malignant cells, histopathology reveals no malignancy

True positive: FNAC positive for thyroid malignant cells , histopathology reveal malignancy

False negative: FNAC negative for thyroid malignant cells, histopathology reveals malignancy

$$\text{Accuracy} = \frac{(\text{True+ve}) + (\text{True-ve})}{\text{Total}} \times 100$$

The sensitivity rate was 80%, the specificity rate was 96%, predictive value of +ve results

Table 1 Cases of FNA diagnosis

F.N.A. Result	NO.
Diagnosis by F.N.A.	72
Undiagnosed by F.N.A.	6
Total cases	78

Table 2 F.N.A.C. Results

F.N.A.C.	No.
Nodular colloid Goiter	52 (66.6%)
Thyroid cyst	4 (5.1%)
Hyperplastic thyroid Nodules	6 (7.6 %)
Papillary ca.	4 (7.6 %)
Follicular tumor	3 (5.1 %)
Hashiomatos thyroiditis	3 (3.8 %)
Suspicious tumor	3 (3.8 %)
Non diagnostic	3 (3.8 %)
Total cases	78 (100%)

Table 3 Histopathological findings

Histopathology Findings	No.
Nodular colloid Goiter	62 (78 %)
Hashiomotos thyroiditis	4 (5.1%)
Follicular adenoma	3 (3.8 %)
Papillary carcinoma	2 (7.6 %)
Hyperplestic nodules	7 (8.9 %)
Total cases	78 (100%)

Table 4 the difference between the FNAC and histopathology

Thyroid Disease	F.N.A.C. No.	Histopathology No.
Nodular colloid Goiter	52 (66.6 %)	61 (78.2 %)
Hashiomat's thyroiditis	3 (3.8 %)	4 (5.1 %)
Thyroid cyst	6 (7.6 %)	7 (8.9 %)
Follicular adenoma	4 (5.1 %)	—
Hyperplastic nodules	3 (3.8 %)	3 (3.8 %) 1 (1.2 %)
Total	78 (100%)	78 (100%)

Discussion

Thyroid diseases are not uncommon and the patients are referred for FNAC as well as tissue specimen diagnosis for various thyroid swellings.

FNAC is a sensitive and highly specific method of evaluating thyroid nodules for malignancy

FNAC of thyroid nodule is reported to have a sensitivity ranges from 65%-98% and a specificity of 72%-100%

In our series the analysis of the data revealed the sensitivity 80% which is less than Harun.A. Nggada ,Alhaj .B.Musa et al.[19] And Danorov, redler A and DeAntoni et al.[15] 88.9% and 91.6% respectively .

In our study the specificity is 96% which is similar to results of Harun.A. Nggada ,Alhaj .B.Musa et al.[19] And Danorov, redler A and DeAntoni et al.[15] 96.1% and 94.7% respectively. The FNR is defined of the percentage of patients with benign cytology in whom malignant lesion are later on confirmed on thyroidectomy.

Our FNR is 1.5 % which is accepted figure compare to compell etal[18] (2.4%), and Yang J, Schnadig V, Logrono R , Wasserman PG [9] (1.7%) we had only one false negative case which was Diagnosis by FNAC as nodular goiter and histopathology revealed a result follicular carcinoma. that was due to in proper sampling of FNAC.

The FPR indicates that a patient with malignant FNAC result was found on histopathological examination to have benign lesion.

In present study the FPR is 2.6% this result is accepted in compare to Caruso and Mezzaferrri et al[17] 6% while Campbell and Pillsbury et al[18] reported 1.2%

The false positive three cases two of them were papillary carcinoma and the last one was follicular tumor by FNA while the histopathology showed one for them are hyper plastic nodule and

the other was nodular colloid goiter and this can be explained by hyper cellularityand atypia of cells. While the last case was hasiomatos thyroiditis and this can be explained by hypercellularity

The accuracy of our study was 97% , this very good result compared Caruso and Mazzaferri et al.[17] result which was 95%and Harun.A. Nggada ,Alhaj .B.Musa et al[19] (94.2%), the interpretation error can be reduced if aspirate was obtain from different portion of the nodule.

The result of our study shows that FNAC is more specific than sensitive in detecting malignancy and there fore it use as a reliable diagnostic test.

Conclusion and Recommendation

- FNA cytology of thyroid nodules are sensitive , specific , accurate and the initial investigation of thyroid disease and should be done before surgery to decide type of surgery patients needs.
- We encourage our physician and surgeon to embrace this procedure during patients handling , the use of ultrasound guided FNA produce is help to decrease the interpretation error.
- Its advisable to compare the final H/P result with initial FNA result the same histopetologist .
- Larger sample is required to for accurate result of FNA in assessment of rare thyroid disorder.

References

1. Rios A, Rordriguez JM, Galindo PJ, Montoya M, Tebar FJ, Sola J, Canteras M, Parrilla P, Fine –needle aspiration biopsy is of limited value for detection of carcinoma in patients with a multinodular goiter Clinical Endocrinology 2005; 61:723-737
2. RJ de Vos tot Nederveen Cappel, ND Bouvy, HJ Bonijer, JM van Muiswinkel, S Chadha, Fine needle

- aspiration cytology of thyroid nodule: how accurate is it and cytopathology, Vol. 12, No. 6. 2001 Dec. 399-405
3. Chow LS, Gharib H, Goellner JR, Van Heerden JA. Fine – needle aspiration biopsies of thyroid nodules that are non diagnostic do not exclude thyroid carcinoma thyroid 2001; 11: 1147-1151.
 4. Sclabas GM; Staerkel GA; Shapiro SE; Fornage BD ; Sherman SI; Vassilopoulos-Sellin R; Lee JE; Evans DB, Fine- needle aspiration of the thyroid and correlation with histopathology in a contemporary series of 240 patients. Am.J Surg 2003;186(6) 709-710.
 5. Baloch ZW, Cibas ES, Clark DP, et al. the National cancer Institute. Thyroid fine needle aspiration state of the science conference: CytoGournal. 2008;5:6
 6. Ko HM, Jhu IK, Yang, SH, et al. clinicopathologic analysis of fine needle aspiration cytology of thyroid . A review of 1613 cases and correlation with histiopathologic diagnosis. Acta Cytol. 2003; 47: 727-732.
 7. Kollur SM, EI Sayed S, EI Hag IA. Follicular thyroid lesions coexisting with Hashimoto's thyroiditis: incidence and possible source of diagnostic errors. Diag Cytopathol. 2003;28: 35-38.
 8. Wang HH. Reporting thyroid fine-needle aspiration: literature review and a proposal . Diag Cytopathol. 2006; 34: 67-76.
 9. Yang J, Schnadig V, Logrono R , Wasserman PG, Fine needle aspiration of thyroid nodules : a study of 4703 patients with histologic and clinical correlations cancer. 2007;11:306-315.
 10. poller DN, Ibrahim Ak, CummingsMH, Mikel JJ, Boote D, Perry M, Fine needle aspiration of thyroid. Cancer 2000; 90: 239-244
 11. Ylagan LR, Farkas T, Dehner LP. Fine needle aspiration of the thyroid: a cytohistologic correlation and study of discrepancies. Thyroid. 2004; 14: 35-41.
 12. Orlandi A, Puscan A, Capriata E, Fideleff H. Repeated fine needle aspiration of the thyroid in benign nodular thyroid disease: critical evaluation of long term follow up. Thyroid. 2005; 15: 274-278
 13. Baloch ZW, LiVolsi VA: Fine – needle aspiration of thyroid nodules: past, present and future. Endocr Pract 2004; 10:234-241
 14. Hamburger JJ: Diagnosis of thyroid nodules by fine needle biopsy: use and abuse. J Clin Endocrinol Metab 1994; 79: 335-339.
 15. D Andrea V, Redler A, Calo P, Donati L, Foti N, Falvo L, De Antoni E. thyroid nodules: comparison of preoperative and intraoperative needle aspirate and definite histological study, Acta Med Croatica 2008 oct; 62(4):391-401.
 16. Bisi H, de Camargo Ry, Longatto Filho A: Role of fine-needle aspiration cytology in the management of thyroid nodule. A review of experience with 1925 cases. Diagn Cytopathol 8: 504-510, 2003.
 17. Caruso D, Mazzaferri EL : Fine needle aspiration biopsy in management of thyroid nodules Endocrinologist 1. 2001: 194-202
 18. Campbell JP and Pillsbury HC 3d.: management of the thyroid nodule Head Neck 1999; 11:414-425
 19. Haruna A. Nggada, Alhaji B. Musa, Bata M. Gali, Mustapha I.A. Khalil: Fine needle Aspiration cytology of thyroid nodules(S): A nigerian Tertiary Hospital Experience. The internet Journal of cardiovascular Resarch. 2006. Volume 5 Number 1.