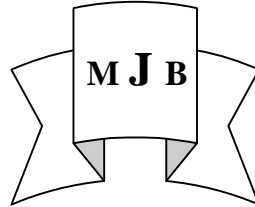


Evaluation of Intralesional Methotrexate in Comparison with Electrocutary in Treatment of Common Warts

Batool Ameen Al-Khafaji Hamid Naji Al-Kelaby Kareema Amine Alkhafaji
College of Medicine, University of Babylon, Hilla, Iraq.



Abstract

In this clinical trial, 42 patients (12 males and 30 females) of 12- 32 years old were randomly selected. They were clinically diagnosed as common warts on at least two symmetrical limbs (upper or lower) were selected and counted to form two groups of right sided and left sided warts. Each side of patient treated with methotrexate (MTX) intralesionally or electrocutary of his /her warts. Both treatment types were randomly allocated to either right side or left side warts. The mean No. of warts was 4.52 on upper limbs and 3.9 on lower limbs. A 6.78% of these warts which was treated with intralesional MTX were cleared compared with 22.6% for electrotherapy. We found that MTX to have clearance rate less than electrocutary. In conclusion: intralesional MTX is less effective than electrocutary in treating common warts on hands and feet.

الخلاصة

شملت هذه الدراسة السريرية اثنين وأربعين مريضا (30 رجلا و 12 امرأة) تتراوح أعمارهم ما بين سن (12-32) سنة وكان اختيارهم بصورة عشوائية. تم التشخيص السريري للتأليل الشائعة على الاقل في طرفين متماثلين من الاطراف العليا أو السفلى. واعتبر كل جانب من الاطراف العليا او السفلى كمجموعة اختبار منفصلة. تمت معالجة كل جانب من جانبي المريض أو المريضه بواسطة حقن عقار الميثوتريكسيت بداخل التأليل أو الكي الكهربائي لها. واستخدمت طريقتي العلاج في الجانب الايسر أو الايمن من الاطراف المصابة بالتأليل عشوائيا. ان المتوسط العددي للتأليل كان 4.52 في الاطراف العليا و 3.9 على الاطراف السفلى. لقد اختفى 6.78% من تلك التأليل المعالجة بالميثوتريكسيت مقارنة بـ 22.6% التي تم معالجتها بالكي الكهربائي. نستنتج من ذلك ان حقن التأليل الشائعة في اليدين أو القدمين بالميثوتريكسيت كان أقل تأثيرا من العلاج بالكي الكهربائي.

Introduction

Warts are benign growths usually caused by a viral infection of the skin or mucous membrane. Chemotherapeutic agents are possible wart treatments[1].

Methotrexate (MTX), a classical antifolate, is one of the most widely used and studied anticancer agents [2,3]. Unlike other anticancer agents, MTX can be safely administered over a wide range of doses, ranging from 20 mg/m² per week in maintenance chemotherapy for acute lymphoblastic leukemia and treatment of nononcologic diseases including rheumatoid arthritis or

psoriasis [3, 4]. Methotrexate and its polyglutamates block de novo nucleotide synthesis primarily by depleting cells of reduced tetrahydrofolate cofactors through inhibition of dihydrofolate reductase (DHFR) [5]. MTX polyglutamates and dihydrofolates that accumulate as a result of DHFR inhibition. It also inhibit thymidylate synthase and other enzymes involved in the purine biosynthetic pathway[6]. Methotrexate has been shown to be safe for long-term use in most children[7, 8]. Toxic effects to proliferating tissues are usually observed in the bone marrow and to a lesser extent in the skin and GI

mucosa. This effect can be reversed by administration of leucovorin [9]. Intralesional injection of methotrexate is effective for giant keratoacanthoma, which is a rapidly growing growth on the skin[10]. This study was designed to evaluate the intralesional MTX in comparison with electrocutary on common warts of hands and feet.

Materials and Methods

A forty eight patients, clinically diagnosed as common warts on at least two symmetric limbs (upper or lower limbs) were selected with the ages between 12- 32 years. Pregnant women, patients with cardiac pacemakers or patients who had taken any form of treatment were excluded from the study. Most patients (42 of 45) continued participation. The warts located on right/ left limbs of each patient were examined and counted to form two groups of right sided and left sided warts. Each patient received both treatment on his/ her warts. The two treatment types were randomly allocated to either right sided or left sided warts. A graphical warts map was prepared for each patient and location of warts along with data regarding wart size and type of treatment were recorded. Other data were collected through a structured questionnaire after an interview and medical examination by a dermatologist.

Treatment and assessment: (Trixiem 5mg/2ml. lemyry S.A DE C.V martries de Rio Branco No. 54 Maxico D.F 16030) was diluted up to different concentrations 2mg/ml, 1mg/ml and 0.5mg/ml. After adding 2% lidocaine, the drug was injected into the lesion using an insulin syringe. Injection was continued until each wart blanched.

In both treatments patients were visited every 15 days. The injections were repeated for a maximum three

times when required and the follow up continued for six month for evidence of recurrence, side effects or any other complaints. A wart was considered cleared if it completely resolved; otherwise it was considered as a failure of treatment. Test of proportion was used to test the significance of differences in wart cure between treatments. [11]

Results

Females constituted 71.43 percent of participants and 28.57 percent were males. Mean age of participants was 22.2 years. Mean number of warts on upper limbs was 4.52 and on lower limbs was 3.9. Distribution of warts on upper and lower limbs was statistically similar between study groups.

In 4.76 percent of the cases, all warts on the limb side treated by MTX were cleared compared with 71.43 percent for electrocutary (table 1), the difference was statistically significant ($P<0.01$). MTX was found to be less effective when the comparison was made between the total numbers of warts cleared by each treatment (table 2).

There were no adverse complications belonged to MTX, although many literatures mentioned many side effects to systemic MTX.

Discussion

In This study intralesional MTX was shown to be of low efficacy in clearing wart vs. electrocutary. Three different concentration of MTX was tested but the same results obtained. This result is agree with Hayes and O'Keefe (1986) that 0.5 mg/ml concentration is effective as 1 mg/ml [12].

In 4.76 percent of patients all the warts treated with MTX were cleared, and in 71.43 percent of patients all the warts treated with electrocutary were cleared. The treatment with MTX is repeated

when required, but it was not effective in 95.24 percent. While the clearance percent for bleomycin was related to the number of treatments received, and independent of the interval between treatments [13].

No published study was found to compare the efficacy of MTX with electrocutary on the same patients or the same study group, in contrast to bleomycin which had been found by Adalatkah, et. al. (2007) to has 1.23 times more clearance efficacy than cryotherapy [14].

Pain is the main problem in both electrocutary and intralesional MTX; analgesia is helpful in both groups. Pain management seems to be easier for MTX and the pain period is shorter compared with the pain and discomfort that may continue for several hours after electrocutary. The cost of MTX therapy is less than electrocutary, and MTX therapy also requires less equipment than electrocutary. There were no cases of significant adverse complications belonged to MTX, although many literatures mentioned many side effects to systemic MTX [10].

Conclusion

Although intralesional MTX is of least cost, easy to control and not required equipments, but it is less effective than electrocutary in treatment of common warts on hands and feet.

References

- 1- Bunney, MH. (1986). Viral warts: a new look at an old problem. *Brit. Med. J.* 293: 10457.
- 2- Allegra, CJ.(1990). Antifolates. In: Chabner, BA.; Collins, JM.; eds. *Cancer Chemotherapy*. Philadelphia: Lippincott Company, 1990:110–153.
- 3- Jolivet, J.; Cowan, KH.; Curt, GA. et al. The pharmacology and clinical use of methotrexate. *N Engl J Med* 1983;309:1094–1104.

- 4- Bright, RD. (1999). Methotrexate in the treatment of psoriasis. *Cutis*.64: 332–334.

- 5- Messmann, R.and Allegra, C.; Antifolates. In Chabner, B.; Longo, D. eds. (2001) *Cancer Chemotherapy and Biotherapy*. Philadelphia: Lippincott Williams & Wilkins, 139–184.

- 6- Chabner, BA.; Allegra, CJ.; Curt, GA. et al. (1985). Polyglutamation of methotrexate: Is methotrexate a prodrug? *J Clin Invest*.76:907–912.

- 7- Giannini, EH. and Brunner, HI. (2005). Treatment of juvenile rheumatoid arthritis. In WJ Koopman, LW Moreland, eds., *Arthritis and Allied Conditions*, 15th ed., vol. 1, pp. 1301–1318. Philadelphia: Lippincott Williams and Wilkins.

- 8- Allegra, CJ.; Chabner, BA.; Drake, JC. et al. (1985) Enhanced inhibition of thymidylate synthase by methotrexate polyglutamates. *J Biol Chem*. 260:9720–9726.

- 9- Katzung, BG. (2001) *Cancer chemotherapy*. In *Basic and Clinical Pharmacology*, 8th edition, pp. 933.

- 10- Speth, K.; Gille, J. and Kaufman, R. (2000). Intralesional methotrexate as effective treatment in solitary gaint keratoacanthoma of the lower lip. *Dermatology*. 200: (4) 317- 319.

- 11- Daniel, W.W. (1999). *Biostatistics: A foundation for Analysis in the Health science*. Sixth ed. P: 250-251.

- 12- Hayes, ME and O'Keefe, EJ. (1986) Reduced dose of bleomycin in the treatment of recalcitrant warts. *J Am Acad Dermatol*. 15 (5 Pt 1):1002-6.

- 13- Bourke, JF.; Berth-Jones, J. and Hutchinson, PE. (1995). Cryotherapy of common viral warts at intervals of 1, 2 and 3 weeks. *Br J Dermatol*. 132(3):433-6.

- 14- Adalatkah, H.; Khalilollahi, H.; Amini, N. and Sadeghi-Bazargani, H. (2007). Compared therapeutic efficacy between intralesional

bleomycin and cryotherapy for
common warts: A randomized

clinical trial. Dermatology Online
Journal 13 (3): 4.

Table 1 Effect of intralesional MTX and electrocutary on total number of warts in each limb

| Treatment trial group | | All warts cured | | Total |
|-----------------------------|-----------|-----------------|-------|-------|
| | | NO | Yes | |
| MTX | Frequency | 40 | 2 | 42 |
| | Percent | 95.24 | 4.76 | 100 |
| Electrocutary | Frequency | 12 | 30 | 42 |
| | Percent | 28.57 | 71.43 | 100 |
| Total | Frequency | 52 | 32 | 84 |
| | Percent | 61.9 | 38.1 | 100 |
| Test of proportion P < 0.01 | | | | |

Table 2 Overall effect of intralesional MTX and electrocutary on treating warts

| Treatment trial group | Number of Warts cured | % | Number of warts not cured | % | Total number of warts treated |
|-----------------------------|-----------------------|-------|---------------------------|-------|-------------------------------|
| MTX | 12 | 6.78 | 165 | 93.22 | 177 |
| Electrocutary | 40 | 22.6 | 137 | 77.4 | 177 |
| Total | 52 | 14.69 | 302 | 85.31 | 354 |
| Test of proportion P < 0.01 | | | | | |