

Screening of Surgically Explored Undescended Testes

Raad Wadullah khaleel* , Zaid Moayad Younis Altaee* , Atheer Attallah Ayyed* , Ibrahim M. Faisal**

*Alsalam Teaching Hospital, Ninawa Health Directorate, **College of Medicine, University of Mosul, Mosul, Iraq
Correspondence: Ibrahim.faisal1977@uomosul.edu.iq

(Ann Coll Med Mosul 2023; 45 (2):185-190).

Received: 27th March 2023; Accepted: 5th July 2023.

ABSTRACT

Background: As one of the most important congenital anomalies, undescended testis, or cryptorchidism contributes to infertility and as well as a risk factor for testicular carcinoma. However, it is unclear if cryptorchidism by its own a cause of testicular cancer.

Objectives: To evaluate the anatomical, morphological anomalies and histopathological changes of undescended testis in patients at various ages presenting to Al-Salam Teaching Hospital.

Materials and methods: A prospective cohort study was done in Mosul city teaching hospitals. Data of 40 patients with undescended testis after surgical exploration of the inguinal region were analyzed. Intra-operative gross appearance was examined and morphological changes were reported. A biopsy was taken from the undescended testis, preserved in Bouin's solution and sent for histopathological examination.

Results: The location of the testis among the 40 male patients was variable, the most common site was in the intracanalicular position (50%). Twenty two patients (55%) had normal sized testes, while in the rest: the testes were smaller or atrophied. Germ cell count was markedly diminished in 65% of the cases. One patient (2.5%) was diagnosed with intratubular germ cell neoplasia.

Conclusion: Patients with undescended testes in Mosul present late for medical care which raises the probability of infertility and malignant transformation.

Keywords: Undescended testis, Germ cell count, Orchiopexy.

فحص الخصيتين غير النازلتين المستكشفت جراحياً

رعد وعد الله خليل* ، زيد مؤيد يونس الطائي* ، اثير عطا الله اياذ* ، ابراهيم محمد فيصل**
*مستشفى السلام التعليمي ، دائرة صحة نينوى ، **كلية الطب ، جامعة الموصل ، الموصل ، العراق

الخلاصة

الهدف من الدراسة : دراسة التشوهات الظاهرية والشكلية بالإضافة الى التغيرات النسيجية للخصية غير النازلة للمرضى من مختلف الاعمار والذين تم علاجهم في مركز الجراحة البولية في احدى المستشفيات التعليمية في محافظة نينوى.

الطريقة : شملت هذه الدراسة ٤٠ مريضاً لديهم خصية هاجرة اجريت لهم عملية استكشاف المنطقة الاربية وعلاج الخصية الهاجرة بالتنبيب او الاستئصال خلال الفترة. شملت المقاييس التي اخذت بنظر الاعتبار حجم الخصية وموقعها والتشوهات الشكلية في البربخ والحبل الناقل للحيامن والتي تصاحب الخصية غير النازلة. كما تم اخذ خزعة من الخصية التي تم علاجها سواء بالتنبيب او الاستئصال وتمت دراسة التغيرات النسيجية المصاحبة.

النتائج : شملت الدراسة ٤٠ مريضاً. كان حجم الخصية اقل من الطبيعي في ١٥ حالة (٣٧,٥%) ولوحظ ان الحجم كان ينحدر عن الحجم الطبيعي بازدياد اعمار المرضى حين قدومهم للعلاج. كان عدد الخلايا المنتجة للحيامن اقل من الطبيعي في ٢٦ حالة (٦٥%) تم اكتشاف حالة واحدة من النماء في الخلايا المنتجة للحيامن.

الاستنتاج : يتأخر مرضى الخصية غير النازلة بالمراجعة لغرض تقديم العلاج النهائي لهم مما يزيد خطر الاصابة بعدم الخصوبة وبالأمراض الخبيثة.

الكلمات المفتاحية : الخصى النازلة ، تعداد الخلايا الجرثومية ، تثبيت الخصية .

INTRODUCTION

Undescended testis, or what is called cryptorchidism is found in 2 -5% of male children born at term, is a commonest congenital abnormality. This condition is commonly accompanied by infertility and considered to be a risk factor for carcinoma of the testes. The risk of cancer in males with undescended testes, is elevated from 3-8 times, and about 5-10% of all male patients with testicular cancer recorded a history for cryptorchidism. Yet, it is not known if undescended testis and testicular carcinoma are occur by one cause, or cryptorchidism provoke a testicular cancer.^{1,2} When the testis not descended, it will be ("together with the epididymis") linked to the abdominal wall by a mesorchium that contains blood vessels and ductus deferens. It lies down at the level of the kidney lower pole, iliac fossa, or in the pelvis. During the 7th intrauterine month, the testes will be existed at anterior superior iliac spine level while the epididymis at posterolateral. The length of gubernaculum is 1.8 cm. The peritoneum descends into the inguinal canal before the testes. "The testes begin to enter the internal ring as the gubernaculum emerges from the external ring. As the gubernaculum reaches the bottom of the scrotal sac, it begins to shorten until its lower two-thirds have disappeared completely. At about the end of the seventh intrauterine month, the testes pass through the inguinal canal. Although descent through the canal is accomplished in a few days, it takes four additional weeks for the testes to pass from the external ring to the bottom of the scrotum."³

Descent of testes is either complete or incomplete at birth. According to a previous work on premature births, the testis was undescended in 50% or more of the older infants.⁴ At term, the testis lies in the scrotum where it functions optimally at 33°C. A testis situated in the inguinal canal or abdomen is affected continuously by 35°C and 37°C respectively with progressive alteration in morphological and physiological function in addition to an elevated risk of complications.⁵ The testis descent is a complicated, multiple stage process that necessitates anatomical and hormonal factors interaction.⁶ The degeneration of the cranio-suspensory ligament and thickening of the gubernaculum are important anatomical events in releasing the testes from their urogenital ridge site and guiding the free gonads into the scrotum. Androgens have essential part in these processes, especially in permitting the testis passing the inguinal canal during the last phase of descent.⁷ This phase "transabdominal" of descent is controlled by insulin-like 3 (INSL3) and Leydig cell products. INSL3 levels are high in male boys at

puberty, undetectable in females while lower in those with cryptorchidism. A small percent might had a mutation either in the INSL3 gene or the receptor gene. Anti-Mullerian hormone also contributes to testis descending.⁸

The predominant factor that regulate the 2nd phase of testis descending into the scrotum is androgens. There is a large body of evidence illustrating how androgens promote testis descending into the scrotum. This includes the testis descent completion after birth accompanying neonatal surge in levels of testosterone. Furthermore, "human chorionic gonadotropin (hCG) injections that cause a significant increase in testosterone concentrations is a time-honored method for medicinal treatment of undescended testis".⁹

According to a recent epidemiological study the prevalence of cryptorchidism increased in recent years.¹⁰ It is thought that testes in cryptorchid undergo gross morphologic changes in relation to the size and the shape, different levels of detachment between the epididymis and testis, and elongation of the caudal epididymis and vas deferens. In addition to histological changes, such as decreased germ-cell counts.¹¹

Cryptorchidism is a heterogeneous disease, and the function of testes in adulthood may show different degrees alterations, as for seminal quality wings between normozoospermia to full azoospermia these causing males to become usually subfertile in adulthood because of spermatogenesis. It is well known that excryptorchid patients show decreased sperm concentration, elevated FSH, and decreased plasma inhibin B levels causing reduction in testicular volume and deterioration of fertility potential.¹²

Cryptorchidism is a common cause of secretory azoospermia, accounting for 20% of all azoospermic patients. It is widely acknowledged that testicular malposition causes early and progressive histological deterioration. As a result, the age for surgical correction of cryptorchidism (orchidopexy) has been reduced, and it is now recommended by age 2 years.¹³

Despite operation for cryptorchidism, it has been reported that one-third of patients are likely to be infertile. Although the exact reason of testicular cancer is unknown, a strong link to cryptorchidism is highly accepted. In fact, cryptorchid males have a higher lifetime risk of testicular neoplasia ("carcinoma in situ testis and invasive tumors") than the general population which is about four times higher. It has been reported that men who successfully treated from cryptorchidism have a lower risk of developing testicular cancer. The mechanism that link cryptorchidism to

carcinogenesis, on the other hand, is still unknown.¹⁴

PATIENTS AND METHODS

A prospective cohort study was conducted on 40 male patients with age ranging 2-37 years who presented with a diagnosis of unilateral or bilateral undescended testis and admitted for exploration of the inguinal region in the urology department of Al-Salam Teaching Hospital/Ninawa governorate from 2021-2022. Pre-operative general urine examination (GUE) and hemoglobin (Hb) estimation was done for all patients. After obtaining a signed informed consent from the patients or their parents or relatives explaining the procedure and informing them about the biopsy that would be taken from the affected testes, an open exploration of the inguinal region was done under general anesthesia. For patients in whom testes were present, restoration of undescended testes into a subdartos pouch in the ipsilateral scrotum was done after taking a biopsy from the body of the testes. The biopsy was preserved in Bouin's solution (which is a mixture of alcohol, formalin and glacial acetic acid). The specimen was then sent for histopathological examination where germ cell count was assessed together with the absence or presence of carcinoma in situ of the testis (CIS). In some cases, failure of the testes to reach the scrotum because of short spermatic cord indicated orchidectomy. This was dependent on the surgeon personal decision at the situation. Intra-operative assessment of the testes and epididymis was done regarding the location of the testes and the absence or presence of vassal and/or epididymal anomalies. The longitudinal diameter of the testes was measured to roughly assess the testicular size.

RESULTS

The study had been done on 40 male patients with age ranging from 2 to 37 years old (Table 1).

Table (1). Frequency distribution of study population according to age

Age groups (In years)	No. (n=40)
2 – 4	11
5 – 10	10
11 – 15	6
16 – 20	7
> 20	6

Figure (1) illustrates a total of 42 open exploration of the inguinal region for undescended testis including right operation of 25 and left of 13. Bilateral operation was 2 only.

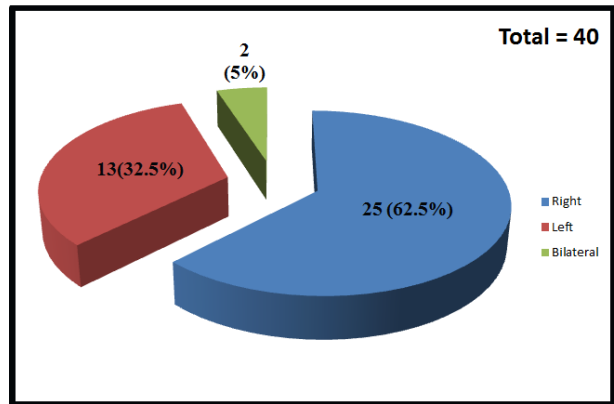


Figure (1). Side of Affection with Undescended Testes

Intra-operatively as shown in Table 2, the location of the testis was variable. It was found in the retroperitoneum in one case (at a level higher than the internal ring). In 13 patients, the testes were found lying on the internal ring.

Twenty patients had intracanalicular testes and 3 others had their testes in the suprascrotal area. Four of the explored testes showed vasal/epididymal anomalies including a high-looped epididymis in 2 cases. A blind-ended vas away from the testis was found in the other 2 testes.

Depending on the intra-operative findings and the personal judgment, orchidectomy was done for 5 patients and orchidopexy into the scrotum was done for the rest of the patients.

Table (2). Patient's intra-operative findings

Location of The Testis	
Intra-abdominal	1(3%)
Over the internal ring	13 (35%)
Intracanalicular	20 (54%)
Suprascrotal	3 (8%)
Vasal/Epidedymal Anomalies	
Present	4 (9.5%)
Absent (No Anomaly)	38 (90.5%)
Operation done	
Orchidectomy	5 (12%)
Orchiopexy	32 (76%)
(Absent Testes)	5 (12%)

Figure (2) shows that of the 37 cases in whom testis was present, 22 had a normally sized testis and 15 had a smaller than normal or atrophic testis as assessed by the measurement of the longitudinal diameter intra-operatively.

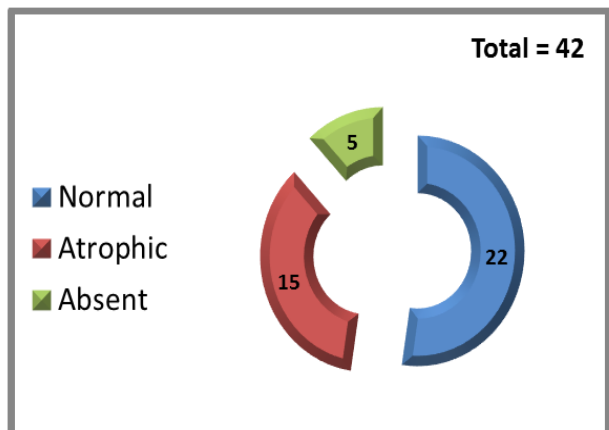


Figure (2). Assessment of testicular size by measuring the longitudinal diameter

As shown in Figure (3), histopathological examination of the biopsies taken from the testes showed different degrees of germ cell aplasia. A markedly diminished germ cell count (GCC) was found in 26 cases, slightly diminished in 6 cases and normal GCC was encountered in 5 cases. The degree of hypoplasia was increasing in severity with increasing age. Almost all patients older than 10 years of age had a markedly diminished germ cell count. One of the two patients who had bilateral undescended testes had unilateral (right) intratubular germ cell neoplasia. The patient was counseled for orchidectomy. However, he failed to continue his follow-up and orchidectomy was not done.

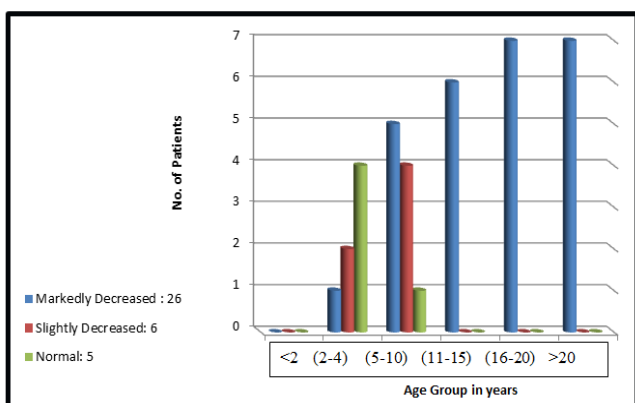


Figure (3). Germ cell count in the affected testis

DISCUSSION

The first important finding in the present work was that the children with undescended testes presented late to seek for medical intervention. Although cryptorchidism is a congenital anomaly that is noticeable at birth, none of the patients is seen discovered in first year of life which is the ideal age for surgical intervention. These findings are in agreement with previous works.^{15,16}

In the aforementioned study, 80% of the patients were older than 4 years. A study done by David et al, in 2008 showed that 44% of the patients presented within the first 5 years of life.¹⁷ This delay in attendance is due in part to people's lack of awareness and the lack of expert birth attendants who can diagnose cryptorchidism during delivery.

The age at surgery was 2 to 37 years with the major age group being 2-4 years. In Mosul locality, the current mean age at which surgery done is 5-10 years; the reasons for this lateness include late presentation, ignorance of initial attending doctors regarding age at optimal treatment and lack of recognition by midwives. Similar results were found in the study done by Ameh et al.¹⁸

The age at attendance was a significant element of the morphological alterations. Testicular size was getting abnormal or atrophic as the patient go older (Figure 4), so that there were significant statistical differences seen between the group that attended between 5 years of age and those who attended later. p-value was <0.05 at 95% confidence interval in age groups below 5 and was highly significant (p-value <0.001 at 99% confidence interval) at age groups above 5 years. Similar results were obtained in the study done by David et al, in 2008.¹⁷

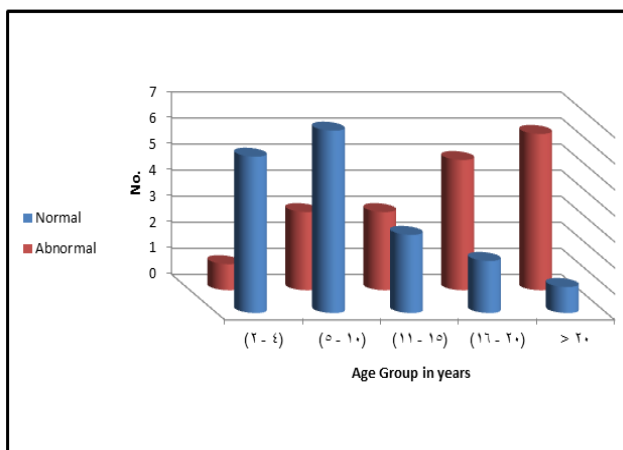


Figure (4). Undescended testicular size according to age groups

Out of the 42 operations that were done, five orchidectomies (12%) were performed and 5 (12%) patients had absent testis on exploration. Similar percentage was encountered in a study done by Ameh et al.¹⁸

Another study done in India by Krishna et al who discovered a close correlation between the degree of histological damage and the age of the subject.¹⁹

A study done by Schindler et al, on the other hand revealed no correlation between the age of the patient and the germ cell count.²⁰

No difference was detected between the age groups regarding the elongation and looping of the epididymis as well as the vassal anomalies. However, these changes were more prominent in the highly located testes. Again, this agrees with the finding of Miliaras et al.¹⁵

CONCLUSIONS

1. It can be concluded that, despite the fact of the need for early surgical correction of undescended testes is well established, patients continue to attend late to the surgeon, at least in Mosul area, putting them at risk of infertility or malignant transformation.
2. The importance of early surgical corrections should be emphasized to the medical staff and certain misconceptions, such as the age at which spontaneous testicular descent can occur, should be clarified.

RECOMMENDATIONS

1. Educational programs for parents about undescended testis and the benefits of early detection.
2. Management of undescended testis may be improved with educational update and new transferring models among primary health practitioners.
3. Timely referral to a surgical specialist and timely surgical correction are important to decrease infertility and other complications.
4. Physicians should be encouraged to check testicular descent in boys throughout childhood.

REFERENCES

1. Stockman, J.A. Age at Surgery for Undescended Testis and Risk of Testicular Cancer. *Yearbook of Pediatrics*, 2009, 199-201. doi:10.1016/s0084-3954(08)79090-0.
2. Ozaki, Y., Narita, T., Hatakeyama, S., Tanaka, T., Togashi, K., Hamaya, T., et al. Trends of incidence and age in adults with testicular germ cell tumors: a two-decade multicenter retrospective study. *Transl Androl Urol* 2023;12(2):161-167 | <https://dx.doi.org/10.210>.
3. Shreyas, K., Rathod, K.J. and Sinha, A. Management of high inguinal undescended testis: a review of literature. *Ann Pediatr Surg*. 2021; 17, 42. <https://doi.org/10.1186/s43159-021-00107-6>
4. Rodprasert W, Virtanen HE, Mäkelä J-A and Toppari J Hypogonadism and Cryptorchidism. *Front. Endocrinol* 2020; 10:906. doi: 10.3389/fendo.2019.00906
5. David, O.O., and Iyekoretin, E. Undescended testes in a developing country: A study of the management of 71 patients; *African Journal of Paediatric Surgery* 2008; 5(1): 11-4. DOI: 10.4103/0189-6725.41629
6. Nepal P, Kumar D, Ojili V. Abnormal descent of the testis and its complications: A multimodality imaging review. *SA J Radiol*. 2018 Sep 27;22(1):1374. doi: 10.4102/sajr.v22i1.1374. PMID: 31754510; PMCID: PMC6837786.
7. Martin, L. J., and Touaibia, M. Improvement of Testicular Steroidogenesis Using Flavonoids and Isoflavonoids for Prevention of Late-Onset Male Hypogonadism. *Antioxidants*. 2020; 9(3), 237. doi:10.3390/antiox9030237
8. Couture, R., Mora, N., Al Bittar, S., Najih, M., Touaibia, M., Martin, L.J. Luteolin modulates gene expression related to steroidogenesis, apoptosis, and stress response in rat LC540 tumor Leydig cells. *Cell Biology and Toxicology*. doi:10.1007/s10565-019-09481-9.
9. John, M. H., Bridget, R. S., Ruili, L., et al. The Regulation of Testicular Descent and the Effects of Cryptorchidism, *Endocrine Reviews*, 2013;34,(5):725–752, <https://doi.org/10.1210/er.2012-1089>
10. Désiré, A. M., Buhendwa, C., Césaire, T. M. A., et al. Epidemiology, Diagnosis and Therapeutic Approaches of Cryptorchidism at the Panzi General Hospital, DR Congo: A 5-year Retrospective Study. *Ethiop J Health Sci*. 2020 Jan;30(1):107-114. doi: 10.4314/ejhs.v30i1.14. PMID: 32116439; PMCID: PMC7036455.
11. Niedzielski, J., Nowak, M., Kucharski, P., Marchlewska, K., Słowikowska-Hilczer, J. Testicular, Epididymal and Vasal Anomalies in Pediatric Patients with Cryptorchid Testes and Testes with Communicating Hydrocele. *Clin.*

- Med. 2022, 11, 3015.
<https://doi.org/10.3390/jcm11113015>.
12. Chung E, Brock GB. Cryptorchidism and its impact on male fertility: a state of art review of current literature. *Can Urol Assoc J.* 2011 Jun;5(3):210-4. doi: 10.5489/cuaj.10106. PMID: 21672488; PMCID: PMC3114036.
 13. Leslie, S. W., Sajjad, H., Villanueva, C. A. Cryptorchidism. [Updated 2022 Nov 28]. In: StatPearls [Internet]. Treasure Island (FL): StatPearls Publishing; 2022 Jan-. Available from: <https://www.ncbi.nlm.nih.gov/books/NBK470270/>
 14. Ferguson L, Agoulnik AI. Testicular cancer and cryptorchidism. *Front Endocrinol (Lausanne).* 2013 Mar 20;4:32. doi: 10.3389/fendo.2013.00032. PMID: 23519268; PMCID: PMC3602796.
 15. Miliaras, D., Vlahakis-Miliaras, E., Anagnostopoulos, D., Koutsoumis, G., Pergamalis, G., Miliaras, S. Gross morphologic variations and histologic changes in cryptorchid testes. *Pediatr Surg Int* 1997;12: 158-162. doi:10.1007/BF01349988.
 16. Shin, J., Jeon, G. W. Comparison of diagnostic and treatment guidelines for undescended testis. *Clin Exp Pediatr* 2020;63(11):415-421. DOI: <https://doi.org/10.3345/cep.2019.01438>.
 17. David, O. O., Iyekoretin, E. Undescended testes in a developing country: a study of the management of 71 patients. *Afr J Paediatr Surg.* 2008 Jan-Jun;5(1):11-4. doi: 10.4103/0189-6725.41629. PMID: 19858656..
 18. Ameh, E. A., Mbibu, H. N. Management of undescended testes in children in Zaria, Nigeria. *East Afr Med J.* 2000 Sep;77(9):485-7. doi: 10.4314/eamj.v77i9.46694. PMID: 12862139.
 19. Krishna, R., Kotaiah, M., Geetha, K., Santosh, G., Srinivas, R. P., Ramesh, R. K. Cryptorchidism and its Effects on Histomorphology of Testis in Paediatric Age Group. *J. Evolution Med. Dent. Sci.* 2019 Aug;8(31):2278-4802. DOI: 10.14260/jemds/2019/540.
 20. Schindler, A. M., Diaz, P., Cuendet, A., Sizonenko, P. C. Cryptorchidism: a morphological study of 670 biopsies. *Helv Paediatr Acta.* 1987 Oct;42(2-3):145-58. PMID: 2891637.