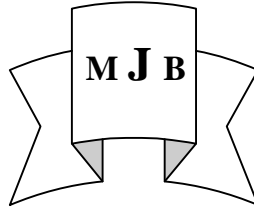


## Significance of Reciprocal ST Segment Depression in Acute Inferior Myocardial Infarction

Ala Hussain Abbase

College of Medicine, University of Babylon, Hilla, Iraq.



### Abstract

**Back ground and purpose :** Precordial ST segment depression can occur in patients with acute inferior myocardial infarction. The aim of this study is to find if there are differences between patients with out reciprocal changes, patients with reciprocal changes maximum in  $V_1-V_3$  and patients with reciprocal changes maximum in  $V_4-V_6$  regarding the results of echocardiography, angiography and development of complications and in hospital mortality.

**Patient and method :** From April 2009 to April 2010, 72 patients with acute inferior myocardial infarction were included in this study divided into three groups, group I with no ST depression, Group II maximum ST depression in  $V_1-V_3$  and group III with maximum ST depression in  $V_4-V_6$ . Echocardiography was done, patients were followed for development of complications and mortality and coronary angiography was done to 16 patients.

**Results :** Remote regional wall motion abnormality was highest in group III 90% compared with group II 72% and group I 15%.

Ejection fraction was lowest in group III  $36 \pm 10\%$  compared with group II  $42 \pm 10\%$  and group I  $56 \pm 11\%$ .

Complications and mortality were as follows: group III (60% complication and 20% mortality), group II (32% complication and 8% mortality) and group I (7% complications and 2% mortality).

Coronary angiography showed multivessel disease in group III (71%), group II 50% and group I 33%.

**Conclusion:** Precordial ST depression specially  $V_4-V_6$  reflects larger infarction size or multivessel disease thus carries worse prognosis with lower ejection fraction, more regional wall motion abnormalities and higher complications and mortality.

### أهمية انخفاض مستوى ST التبادلي في احتشاء العضلة القلبية السفلي

#### الخلاصة

**الخلفية والهدف :** انخفاض جزء التخطيط ST ممكن الحدوث في حالات احتشاء العضلة القلبية السفلي . الهدف من هذه الدراسة هو لمقارنة المرضى الذين لا يحدث لديهم هذا الانخفاض مع المرضى الذين يحصل لهم انخفاض (وأشد من  $V_1-V_3$ ) مع المرضى الذين يحدث لديهم انخفاض (وأشد من  $V_4-V_6$ ) بالنسبة لنتائج فحص القلب بالاىكو ونتائج قسطرة شرايين القلب وحصول مضاعفات ووفيات .

**الطرائق :** من نيسان 2009 الى نيسان 2010 أجريت هذه الدراسة وشملت 72 مريضا مصابا باحتشاء العضلة القلبية الحاد قسموا إلى ثلاثة مجاميع المجموعة الأولى (27 مرضا) لا يوجد لديهم انخفاض في جزء التخطيط ST ، المجموعة الثانية (25 مريضا) يوجد لديهم انخفاض أشده في ( $V_1-V_3$ ) و المجموعة الثالثة (20 مرضا) يوجد لديهم انخفاض أشده في ( $V_4-V_6$ ) . اجري فحص القلب بالاىكو لكافة المرضى و تمت متابعة المرضى لظهور مضاعفات ووفيات. أجريت قسطرة شرايين القلب لستة عشر مريضا .

**النتائج :** لوحظ وجود مناطق بعيدة مصابة بقلة الانبساط بنسبة أكثر في المجموعة الثالثة 90% مقارنة بالمجموعة الثانية 72% و المجموعة الأولى 15% . نسبة ضيق القلب كانت الأقل في المجموعة الثالثة  $36 \pm 10\%$  مقارنة بالمجموعة الثانية  $42 \pm 10\%$  و

المجموعة الأولى  $56 \pm 11\%$ . المضاعفات و الوفيات كانت في المجموعة الثالثة (60% مضاعفات و 20% وفيات) والمجموعة الثانية (32% مضاعفات و 8% وفيات) و المجموعة الأولى (7% مضاعفات و 2% وفيات) .  
 قسرة شرايين القلب أظهرت أكثر من شريان تاجي مصاب بتضييق في المجموعة الثالثة بنسبة 71% و المجموعة الثانية 50% و المجموعة الثالثة 33%.  
**الاستنتاج:** المرضى المصابون بانخفاض ST خاصة  $V_4-V_6$  لديهم احتشاء عضلة قلبية أوسع مع شمول أكثر من شريان تاجي متضايق ولذلك فهم أكثر خطورة و لديهم نسبة اقل لضخ القلب ونسبة أكثر لوجود مناطق مصابة بضعف الحركة مع نسبة أكثر من المضاعفات و الوفيات .

## **Introduction**

**I**nferior wall myocardial infarction accounts for 40-50% of all acute myocardial infarction and generally viewed as having favorable prognosis than anterior infarction.

There are many investigations which are done in the setting of acute myocardial infarction, however, ECG remains the most basic and readily available, widely accepted tool for it's diagnosis[1].

Numerous studies have investigated the pathophysiology and prognostic significance of precordial ST segment depression in patients with acute inferior myocardial infarction [2-5], most are limited to ST depression in leads  $V_1-V_4$  or don't distinguish between ST depression in leads  $V_1$  to  $V_3$  versus the more left ward precordial leads (leads  $V_4-V_6$ ) and the conclusion drawn in these studies conflict [6].

To investigate whether there are differences between the different patterns of precordial ST depression regarding development of complications, mortality, Echocardiographic and angiographic findings in patients with acute inferior myocardial infarction this study was conducted.

## **Patients and Methods**

The study was conducted in Merjan teaching hospital between April 2009- April 2010, involving patients with acute inferior myocardial infarction for which the diagnosis depended on chinal features of

patients with recent chest pain more than 30 minutes associated with ECG changes in form of ST elevation  $\geq 1$ mm in at least two inferior leads with elevated cardiac biochemical markers.

Patients with previous myocardial infarction, previous coronary by pass surgery, left bundle branch block, left ventricular hypertrophy were not included in the study, in addition to that patients who had ST elevation in anterior or anterolateral leads in addition to ST segment elevation in inferior leads were excluded from the study. Patients with poor echo cardiographic window were also excluded from the study.

Complete history and physical examination was done for the patients regarding age, sex, history of hypertension [on treatment or B.P.  $> 140/90$ ], history of diabetes mellitus [on treatment or fasting blood sugar  $\geq 7$  mmol/l or random blood sugar  $\geq 11.1$  mmol/l] [7], and history of smoking.

12 leads electrocardiograms were done to all patients at time of admission and frequent times later on. ST segment deviation from base line was measured 60 m.second after J point. The patients were divided into three groups, group I : ST depression of  $< 1$  mm in all precordial leads, group II : ST depression of  $\geq 1$  mm in one or more precordial leads with the sum of ST segment depression in lead  $V_1-V_3$  equal or more than the sum in leads  $V_4-V_6$ , group III : ST depression  $\geq 1$  mm in one or more precordial

leads with the sum of ST segment depression in leads V<sub>4</sub>-V<sub>6</sub> greater than the sum in leads V<sub>1</sub>-V<sub>3</sub>

Thrombolytic therapy was given for every patient who presented with chest pain no more than 12 hours with no contraindication for thrombolytic therapy.

The patients were followed during period of hospitalization that ranged from 3-10 days for any complications (like heart failure, high degree heart block, serious ventricular arrhythmia) and in hospital mortality.

Echocardiography was done for all patients using Philips Envisor version C.O.2 and the result were studied in relation to segmental wall motion abnormalities, ejection fraction was measured when possible by modified Simpson's method and was correlated with visual assessment.

Some of the patients underwent selective coronary angiography by the percutaneous (Judkins) technique after a period ranged from 3 weeks to 9 months . Significant coronary artery

**Table I** shows the demographic characteristics of the three groups

variable	Group I No 27	Group II No 25	Group III No 20	P. Value
Age	51 ± 10	52 ± 7	54 ± 9	N.S
Male / Female	19/8	20/5	16/4	N.S
Hypertension	8	10	7	N.S
Diabetes mellitus	6	7	4	N.S
Smoking	10	15	7	N.S
Thrombolytic therapy	15	14	12	N.S

**P > 0.05**

Demographic variables , major cardiovascular risk factors and use of thrombolytic therapy were similar between patients in the three groups.

Presence of remote regional wall motion abnormalities was

disease was considered when there was 70% and more narrowing of the lumen except left main stem where lumen narrowing of 50% and more was considered significant.

**Statistical analysis**

The variables were presented as means ± SD as proportions for categorical data. Analysis of variance (ANOVA) test was used to determine the significant level of difference in various variables of patients groups . P value less than 0.05 was considered significant.

**Results**

72 patients enrolled in the study ,55 males and 17 females, their age ranged 36-85 years [mean 51 ± 8 years]

27 patients (37.5%) had no precordial ST depression (group I), while 45 patients (62.5%) had ST depression, 25 (35%) patients had ST depression in V<sub>1</sub>-V<sub>3</sub> more than V<sub>4</sub>-V<sub>6</sub> (group II) and 20 (28%) patients has ST depression in V<sub>4</sub>-V<sub>6</sub> more than V<sub>1</sub>-V<sub>3</sub> (group III).

significantly less in group 1 compared with group II and group III and was more in group III, ejection fraction was significantly higher in group 1 compared with group II and group III and was lowest in group III as shown in table II

**Table II** shows the presence of remote regional wall motion abnormalities and the ejection fraction of the three groups.

	Group I No27	Group II No25	Group III No20
Remote regional wall motion abnormalities	4 (15%)	18 (72%)	18 (90%)
Ejection fraction	56 ± 11%	42 ± 10%	36 ± 10%

**P < 0.05**

Remote regional wall motion abnormalities include areas other than inferior wall including posterior, posterolateral, inferoseptal, anteroseptal, and apical.

**Table III** shows the development of complications and mortality in the three groups

	Group I No27	Group II No25	Group III No20
Complications	2 (7%)	8 (32%)	12 (60%)
Death	1 (4%)	2 (8%)	4 (20%)

The most common recorded complications were high degree heart block, heart failure and ventricular arrhythmia.

Coronary angiography was done to 16 patients , the results are shown in table (IV).

**Table IV** shows the results of coronary angiography that was done to 16 patients

	Group I	Group II	Group III
No. of diseased vessel	No 3	No 6	No 7
Single vessel	2(67%)	3(50%)	2(29%)
multi vessel	1(33%)	3(50%)	5(71%)

71%Patients in group III had multivessel disease (5 out of 7) and all of the 5 patients had LAD (left anterior descending artery ) disease .

50% Patients with group II had multivessel disease [three patients, two of them had diseased LAD].

Out of 8 patients with multivessel disease 6 patients had diseased LAD

### **Discussion**

Reciprocal ST depression is common in patients with inferior wall myocardial infarction. It occurred in 62.5% in this study while other studies gives different figures from roughly 50%[8]to 56%[9] to 80%[1].

It is generally agreed that the presence of precordial ST depression identifies a sub group of patients with inferior wall

myocardial infarction with lower ejection fraction reflecting larger infarction and more severe regional wall motion abnormalities.

Shah et al found abnormal regional wall motion abnormalities in patients with ST depression [with out mentioning the maximum site] in 50% VS 15% in patients with out ST depression[10].

Gold borg found 13 out of 14 patients with reciprocal changes (with out mentioning the site of maximum ST depression) had posterolateral akinesia while 11 patients with out reciprocal changes had no posterior akinesia[11].

Celiks et al concluded in his study that reciprocal ST segment depression during early phases of inferior infarction is an electrical reflection of primary ST segment elevation in the area of infarction rather than a consequence of ischemic distance.[12]

This study showed the incidence of remote regional wall motion abnormality was higher in patients with maximum ST depression in  $V_4-V_6$  than those with maximum ST depression in  $V_1-V_3$  and both were higher than patients with out ST depression.

Mean left ventricular ejection fraction in patients with ST depression given in different studies (with out mentioning the site of maximum ST depression) are  $48 \pm 13$ ,  $45 \pm 11$  VS  $56 \pm 11$ ,  $63 \pm 6$ [13] in patients with out ST depression .

This study showed that patients with maximum ST depression in  $V_4-V_6$  had lower ejection fraction than patients with maximum ST depression in  $V_1-V_3$  and both were lower than

ejection fraction of patients with out ST depression.

GP parale et al found ejection fraction less than 40% in 80% of patients with maximum ST depression in  $V_4-V_6$  and 13% of patients with maximum ST depression in  $V_1-V_3$  had ejection fraction less than 40%[1].

The two leading explanations for anterior ST depression that are believed to explain the larger infarction with lower ejection fraction, more remote regional wall motion abnormalities and more complicated courses observed in these patients are anterior ischemia due to concomitant LAD disease or more extensive and severe inferoposterior infarction which produces ST elevation manifested as anterior ST depression on the surface electrocardiography.

Some studies mentioned that complications in patients with reciprocal changes occurred in 72% [with out mentioning the site of maximum ST depression] compared with 31% in patients with out ST depression.

This study showed that complications occurred more in patients with maximum ST depression in  $V_4-V_6$  (40%) than patients with maximum ST depression in  $V_1-V_3$  (24%) and the lowest complications occurred in patients with out ST depression (7%).

Mortality rates among patients with inferior myocardial infarction is generally 2-9%[1,14] but it differs according to ST depression. Some studies compared the mortality in patients with out ST depression 4%, 4% VS 31%, 28%[13,15] in patients with precordial ST depression with out

taking in consideration the site of maximum ST depression.

This study showed that mortality was higher in patients with maximum ST depression in V<sub>4</sub>-V<sub>6</sub> than that of patients with maximum ST depression in V<sub>1</sub>-V<sub>3</sub> and lowest mortality occurred in patients with out ST depression.

So electrocardiography during acute inferior myocardial infarction with maximum ST depression in V<sub>4</sub>-V<sub>6</sub> indicates larger infarction and predicts high hospital complications and mortality.

Coronary angiography was performed to 16 patients only and this low number is due to multiple causes including that primary percutaneous intervention is not a routine practice in our center, many patients became stable and their physicians preferred to continue on medical therapy, some patients had been lost in the follow up and probably some of them underwent coronary angiography in other centers.

Most of the patients who underwent coronary angiography had reciprocal changes [13 patients 81%] 7 of them belonged to group III, most common two indications were post infarction angina and heart failure.

Multivessel disease observed more in patients with group III and all the patients whom they had multivessel disease had LAD lesions reflecting that reciprocal ST depression in V<sub>4</sub>-V<sub>6</sub> might be due to anterior ischemia from concomitant LAD disease.

Zoghim M et al found multivessel disease in 58% of patients with reciprocal changes and in 40% of patients with out reciprocal changes concluding that presence of reciprocal

changes during an acute inferior myocardial infarction correlates with the presence of multivessel disease[16].

This conclusion was agreed by Chatterjee et al who mentioned that patients with reciprocal changes had more double vessel or triple vessel disease[17].

Other studies found that concomitant stenosis of LAD can be detected angiographically in 50% of all patients with inferior myocardial infarction whether ST depression is present or not[8].

Roubin et al found 36% diseased LAD in patients with precordial ST depression [with out mentioning the site of maximum ST depression] VS 3% for patients with out ST depression[13], and multivessel disease occurred in 53% in patients with precordial changes VS 6% in patients with out ST depression.

So ST depression in precordial leads reflects presence of more than single vessel disease and this occurs more in patients with maximum ST depression in V<sub>4</sub>-V<sub>6</sub> and thus explain the lower ejection fraction, remote regional wall motion abnormalities and higher incidence of complications and mortality . It is thought that in patients with ST depression and single vessel disease a branch of the right coronary artery often supplies the apex that it did in patients with out anterior ST depression so ST depression is either a reflect of larger infarction due to multivessel disease or greater amount of myocardium supplied by infarct related artery[18].

## **Conclusion**

Patients with inferior myocardial infarction and greater ST depression in leads V4-V6 have higher rate of diffuse coronary artery disease , lower ejection fraction , more remote areas of regional wall motion abnormalities, more frequent complications and mortality.

## **Recommendation**

The admission electrocardiogram is a simple , easily obtained non invasive and in expensive tool that may help in identifying sub groups of patients with inferior acute myocardial infarction who have diffuse coronary artery disease and at high risk and therefore may benefit from a more invasive approach.

## **References**

1. GP parate, PM Kulkarni, SK Khade et al. Importance of reciprocal leads in acute myocardial infarction JAPI. May 2004, vol 52:376-379.
2. Berger PB, Ryan TJ. Inferior myocardial infarction; high risk sub groups. Circulation 1990;81:401-411.
3. Bates ER, Clemmensen PM, Califf RM et al. precordial ST segment depression predicts a worse prognosis in inferior infarction despite reperfusion therapy. J AM Coll Cardiol 1990; 16:1538-1544.
4. Hasdai D, sclarovsky S, Solodky A et al. Prognostic significance of maximum precordial ST segment depression in right (V<sub>1</sub>-V<sub>3</sub>) versus left (V<sub>4</sub>-V<sub>6</sub>) leads in patients with inferior wall acute myocardial infarction. Am J Cardiol 1994; 74 : 1081-1084.
5. Birnbaum Y, Herz I, Scharovskys etal. Prognostic significance of different patterns of precordial ST depression in inferior wall acute myocardial infarction . J AM Coll Cardiol 1995; 85:343.
6. Yochai Birnbaum, MD Galen S. Wagner, MD, Gabriel. Etal. Correlation of angiographic findings and right (V<sub>1</sub>-V<sub>3</sub>) versus left (V<sub>4</sub> to V<sub>6</sub>) precordial ST segment depression in inferior wall acute myocardial infarction. AM J cardiol 1999;83 :143-148.
7. Nicki R. Colledge, Brian R. Walker, stuart H. Ralston. Diabetes mellitus. Davidson's principles and practice of medicine. 2010; 21:806.
8. P.K. Shah, Daniel S. Berman and H.J.C. Swan. Precordial ST segment depression in acute inferior myocardial infarction. International Journal of Cardiology. 1983; volume 4.Issue 1:75-80.
9. Gibson RS. Crampton RS, Watson DD. Etal. Precordial ST depression during acute inferior myocardial infarction clinical, scintigraphic and angiographic correlations. Circulation 1982; 66:732-741.
10. Shah PK, Pichler M, Berman DS, Maddahi J:Non invasive identification of a high risk subset of patients with acute inferior myocardial infarction. AM J Cardial 1980; 46:915-921.
11. Gold berg HL, Borer JS, Jacobstein JG, Kluger J. Anterior ST segment depression in acute inferior myocardial infarction : indicator of postero Lateral infarction. AM. J cardial 1981; 48:1009-1015.
12. Celik S, Yilmaz R, Baykan M , et al . Are reciprocal changes a consquence of ischemia at a distance or merely a benign electrical phenomenon ? A pulsed- wave tissue doppler echocardiographic study . Ann Non invasive Electrocardiol 2003 Oct;8(4):302-7.
13. Roubin GS, Shen W F, Nicholson M. Anterolateral ST segment depression in acute inferior myocardial infarction : Angiographic and clinical

implications. Am Hearts Cardiol 1985; 55:325-329.

14. Kennedy JW, Martin GV, Davis KB, Maynard C . The western Washington intravenous strepto Kinase in acute myo cardial infarction randomized trial. Circulation 1988; 77:345-352.

15. Mark A. Hlatky MD, Robert M. Califf MD, Kerry L.Lee PhD . Prognostic significance of precordial ST segment depression during inferior acute myocardial infarction. The American J of Cardiology. 1985;55:325-329

16. Zoghi M, Gurgun C, Yavuzgil O et al. The angiographic correlation

between ST segment depression in non infarcted leads and the extend of coronary artery disease in patients with acute inferior myocardial infarction : a clue for multivessel disease.Can J Cardiol.2003 Jan;19(1):67-71.

17. Chatterijee S, Roy S , Maity AK et al . Reciprocal ST segment depression in acute myocardial infarction . J Indian Med Assoc. 1996 Jan;94(6):221-3.

18. Peter B. Berger, MD, Thomas J. Ryan, MD. Inferior myo cardial infarction high-risk sub group. Circulation 1990; 81:401-411.