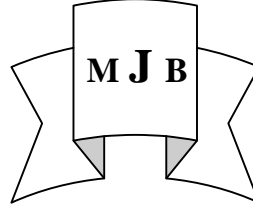


Rupture Ovarian Germ Cell Tumour, a Case Report

Ameer Kadhun Daher Maha Assim Kareem Ramzi Kadhun AL-Biati *
Collage of Medicine Wasit University, Iraq.
ameer_kadhun@yahoo.com
*Wasit Medicine Office

Case Report



Abstract

Germ cells tumors represent a very complicated group of tumors of the ovary and their histogenesis is not well clarified. They are rapidly growing neoplasms that arise from primordial germ cells derived from the embryonal gonad. Malignant germ cell tumours comprise less than 5% of all ovarian neoplasms. Embryonal carcinoma is quite rare, amounting to approximately three percent of ovarian germ cell tumours. We report a case mixed germ cell tumour, mainly embryonal carcinoma, in 12 years old female present with acute abdomen due to rupture of the tumour inside the abdominal cavity.

انفجار ورم الخلايا الجرثومية المختلط , تقرير عن حاله مرضيه ومراجعة البحوث

الخلاصه

اورام الخلايا الجرثومية تمثل اورام معقده جدا من اورام المبيض ودراستها النسيجية غير موضحة جدا. وهي اورام سريعة النمو تأتي من خلايا اوليه جرثومية من الاعضاء التناسليه الجنينيه . الاورام الجرثومية الخبيثه تمثل اقل من 5% من اورام المبيض. سرطان الخلايا الجنينيه نادر جدا و تصل الى 3% تقريبا من اورام الخلايا الجرثومية للمبيض. ونذكر هنا تقرير لحاله من ورم الخلايا الجرثومية المختلط وغالبيةه مكون من سرطان الخلايا الجنينيه في طفله عمرها 12 سنه والتي حضرت في حالة بطن حاد نتيجة انفجار الورم داخل التجويف البطني.

Introduction

A germ cell tumor (GCT) is a Neoplasm derived from germ cells, can be cancerous or non-cancerous. Germ cells normally occur inside the gonads (ovary and testis). Germ cell tumors that originate outside the gonads may be birth defects resulting from errors during development of the embryo. Some investigators suggest that this distribution arises as a consequence of abnormal migration of germ cells during embryogenesis. Others hypothesize a widespread distribution of germ cells to multiple sites during normal embryogenesis, with these cells conveying genetic information

or providing regulatory functions at somatic sites [1].

Ovarian germ cell tumors comprise approximately 15% to 20% of all ovarian neoplasms. They are rapidly growing neoplasms that arise from primordial germ cells derived from the embryonal gonad. Malignant germ cell tumours comprise less than 5% of all ovarian neoplasms. The incidence of malignant ovarian germ cell tumors range from 1 to 6 percent as reported in the West and from 8 to 19 percent in Asia [2].

Germ cell tumors are classified by their histology regardless of location in the body, and are broadly divided in two classes:

- **The germinomatous or seminomatous germ cell tumors (GGCT, SGCT)**

include only germinoma and its synonyms dysgerminoma and seminoma.

- **The nongerminomatous or nonseminomatous germ cell tumors (NGGCT, NSGCT)** include all other germ cell tumors, pure and mixed e.g. embryonal

carcinoma, endodermal sinus tumor (yolk sac tumor), choriocarcinoma, Polyembryoma and teratoma[3].

The term "embryonal carcinoma" was used in a study by Kurman [4], as it is analogous to embryonal carcinoma of the adult testis and can be distinguished from the endodermal sinus tumour by its distinctive morphology, immunohistochemistry, and clinical features [4].

In the ovary, embryonal carcinoma is quite rare, amounting to approximately three percent of ovarian germ cell tumours. The median age at diagnosis is 15 years. Symptoms and signs are varied, and may include sexual precocity and abnormal (increased, reduced or absent) uterine bleeding. There are often elevations in serum human chorionic gonadotropin (HCG) and alpha fetoprotein (AFP) levels. At surgery, there is extension of the tumour beyond the ovary in forty percent of cases. They are generally large, unilateral tumours, with a median diameter of 17 centimeters. Long term survival has improved following the advent of chemotherapy [5].

In the absence of obvious metastatic disease, accurate staging of germ cell tumors of the ovary requires laparotomy with careful examination of the entire diaphragm, both paracolic gutters, pelvic nodes on the side of the ovarian tumor, the para-aortic lymph nodes, and the omentum. The contralateral ovary should be carefully

examined and biopsied if necessary. Ascitic fluid should be examined cytologically. If ascites is not present, it is important to obtain peritoneal washings before the tumor is manipulated. In patients with dysgerminoma, lymphangiography or computed tomography is indicated if the pelvic and para-aortic lymph nodes were not carefully examined at the time of surgery.

The American Joint Committee on Cancer (AJCC) have designated staging for ovarian germ cell tumors. [6]

Stage I

- Stage I ovarian germ cell cancer is growth limited to the ovaries.

- Stage IA: Tumor is limited to ovary; capsule is intact, and no tumor is present on the ovarian surface. No malignant cells are present in ascites or peritoneal washings.

Stage IB: Tumor is limited to both ovaries; capsules are intact, no tumor is present on the ovarian surface. No malignant cells are present in ascites or peritoneal washings.

Stage IC: Tumor is limited to one or both ovaries with any of the following:

Capsule is ruptured

Tumor is present on the ovarian surface

Malignant cells are present in ascites or peritoneal washings

Note: Malignant ascites is not classified. The presence of ascites does not affect staging unless malignant cells are present

Stage II

Stage II ovarian germ cell cancer is growth involving one or both ovaries with pelvic extension and/or implants.

Stage IIA: Extension and/or implants are present on the uterus and/or fallopian tubes. No malignant cells are present in ascites or peritoneal washings.

Stage IIB: Extension to and/or implants are present on other pelvic

tissues. No malignant cells are present in ascites or peritoneal washings.

Stage IIC: Pelvic extension and/or implants (stage IIA or stage IIB) with malignant cells are present in ascites or peritoneal washings

Different criteria for designating cases to stages IC and IIC have an impact on the diagnoses. To evaluate the impact of the differing criteria, determine if rupture of the capsule was the result of any of the following possibilities:

- A spontaneous rupture
- A rupture caused by the surgeon

It is also important to determine if the source of the malignant cells detected was the result of either of the following:

Peritoneal washings

Ascites

Stage III

Stage III ovarian germ cell cancer is growth involving one or both ovaries with microscopically confirmed peritoneal implants outside the pelvis. Superficial liver metastasis equals stage III. Tumor is limited to the true pelvis but with histologically verified malignant extension to the small bowel or omentum .

Stage IIIA: Microscopic peritoneal metastasis is present beyond the pelvis (no macroscopic tumor).

Stage IIIB: Macroscopic peritoneal metastasis is present beyond the pelvis and is 2 cm or smaller in greatest dimension.

Stage IIIC: Peritoneal metastasis is present beyond the pelvis and is larger than 2 cm in greatest dimension, and/or regional lymph node metastasis is present

Stage IV

Stage IV ovarian germ cell cancer is growth involving one or both ovaries with distant metastasis. If pleural effusion is present, there must be positive cytologic test results to designate a case to stage IV.

Parenchymal liver metastasis equals stage IV[6].

An ovarian tumor can also be described by grade (G), which is how similar the tumor is to normal tissue. Tumor grade is determined by examining the tumor tissue under a microscope. Cells that appear healthy are called well-differentiated. In general, the more differentiated the ovarian tumor, the better the prognosis [7].

GX: The grade cannot be evaluated.

GB: The tissue is considered borderline cancerous.

G1: The tissue is well-differentiated (contains many healthy-looking cells).

G2: The tissue is moderately differentiated (more cells appear abnormal than healthy).

G3 to G4: The tissue is poorly differentiated or undifferentiated (all or most cells appear abnormal) [7].

Primary conservative surgery with comprehensive staging laparotomy and surgical cytoreduction of advanced disease, followed by prompt institution of adjuvant cisplatin-based combination chemotherapy have resulted in high cure rates in this disease. The role of laparotomy for post chemotherapy residue in ovarian germ cell tumors is in a state of evolution. The type of operative procedure in this setting is dictated by initial disease status, histology and operative findings, with fertility preservation always considered a desirable end point. In the studies about second look laparotomy for ovarian germ cell tumors, the patients who had initial complete resection of the tumor, with no teratomatous element and clinically no postchemotherapy residue with normal tumor markers were not found to benefit from the procedure [8].

Case report

A 12 years old female present to the surgical emergency department in Al-Karama teaching hospital/ Wasit Governorate- Iraq at 18th of December 2009 with history of 1 week lower abdominal pain not responding to usual conservatives treatment, followed by acute onset of sever abdominal pain vomiting and abdominal distention.

There was no history of abdominal trauma.

Physical examination revealed pale dehydrated afebrile female, Vital signs were as follows: blood pressure of 100/65 mmHg, pulse rate 115 bpm respiration 20/min. with generalized symmetrical tender abdominal distention.

Investigation show anemia (Hb9gm/dl) , increase WBC(11000), normal blood urea and blood sugar. a chest x-ray was normal and abdominal plain x-ray not suggestive.

Ultrasound examination of abdomen and pelvis show moderate ascites with pelvic mass extending up to just below the umbilicus. . CT scan confirms the diagnosis of ascites and irregular

solid mass extended below the abdominal wall from the pelvis, normal liver and Para aortic lymph nodes.

After resuscitation explorative laparotomy, through a midline incision, performed with finding of hemorrhagic ascites, ruptured big right ovarian tumor with gross feature of greater omentum invasion, normal looking liver and no enlarged lymph nodes can be detected.

Operative procedure included right salpingoophrectomy and omentectomy with biopsy of the other ovary; all send for histopathology study. Patient had uneventful postoperative period. Postoperative tumor marker were elevated alpha fetoprotein 448ng/ml (normal less than 8.5ng/ml) and mildly elevated level of B-HCG 28mIU/ ml (normal 0.1- 5.7 mIU/ ml).

Pathology

Gross examination

Necrotic haemorrhagic smooth mass with extensive cystic necrosis, measuring 18x10x8 cm with tube and part of ovary; grey measure 2x1x1 cm. figure.(1, 2)

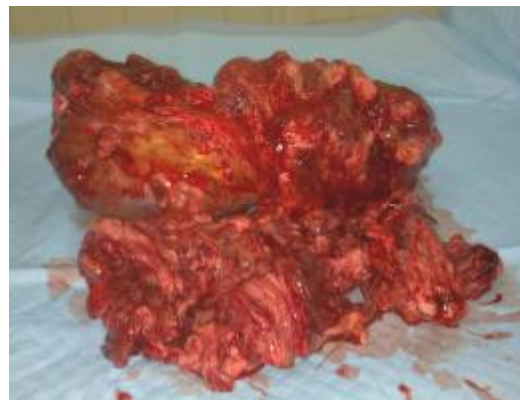
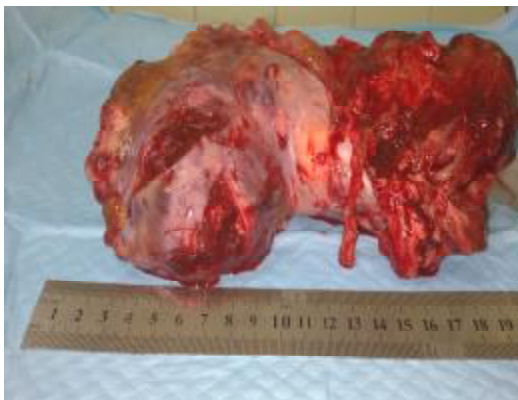
Figure 1 and 2 necrotic haemorrhagic soft mass

Microscopical examination: patient record no. 3102.....December 2009 Ovarian tumour showing solid sheets of malignant primitive cells forming

papillae and abortive glandular structures with extensive necrosis and congestion, pictures mostly of embryonal carcinoma. However foci

of combination with yolk sac tumour seen diagnosed by perivascular

Schiller - Duval bodies. Figure (3, 4)

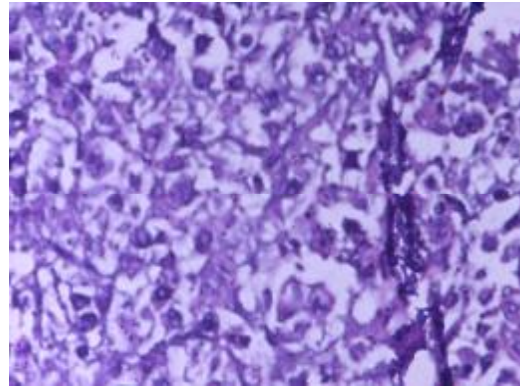
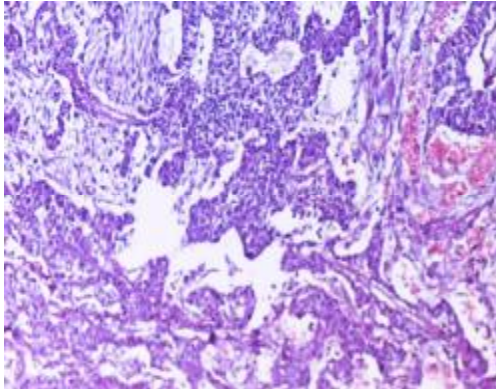


Figure 3 and 4 solid sheets of malignant primitive cells forming papillae and abortive glandular structures with extensive necrosis and congestion.

Discussion

Gonadal germ cell tumors continue to be the cause of diverse, diagnostically challenging issues and their correct resolution often has major important therapeutic and prognostic implications. They are academically interesting because of the biological diversity exhibited in the two gonads and variation in frequency of certain neoplasm. The most dramatic examples of the latter are the frequency of dermoid cyst in the ovary compared to the testis and the reverse pertaining to embryonal carcinoma[9]. Ovarian germ cell tumors commonly occur in teenagers and in women in their twenties, who generally desire to preserve their reproductive and ovarian endocrine functions. The patients frequently have large adnexal tumors with a median diameter of 16 cm and, with the exception of dysgerminomas are usually unilateral[10]. According to the WHO classification, mixed germ cell tumors of the ovary that contain more than one neoplastic germ cell element, are one of the subcategories of germ cell tumors [11].

We report a case of mixed germ cell tumour of the ovary, mainly embryonal carcinoma with foci of yolk

sac tumour, in 12 years old child which required emergency operation for rupture of the tumour. In the study of Gershenson et al, The median age of the patients was 16 years. The most common symptom was abdominal pain, occurring in 38 patients (90%) [12]. while De Backer A et al stated that ovarian germ cell tumors are rare in childhood and Sixteen patients (24%) had an emergency operation for tumor torsion [13]. Germ cell tumor may advance in size very quickly, and the patient presents with acute abdomen due to capsule distention, rupture, or torsion [14]. Management of our patient included salpingo- oophrectomy and staging procedure followed by postoperative tumor marker follow up and cisplatin-based combination chemotherapy. Embryonal carcinoma of the ovary is an extremely rare tumour and represents only about 3 per cent of malignant ovarian germ cell tumours [15]. However, the characteristics of the tumour and the patients have some special qualities as high rates of healing goes together with a strong desire to keep fertility intact because this condition occurs in female children and adolescent girls. Neither the prognosis nor the treatment of

these tumours is homogeneous; the low incidence is the reason it is hard to develop prospective studies for establishing prognostic factors and specific treatments. The introduction of adjuvant chemotherapy into initial surgery has improved the prognosis of these patients. In view of the rarity of these tumours, it is advisable to work within cooperative groups that may have subgroups for the treatment of rare tumours. This will probably be the only way to move forward in the prospective knowledge of prognostic factors for these tumours [16]. The purpose of screening is to discover ovarian cancer in early stages, when it is more curable, on the hypothesis that early-stage cancer develops into later-stage cancer. However, it is not known whether early stage ovarian cancer evolves to later stage cancer, or whether stage III (peritoneal cavity involvement) arises as a diffuse process. Routine screening of the general population is not recommended by any professional society. This includes the U.S. Preventive Services Task Force, the American Cancer Society, the American College of Obstetricians and Gynecologists, and the National Comprehensive Cancer Network[17].

Conclusions

Embryonal carcinoma is a rare germ cell tumour of the ovary and the preoperative diagnosis of which is difficult. To the best of our knowledge, it is the first reported case in our territory.

Recommendations

It is advisable to work within cooperative groups for the treatment of rare tumours and reporting such a cases will probably be the way to move forward in the management of these tumours.

References

1. Ulbright TM. "Germ cell tumors of the gonads: review emphasizing problems in differential diagnosis, newly appreciated, and controversial issues". *Mod. Pathol.* (2005) 18 Suppl 2: S61–79. doi:10.1038/modpathol.3800310. PMID 15761467. PubMed free full text.
2. Lim FK, Chanrachakul B, Chong SM, et al. Malignant ovarian germ cell tumours: experience in the National University Hospital of Singapore. *Ann Acad Med Singapore* 1998; 27(5):657-61. [Medline]
3. Daniel D Mais, article: "eMedicine - Germinoma, Central Nervous System" Daniel D Mais, MD". <http://www.emedicine.com/med/topic2246.htm>. Retrieved 2007-11-03
4. Kurman RJ, Norris HJ. Embryonal carcinoma of the ovary: A clinicopathologic entity distinct from endodermal sinus tumour resembling embryonal carcinoma of adult testis. *Cancer* 1976.38(6):2420- 2433.
5. Mills, S .Sternberg's Diagnostic Pathology. 5th Edition 2009. ISBN 978-0-7817-7942-5.
6. Ovary. In: American Joint Committee on Cancer.: AJCC Cancer Staging Manual. 6th ed. New York, NY: Springer, 2002, pp 275-284.
7. Ovary. In: American Joint Committee on Cancer.: AJCC Cancer Staging Manual, Seventh Edition (2010) published by Springer-Verlag New York, <http://www.cancerstaging.net/>
8. Abu-Rustum, Aghajanian C. Management of germ cell tumors of the ovary. *Semin Oncol* 1998;2:235-242.
9. Naki M.M, Tekcan C, Yılmaz fi.E, Wetherilt L, Berkman S,. Pregnancy After Successful Management of a Malignant Mixed Germ Cell Tumor of the Ovary,

- J Turkish-German Gynecol Assoc, Vol. 7(2); 2006:133-136.
10. Sagae S, Kudo R. Surgery for germ cell tumors. *Semin Surg Oncol* 2000; 19(1): 76-81.
11. Tewari K, Cappuccini F, Disaia PJ, Berman ML, Manetta A, Kohler MF. Malignant germ cell tumors of the ovary. *Obstet Gynecol* 2000;95 (1):128-133.
12. Gershenson DM, Del Junco G, Copeland LJ, Rutledge FN. Mixed germ cell tumors of the ovary. *Obstet Gynecol*. 1984 Aug; 64(2): 200-206.
13. De Backer A, Madern GC, Oosterhuis JW, Hakvoort-Cammel FG, Hazebroek FW. Ovarian germ cell tumors in children: a clinical study of 66 patients. *Pediatr Blood Cancer*. 2006 Apr; 46(4):459-64.
14. okan ozkaya. Mekin sezik. Ali riza aydin. Nilgun kapucuglu et al. mixed germ cell tumor of the ovary mimicking unruptured ectopic pregnancy presenting with usually high serum alpha-fetoprotein level. *Gynaecol Surg*(2005) 2: 307- 310.
15. Kurman RJ, Norris HJ. Malignant germ cell tumors of the ovary. *Hum Pathol* 1977;8(5):551-64.[Medline].
16. Guillem V, Poveda A Germ cell tumours of the ovary. *Clin Transl Oncol*. 2007 Apr;9(4):237-43.
17. Screening for Ovarian Cancer Daniel L. Clarke-Pearson, *N Engl J Med*, 361:170, July 9, 2009.