



Effect of Aspartame on the Rat's Thyroid Gland: A histological and Morphometrical Study

Nali Abdulkader Maaruf (M.Sc)¹, Zana Mustafa Mahmood (M.Sc)²
and Paiman Jamal Muhamad Amen (PhD)

Abstract

Background: The aspartame is a synthetic sweetener has been used for many purposes as an anti-inflammatory agent, antioxidants and hepato protective, its metabolites can be toxic to many organs and several studies on laboratory animals have been made to verify aspartames toxicity which can cause harmful effect after administration for long duration at a dose of 150 mg/kg body weight.

Objective: To evaluate the effect of aspartame on morphometric and histopathological changes of the rat's thyroid gland, since the aspartame sweetener is widely used worldwide.

Patients and Methods: Fifty adult Wister albino rats were used and divided randomly into two groups. The treated group received 150 mg/kg aspartame orally daily after dissolving it in 2cc distilled water and the control group received 2cc distilled water daily orally for eight weeks.

Results: Histological examination of aspartame-treated group showed loss of normal architecture of the thyroid gland. morphometrical measurement showed many follicles were small in size and others had disrupted wall and detached cells in their lumens, there was significant increase in the height of cells and number of follicles with decrease inwidth of the cells.

Conclusion: Administration of aspartame at a dose 150 mg/kg had a significant effect on both histologic and morphometrical structure of the adult rat's thyroid gland.

Key words: Thyroid gland, Aspartame, Histological examination.

Corresponding Author: nail.maaruf@med.hmu.edu.iq

Received: 22th November 2016

Accepted: 29th January 2017

¹ , Department of Anatomy and Histology-College of Medicine-Hawler Medical University- Iraq.

Introduction

Aspartame is an artificial sweetener used by hundreds of millions of people worldwide [1]. Commercial names of the newly introduced Aspartame include 'Nutra Sweet,' 'diet sweet,' 'canderel,' and others. It is about 200 times sweeter than sucrose so much less of it can be used to give the same level of sweetness. This, in turn, lowers the calories in the food or beverages. It is found in more than 6000 products, for

example tabletop sweeteners, candies, soft drinks and some pharmaceuticals such as sugar free cough drop and vitamins [2][3].

Aspartame is composed of phenylalanine (50%), aspartic acid (40%) and methanol (10%). Phenylalanine plays an important role in neurotransmitter regulation; however, it can reach a toxic level in people with a genetic disorder called phenylketonuria (PKU) [4].



Aspartic acid is thought to play a role as an excitatory neurotransmitter in the central nervous system [5][6]. Asparagines, glutamate, and glutamine are formed from their precursor, aspartic acid. Methanol, which forms 10% of the broken down product, is transformed to formate in the body, which may either be excreted or give rise to formaldehyde, diketopiperazine (a carcinogen) or other toxic materials [7][8].

In the gastrointestinal tract the aspartame is metabolized into phenylalanine, methanol and aspartic acid, and then to formaldehyde and Formic acid in many tissues. Formic acid is regarded as a chief metabolite causing harmful damaging effects of acute intoxication by methanol. Long term intake of aspartame leads to histopathological changes in the liver and decrease the deposition of glycogen in hepatocytes [10]. Some researchers have recorded that aspartame does not induce any endocrine-like activities [11][12].

The thyroid gland is one of the largest endocrine glands composed of right and left lobes connected via isthmus. The gland is located in the anterior neck over the trachea which produces thyroid hormones which controls rate of metabolism of the body. In cross section the thyroid follicle had cuboidal follicular cells enclosing a cavity, which usually is filled with a gel-like material called colloid. The nuclei of the follicular cells are rounded in shape. Between follicles, there was interfollicular tissue.

The aim of the study was to detect the morphological and histological changes that occur on the male thyroid gland after administration of aspartame.

Patients and Methods

Fifty Wister Albino male rats approximately 8 – 16 week weighting (200 - 300) gm were used in this study under supervision of staff of Animal House in the College of Medicine, Hawler Medical

University, Erbil city. Housed in plastic cages bedded with wooden chips under stranded laboratory conditions.

All the experiments in the present study were done in the period from January -2016 to Jun -2016.

The study was designed to investigate the effect of aspartame on the male rat's thyroid gland. The rats divided into two groups.

Control group the animals were bred under normal condition, administered distilled water 2 cc orally daily, ten normal healthy albino rats were sacrificed and the samples compared with that of treated animals.

Treated group the animals were received 150 mg/Kg aspartame after dissolving it in 2 cc DW orally daily for eight weeks.

At the end of the experiments the rats were anesthetized with ketamine hydrochloride and xylazine placed in the supine position on the dissection tray, by using string the limbs were tied to stretch the rat out. A mid-line incision (vertical incision) was made from the mandible to the upper end of the manubrium sterni. The strap muscles were retracted carefully, after cutting the sternomastoid and the infrahyoid muscles, thyroid gland was appeared (the thyroid gland was postrolateral to the trachea), The thyroid gland with part of trachea was rapidly removed and fixed overnight in the formal saline (10%) and embedded in paraffin wax for histological studies (H&E staining) in Department of Histopathology, Rizgary Teaching Hospital Erbil.

Sections from the thyroid gland are examined under light microscope; the measurement and calculation of histological sections were carried out using image analyzer (Scope image software 9.0 "H3D" computer system-England, digital binocular compound microscope) in Histology department/College of Science/ Salahaddin University/Erbil.

Regarding H&E stained sections the following parameters will be measured.

Area of follicles was counted in five randomly selected microscopical fields using magnification power at magnification power X400.

Area of colloid was also measured in ten follicles by interactive drawing around the circumference of the follicles at magnification power X400.

The average of follicular cell height and width the height and width of the cells were measured from inside to outside edge at magnification power (400 ×) then the mean of the measurements was calculated for each follicle.

The number of follicles were counted in ten fields (5 from center and 5 from peripheral) using magnification power (40×).

Statistical analysis

The obtained data are entered into Excel at first preliminary calculations are performed. Further statistical analyses are made by using statistical package SPSS version 22. The results are expressed as mean ± standard error of the mean. Differences

between means are estimated for statistical significance using T test (Independent and paired), p value of 0.05 is considered as statistically significance.

Results

Examination of histological sections of all control rats showed the thyroid gland has clearly revealed that the size of the follicles is not at all homogeneous, as larger follicles are usually found in the periphery and smaller ones are found in the central, the thyroid follicles vary greatly in shape, but they are usually irregularly oval to spheroid in shape. Examination of the thyroid gland of rats of the some experimental group showed marked distortion of follicular structure, some sections showed loss of normal and seriously damaged architecture of thyroid gland, the some follicles had exfoliated cells in their lumens due to destruction and necrosis of thyrocytes, vacuolation of the some colloid and cell are present in some areas it was not possible to recognize a follicular pattern (Fig 2, 3, and 4) .

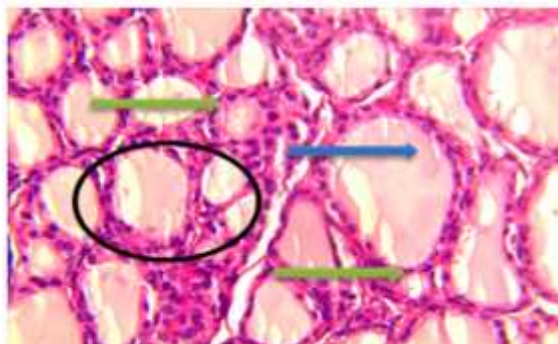


Figure (1): Cross section through the thyroid of control group showing: the thyroid follicles of various sizes (black circle) filled with homogenous colloid (blue arrow) lined by cuboidal or flat cells (green arrow) H&E x400.

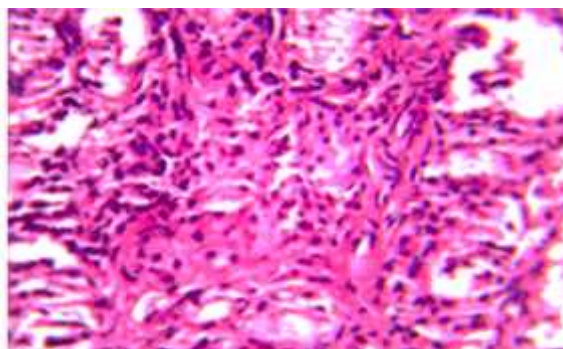


Figure (2): Cross section through the thyroid of treated group showing: distortion of follicular structure, some section showed loss of normal and seriously damaged architecture of thyroid gland H&E x400.

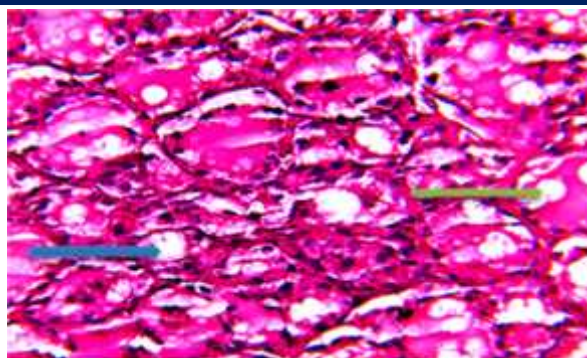


Figure (3): Cross section through the thyroid of treated group showing : the thyroid follicles lined with vacuolated follicular cells (Green arrow) and having vacuolated colloid (Blue arrow) H&E x400.

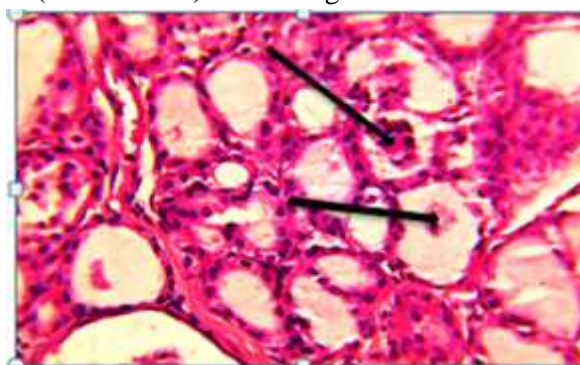


Figure (4): Cross section through the thyroid of treated group showing: the thyroid follicles lined with exfoliated cells in their lumens (Black arrow) H&E x400.

Aspartame treatment showed a significant effect on the morphometrical measurement of the thyroid gland as the following.

The area of colloids: The study showed that there was a highly significant decrease in the percentage of the area of colloid after administration of aspartame at ($p \leq 0.05$) with mean value (44.55 ± 0.6) in comparison to the control male and female rats with mean value $100\% \pm 0.00$; $100\% \pm 0.00$ respectively (Table 1).

The Area of follicles (μm): The study showed that there was a highly significant decrease in the area of follicles after administration of aspartame at ($p \leq 0.05$) with mean value 1539.7 ± 35.78 in comparison to the control rats with mean value 2179.8 ± 42.89 (Table 1; Figure 5).

The average of follicular cell width (μm): The study showed that there was a highly

significant decrease in the width of cell after aspartame administration at ($p \leq 0.05$) with mean value (6.37 ± 0.07) in comparison to the control rats with mean value (8.58 ± 0.003) (Table 1; Figure 6).

The average of follicular cell height (μm): A highly significant increase in the height of cell rats after aspartame administration at ($p \leq 0.05$) with mean value 10.26 ± 0.19 in comparison to the control rats with mean value 6.51 ± 0.02 (Table 1; Figure 6).

The number of follicles per field: A high significant increase in the mean number of follicles were detected in rats after aspartame administration at ($p \leq 0.05$) with mean value 11.45 ± 0.16 in comparison to the control rats with mean 8.8 ± 0.26 value (Table 1).



Table (1): The morphometrical data (µm) in both control and treated group.

Rats		Mean±SE	P-Value
Area of follicle	Control (No. 100)	2179.8±42.8 9	0.00 HS
	Treatment (No.400)	1739.7±35.7 8	
Area of colloid	Control (No.100)	100±0.00	0.00 HS
	Treatment (No.400)	44.55±0.6	
Number of follicle	Control (No.50)	8.8±0.26	0.000 HS
	Treatment (No.2000)	11.45±0.16	
Width of cell	Control (No.500)	10.26±0.19	0.000 HS
	Treatment (No.2000)	6.51±0.02	
Heights of cell	Control (No.500)	6.37±0.07	0.000 HS
	Treatment (No.2000)	8.58±0.003	

No=indicate number follicles or follicular cells measured

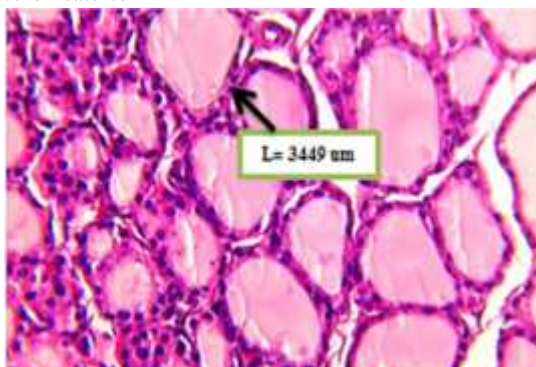


Figure (5): Section showing the method applied by digital binocular compound microscope to calculate the area of follicle H&Ex400.

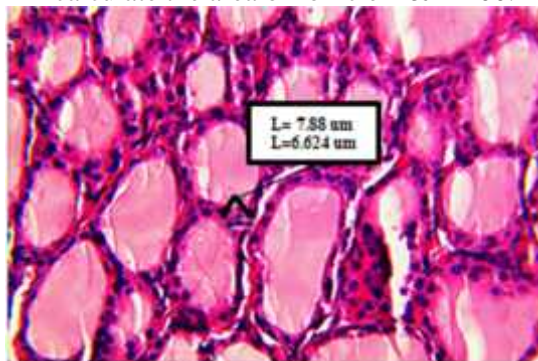


Figure (6): Section showing the method applied by digital binocular compound microscope to calculate the height and width of the follicular cells H&E x400.

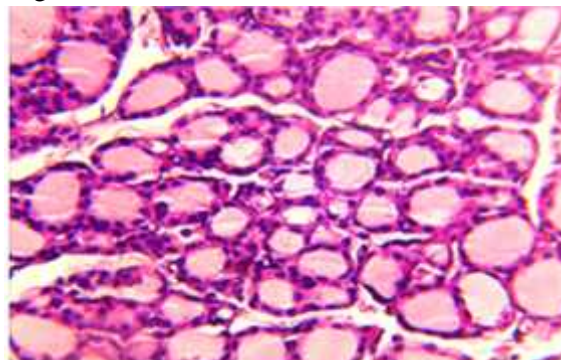


Figure (7): Cross section through the thyroid of treated gland small size of follicles and some of them contain no colloid with a wide interfollicular space with no colloid.



Discussion

The results obtained from the present study showed that the administration of aspartame at a dose 150 mg/kg produce microscopic changes of histology of the thyroid gland, there was marked distortion of architecture of thyroid gland.

The mean follicular area was highly significantly decreased and most of them were smaller in size, with no colloid. These follicles may be atrophic follicles, stimulated or newly formed. These degenerative changes may be due to the direct toxic effect of aspartame on thyroid cells. On the other hand the degenerative changes could occur as a consequence of release of free radicals and production of aspartic acid and methanol. This was agreement with many authors which described the effect of methanol which produce morphological changes of thyroid gland [2]. The possible explanation is that methanol might increase the lipid peroxidation products which cause apoptosis by activation of intrinsic pathway [4]. Moreover methanol has oxidative phosphorylation effects on mitochondria [14].

Many follicles showed epithelial shedding. This shedding can be attributed to cellular distension which resulted in cellular disruption, so this disruption might interfere with the transport of colloid material between the follicular cells and the follicular lumen and this may be represented ultra-structurally or histologically.

Furthermore, the decrease in the follicular area, in the treated group may be due to decrease its content (colloid material) because it is known that the area of a follicle depends on the amount of colloid [15].

The amount of colloid in the follicles was decreased significantly which indicates that thyroid gland was in an active state. Activation of phagocytosis/pinocytosis of the colloid that contains thyroglobulin causes it to decrease in the follicular lumen, thereby

decrease the colloidal area and increase the height of the follicular epithelium [16].

The increase number of the follicles is due to decrease the size of follicles and colloid contents; this comes in agreement with results of Castillo et al (2003) as their study show that increase the colloid contents in the follicle lead to increase the size of follicles and number of follicles.

The columnar cells of the follicular epithelium in the study group indicates increase in the thyroid activity, this effect could be due to the impairment of thyroid function caused by administration of aspartame.

The findings of this study indicated hyper activity of the thyroid gland in aspartame treated rats because follicular epithelium height depends on the functional state of the thyroid gland [17].

On the other hand, it has been recorded that the aspartame causes decrease serotonin level by mechanism of increased supply of phenylalanine [18]. Serotonin is an important substance for release of T3, and activates follicular cells of thyroid by stimulating them to engulf thyroglobulin in the follicular lumen [19][20].

The increase the spaces between the follicles may be due to presence of a large number of atrophic follicles. Increase the intracellular connective tissue may be due to increase in the amount of collagen fibers in response to its over production as a consequence of repeated injury to epithelial cells which regenerate new fibers. Moreover, this expansion may be due to increase of deposition of glycoproteins [21].

In conclusion, administration of aspartame at a dose 150 mg/kg for four weeks causes morphological changes of thyroid gland by decreased in the area of follicles, area of colloid and width of epithelium and increased of number of follicles and height of epithelium histological



changes shows destruction of thyroid follicles.

Conflict of Interest

The author reports no conflicts of interest.

References

- [1] Karol R, Jadwiga EJ. Effects of aspartame metabolites on astrocytes and neurons. *Folia Neuropathologica*. 2013; 51 (1): 10-17 .
- [2] Butchko HH, Stargel WW, Comer CP, Mayhew DA, Benninger C, Blackburn GL, *et al*. Aspartame: review of safety. *Regul Toxicol Pharmacol*. 2002;35(2,Pt 2):S1–S93 .
- [3] S kalska B. Zawarto sztucznych substancji słodzących-aspartamu, acesulfamu K i sacharynianusoduwnapojach dietetycznych. *Wydawn Nauka Technol Jako* 2007; 3: 127-138. [4] Mourad IM. Effect of aspartame on some oxidative stress parameters in liver and kidney of rats. *Afr J Pharm Pharmacol* 2011; 5:678–682.
- [5] Ekong MB. Aspartame: Sweet or Bitter. *The Internet Journal of Health* 2009; 9: 2.
- [6] Roberts HJ. Does Aspartame Cause Human Brain Cancer? *J Adv Med* 1991; 4: 231-241 .
- [7] Abdel-Salam OME, Salem NA, Hussein JS. Effect of aspartame on oxidative stress and monoamine neurotransmitter levels in lipopolysaccharide-treated mice. *Neurotox Res* 2012; 21:245–25.
- [8] Humphries P, Pretorius E, Naudé H. Direct and indirect cellular effects of aspartame on the brain. *Eur J Clin Nutr* 2008; 62:451–462.
- [9] Camfield PR, Camfield CS, Dooley JM, Gordon K, Jollymore S, Weaver DF. Aspartame exacerbates EEG spike-wave discharge in children with generalized absence epilepsy: a double-blind controlled study. *Neurology*. 1992;42:1000–1003.
- [10] Perspect. Tutelyan VA, Kravchenko LV, Kuzmina EE. The effect of aspartame on the activity of rat liver xenobiotic-metabolizing enzymes. *Drug Metab Dispos* 2007; 115(9):1293–1297.
- [11] Portela GS, Azoubel R, Batigália F. Effects of aspartame on maternal-fetal and placental weights, length of umbilical cord and fetal liver: a kariometric experimental study. *Int J Morphol*. 2007; 25:549–554.
- [12] Marielza R, Ismael Martins & Reinaldo Azoubel. Effects of Aspartame on Fetal Kidney: A Morphometric and Stereological Study *Int. J. Morphol*. 2007, 25(4):689-694 .
- [13] Alleva R, Borghi B, Santarelli L, Strafella E, Carbonari D, Bracci M, Tomasetti M. In vitro effect of aspartame in angiogenesis induction. *Toxicol In Vitro* 2011;25:286–293.
- [14] Hartoft MA, Rasmussen K, Buuschar C and Bock T. Estimation of number of follicles, Volume of colloid, and inner follicular surface area in thyroid gland of rats. *Journal of anatomy*. 2005. 207:117-124.
- [15] Castillo V, Lalia J and Junco M. Changes in Thyroid Function in Puppies Fed a High Iodine Commercial Diet. *Colombian Vet J*. 2003. 161:80-84.
- [16] Abeer M. Shady and Fayroz I. Noor El-Deen. Effect of Chlorpyrifos on Thyroid Gland of Adult Male Albino Rats. *Egypt. J. Histol*. 2010. 33: 1110 – 0559.
- [17] Sharma RP, Coulombe RA Jr. Effects of repeated doses of aspartame on serotonin and its metabolite in various regions of the mouse brain. *Food Chem Toxicol* 1987; 25:565–568.
- [18] Morley JE, Raleigh MJ, Brammer GL, Yuwiler A, Geller E, Flannery J, Hershman JM. Serotonergic and catecholaminergic influence on thyroid function in the vervet monkey. *Eur J Pharmacol* 1980; 67:283–288.
- [19] Melander A, Hakanson R, Westgren U. Significance of thyroid mast cells in the regulation of thyroid activity. *Agents Actions* 1973; 3:186.
- [20] Rencüzo ullari E, Tüylü BA, Topakta M, İla HB, Kayraldiz A, Arslan M, Diler SB. Genotoxicity of aspartame. *Drug Chem Toxicol* 2004; 27:257–268.