

## Comparative Ultrasound Study (Transvaginal & Transabdominal) in the Diagnosis of Ectopic Pregnancy

Dalya Falaki\*, Hadeel Mohamed Farook Ahmed\*, Jasim Ibrahim Haichal\*

\*College of Medicine , University of Mosul , Mosul , Iraq

Correspondence: dalyafalaki\_radio@uomosul.edu.iq

(Ann Coll Med Mosul 2024; 46 (1):56-62).

Received: 7<sup>th</sup> March 2024; Accepted: 6<sup>th</sup> April 2024.

### ABSTRACT

**Background:** Ectopic pregnancy is an important life threatening condition and affecting women fertility in our society of Mosul city ,so an early and accurate diagnosis is very necessary to reduce its complication , which can be done by further examining the patient first by less invasive transabdominal ultrasound, and the second is the more invasive but more diagnostic endo vaginal ultrasonography.<sup>1</sup> .

**Objective:** To compare transabdominal and transvaginal ultrasound for the early diagnosis of ectopic pregnancy cases and offer guidance for choosing diagnostic methods in clinical practice.

**Sample & Methods:** Eighty patients admitted to the hospital between February 2023 and August 2023, who received clinical diagnoses and were subsequently confirmed to have ectopic pregnancies, were chosen as the subjects of this research. The ages of the women ranged from 20 to 40 years old, these women underwent sonographic scans at a gestational age of 44.8 days, (6 weeks and 3 days pregnancy). The patients underwent examinations using both transabdominal and transvaginal ultrasound. Ultrasound performance was observed and compared in terms of accuracy, specificity and sensitivity.

Additionally, a comparison was conducted with regards to the determination of the following factors: the presence of adnexal masses, peritoneal liquid, pseudocysts, and any indeterminate echoes.

**Results:** There was a significant difference between the two methods, as transvaginal ultrasound detected extrauterine gestational sacs in 73% of cases, while transabdominal ultrasound identified them in 63% of cases, the sensitivity of transabdominal ultrasound was 73.1%, while the sensitivity of transvaginal ultrasound was higher at 92.3%. The accuracy of transabdominal ultrasound was 73.3%, while transvaginal ultrasound was 90%. Regarding both techniques, the specificity was identical at 75%, transvaginal ultrasound provided a positive correct diagnosis rate equal to 91.25% , but transabdominal ultrasound, was confirmed diagnosis rate of 78.75% using a combination of transvaginal and transabdominal ultrasound offered diagnosis rate equal to 96.25 %.

**Keywords:** Transabdominal ultrasound, transvaginal ultrasound, ectopic pregnancy

### دراسة مقارنة بالموجات فوق الصوتية (عبر المهبل وعبر البطن) في تشخيص الحمل المنتبذ

داليا عبد القادر الفلكي\* ، هديل محمد فاروق احمد\* ، جاسم ابراهيم هيجل\*  
\*كلية الطب ، جامعة الموصل ، الموصل ، العراق

#### الخلاصة

**الخلفية:** يعد الحمل خارج الرحم حالة هامة تهدد الحياة وتؤثر على خصوبة المرأة في مجتمعنا في مدينة الموصل، لذا فإن التشخيص المبكر والدقيق ضروري للغاية للحد من مضاعفاته، والذي يمكن القيام به عن طريق إجراء مزيد من الفحص للمريض أولاً عن طريق الموجات فوق الصوتية عبر البطن الأقل تدخلاً، والثاني هو التصوير بالموجات فوق الصوتية المهبلية الأكثر توغلاً ولكن الأكثر تشخيصاً<sup>1</sup>.

**الهدف:** مقارنة الموجات فوق الصوتية عبر البطن والمهبل للتشخيص المبكر لحالات الحمل خارج الرحم وتقديم إرشادات لاختيار طرق التشخيص في الممارسة السريرية.

**العينة والطرق:** تم اختيار ثمانين مريضاً تم إدخالهم إلى المستشفى بين فبراير ٢٠٢٣ وأغسطس ٢٠٢٣، والذين تلقوا تشخيصات سريرية وتم التأكد لاحقاً من إصابتهم بالحمل خارج الرحم، كمواضيع لهذا البحث. تراوحت أعمار النساء من ٢٠ إلى ٤٠ سنة،

خضعت هؤلاء النساء لفحوصات بالموجات فوق الصوتية عند عمر حمل قدره ٤٤.٨ يومًا (٦ أسابيع و٣ أيام من الحمل). خضعت المريضات للفحوصات باستخدام كل من الموجات فوق الصوتية عبر البطن والمهبل. تمت ملاحظة أداء الموجات فوق الصوتية ومقارنتها من حيث الدقة والنوعية والحساسية. بالإضافة إلى ذلك، تم إجراء مقارنة فيما يتعلق بتحديد العوامل التالية: وجود كتل ملحقة، والسائل البريتوني، والأكياس الكاذبة، وأي أصداء غير محددة.

**النتائج:** كان هناك اختلاف كبير بين الطريقتين، حيث كشفت الموجات فوق الصوتية عبر المهبل عن أكياس الحمل خارج الرحم في ٧٣% من الحالات، بينما حددتها الموجات فوق الصوتية عبر البطن في ٦٣% من الحالات، وكانت حساسية الموجات فوق الصوتية عبر البطن ٧٣.١%، بينما كانت حساسية الموجات فوق الصوتية عبر المهبل أعلى بنسبة ٩٢.٣%. بلغت دقة الموجات فوق الصوتية عبر البطن ٧٣.٣%، بينما بلغت دقة الموجات فوق الصوتية عبر المهبل ٩٠%. فيما يتعلق بكلتا التقنيتين، كانت الخصوصية متطابقة بنسبة ٧٥%، وقدمت الموجات فوق الصوتية عبر المهبل معدل تشخيص صحيح إيجابي يساوي ٩١.٢٥%، ولكن تم تأكيد معدل التشخيص باستخدام الموجات فوق الصوتية عبر البطن بنسبة ٧٨.٧٥%، باستخدام مزيج من الموجات فوق الصوتية عبر المهبل وعبر البطن التي قدمت معدل تشخيص يساوي ٩٦.٢٥%.

**الكلمات المفتاحية:** الموجات فوق الصوتية عبر البطن، الموجات فوق الصوتية عبر المهبل، الحمل خارج الرحم.

## INTRODUCTION

Ectopic pregnancy is a frequently encountered acute abdominal condition and a potential life-threatening complication in pregnant women. Gestation involves the implantation and growth of a fertilized ovum. When the fertilized ovum implants outside the uterus, it is termed an ectopic pregnancy<sup>2</sup>. An ectopic pregnancy occurs when there is a deviation from normal human reproductive physiology, leading to the implantation and development of the conceptus outside the typical endometrial cavity. Unfortunately, this abnormal condition often results in fatal demise. If not promptly diagnosed and treated, an ectopic pregnancy can pose a serious threat to a patient's life.<sup>3</sup>

Discovering pregnancy cases that occur outside the uterus (ectopic pregnancy) presents considerable challenges. Research indicates that as many as 40% of these cases remain undiagnosed during the initial assessment. Additionally, identifying an extra-uterus pregnancy through medical history and physical examination is a formidable task, as both the historical details and physical examination findings lack sensitivity and specificity for an accurate diagnosis. Furthermore, data suggests that even experienced gynaecologists are unable to identify over half of the masses associated with ectopic pregnancies during physical examinations.<sup>4</sup>

There are two ultrasound methods available to assess ectopic pregnancy: the first is the minimally invasive transabdominal ultrasound, and the second is the more invasive yet highly diagnostic endovaginal one.<sup>5</sup>

"Both examinations have their unique advantages; most patients with ectopic gestation can be diagnosed before rupture, but the possibility of misdiagnosis or missed diagnosis still exists.

Transabdominal ultrasound, which is a conventional method for detecting ectopic gestation, is known for its wide scanning area. While transabdominal ultrasound can quickly and accurately detect ascites, it carries a high risk of being influenced by factors like obesity and an inadequately filled bladder. These factors can substantially reduce the diagnostic precision of ectopic gestation."<sup>6</sup>

As a diagnostic method, transvaginal ultrasound (TVS) is currently challenging laparoscopy as the primary choice for diagnosing ectopic pregnancy. The widespread use of high-resolution TVS in the early stages of the first trimester has led to the detection of over 80% of ectopic pregnancies before they rupture. Additionally, more than 50% of these cases are diagnosed in asymptomatic women through ultrasound alone.<sup>7</sup>

Thus the current study is aiming to compare between the two methods of ultrasound, as well as the using of them together.

## METHODOLOGY

To assess the clinical impacts of different ultrasound techniques, specifically transvaginal ultrasound in comparison with transabdominal ultrasound, a total of 80 patients diagnosed with ectopic gestation and admitted to the Al-Zahrawi private hospital, the study start from February 2018 to February 2020 sample were chosen and organized into distinct study groups.

### Subjected Women have been Chosen Purposively to Meet the Following Criteria:

The women's ages varied between 20 and 40 years old, with an average age of  $29.94 \pm 5.06$  years. The women have been scanned at a gestational age of 44.8 days, which is equivalent to 6 weeks and 3 days into their pregnancies.

## Exclusion Standards

All those women who have age older than forty years, or suffered from a membrane immature burst, bleeding associated with placenta previa.

Patients who didn't agree for Transvaginal ultrasound as well as women who has confirmed urogenital or gynecological abnormality.

Beside cases those didn't have histopathology reports, lastly women who had cesarean delivery before to make sure of accuracy.

The cases had clinical complaints include lower abdominal pain, menopause, irregular bleeding from vagina , stomachache, abdominal mass , dizziness , fainting episodes with a history of amenorrhea and their pregnancy test was positive.

The ultrasound exam confirmed either presence of pregnancy outside the uterus as the diagnosis or pointed to it as a differential diagnosis in an adnexal mass definition

All cases have been signed informed consent.

Then transabdominal ultrasound has been conducted by utilizing a probe with power (3.5 MHz) as

this technique uses 3.5–5 MHz curved or straight transducers to offer a comprehensive, wide field of view of the pelvic region, with a particular focus on the upper pelvis <sup>7</sup> where the patient body extended on diagnosis desk ,then the transducer pushed tightly opposite to the skin after using linking gel whether acoustic or auditory to make the transducer more safe for the body and eliminate air pockets that may exist between skin and the transducer , after that it swept over the specific area in pelvic zone in the direction forward and backwards .

In order to identify and assess various aspects, including the morphology of the endometrial lining, blood flow patterns, the size and position of the uterus, and the existence of any liquid, the examination also included checking for the existence of liquid in the pelvic cavity, hepatic recess, bilateral foss iliacus , and splenorenal stump , as well as around the liver.

Additionally, the presence of enclosed masses in the Douglas pouch and its bilateral fossa iliacus was investigated. If liquid was detected, observations were made regarding the scope involved and the condition of sound transmission.

In cases where enclosed masses were identified, an analysis was conducted to assess the relationship between the morphology, size, boundaries, and internal echoes of the enclosed mass and the adjacent organs. Furthermore, the blood flow in the bilateral adnexa area and the trophoblast around the enclosed masses were examined.

- Transvaginal ultrasounds were performed in each woman after evaluating their urinary bladder to be empty immediately after the abdominal scan depending on traditional technique where the cases were placed in the dorsal lithotomy position and be sure to placed their feet in front of the base and perineum next to the edge of the investigation desk.

The ultrasound probe, set at a frequency of 6.0 MHz, was gently inserted into the vaginal area. <sup>8</sup>

A comprehensive examination was conducted by adjusting, advancing, retracting, and turning the probe in multiple directions.

An adnexal mass, embryo, pelvic liquid, primitive cardiac tube pulsations, and an intrauterine pseudo-pregnancy sac were detected to observe any presence of a lump near the fallopian tube, an embryo, liquid in the pelvic area, and early heart tube pulsations

## Ultrasound Diagnostic Standards

An ultrasonic diagnostic result could be considered positive if any of the following conditions were observed:

- Absence of a gestational sac within the uterus, but the presence of a gestational sac echo characterized by a dense echo mass enclosed by an echo-free sac was detected outside of the uterus, and this sac was intact with an embryo and original cardiovascular pulsations inside.
- In the adnexal area, irregular echoes with unclear boundaries and uneven echo masses on one side , or solid or complex mass is observed in this region are observed.
- Extra uterine gestational sac is found, which may contain a fetus, a fetal pole, or an empty sac outside the uterus.
- There's evidence of peritoneal collections.

## Statistical Analysis

During the examination by ultrasound in its two techniques that has been used, specific notes were picked up about the existence of an adnexal mass, Accumulation of fluid in the cul-de- sac and hepatic-renal pouch, along with the presence of a gestational sac, as well as an embryo displaying cardiac activity outside the uterus.

After data collectivity regarding specificity, sensitivity and accuracy, also the values of prediction both positive and negative for individual transabdominal and transvaginal ultrasonic diagnosis of ectopic pregnancy these values were calculated and processed by statistical suitable methods, in order to make a comparison of the two ultrasonographic technique findings.

SPSS program has been used in its 20.0 version to process the data. Chi-square test has been used after classified of patients categories where the data were presented in the form of percentage, the statistical significant difference value was given as  $P < 0.05$ .

## THE RESULTS

### Regarding Image Analysis

In a study involving patients suspected of having ectopic pregnancy, the diagnostic accuracy of transvaginal and transabdominal ultrasonic was compared. In all 80 patients who had a positive pregnancy test, no embryonic sac was found within the uterus. Instead, specific criteria such as a double decidua sign and non-specific internal uterine echoes were used to make identifications.

Transabdominal ultrasound was able to confirm the presence of a gestational sac. However, it could not provide accurate information about the location and size of the gestational sac or the presence of an embryo.

Furthermore, the images did not provide clarity regarding the presence of a Vitelline Sac, the presence of an original cardiac beat, the measurement of endometrial thickness, the presence of pelvic fluid, the assessment of blood flow to the mass, or the existence of ascites (as shown in Figure 1).

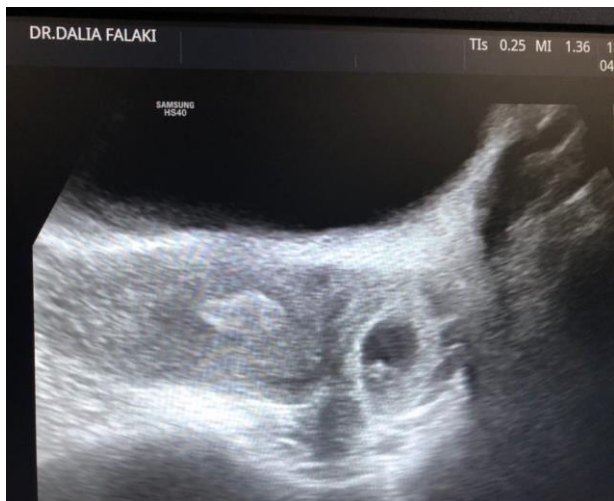

Figure (1): displays the outcomes of a transabdominal ultrasonic, showing an ectopic pregnancy mass with increased echo in the adnexal region.

On the contrary, transvaginal ultrasound proved to be more precise in diagnosing the presence of a pregnancy sac and yolk membrane, besides determining the location and dimensions of the gestational sac. It also provided a clear visualization of the embryo, detected the original fetal heartbeat, and measured both the endometrial thickness and deepness of pelvic fluid, (seen in figure 2).

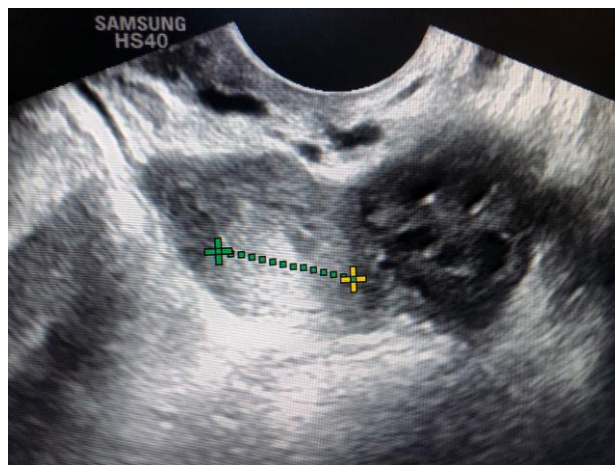

Figure (2): illustrates the findings from transvaginal ultrasonic, revealing an ectopic pregnancy mass located in the adnexal region. There is no apparent gestational sac echo.

### Regarding The Comparison

The comparison of the examination accordance rate for 80 patients with ectopic gestation based on ultrasound testing results:

Ultrasound testing results for a total of 80 patients with ectopic gestation are provided below:

Among these patients, 73 were positively confirmed to have ectopic gestation through transvaginal ultrasound, resulting in a positive correct diagnosis rate equal to 91.25%.

Additionally, 63 patients were diagnosed with ectopic pregnancy, gestation through transabdominal ultrasound, with a positive confirmed diagnosis rate of 78.75%.

Out of the 80 patients with ectopic gestation, 77 were diagnosed with ectopic gestation using a transvaginal and transabdominal ultrasonic together. The positive confirmed diagnosis rate for this combined approach was 96.25 %. Importantly, the detection rate achieved through this combined method was significantly higher compared to using transabdominal ultrasound and transvaginal ultrasound individually, and this difference was statistically significant ( $P < 0.05$ ; see table 1).

Table (1): Comparison for confirmed positive diagnosis rates of ectopic pregnancy for the ultrasound (TAS, TVS, combined)

Type of diagnosis	NO of patients	NO of confirmed results	Positive rate parentage
Transabdominal ultrasonic	80	63	78.25%
Transvaginal ultrasonic	80	73	91.25%
Combined ultrasonic	80	77	96.25%

Transvaginal ultrasound was notably more sensitive in identifying the presence of a gestational sac, whether or not an embryo was present, in comparison to transabdominal ultrasonic.

Adnexal mass determination, peritoneal fluid, pseudocyst and any indeterminate echoes have been nearly comparable between two diagnostic methods (table 2).

Table (2): Comparison for the existence of adnexal mass determination, peritoneal fluid, pseudocyst and any indeterminate echoes

Results	Diagnosis method		P value
	Transvaginal (n= 80)	Transabdominal (n=80 )	
<b>Pregnancy sac</b>			
Exist	48 (60.2%)	27(34%)	0.036
Not exist	32(40%)	52 (65%)	
<b>Adnexal block</b>			
Exist	26.4(33%)	21 (26.25%)	0.390
Not exist	53(66.25%)	58 (72.25%)	
<b>Peritoneal liquid</b>			
Exist	47 (58.75%)	34 (42.25%)	0.152
Not exist	32(40%)	44(55%)	
<b>Pseudo-cyst</b>			
Exist	8(10%)	7(8.7%)	0.501
Not exist	72 (90%)	75 (93.75%)	
<b>Indeterminate echoes</b>			
Exist	16(20%)	10 (12.25%)	0.370
Not exist	64(80%)	68 (85%)	

### Comparison Regarding Accuracy, Specific and Sensitivity

The study's findings indicate that the sensitivity of transabdominal ultrasound was 73.1%, while the sensitivity of transvaginal ultrasound was higher at 92.3%, which suggest that transvaginal ultrasound is more sensitive in detecting ectopic gestation compared to transabdominal ultrasound.

The accuracy of transabdominal ultrasound diagnosis was found to be 73.3%, while transvaginal ultrasound demonstrated a higher diagnostic accuracy of 90%.

Regarding both techniques, the specificity was identical at 75%, and this similarity might be influenced by the limited sample size in the study.

In cases where transabdominal ultrasound failed to detect ectopic gestation, transvaginal ultrasound revealed the presence of a small ectopic sac with a diameter ranging from 5 to 12 mm. These ectopic sacs were characterized by a ring-like structure with a thickness of 3-5 mm and had an echogenic contour, as shown in Figure 3.

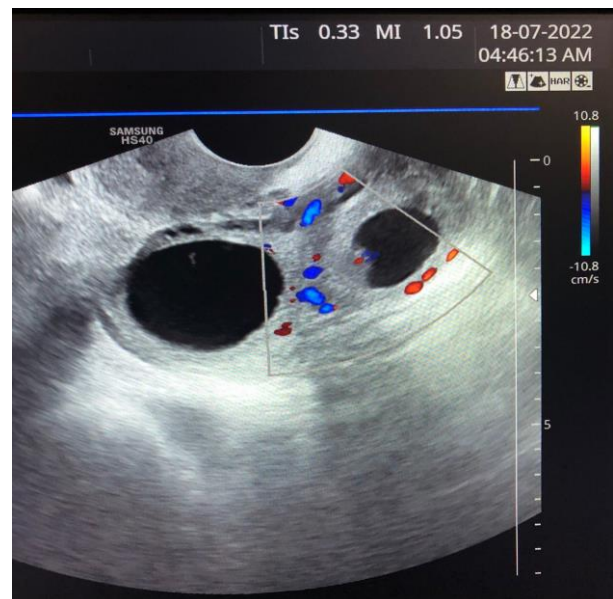


Figure (3): the transvaginal ultrasonographic (TVS) results indicate the presence of a gestational cyst with a fetal pole in adnexal area (in left).

Vaginal scanning proved to be more accurate than abdominal scanning in detecting the sac content, such as the fetal pole and Vitelline Sac, as well as identifying any fluid in the cul-de-sac, as illustrated in Figure 4.

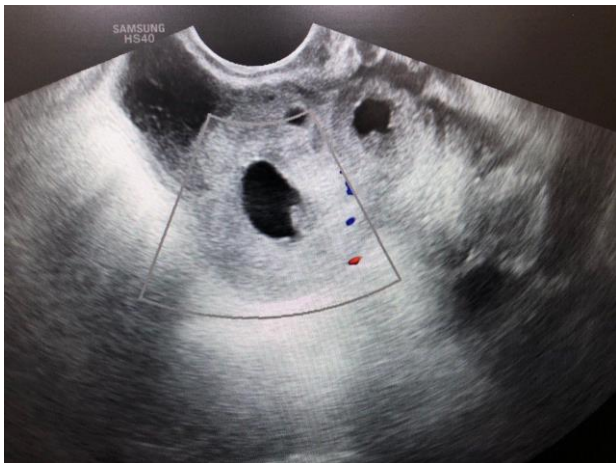


Figure (4) "Transabdominal ultrasound (TAS) revealed an empty uterus with a structure resembles a sac detected in the adnexa. There were no signs of Vitelline Sac in the uterus. However, transvaginal ultrasound (TVS) clearly showed the presence of an embryo inside the liquid-filled sac of pregnancy."

## DISCUSSION

It's important to note that in most cases, especially early in pregnancy, the gestational age may only be 5-6 weeks, and the sac may appear empty on ultrasound because the embryo is still very small and not yet visible.<sup>9</sup>

The incidence of ectopic pregnancy has been on the rise in recent years. Several factors contribute to this trend, including increased work and lifestyle pressures, a higher prevalence of gynecologic inflammation, termination of Pregnancy, and a larger number of younger patients being affected.<sup>10</sup>

The study findings indicate that the sensitivity of transabdominal ultrasound was 78.25 %, while the sensitivity of transvaginal ultrasound was higher at 91.25%. Both techniques exhibited the same specificity, which was 75%, although this similarity might be attributed to the small sample size used in the study. In terms of diagnostic accuracy, transabdominal ultrasound had an accuracy of 73.3%, whereas transvaginal ultrasound demonstrated a higher accuracy rate of 90%.

In the current study, transvaginal ultrasound detected extra uterine gestational sacs in 73% of cases, while transabdominal ultrasound identified them in 63% of cases. This suggests that transvaginal ultrasound was more effective in identifying extra-uterine gestational sacs compared to transabdominal ultrasound in this particular study.

In the study, using both TAS and TVS in common manner had a detection rate of 96.7%, which was significantly bigger than the rates achieved with transabdominal or transvaginal ultrasound alone. This difference was statistically significant ( $P < 0.05$ ), indicating that the combined approach was more effective in identifying the condition under investigation.

Regarding Comparison for the existence of pregnancy sac, adnexal block determination, peritoneal liquid, pseudocyst and any Indeterminate echoes, it was found that TVS percentage in determining the mentioned factors was 60% , 33% , 58.75% , 10% , 20% for each sequent, in contrast of TAS which gave percentages 34% , 26% , 42.25% , 8% , 12.2%.

## CONCLUSION

This study demonstrates that transvaginal ultrasound is more effective than transabdominal ultrasound in the early detection of ectopic pregnancy. However, to minimize the risk of misinterpretation, both methods are recommended together because transvaginal ultrasonic has limitations in terms of its field of view.

## REFERENCES

1. Seow KM, Wang PH, Huang LW, Hwang JL. Transvaginal sono-guided aspiration of gestational sac concurrent with a local methotrexate injection for the treatment of unruptured cesarean scar pregnancy. *Arch Gynecol Obstet.* 2013;288(3):361–366
2. Sowter, M. C., & Farquhar, C. M. (2004). Ectopic pregnancy: an update. *Current Opinion in Obstetrics and Gynecology*, 16(5), 289-293.
3. Kaakaji Y, Nghiem HV, Nodell C, Winter TC. Sonography of obstetric and gynecologic emergencies: Part II, Gynecologic emergencies. *AJR Am J Roentgenol.* 2000 Mar;174(1):651-6. [PubMed] [Reference list]
4. Juliano ML, Sauter BM. Fetal outcomes in first trimester pregnancies with an indeterminate ultrasound. *J Emerg Med.* 2012 Sep;43(4):417-22.
5. Huang JK. Comparison of effect of transabdominal ultrasound and transvaginal ultrasound in the diagnosis of ectopic pregnancy. *Contemp Med.* 2013;19(2):43–44. doi:10.3969/j.issn.1009-4393.2013.1.030
6. Winder S, Reid S, Condous G. Ultrasound diagnosis of ectopic pregnancy. *Australas J Ultrasound Med.* 2011 May;14(3):29-33. doi: 10.1002/j.2205-0140.2011.tb00192.x. Epub 2015 Dec 31
7. Sahdev, A. (2013). Ovary and Adnexa: Imaging Techniques, Anatomy and Normal Findings. In: Hamm, B., Ros, P.R. (eds) *Abdominal Imaging.* Springer, Berlin, Heidelberg. h
8. Zulfiqar, M., Shetty, A., Yano, M., McGettigan, M., Itani, M., Naeem, M., ... & Siegel, C.L. (2021). Imaging of the vagina: Spectrum of disease with emphasis on MRI appearance. *RadioGraphics*, 41(6), 1549-1568.
9. Kirk E, Bottomley C, Bourne T. Diagnosing ectopic pregnancy and current concepts in the management of pregnancy of unknown location. *Hum Reprod Update.* 2014;20(2):250-261. doi: 10.1093/humupd/dmt047
10. Zhang MX, Zhang YL, Wang CJ, Ma CF. Application value of ultrasonic examination in the diagnosis of middle and advanced pregnancy complicated with acute abdominal diseases. *Shandong Med J.* 2009;49:42. doi: 10.3969/j.issn.1002-266X.2009.33.039