

## **Therapeutic Effect of Curcumin on Dermatitis Induced by Acetone in Female Rats**

Ameer Abdul Hussein Abdul AL-Abbas

Shatha Mousa Mlaghee

*Department of Physiology, Biochemistry, and Pharmacology, Faculty of Veterinary Medicine,  
University of Kufa, Iraq*

Corresponding author: AAA, e-mail: [Amырj7529@gmail.com](mailto:Amырj7529@gmail.com), ORCID: [0009-0005-2613-022X](https://orcid.org/0009-0005-2613-022X)

Co-author: SMM, e-mail: [Shatham.mlaghee@uokufa.edu.iq](mailto:Shatham.mlaghee@uokufa.edu.iq) ORCID: [0000-0003-3671-688X](https://orcid.org/0000-0003-3671-688X)

Received date: **1 June. 2023** Accepted: **19 June. 2023** page; (1-8) Published: **30 Dec. 2023**

DOI: <https://doi.org/10.36326/kjvs/2023/v14i212138>

### **Abstract**

The aim of this study was to evaluate different concentration of curcumin on induced atopic dermatitis in female Albino rats, particularly, immunomodulatory effect of curcumin in induced dermatitis by pure acetone 99.9% in female rats. Thirty rats were divided into two groups, control negative group (contain 6 female rats), control positive group (contain 24 female rats) include, dermatitis treated with curcumin 3% group, dermatitis treated with curcumin 5% group, dermatitis treated with pure gel group, the histopathological results of atopic dermatitis treatment by curcumin 5%, showed re-epithelialization activity maintained the epidermis layer, which showed normal thickness. Also, no inflammatory cells were observed in examined skin section. However, sloughing epithelial cells debris was observed above epidermis layer, the curcumin 5% group has a better healing effect comparison with curcumin 3%. determination of Interleukin 13. the study showed a significant decrease ( $P < 0.05$ ) Interleukin 13 level than untreated group (+), pure gel group and there were decrease in other treated groups when compared to the untreated but slight. In atopic dermatitis the curcumin 5% gives best result in comparison with control positive groups because of it gives better therapy results. This study concluded that 5% curcumin effectively treats rat dermatitis, exhibiting superior therapeutic effects within 10 days, with IL-13 serving as a potential efficacy marker, while demonstrating safety and reducing complication risk.

**Keywords: Atopic dermatitis, Curcumin, ELISA, interleukin 13.**

**Copyright:** © 2023 Abdul el-Abbas & Mlaghee. This is an open access article distributed under the terms of the [Creative Commons Attribution License](https://creativecommons.org/licenses/by/4.0/), which permits unrestricted use, distribution, and reproduction in any medium, provided the original author and source are credited.

### **INTRODUCTION**

Atopic dermatitis (AD) is a relapsing chronic inflammatory skin disease characterized by eczematous skin lesions and intense pruritus and The etiology of AD is highly complex, but several lines of evidence suggest that a genetic predisposition leads to a defective skin barrier and a dysregulated immune response [1] environmental triggers such as food allergens, inhalable respiratory

allergens, irritating substances and infectious microorganisms play an important role in the development of AD. Scratching induced by pruritus disrupts skin barrier functions, which also contributes to the development of atopic dermatitis [2].

Atopic dermatitis is the most common atopic disease [3]. Symptoms of atopic dermatitis include erythema, diffuse pruritic skin lesions, and occasional flares. An atopic

immune response involves T cells and antigen-presenting cells (APCs) such as B cells and neutrophils. The antigen-presenting cells bind and present epitopes of allergens to the T cells to evoke cell-mediated responses and maintain immune responses. atopic dermatitis is a Th2-mediated hyper-immune response. In atopic dermatitis, T cells excessively differentiate to Th2 cells and induce both IgE synthesis and mediate mast cell differentiation through Th2 cytokines such as IL-4, IL- 5, and IL-13 [4]. Atopic dermatitis belongs to the spectrum of the atopic disorders, including food allergy, allergic asthma and allergic rhinoconjunctivitis, which are relevant comorbidities, Immunoglobulin E (IgE)-related allergic reactions to environmental allergens represent the common aspect of atopic diseases [5]. The aim of this study was to evaluating the immunomodulatory effect of the curcumin on induced atopic dermatitis in female Albino rats.

## **MATERIALS AND METHODS**

### **Animal ethical statement:**

All procedures used in this study were reviewed and approved by the Scientific Committee of the College of Veterinary Medicine, University of Kufa in compliance with the ethical principles of animal welfare with reference number UK.VET.2023.11201.

Preparation curcumin gel (3%,5%):

1g of Carbopol-940 was dissolved in 100 ml of distal water and placed on a magnetic stirrer for 20 mint at 300° C. Then adjust the PH of the carbopl-940 solution by using triethanolamine (TEA), and left the gel for 24 hours at room temperature, and added 3g from curcumin at 100ml pure gel to prepare curcumin3%,5g from curcumin at 100ml pure gel to prepare curcumin 5% [6].

### **Experimental animal:**

Thirty 12weeksold female Albino rats weighing (150-200g) were supplied from the Faculty of Veterinary Medicine, University of Tikrit. Rats were placed in plastic cages (six rats per cage) with woods shared for bedding. Rats were housed in animal house of Faculty of Science, Kufa University and kept in well-ventilated under controlled temperature

(between 23 °C and 25 C) [7]. Animals were fed with commercial food from the manufacturer green world company. Rats were assigned randomly one weeks before the experimental period for adaptation, during the lab work in the lab animal house use lab coat, cloves and face mask which is surgical disposable. Thirty female rats were divided into five groups, control negative group without any treatment (contain six female rats), control positive group contain 6 female rats, dermatitis group + Curcumin 3% contain 6 female rats, dermatitis group + Curcumin 5% contain 6 female rats, dermatitis group + Pure gel contain 6 female rats, after the final treatment period, the rats were anesthetized through an injection of a mixture of xylazine and ketamine. This allowed for the safe and efficient collection of (3ml) blood samples from each rat via the cardiac puncture technique, using a disposable syringe. The blood was then transferred into a gel tube to separate the serum. The serum was separated by centrifugation at 3000 rpm for 15 minutes before being stored at -20 C° in Eppendorf tubes for ELISA test used to measure concentration interleukin 13 according to [8].

### **Induction of atopic dermatitis:**

Squad the cotton in container (3.5cc) with 99.9% pure acetone was used and it was put on skin for 5 minute for six days consequently to induce atopic dermatitis, acetone has been used due to its desiccating effect (increasing transcutaneous water loss) on the skin and due to the principle of acetone action, the effect on the skin is to alter the cutaneous barrier of the skin causing the destruction of the filaggrin protein and skin tissue [9].

### **Statistical analysis:**

GraphPad Prism version 8.0.2 (263) was used to do the statistical analysis of the experimental data. One-way and two-way ANOVA were employed to assess the significant differences within and between groups. The results were presented as mean  $\pm$  standard errors (SE), and statistical significance was defined as a  $P < 0.05$  [10].

**RESULTS**

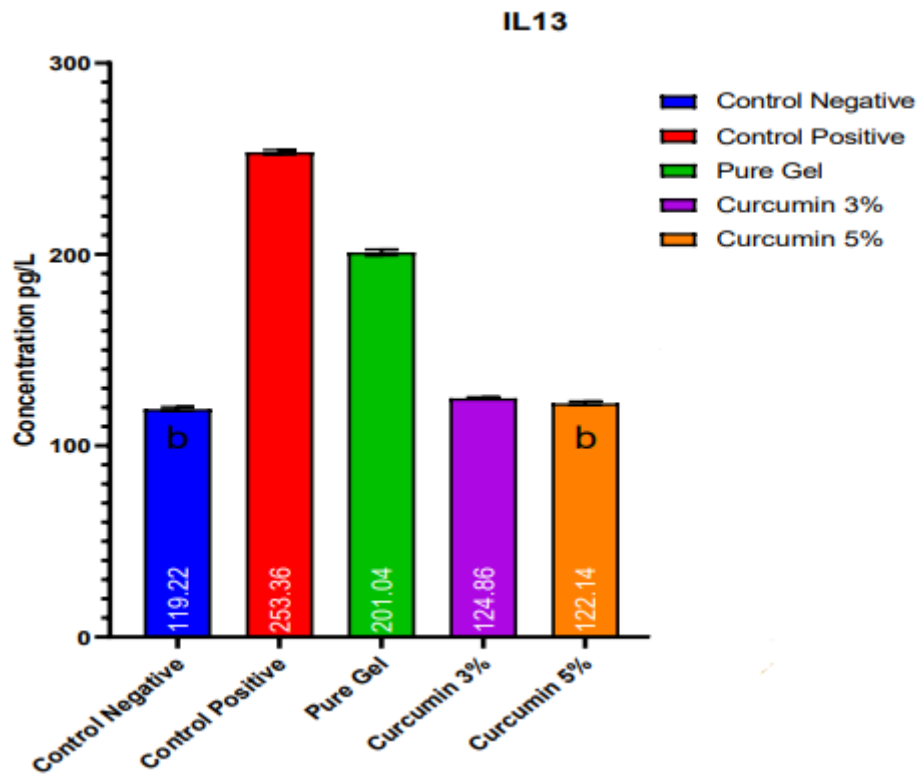
**Determination of serum interleukin 13 (pg/ml):**

Determination the level of Interleukin-13 serum samples results that used in this study show significant increase (P<0.05) in control positive compared with the negative group there is significant different present. When

comparing the treated groups with the positive group there is a significant different (P<0.05) the (curcumin 5%) and (curcumin 3%) and very low different with pure gel. Also comparing treated groups between them, significant increase (P<0.05) pure gel, but curcumin 3% and curcumin 5% very low different, and no significant between control negative and curcumin 5% as shown in table 1, and in figure 1, shown each group contain mean ± stander error.

**Table 1.** Groups of Interleukin 13 (mean± stander error).

Group	Control Negative	Control Positive	Pure Gel	Curcumin 3%	Curcumin 5%
mean±S.E	119.2±0.45	253±0.55	201±0.67	124.9±0.22	122.1±0.44

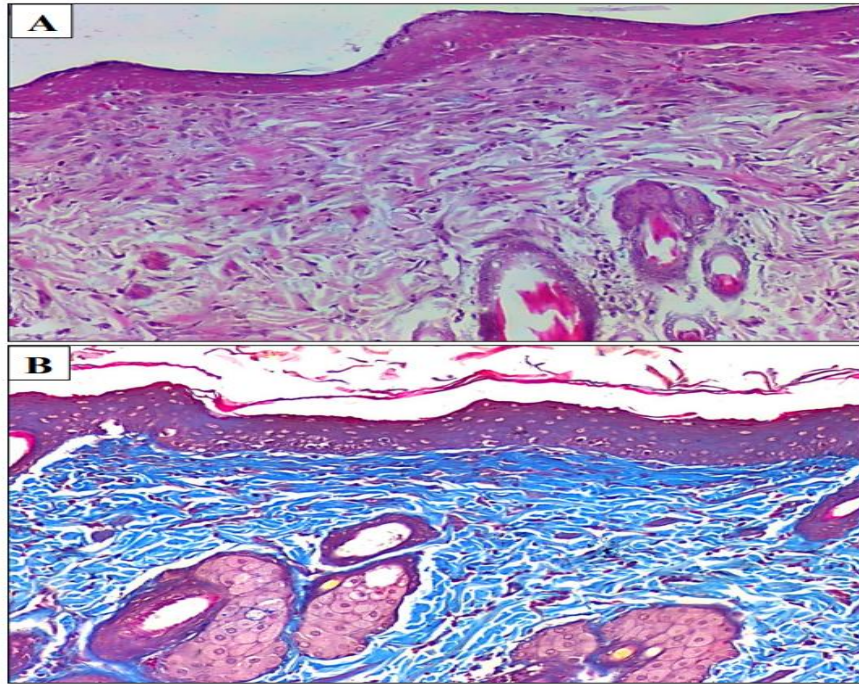


**Figure 1.** The serum of Interleukin 13 concertation (pg/ ml) in female rats. (The different small letters denoted significance between groups, P<0.05.)

**Histological changes:**

The histology of the skin rats from control negative groups showed normal morphological appearance epidermis layer of skin, and a fibroblastic connective tissue layer

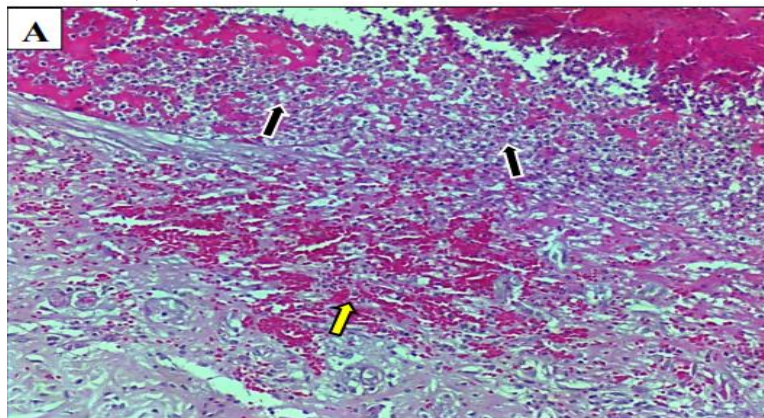
(dermis), The blue-staining keratohyalin granule also showed up in this section illustrated in the figure (2 A and B).



**Figure 2 A,B.** Photomicrograph back area of normal skin (control negative) female rat(100x).

After six days from use pure acetone (99.9%), atopic dermatitis and severe infiltration of inflammatory cells (black arrow) above the skin layers and in dermis layer with presence of hemorrhage (yellow arrow) were observed

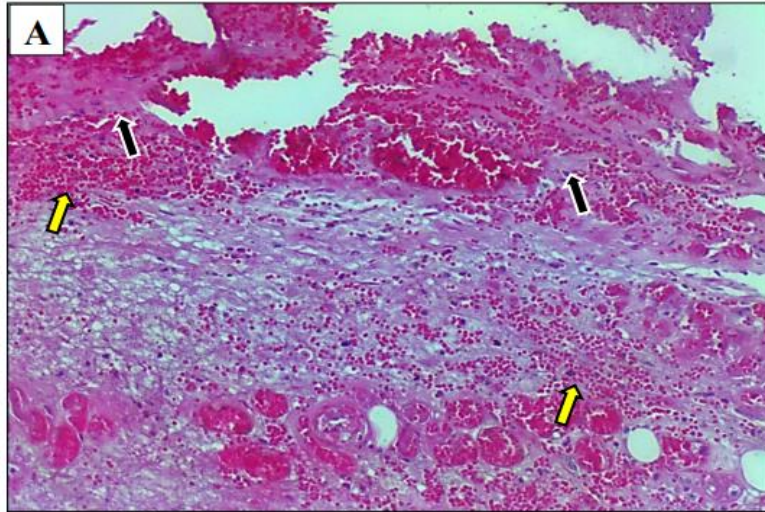
in affected area. Note disappearing of epidermis layer due to severe necrosis of epithelial cells of epidermis layer. H&E. A: 100x. Figure 3



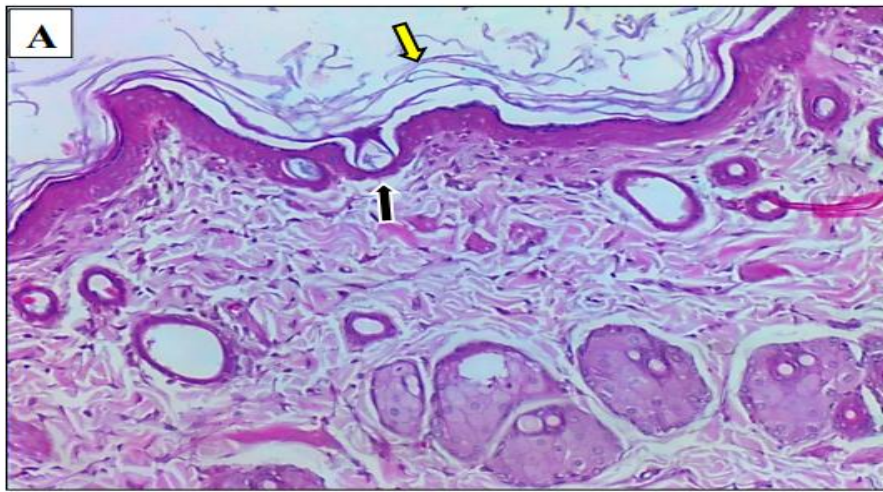
**Figure 3.** Photomicrograph back area of skin (control positive) female Rats(100x).

Severe infiltration of inflammatory cells (black arrow) above the skin layers and in dermis layer with presence of hemorrhage (yellow arrow) were observed in affected area. Note

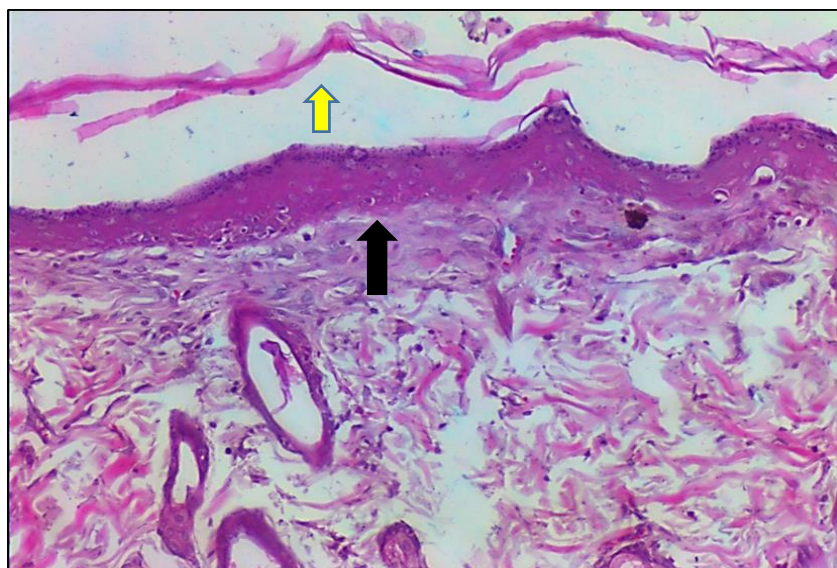
disappearing of epidermis layer due to severe necrosis of epithelial cells of epidermis layer. A: H&E as figure 4



**Figure 4.** Photomicrograph back area of skin treatment by (pure gel) female Rats(100x). Thin epidermis layer (black arrow) was observed, where one of two layer of epithelial cells of epidermis with presence of debris of sloughing epithelial cells (yellow arrow). A: H&E as figure 5



**Figure 5.** Photomicrograph back area of skin treatment by (curcumin 3%) female Rats(100x). epithelialization activity maintained the epidermis layer (black arrow), which showed normal thickness. Also, no inflammatory cells were observed in examined skin section. However, sloughing epithelial cells debris (yellow arrow) was observed above epidermis layer. A: H&E as figure 6



**Figure 6.** Photomicrograph back area of skin treatment by (curcumin 5%) female Rats(100x).

## DISCUSSION

The present study was conducted to investigate the therapeutically and immunomodulatory effects of curcumin concentration 3%, 5% on acetone induced atopic dermatitis in comparison with control positive groups for atopic dermatitis. Acetone was used to induce atopic dermatitis, also referred to as dimethyl ketone or 2-propanone, Acetone is readily absorbed by ingestion, inhalation and skin contact [11]. less risky than other chemical solutions, with perfect atopic dermatitis on day six [12]. curcumin is a promising therapeutic agent due to its natural antioxidant properties and strong anti-inflammatory and antimicrobial functions and the reduce water loss from wound These finding were agreement with [13] Curcumin that has anti-inflammatory effect by inhibiting nuclear factor kappa-light-chain-enhancer of activated B cells via suppression of I $\kappa$ B kinase (IKK), which prevents the NF- $\kappa$ B translocation to the nucleus, and stimulating apoptosis [14], NF $\kappa$ B is activated by oxidative stress and inflammatory agents [15]. while pure gel is no treated atopic dermatitis compared with control negative, no effect on IL13.

Histopathological examination showed normal skin appearance with typical squamous epithelial cells as well as a fibroelastic type of connective layer was seen in the control (-) group, the eczematous skin indicated acetone-

induced damage which characterized as atopic dermatitis. Skin index of damage caused by acetone was showed the obvious density and lengthening of skin's external layer due to acetone action, that destroys the proteins like *pro filaggrin*, resulting in a destruction in the barrier of skin and raising trans epidermal water lack, in the end leading to skin dehydration, as well as infiltration of inflammatory cells, after use curcumin the animal stops scratching, the damaged region still has redness, Also, the skin would become very smooth at touches and complete healing in effected area, the color of skin return to normal, hair grow back [16].

In chemotherapy, curcumin has positive effects and is a chemosensitizer and also reduces toxic and adverse effects of chemotherapeutic, they have a variety of mechanisms of action that contribute to their efficacy in treating AD, which include anti-inflammatory, antiproliferative, and immunosuppressive effects, More specifically, they suppress the quantity and activity of many inflammatory cell types and cytokines, including neutrophils, monocytes, lymphocytes, Langerhans cells, interleukins (ILs, including IL-1 $\alpha$ , IL-1 $\beta$ , IL-2), tumor necrosis factor (TNF), and granulocyte-monocyte colony stimulating factor. They also induce anti-inflammatory proteins, such as lipocortin, vasocortin, and vasoregulin, topical

corticosteroids can effectively prevent AD flares, as compared to proactive use of nonmedicated vehicle [17].

### CONCLUSIONS

The following conclusions have been drawn from the study's results, the curcumin 5% gives best result in comparison with control positive groups because of it gives better therapy results, the IL-13 in rats could be used to detect the curcumin efficacy in skin treatment, curcumin gives the best therapy results in ten days of administration period, dermatitis in rats can be induced by pure acetone 99.9%, the curcumin is so useful to treat atopic dermatitis in rats, curcumin did not show harmful effects on the rats throughout the administration study period (10 days), the curcumin reduces the risk of complication.

### CONFLICT OF INTEREST

The researchers declare that there is no conflict of interest in the publication of this paper.

### ACKNOWLEDGMENT

We would like to thank and appreciate to the College of Veterinary Medicine at the University of Kufa, especially the Department of Physiology, Biochemistry, and Pharmacology, for the facilities they provided to complete this research.

### REFERENCES

- [1] Dicesare, Antonella; DI Meglio, Paola; Nestle, Frank O. A role for Th17 cells in the immunopathogenesis of atopic dermatitis?. *Journal of Investigative Dermatology*, 2008, 128.11: 2569-2571.
- [2] Kuramoto, Takashi, et al. Atopic dermatitis-like skin lesions with IgE hyperproduction and pruritus in KFRS4/Kyo rats. *Journal of dermatological science*, 2015, 80.2: 116-123.
- [3] Darlenski, Razvigor, et al. Atopic dermatitis as a systemic disease. *Clinics in dermatology*, 2014, 32.3: 409-413.
- [4] Lee, Dae-hyo, et al. Anti-inflammatory effects of natural flavonoid diosmetin in IL-4 and LPS-induced macrophage activation and atopic dermatitis model. *International Immunopharmacology*, 2020, 89: 107046.
- [5] Thyssen, Jacob P., et al. Assessment of major comorbidities in adults with atopic dermatitis using the Charlson comorbidity index. *Journal of the American Academy of Dermatology*, 2017, 76.6: 1088-1092.
- [6] Krishna Kumar, Nitish Kumar, Arpita Singh AG. Development and Evaluation of Curcumin Emulgel with Cumin Oil for Topical Application. *Clinical Pharmacology & Biopharmaceutics*, 10(9), 1–7. Retrieved from <https://www.omicsonline.org/open-access/development-and-evaluation-of-curcumin-emulgel-with-cumin-oil-for-topical-application-117190.html>  
<https://www.omicsonline.org/peer-reviewed/development-and-evaluation-of-curcumin-emulgel-with-cumin-oil-for-topical-application,2021,19:1-7>.
- [7] Al-haidary, Dher Muhyaddin Taher; Naqi, Mohammad Taha. Comparative histophysiological study the effective treatment of induced eczema in rats that treated with Lanolin and glycerine with Vaseline in rats. *Kufa Journal For Veterinary Medical Sciences*, 2020, 11.2: 63-69.
- [8] Zhou, Meihua; SUI, Hongfeng. Effect of total glucosides of paeony on the changes of IL-4 and ICAM-1 levels in eczema mouse model serum. *Experimental and therapeutic medicine*, 2019, 17.3: 1545-1550.
- [9] Durrani, Timur, et al. Solvent-based paint and varnish removers: a focused toxicologic review of existing and alternative constituents. *Journal of Applied Toxicology*, 2020, 40.10: 1325-1341.
- [10] Brown, Angus M. A new software for carrying out one-way ANOVA post hoc tests. *Computer methods and programs in biomedicine*, 2005, 79.1: 89-95.
- [11] Memarzia, Arghavan, et al. Experimental and clinical reports on anti-inflammatory, antioxidant, and immunomodulatory effects of Curcuma longa and curcumin, an updated and comprehensive review. *BioFactors*, 2021, 47.3: 311-350.
- [12] Deng, Benliang, et al. Curcumin treatment enhances bioactive metabolite accumulation and reduces enzymatic browning

in soybean sprouts during storage. *Food Chemistry*: X, 2023, 17: 100607.

[13] Zia, Aliabbas, et al. The role of curcumin in aging and senescence: Molecular mechanisms. *Biomedicine & Pharmacotherapy*, 2021, 134: 111119.

[14] Suryawati, Nyoman, et al. Moisturizing Nanoemulgel of Turmeric (*Curcuma longa*) Rhizome Extract Ameliorates Atopic Dermatitis-like Skin Lesions in Mice Model through Thymic Stromal Lymphopoietin, Interleukin-13, and Interleukin-17. *Biomolecular and Health Science Journal*, 2022, 5.2: 81-87.

[15] Tavakol, Shima, et al. The impact of the particle size of curcumin nanocarriers and the ethanol on beta\_1-integrin overexpression in fibroblasts: A regenerative pharmaceutical approach in skin repair and anti-aging formulations. *DARU Journal of Pharmaceutical Sciences*, 2019, 27: 159-168.

[16] Joodaki, Hamed; Panzer, Matthew B. Skin mechanical properties and modeling: A review. *Proceedings of the Institution of Mechanical Engineers, Part H: Journal of Engineering in Medicine*, 2018, 232.4: 323-343.

[17] Del rosso, James; Friedlander, Sheila Fallon. Corticosteroids: options in the era of steroid-sparing therapy. *Journal of the American Academy of Dermatology*, 2005, 53.1: S50-S58.

[18] Schmitt, J., et al. Efficacy and tolerability of proactive treatment with topical corticosteroids and calcineurin inhibitors for atopic eczema: systematic review and meta-analysis of randomized controlled trials. *British journal of dermatology*, 2011, 164.2: 415-428.