

Review about *Sarcocystis* in Ruminants in Iraq

Howaida Hamle Abed* and Ali Issa Fadhil

Department of Parasitology, College of Veterinary Medicine, University of Baghdad, Iraq

*Corresponding Author: howaida.h@covm.uobaghdad.edu.iq

Doi: <https://doi.org/10.37940/AJVS.2022.15.2.1>

Received: 6/7/2022 Accepted:21/10/2022

This article is licensed under a CC BY (Creative Commons Attribution 4.0)

<http://creativecommons.org/licenses/by/4.0/>.

Abstract

This review was conducted to give an overview of the current state of knowledge on *Sarcocystis* infectivity, pathogenicity, and transmissibility here, based on our current understanding virulence. *Sarcocystis* species are parasitic protozoa. *Sarcocystis* is about 220 species that may be found all over the world. Heteroxen and protozoan parasites *Sarcocystis* spp. develop cysts in intermediate hosts' tissues and are thrown out as *sporocysts* with definitive hosts. Herbivores, which are their intermediate hosts, have cysts in their hearts, oesophagus, diaphragms, tongues, jaws, and other skeletal muscles. In general, canid-transmitted *Sarcocystis* spp. are more pathogenic than felid-transmitted *Sarcocystis* spp. Fever, anemia, weight loss, decreased wool quality and milk output, and abortion are all signs of intermediate hosts.

Keywords: *Sarcocystis*, Ruminant, Heteroxen , Cysts

مقال عن طفيلي *Sarcocystis* في المجترات في العراق

الخلاصة

هدف هذا المقال الى تقديم لمحة عامة عن العدوى بمرض الحويصلات الصنوبرية ، والإمراضية ، وطريقة الانتقال ، بناءً على فهمنا ضراوة الإصابة. طفيلي داء الحويصلات الصنوبرية هو احد الاوالي الطفيلية ويضم حوالي 220 نوعا تم تسجيلها في جميع انحاء العالم. وهي من الطفيليات التي تحدث اكياس في انسجة المضيف الوسيط اما في المضيف النهائي فيتم طرحها على شكل اكياس بوغية. تعتبر الحيوانات اكلات الاعشاب المضيف الوسيط لهذا الطفيلي حيث تتواجد الاكياس في القلب والمريء والاعشبية واللسان والفكين والعضلات الهيكل العظمي الاخرى . بشكل عام يسبب طفيلي داء الحويصلات الصنوبرية الحمى ، وفقر الدم ، وفقدان الوزن ، وانخفاض جودة الصوف وإنتاج الحليب ، والإجهاض كلها علامات تظهر على المضيف الوسيط.

Introduction

Sarcocystis spp. is a protozoan intracellular parasite of the phylum Apicomplexa that is found across the Protista kingdom.

Miescher discovered long, thin, white cysts in the domestic mouse muscles in Switzerland in 1843 and gave it the name *Sarcocystis* spp. (1). For the

next 20 years, these cysts were known as "Miescher's tubules." Sarcocysts were also known as "milky white threads." Similar organisms were found in swine by Kühn in 1865 and termed *Synchytrium miescherianum*. Lankester considered the genus for the first time in 1882 (1). The *Sarcocystis* life cycle was unknown until 1972, *Sarcocystis* has a heteroxenous life cycle, which means there are two types of hosts: definitive and intermediate. (2).

Classification of *Sarcocystis*

According to (3), the *Sarcocystis* was classed as follows:

Kingdom: *Protista*

Phylum: Apicomplexa

Class: Conoidasida

Order: Eucoccidiorida

Suborder :Eimeriorina

Family: Sarcocystidae

Genus: Sarcocystis

Sarcocystis species in ruminants

Sarcocystis infects sheep in a variety of ways, some of which are transmitted by canids and others by felines (cats) (4). Four *Sarcocystis* species have been identified in sheep, including *Sarcocystis ovicanis* (*Sarcocystis tenella*) and *Sarcocystis arietcanis*, two pathogenic *Sarcocystis* spp. that are transmitted by dogs.

Sarcocystis medusiformis, *Sarcocystis ovifelis* (*Sarcocystis gigantea*), and *Sarcocystis ovifelis* (*Sarcocystis gigantea*) are felid-transmitted non-pathogenic *Sarcocystis* species. *Sarcocystis capricanis* and *Sarcocystis hircicanis* form microscopic pathogenic cysts, while *Sarcocystis caprafelis* in goats develop macroscopic non-pathogenic cysts (1,4)

Cattle are intermediate hosts for *S. cruzi*, which has canids as its definitive host; *S. hirsute* has cats as their final host; and *S. hominis* has humans as its final host. Water buffaloes are intermediate hosts for *S. buffalonis* and *S. fusiform* that have cats as their final hosts. One species known to infect camels is *Sarcocystis cameli*, which is transferred by dogs (4,5,6).

Diagnosis

Trichnoscropy, Muscle Mincing Method, Histological Examination, Acid Pepsin Digestion Test, and Electron Microscope are some of the laboratory methods used to diagnose Sarcocystosis (7,8,9). Molecular approaches have been substantially developed in research facilities over the last decade, resulting in the polymerase chain reaction (PCR) method becoming a significant tool for the identification of *Sarcocystis* spp (10,11).

Life Cycle

Sarcocystis is a parasitic protozoa that is found in a wide spectrum of vertebrates and is one of the most widely spread in nature. Sarcocysts can be found in animals' muscles and central nervous

systems. *Sarcocystis* have a two-host life cycle that requires the presence of both an intermediate (herbivore) and definitive (carnivore) host for the lifecycle to be completed (12).

When microgametes and macrogametes reproduce in the epithelial cells of the ultimate host, the sexual stage cycle begins. The sporulated oocysts are formed in the host. When the thin-walled sporulated oocysts shatter during passage, the sporocysts are discharged. In the feces, the final host excretes both sporocysts and sporulated oocysts. (13, 14) . The intermediate host infected via contamination of feed or water with sporocysts , sporozoites excise from the sporocysts, sporozoites reach to the endothelium cells after penetrate the intestinal mucosa ,after that schizonts forming the first stage of reproduction which asexual stage begins (15) . Sarcocysts are formed when merozoites are liberated from schizonts and go to muscle tissue. Merozoites split into pairs and create metrocytes within the cyst tissues. Metrocytes mature into banana-shaped bradyzoites, which divide slowly and infect their final hosts. (16) . The bradyzoites penetrate the mucosa and develop into macrogametes and micrgametocytes in the intestinal epithelial cells when the final host (a carnivore) eats muscle tissue containing infective bradyzoites. (Fig. 1) (17).

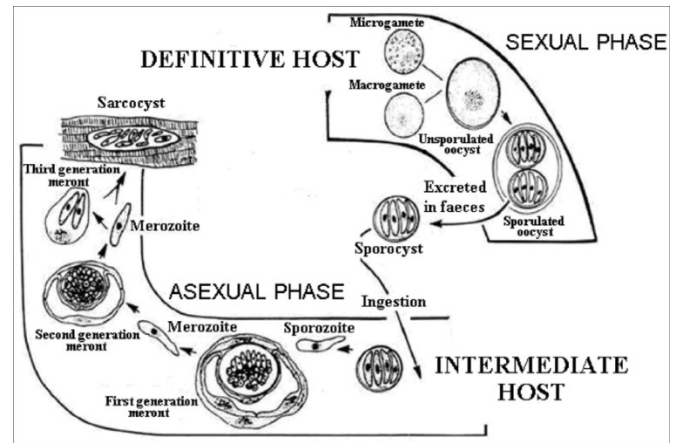


Figure 1: Diagram the Life cycle of *Sarcocystis* (12).

Review in previous studies Distribution of *Sarcocystis* species in ruminants in Iraq.

Several investigations on the prevalence of Sarcocystosis in ruminants in Iraq have indicated that high cases of infection have been documented for both microscopic and macroscopic cysts. (18) discovered that the percentage of infection in goats in the governorate of Baghdad has reached 100%; . (19) found that 97% of sheep infected with microcystic *Sarcocystis*, (20) discovered that the percentage of macroscopic and microscopic infection in goats in Al Sulaymaniyah was 33.6% and 97.4 %, respectively, and (21) found that 100 % of goats infected with microcystic *Sarcocystis*., (22) found that 66.55% of slaughtered cattle at Babylon abattoir had microscopic *Sarcocystis*, which detected by trichoscopy, while histological technique detected 70% was infected. Other research on different livestock animals in Iraq by (8) to detect the prevalence of *Sarcocystis* spp. in Baghdad governorate, Iraq, The percentages of macroscopic infection were 4.1 % in (605 sheep),

33.6% in (826 goats), 0.2 %in (1080 cattle), 15.6 % in (580 water buffaloes), and 0.3 % in (36 camels), respectively, while the prevalence percentages of microscopic infection were 97.0, 97.4, 97.8, 82.9, and 91.6 for the previous hosts. (23) found that the percentage of microscopic infection in cows increased with age, reaching 100%.

Pathogenesis and clinical sings of *Sarcocystis* in intermediate host

In general, not all *Sarcocystis* species are harmful to intermediate hosts. *Sarcocystis* species carried by dogs more pathogenic than those transmitted by cats (1).

The severity of the infection in domestic animals is determined by the species of parasite, the amount of digested sporocysts, as well as the animal's age and immune status(15).Fever, anorexia, tachypnea, tachycardia, encephalitis, encephalomyelitis, reduced milk production, diarrhea, weakness, anemia, icterus and abortion or the birth of a stillborn fetus in pregnant mammals (24).

During the anemic phase, serum bilirubin, lactic dehydrogenase, alanine aminotransferase, sorbitol dehydrogenase, and creatinine phosphokinase are all raised for brief durations, as the infection progresses, blood urea nitrogen levels rise, growth is harmed, animals get hyper excitable, hyper salivate, and lose hair, emaciation is observed in some animals, and some have nervous signs such as decumbency, cycling gait, and death (25).

Conclusion:

Sarcocystis is a protozoan parasite that causes acute and chronic illnesses in ruminants as intermediate hosts. Canid transmitted *Sarcocystis* species are more pathogenic than felid-transmitted *Sarcocystis* species. Reduced milk yield, miscarriage, central nervous system symptoms, and mortality, resulting in large economic losses. As a result, health precautions must be taken to avoid high economic losses.

Acknowledgement

We would like to thank Reviewers for taking the time and effort necessary to review the manuscript. We sincerely appreciate all valuable comments and suggestions, which helped us to improve the quality of the manuscript.

Conflicts of Interest

The authors declare no conflict of interest.

References

- 1- Dubey JP, Calero-Bernal R, Rosenthal BM, Speer CA, Fayer R . *Sarcocystosis of animals and humans*, 2nd edn. 2015 .CRC Press, Boca Raton, Florida, USA
- 2- Elmishmishy B M M. “Molecular Characterization of *Sarcocystis* Species in Sheep PhD Thesis, M. Univ.2017.
- 3-Levine ND . *The Protozoan Phylum Apicomplexa*,2018; vol 2. CRC Press, Boca Raton, Florida, USA
- 4-Davood A , Elahe N,Mona H, Mohammad R, · Ahmad D, Seyyed Ali Sh, · Abdol Sattar P, Shirzad Gh,Shahabeddin S,Dariush S, Reza S, ·

- Seyed Abdollah H, · Abolghasem S. Sarcocystosis in Ruminants of Iran, as Neglected Food-Borne Disease:A Systematic Review and Meta-analysis . *Acta Parasitologica*.2020 ; <https://doi.org/10.2478/s11686-020-00210-5>.
- 5-Fayer R. *Sarcocystis* spp. In human infections. *Clinical Microbiology Reviews*. 2004;17(4), pp.894-902.
- 6-Hamidinejat H, Jalali M H R,Gharibi D, Molayan P H.. Detection of *Sarcocystis* spp.in cattle (*Bos taurus*) and water buffaloes(*Bubalus bubalis*) in Iran by PCR–RFLP. *J ParasitDis* .2015 ;(Oct-Dec.) 39 (4):658–662 .
- 7-Hilali M , El-Seify M, Zayed A, El-Morsey, A, Dubey J P. *Sarcocystis dubeyi* (Huong andUggla, 1999) infection in water buffaloes(*Bubalus bubalis*) from Egypt. *The Journal ofparasitology*.2011: Jun;97 (3):527-8 .
- 8-Faraj, A.,Kawan, M. Detection of *Sarcocystosis* in some wild birds. *Iraqi Journal Vet. Med*. 2012 ;36:56-70.
- 9-Mohamed M, Fatma M , Hiekal A, El-Hoshy S, Radwan M and Abd El Naby W.(2016). Characterization of *Sarcocystis* Species Based on Traditional and
- 10-Rubiola S, Chiesa F, Zanet S and Civera T. Molecular identification of *Sarcocystis* spp. in cattle: partial sequencing of Cytochrome C Oxidase subunit 1 (COI). *Italian Journal of Food Safety*.2019; 7:7725.
- 11-Alina M, Dalius B, Naglis G , Evelina J , Vytautas J;, Egle R, Lukošien · and Petras P. Molecular Identification of *Sarcocystis* Species in Sheep from Lithuania .2022; *Animals* 2022, 12, 2048. <https://doi.org/10.3390/ani12162048>.
- 12-Dubey J, Mor´e G, Wilpe E, Calero-Bernal R, Verma S and Schares G. *A Sarcocystis rommeli*(Apicomplexa: Sarcocystidae) from cattle (*Bos taurus*) and its differentiation from *Sarcocystis hominis*, *Journal of Eukaryotic Microbiology*.2016: 63(1): 62–68.
- 13-Olias P, Gruber A, Heydorn A, Kohls A, Hafez H and Lierz M. Unusual biphasic disease in domestic pigeons (*Columba livia f. domestica*) following experimental infection with *Sarcocystis calchasi*. *Avian Dis*.2010: 54:1032-1037.
- 14-Reissig EC, Moré G, Massone A, Uzal FA. Sarcocystosis in wild red deer (*Cervus elaphus*) in Patagonia, Argentina. *Parasitol Res*. 2016;115:1773–1778.
- 15-Dubey J. Van Wilpe E, Calero-Bernal R and Verma S. *Sarcocystis heydorni*, (Apicomplexa: Sarcocystidae) with cattle (*Bos taurus*) and human (*Homo sapiens*) cycle. *Parasitology Research*. 2015b :114: 4143–4147.
- 16-Tappe D, Abdullah S, Heo C, Kannan Kutty M and Latif B. Human and animal invasive muscular Sarcocystosis in Malaysia - recent cases, review and hypotheses. *Trop. Biomed*. 2013: 30: 355-366.
- 17-Dubey J, Calero-Bernal R, Rosenthal B, Speer C, and Fayer R. Sarcocystosis of animals and humans, 2nd ed.Boca Raton, Florida: CRC Press.2015a pp: 501.
- 18- Bushra H Sh and Sara O S . Sarcocystosis in meat-producing animals: an updating on the molecular characterization .2021; *Veterinary*

- Pathobiology and Public Health .2021;144-151.
<https://doi.org/10.47278/book.vpph/2021.012>.
- 19-Al-Dulaimi G K. Epidemiological study of Sarcocystosis in sheep in Baghdad city, M.Sc. Thesis Col. Vet. Med., Univ. Baghdad, Iraq .1992.
- 20-Barham S M. Study The Epidemiology of Caprine Sarcocystosis in Sulaymania Area, M.Sc. Thesis Col. Vet. Med., Univ. Baghdad, Iraq.1992.
- 21-Zangana I K and Hussein S N . Prevalence of *Sarcocystis* Species (*Sarcocystis Ovicanis* and *Sarcocystis Capricanis*) in Tongue Muscle of Sheep and Goats in Duhok Province, Kurdistan Region, North Iraq. ARO- Sci. J. Koya Univ.2017; 5(1): 36-40.
- 22-Mohammad H .Prevalence of Bovine *Sarcocystosis* in Babylon province.Journal KufaVet.MedicalSciences. 2012;3(2):78-83.
- 23-AL-Bayati S M. Study in epidemiology of bovine *Sarcocystosis* in Baghdad area .MSc Thesis, Baghdad University. Iraq,1993.
- 24-Cooper B and Valentine B. Muscle and tendon. In: Maxie MG ed. Jubb, Kennedy, and Palmer's Pathology of Domestic Animals. Vol 1. 6th ed. St. Louis, MO: Elsevier.2016; 235-6.
- 25-Fayer R , Esposito DH , Dubey JP. Human infections with *Sarcocystis* species. Clinical microbiology reviews, 2015; 28(2):295–311.