

The Efficacy of Mesenchymal Stem Cells loaded in Acacia Gum Hydrogel and Acacia Gum Hydrogel on Skin Wounds Healing in Rats

Wissam Abdullah Alhayani

Department of Veterinary Surgery and Obstetrics, College of Veterinary Medicine, University of Fallujah.

Corresponding Author: wisamabd82@uofallujah.edu.iq

Doi: <https://doi.org/10.37940/AJVS.2021.15.1.8>

Received: 6/3/2021 Accepted: 12/6/2022

This article is licensed under a CC BY (Creative Commons Attribution 4.0)

<http://creativecommons.org/licenses/by/4.0/>.

Abstract

Cutaneous wound healing processes start at the beginning of the trauma leading to impairment of physical and functional tissue continuity. The present work aimed to clarify the efficacy of stem cells loaded in acacia gum hydrogel and acacia gum hydrogel on skin wound healing in rats. Thirty-six adult male rats (Wister rats). The weight of the rats was estimated between 150-160 grams and the animals were divided into three groups (n=12). In Group A (control group), the surgical skin wound was established and treated with normal saline only. Group B: surgical skin wound was made and covered with Acacia gum hydrogel. Group C: surgical skin wound was made and covered with mesenchymal stem cells loaded in Acacia gum hydrogel. Examination of wound healing on days 3, 7, 14 and 21 for gross and microscopic pathological changes. The gross pathological evaluation showed no significant difference between all groups but the histopathological result showed the Acacia gum improved wound recovery better than the control group, although the wound was not completely closed on day 21 in Acacia gum and control groups contrary to the stem cells treated group, which showed complete wound closure. The best ever histopathological result of wounds healing in mesenchymal stem cells loaded in acacia gum hydrogel treated groups.

Keywords: Wound Healing, Mesenchymal stem cells, Acacia gum hydrogel.

فعالية الخلايا الجذعية الوسيطة المحملة في الهلام المائي لصمغ الأكاسيا و الهلام المائي لصمغ الأكاسيا على التئام الجروح الجلدية في الفئران

الخلاصة

تبدأ عمليات التئام الجروح الجلدية بعد تعرض أنسجة الجلد الى الكدمات التي تفقدها وظائفها. هدفت الدراسة الحالية الى تقييم كفاءة استخدام الخلايا الجذعية الوسيطة المحملة في الهلام المائي لصمغ الأكاسيا والهلام المائي لصمغ الأكاسيا على التئام الجروح الجلدية ذات السماكة الكاملة في الفئران. تم استخدام ستة وثلاثون جرذاً ذكراً بالغاً يتراوح وزنها بين 150 و 160 جم وتم تقسيمها إلى ثلاث مجموعات متساوية (n = 12). في المجموعة أ (المجموعة الضابطة). تم عمل جرح جلدي ومعالجته بمحلول ملحي عادي. في المجموعة ب: تم عمل جرح جلدي جراحي وتغطيته بطبقة الهلام المائي لصمغ الأكاسيا. في المجموعة ج: تم عمل جرح جلدي جراحي وتغطيته بالخلايا الجذعية الوسيطة المحملة في الهلام المائي لصمغ الأكاسيا. تم اجراء الفحوصات العيانية والنسجية على النسيج لفحص وتقييم التئام الجروح في الأيام 3 و 7 و 14 و 21. أظهرت الفحوصات المرضية العيانية عدم وجود اختلافات ذات فرق معنوي وأظهرت النتائج المرضية النسجية أن الهلام المائي لصمغ الأكاسيا عزز التئام الجروح أكثر من المجموعة الضابطة ولكن لم يحدث الإغلاق الكامل للجرح في اليوم الحادي والعشرين. افضل النتائج المرضية النسجية لالتئام الجروح ظهرت في مجموعة التي تمت استخدام الخلايا الجذعية الوسيطة المحملة في الهلام المائي لصمغ الأكاسيا.

Introduction

Skin is a complex structure designed to protect organism from exogenous environments and thus wound lead to damage of numerous structures, cellular layers and lineages, like the dermis, epidermal keratinocyte layer, hair follicles, sweat glands, fibroblasts, extracellular matrix, nerves, blood vessels and lymphatic vessels (1). Wound healing is complex regeneration processes involves three crucial stages (inflammatory reaction, proliferative and maturation phases), and also involves the interaction between many important components (e.g. cells, intercellular matrix, signaling factors) (2, 3).

Acacia gum (Gum Arabic) is a branched-chain, complex mixture of glycoproteins and polysaccharides contains some minerals and salts (4). Acacia gum has the capability to absorb fluids and maintain wound hydration to speed up the wound healing process (5).

Bone marrow mesenchymal stromal cells (BM-MSCs) are most encouraging tools of wound healing. BM-MSCs are multipotential stem cells that can differentiate to give rise different types of cells, growth factors and cytokines for wound healing (6). It has the ability to move to the area of the injury and enhance wound healing (7).

The present study aims to evaluate and compare between BM-MSCs loaded in acacia gum hydrogel and acacia gum hydrogel in wound healing.

Materials and Methods

Preparation of Acacia gum hydrogel

Preparation of Acacia gum hydrogel according of technique by (8) with some modifications. The Acacia gum was grinded into a powder then digested by adding 20 mg of Acacia gum to 1 ml solution of 1 M of HCL acid and deionized water, then the solution was constant stirring for 24 h at

room temperature for digestion of Acacia gum. Afterward pH was raised to 8 using NaOH. Added of phosphate buffered saline to lowering a pH-value of 7.4 (isotonic solution). The hydrogel was stored as neutralized samples with a pH 7.4 at 4 °C.

Isolation and culture of BM-MSCs

Six weeks old, adult male Wistar rats were sacrificed with overdose anesthesia (at 5 times the anesthetic dose) of ketamine and xylazine mixture according to animal euthanasia guidelines on the American Veterinary Medical Association (AVMA). Sterilization the animal by putting the whole body of animals in 70% alcohol. The femur and tibia were aseptically removed from body, and then loaded into sterile petri dish. Petri dish was placed under laminar flow hood, then the bones washed with phosphate buffer saline (PBS) and the cancellous bone was isolated from the femur and tibia by injection the cavity of the bone marrow with complete media to flushing bone marrow cells. The mixture plated in culture flask (T-25) and supplanted with 10 ml of Dulbecco's Modified Eagle's Medium (Sigma, USA). Examined under inverted microscope. The flask was labeled by cell type and date and then incubated in incubator (37 °C and 5% CO₂) and the medium was changed every 3-4 days (after 4 days in first time) until cultures were reached 70% confluent (usually 5-14 days). For subculturing, BM-MSCs were detached with trypsin/EDTA, centrifuged, divided, and cultured.

Loading BM-MSCs in Acacia gum hydrogel

BM-MSCs at concentration of 3×10^6 were loaded in 0.5 ml Acacia gum hydrogel, and then incubated 6 h in a 5% CO₂ humidified incubator at 37 °C.

Experimental Animal

Thirty-six rats were equally split into three groups

(n=12):

Group A: Circular surgical skin wound (1.5 cm in diameter) was established and treated with normal saline (control group).

Group B: Circular surgical skin wound (1.5 cm in diameter) was established and covered with Acacia gum hydrogel.

Group C: Circular surgical skin wound (1.5 cm in diameter) was established and covered with BM-MSCs loaded in Acacia gum hydrogel.

The animals housed separately in laboratory cages and had free access to food (standard rodent pellet diet) and freely water access. Acclimatization the animals one-week before starting the experiment.

The Surgical Procedure

The rats get anesthesia by combination of xylazine (20 mg/ kg) (Adwia Company, Egypt) and ketamine (80 mg/kg) (Alfasan, Holland) and given intramuscular injection.

The animals were prepared for aseptic surgery and full thickness of circular skin circular incision of 1.5 cm in diameter was made in halfway between the imaginary line connecting the animal's shoulders according to (9). The group A, the wound defect was created by forceps and small size scissor and treated with normal saline and left without any treatment as group A. The group B, the wound was created and covered with 0.5 ml of acacia gum hydrogel. The group C, the wound was created and covered with 0.5 ml of BM-MSCs loaded in acacia gum hydrogel.

Pathological examinations

A. Gross pathological study of wound healing

Gross pathological examinations included percentage ratio of wound contraction on day 3, 7, 14 and 21 after induced of wound. The percentage of wound healing was calculated

according to (9) as calculating the distance and size of the wound by using numerical calipers as the following equation (9).

$$\text{Healing contraction ratio (\%)} = \frac{\text{wound measurement at day 0} - \text{wound measurement at day x}}{\text{wound measurement at day 0}} \times 100$$

Microscopic evaluation of wound healing:

The histological evaluation done on day 3, 7, 14, and 21 of the surgery, the specimens of all the rats were collected from skin wound and washed with normal saline then the samples preserved in neutral buffered formalin (10%), processed and stained with hematoxylin and eosin stain (H&E). Five fields were examined and the lesions were examined for any under light microscopy (Olympus Japan) for pathological changes and the photo captured (Sony digital camera)

Statistical Analysis

The statistical analysis using analysis of variance of one-way ANOVA test (with Tukey test afterwards in SPSS statistical software (version 24). Probability at 0.05 level were used for statistical difference.

Results and Discussion

In present study, efforts have been made for providing promising tools in the wound regeneration depending on gross and histopathological evaluation of healing capability of BM-MSCs loaded in Acacia gum hydrogel and Acacia gum hydrogel on skin wound healing in rats. This study was the first study use the combined (BM-MSCs loaded in Acacia gum hydrogel).

Gross pathological study of wound healing

Experimental rats expressed good model in wound study as they tolerated surgery well and survived healthy during the study period. This result in consisted with other researchers that served the rats as a good model for skin wound

regeneration study (2,3) In gross pathological study of wound healing and showed no difference in wound healing between all groups , these findings could be attributed to use small size wound in study.

Gross pathological study and measurements of wounds at days 0, 3, 7, 14 and 21 post-wound presented in Figure 1 and Table 1. The wound appearance and calculations showed no difference in diameter at day 0 and days 3 in all groups. Meanwhile, at days 7 and 14 the contraction appeared highest in both treated groups compared to group A but these results are considered statistically non-significant. Complete wound closure in the group C at day 21 showed minimal scar formation when compared with other groups (A and B) which showed incomplete wound closure at day 21 although these results was considered statistically non-significant.

These results is in contrast with (10) that found the significant result in gross pathological appearance of mesenchymal stem cells treated groups. Furthermore, faster contraction of wound and complete close wound was mentioned in mesenchymal stem cells treated groups by (11,12). Karp and Teo (13) were also clarified the best wound healing results of local wound injection of mesenchymal stem cells.

Histopathological evaluation of healed wound area:

Day 3 :

The histology of the wound tissues on the days 3 after induced of wound showed same histological changes including infiltration inflammatory cells, granulation tissue formation with and blood vessels congestion and presence of angiogenesis and collagen distribution in all of experiment groups.

Day 7:

Group A and Group B at this time-showed sever inflammatory reaction meanwhile the group C

showed less inflammatory cells and more collagen, fibroblast, and blood proliferating capillaries than the control group,

Day 14:

The histological study of group A showed necrosis, incomplete epithelialization of epidermis with high numbers of inflammatory cell, while group B and group C showed numerous of collagen distribution with increase of intensity and complete epithelia layer formation.

Day 21:

Group A showing presence of covering crust with filling of wound bed and presence of granulation tissue with epidermis disappearance of the skin growing and the surface of wound covering with epidermal regeneration and filling of wound bed with regenerated epidermis and increasing thickness of epidermis. Group C showed fully regeneration of the dermis and epidermis. The dermal regeneration with fully hair follicles formation and presence of regenerated sebaceous glands and absence of inflammatory cells.

Histopathological study of healed wound area show superior wound healing in stem cells group as dermal regeneration with fully hair follicles formation and presence of regenerated sebaceous glands and absence of inflammatory cells. Similar findings were seen is several studies that shown the efficiency of BM-MSCs for enhancing wound healing (10). The same advantages were obtained by (14) that he ensure the enhancement effect of mesenchymal stem cells in dermal regeneration in mice and regard good cells source for burns and wounds treatments. The uses Acacia gum to treat wound also done by (5,15) results demonstrate that topical application of Acacia gum hydrogel improvement the wound healing.

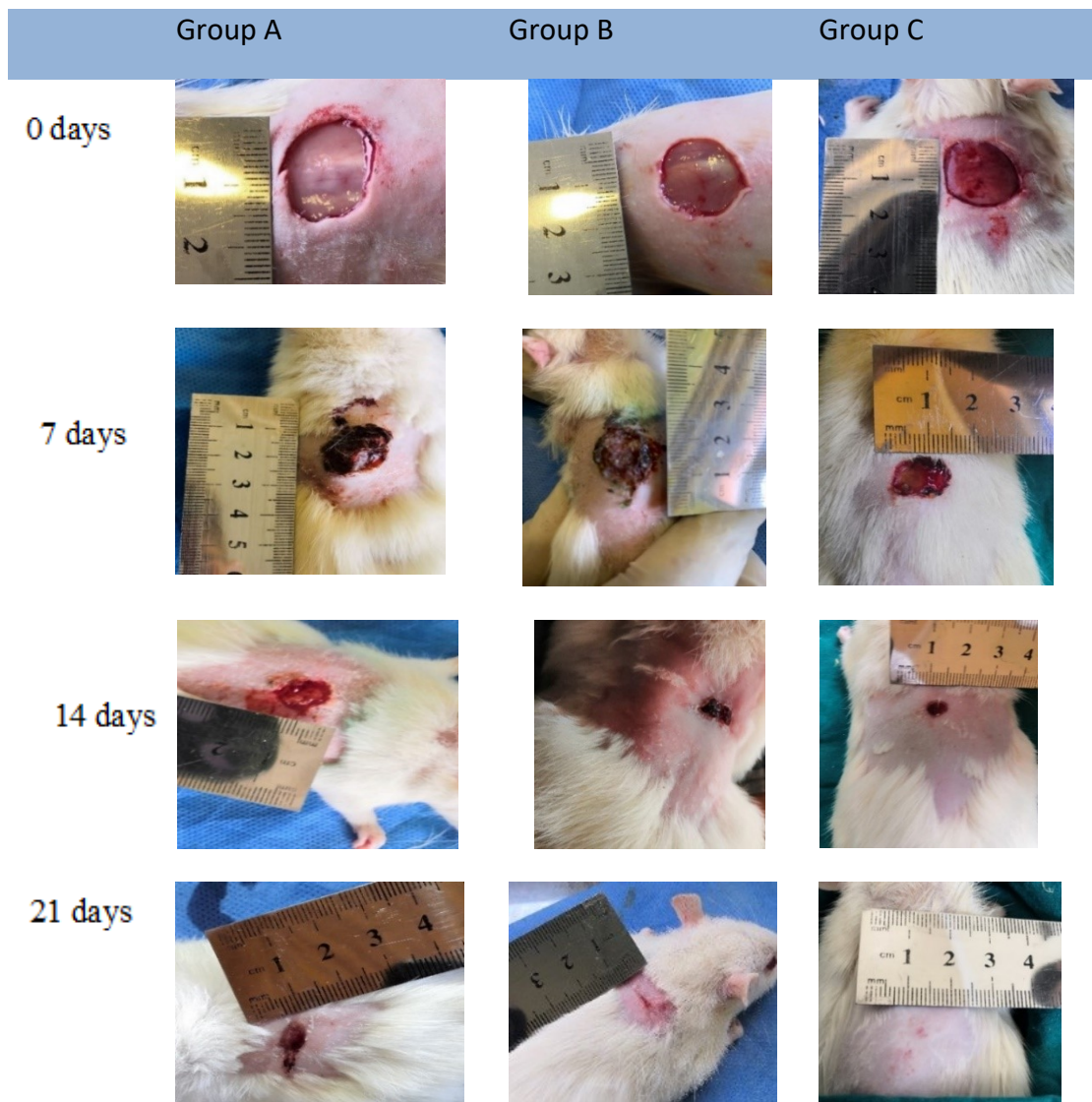


Fig. 1: Gross appearances of wounds area on different post excision days of control, acacia gum hydrogel and BM-MSCs loaded in acacia gum hydrogel groups.

Table 1 wound area (cm²) and Healing contraction ratio (%) (No significant difference in all groups)

Groups		0 day	3rd day	7th day	14th day	20th day
Group A		1.8 (±0.18) cm ²	1.6 (±0.019) cm ²	1.1 (±0.2) cm ²	0.45 (±0.07) cm ²	0.23 (±0.008) cm ²
	Healing contraction ratio		5.9 %	24.1 %	60 %	77.3 %
Group B		1.8 (±0.12) cm ²	1.4 (±0.05) cm ²	1 (±0.018) cm ²	0.32 (±0.04) cm ²	0.08 (±0.005) cm ²
	Healing contraction ratio		12.5 %	28.6 %	69.8 %	91.5 %
Group C		1.8 (±0.2) cm ²	1.5 (±0.02) cm ²	0.9 (±0.09) cm ²	0.15 (±0.01) cm ²	0 cm ²
	Healing contraction ratio		9.1 %	33.3 %	84.6%	100 %

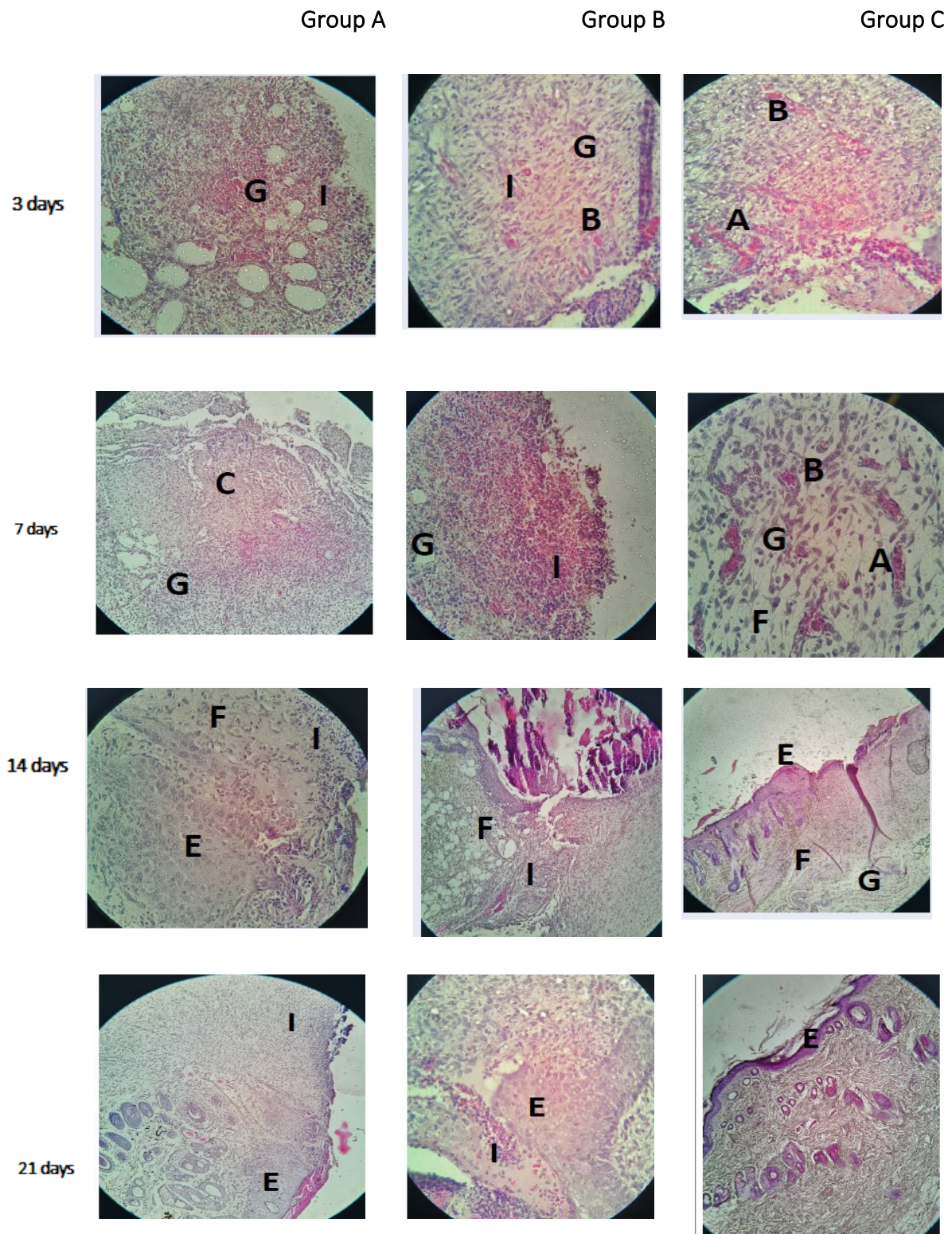


Fig 2. Histophotography of wound area from all experiment groups showed:- Granulation tissue formation(G) infiltration of inflammatory cell (I), Blood vessels congestion (B), angiogenesis (A), Collagen distribution (C) Fibroblast (F), Epidermis (E). (H & E stain).

Conclusion

Mesenchymal Stem Cells loaded in Acacia gum hydrogel and Acacia gum hydrogel treated groups enhanced of wound healing in rats. the study reveal no significant difference in gross appearances but histopathological evaluation clearly showed that the BM-MSCs loaded in acacia gum hydrogel treated group superior than the control group or acacia gum hydrogel group.

References

1. Shaw TJ, Martin P. Wound repair at a glance. *Journal of Cell Science*. 2009;122(18):3209-13.
2. Choi YS, Lee S, Hong SR, Lee YM, Song K, Park M. Studies on gelatin-based sponges. Part III: a comparative study of cross-linked gelatin/alginate, gelatin/hyaluronate and chitosan/hyaluronate sponges and their application as a wound dressing in full-thickness skin defect of rat. *Journal of Materials Science: Materials in Medicine*. 2001;12(1):67-73.
3. Revilla G, Darwin E, Rantam F. Effect of Allogeneic Bone Marrow-mesenchymal Stem Cells (BM-MSCs) to Accelerate Burn Healing of Rat on the Expression of Collagen Type I and Integrin $\alpha 2\beta 1$. *Pakistan journal of biological sciences: PJBS*. 2016;19(8-9):345-51.
4. Ali BH, Ziada A, Blunden G. Biological effects of gum arabic: a review of some recent research. *Food and chemical Toxicology*. 2009;47(1):1-8.
5. Singh B, Sharma S, Dhiman A. Acacia gum polysaccharide based hydrogel wound dressings: synthesis, characterization, drug delivery and biomedical properties. *Carbohydrate polymers*. 2017;165:294-303.
6. McFarlin K, Gao X, Liu YB, Dulchavsky DS, Kwon D, Arbab AS, *et al*. Bone marrow-derived mesenchymal stromal cells accelerate wound healing in the rat. *Wound Repair and Regeneration*. 2006;14(4):471-8.
7. Bharti MK, Bhat IA, Pandey S, Shabir U, Peer BA, Indu B, *et al*. Effect of cryopreservation on therapeutic potential of canine bone marrow derived mesenchymal stem cells augmented mesh scaffold for wound healing in guinea pig. *Biomedicine & Pharmacotherapy*. 2020;121:109573.
8. Kim MY, Farnebo S, Woon CYL, Schmitt T, Pham H, Chang J. Augmentation of tendon healing with an injectable tendon hydrogel in a rat Achilles tendon model. *Plast Reconstr Surg*. 2014 May;133(5):645e-653e.
9. Jarad, As., Jumaa, A., Hasan, M., Shwaish, M., Farhan, W., Ibrahim, Z. Owain, M. and Hussein, M. Diabetic wound healing enhancement by tadalafil. *International journal of pharmaceutical research*. 2020. 12(3):841-847.
10. El Sadik AO, El Ghamrawy TA, Abd El-Galil TI. The Effect of Mesenchymal Stem Cells and Chitosan Gel on Full Thickness Skin Wound Healing in Albino Rats: Histological, Immunohistochemical and Fluorescent Study. *PLoS One*. 2015 Sep 24;10(9):e0137544. doi: 10.1371/journal.pone.0137544. PMID: 26402454; PMCID: PMC4581728.
11. Wu Y, Chen L, Scott PG, Tredget EE. Mesenchymal stem cells enhance wound healing through differentiation and angiogenesis. *Stem Cells*. 2007; 25(10), 2648–59. PMID: 17615264.
12. Seifert AW, Monaghan JR, Voss SR, Maden M. Skin regeneration in adult axolotls: a blueprint for scar-free healing in vertebrates. *PLoS One*. 2012; 7: e32875. doi: 10.1371/journal.pone.0032875 PMID: 22485136.
13. Karp JM, Teo GSL. Mesenchymal stem cell homing: the devil is in the details. *Cell Stem Cell*. 2009; 4: 206–16. doi: 10.1016/j.stem.2009.02.001 PMID: 19265660.
14. Dai Y, Li J, Li J, Dai G, Mu H, Wu Q, *et al*. Skin epithelial cells in mice from umbilical cord

blood mesenchymal stem cells. *Burns*. 2007; 33: 418–428. PMID: 17467179.

15. El-Ferjani, R. M., Ahmad, M., Dhiyaaldeen, S. M., Harun, F. W., Ibrahim, M. Y., Adam, H., Mohd Yamin, B., Al-Obaidi, M. M., & Batran, R.

A. (2016). In vivo Assessment of Antioxidant and Wound Healing Improvement of a New Schiff Base Derived Co (II) Complex in Rats. *Scientific reports*, 6, 38748. <https://doi.org/10.1038/srep38748>.