

## Endoscopic Dacryocystorhinostomy: A Case Series Study from Mosul City

Islam Ghanim Mahmood\*, Professor Ali Abdulmuttalib Mohammed\*\*, Hassan Myasar Abdulwahid\*

\*Unit of Ear, Nose and Throat , Aljamhory Teaching Hospital , \*\*Department of Surgery , College of Medicine ,  
University of Mosul , Mosul, Iraq

Correspondence: aliabdmutt@uomosul.edu.iq

(Ann Coll Med Mosul 2021; 43 (1):81-86).

Received: 29<sup>th</sup> Nove 2020; Accepted: 26<sup>th</sup> Febr 2021.

### ABSTRACT

**Background:** Dacryocystorhinostomy is a technique applied to patients who complain of excessive tearing (epiphora) and demonstrate obstruction of the lacrimal outflow system.

**Objectives:** The present study aims at studying the outcome and complications of endoscopic dacryocystorhinostomy EnDCR.

**Methods:** This case series study was conducted to analyze 70 eyes related to 66 patients with epiphora and recurrent attacks of dacryocystitis who underwent EnDCR for the period from January 2018 to June 2019. Surgeries were done in 2 hospitals in Mosul namely; Al-jumhoory Teaching hospital and Al-Rabee Private hospital.

**Results:** This case series study included 70 eyes of 66 patients (62 unilateral and 4 bilateral cases) complaining from epiphora excessive tearing and/or chronic dacryocystitis. There was 45 females (68.2%) and 21 males (31.8%) with F:M ratio of 2.1:1. The patients' ages ranged between 4-74 years of age with a mean age of  $39 \pm 18.31$ . The success rate of endoscopic dacryocystorhinostomy EnDCR in the present study was 97.15 % depending on clinical improvement of epiphora , endoscopic assessment for patency of the new ostium and passage of tears aided by pressing over the medial canthus. Hemorrhage was the most common complication and there was no serious orbital complication in our study neither during surgery nor in the follow up period.

**Conclusion:** Endoscopic dacryocystorhinostomy EnDCR carries very good success rate with relatively not critical and low complication rate. Moreover, it has the advantage of overlooking unnecessary scar, the ability to operate both sides simultaneously and revising the operation in case of failure of surgery.

**Keywords:** Endoscopic dacryocystorhinostomy, dacryocystitis, epiphora, EnDCR.

## فتح مجرى قناة الدمع بواسطة المنظار: دراسة لسلسلة مرضى من مدينة الموصل

إسلام غانم محمود\* ، الأستاذ علي عبد المطلب محمد\*\* ، حسان ميسر عبدالواحد\*  
\*شعبة الأنف والأذن والحنجرة ، المستشفى الجمهوري التعليمي ، \*\*فرع الجراحة ، كلية الطب ،  
جامعة الموصل ، الموصل ، العراق

### الخلاصة

**الخلفية:** فتح مجرى قناة الدمع هي عملية للمرضى الذين يعانون من الدمع مع انسداد في مجرى قناة الدمع .  
**الأهداف:** تهدف الدراسة الحالية إلى تقييم نتائج ومضاعفات عملية فتح مجرى قناة الدمع بواسطة المنظار .

**الطرق المستعملة:** دراسة لسلسلة مرضى مهتمة ب ٧٠ عينا عائدة ل ٦٦ مريضا يعانون من انسداد مجرى قناة الدمع ممن أجريت لهم عملية فتح مجرى قناة الدمع بواسطة المنظار. أجريت الدراسة في شعبة الأنف والأذن والحنجرة / مستشفى الجمهوري التعليمي ومستشفى الربيع الاهلي، موصل/العراق للفترة من كانون الثاني ٢٠١٨ إلى حزيران ٢٠١٩ .

**النتائج:** أجريت الدراسة على ٧٠ عينا عائدة ل ٦٦ مريضا يعانون من انسداد مجرى قناة الدمع ممن أجريت لهم عملية فتح مجرى قناة الدمع بواسطة المنظار منهم ٢١ ذكرا (٣١.٨%) و ٤٥ أنثى (٦٨.٢%). وكان متوسط العمر بمعدل ٣٩ سنة بمديات تراوحت بين ٤ الى ٧٤ سنة. تشير النتائج إلى أن معدل النجاح الجراحي للعملية ٩٧.١٥% بينما كان النزيف أكثر المضاعفات حدوثا. لم يكن هنالك مضاعفات للعين لا اثناء العملية ولا في فترة متابعة المرضى .

**الاستنتاج:** عملية فتح مجرى قناة الدمع بواسطة المنظار تحمل نسبة نجاح عالية جدا مع مضاعفات قليلة وغير خطيرة نسبيا. اضافة الى ذلك ليس هنالك ندبة للجرح بعد اجراء العملية، يمكن اجراء العملية للجتهتين في نفس الوقت ويمكن اعادة اجراء العملية في حالة فشلها.

**الكلمات المفتاحية:** التهاب مجرى قناة الدمع ، فتح مجرى قناة الدمع بواسطة المنظار ، الدمع .

## INTRODUCTION

The nasolacrimal drainage system consists of superior and inferior canaliculi which feed into the common canaliculus, lacrimal sac and subsequently the nasolacrimal duct, the lacrimal sac is protected in the concavity of lacrimal fossa of the medial orbital wall<sup>1</sup>.

Epiphora is commonly complained, for some people this is a minor inconvenience, yet for others it can be extremely troublesome, and a source of social embarrassment because it can alter refraction. It can stem from proximal obstruction in the drainage system at the punctum or common canaliculus. Dacryocystorhinostomy DCR is a technique applied to patients who complain of excessive tearing (epiphora), chronic or recurrent dacryocystitis and demonstrate obstruction of the lacrimal outflow system. The procedure usually consists of creating a fistula for egress of tears directly from the lacrimal sac into the nose and bypassing the nasolacrimal duct<sup>2</sup>.

Dacryocystorhinostomy DCR was first reported by Caldwell in 1893, an ENT surgeon by profession who created a rhinostomy using an intranasal approach by removing a portion of the inferior turbinate but it did not get popularity at that time. External dacryocystorhinostomy DCR was first described in 1904 by Toti, with a few modifications, yet the procedure remained unchanged from its original description<sup>3</sup>.

The current EnDCR technique was invented between the eighties and nineties of the past century by McDonogh and Meiring. The endoscopic approach tries to avoid a cutaneous incision and provides the surgeon a good visualization of the lacrimal sac during dissection and marsupialization. The EnDCR has become a well-accepted technique for management of nasolacrimal duct obstruction with high success rate<sup>4</sup>.

Massaro et al. used a laser technique to aid endonasal DCR using an argon blue-green laser<sup>5</sup>. Gonnering et al. subsequently reported using both the CO2 and KTP laser<sup>6</sup>.

The present study aims at analyzing the outcome and complications of EnDCR on group of patients operated in Mosul City.

## PATIENTS AND METHODS

This case series study analyzed 66 cases of subjects with epiphora and recurrent attacks of dacryocystitis for the period from January 2018 to June 2019. The patients were diagnosed and referred by ophthalmologists to the private clinic and Otolaryngology Department at Al-jumhoory Teaching Hospital and the surgeries were done in 2 hospitals in Mosul namely; Al-jumhoory Teaching hospital and Al-Rabee Private hospital.

The present study was approved by the Medical Research Ethics Committee (MREC) of the College of Medicine , University of Mosul with approval code 20-21(6) on 5/10/2020 and in line with the 1964 Helsinki Declaration and its later amendments or comparable ethical standards.

The Performa was designed based on objective of the study; after completing ophthalmological assessment and failure of simple probing and syringing by ophthalmologists to solve the problem. After taking informed consents from all patients, they were interviewed to fill a specially prepared formula of enquiry. This formula included history followed by full ORL examination including detailed history, local examination of nose and anterior rhinoscopy. Then diagnostic nasal endoscopy was performed in all patients using 2.7 mm, 0 and 30 degree endoscopes. Illumination was provided by Karl Storz light source. Decongestion of the patient's nose using 2% xylocaine with 0.1 % xylometazoline was done. The subjects were placed in sitting position and endoscopy was conducted in three passes.

## Surgical Procedure

EnDCR was done under general anesthesia with preparation of nasal cavity by application of adrenaline 1:20,000 on small pieces of cotton.

The technique of endoscopic DCR was conducted by making incision in lateral wall of nose using sickle knife or 12 blade of 1cm length starting just anterior to the axilla of middle turbinate and running anteriorly. The incision then runs vertically reaching the insertion of inferior turbinate. A posteriorly based mucosal flap is elevated by Freer which is then partially trimmed to expose the bone (Figure 1). The exposed bone is removed by 2mm Kerrisons punch then a drill has been used to

remove the frontal process of the maxilla by diamond burr. Dilation of the lacrimal puncti and probing of the lacrimal canaliculi was done and here we try to evaluate the actual level of obstruction.

The sac is tensed by the probe and it is incised by a sickle knife vertically anterior to the point of tensing probe. In all the cases above, the sac was widely opened and marsupialized and stents were inserted inside the upper and lower canaliculi and tied by the knot in the nasal cavity (Figure 2). Nasal pack was applied and oral antibiotics with or without analgesia were prescribed for all patients. Nasal pack was removed at the first visit in the next day after operation with instruction for the patient to frequently irrigate the nose with isotonic saline wash to avoid crustation.

All patients in the study had tube inserted for 3 months postoperatively. The long term follow up of the patients was for 12 months with approximately 3 visits; 3, 6 and 12 months postoperatively.

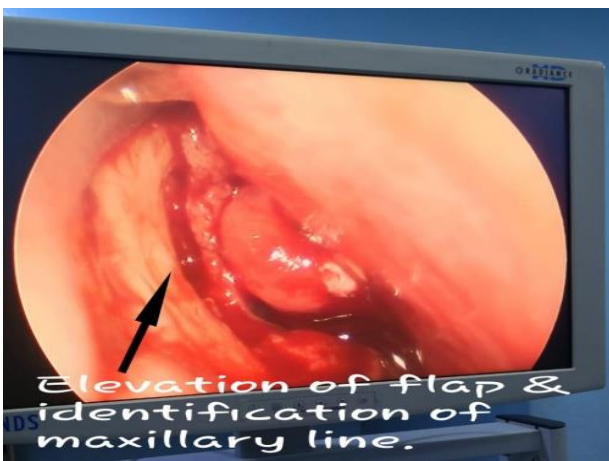
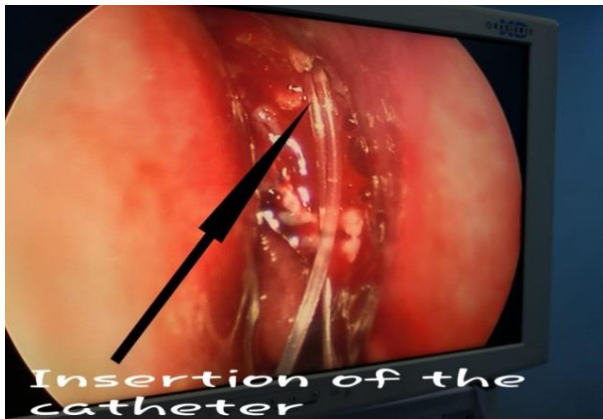


Figure 1 and 2: Procedure of DCR.

## RESULTS

This case series study included 70 eyes of sixty six patients (62 unilateral and 4 bilateral cases) complaining from epiphora excessive tearing and/or chronic dacryocystitis. The study included 45 females (68.2%) and a 21 males (31.8%) with a ratio of 2.1:1. The patients' ages ranged between 4 and 74 years with a mean age of  $39 \pm 18.31$  years. Figure (3) showed that the maximum age incidence was in the seventh decade of life and females are more than males in all age groups.

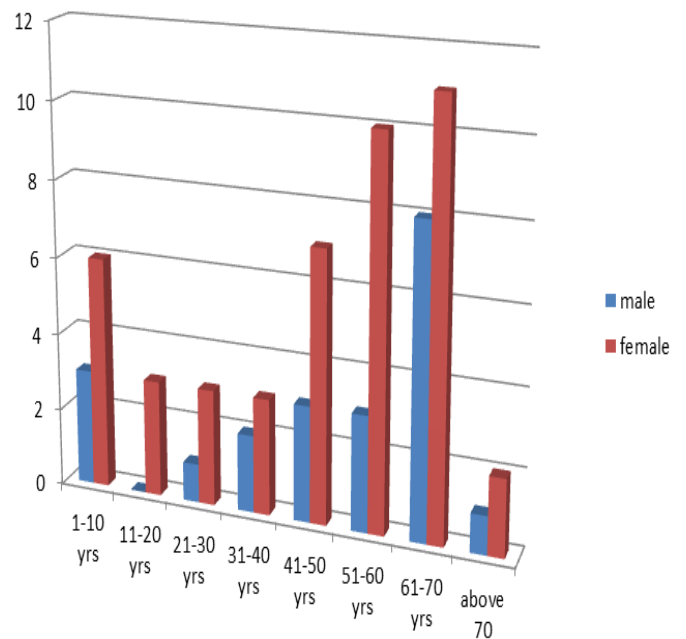


Figure 3: Age groups of patients included in this study.

Sixty two out of 66 patients (94%) were referred from ophthalmologists as newly diagnosed nasolacrimal duct obstruction and/or chronic dacryocystitis, whereas the remaining 4 patients (6%) were revision cases after failure of laser surgery. Moreover, 14 patients (21.2%) were operated by ENT surgeon alone and 52(78.8%) patients by ENT surgeon with ophthalmologist. The mean time of surgery was 30-40 minutes. Furthermore, 29 out 66 patients (44%) had septal deviation to the same side of surgery but only 22 of them (33%) required septoplasty before EnDCR and the mean time of surgery for the latter group was 1hour and 30 minutes. Five patients (7.5%) proved to have acute infection at time of surgery in form of pain, redness and swelling around the medial can thus which were treated preoperatively by local, systemic antibiotics and analgesia.

The success rate of endoscopic DCR in the present study was 97.15 %, 68 eyes out of 70 eyes had good results and their symptoms were cured, whereas only 2 eyes (2.85%) required revision surgery 2 years after failure of the 1<sup>st</sup> operation.

Hemorrhage was the most common complication which occurred in 16 patients. Grade 3, 4 and 5 bleeding required frequent suction and prolonged the time of surgery, here we used local cotton swabs impregnated with adrenaline and asked the anesthetist to induce hypotensive anesthesia to decrease bleeding. Fortunately, we did not abort any surgery in the present study because of bleeding.

The other complications were listed in table (1). There was no serious orbital complication in our study neither during surgery nor in the follow up period. Moreover, there was no statistical significance in occurrence of complications between males and females.

Table (1): Gender difference in complications of EnDCR.

Complication	Total	Females [n = 45] No. (%)	Males [n = 21] No. (%)	P- value*
Hemorrhage	16	10 (22.2)	6 (28.7)	0.586
Granulation tissue	15	8 (17.8)	7 (33.3)	0.186
Synechia	14	11 (24.4)	3 (14.3)	0.308
Discomfort from tube	11	7 (15.0)	4 (19.1)	0.730
Crustation	3	2 (4.4)	1 (4.8)	0.955
Cheese wire	1	1 (2.2)	0 (0.0)	---
Orbital fat exposure	1	1 (2.2)	0 (0.0)	---

\* Z-test of two proportions was applied.

## DISCUSSION

In Mosul city the EnDCR was first done in 2006 by Saeed while LASER DCR was done in approximately the same time 2008<sup>7</sup>. The aim of the study is to present our experience of EnDCR in Mosul city regarding the indications and outcome

It is important to have standard in making decision for success of DCR surgery. The Royal College of Ophthalmologists (1999) published a guideline for clinical governance suggesting that freedom from epiphora 3 months after surgery was the marker for a satisfactory procedure<sup>8</sup>. According to the above criteria, the success rate of EnDCR in the current study was 97.15% Similarly, Jim et al. 2006 had success rate of 96% by using technique of EnDCR with creation of large epithelialized fistula<sup>9</sup>. Moreover, chougule SS et. al. 2010<sup>10</sup> reported a 97.7% success rate using EnDCR without preservation of mucosal flap. Furthermore, Saeed BM et. al. 2013<sup>11</sup> on studying EnDCR on 50 paediatrics, their ages were 3-12 years had success rate of 90%.

On the contrary, Sung et.al. of Korea 2019<sup>12</sup> published a study on 2 age groups of EnDCR ,first one was 30-61 years the other group was 62-89 years with success rates of 91.8% and 88.2% respectively. They reached a conclusion that comorbid conditions that increased with age such as diabetes and eyelid laxity may increase functional failure.

Regarding the external approach, Leong et. al. 2002<sup>13</sup> reported a 94% success rate for external DCR and 86% for endoscopic approach, thus he reached a conclusion that external DCR has a better outcome than endoscopic one although the latter is associated with less complications. The merit of external DCR is the good exposure of anatomy and surgical field allowing precise removal of bone in lacrimal fossa and exact anastomosis of the nasal mucosa and lacrimal sac<sup>14</sup>.

The patients in this study passed their postoperative period smoothly with simple discomfort at the first 2 visits and were treated by isotonic saline irrigation and cleaning the nose, then they were symptom free till the last visit in about 1 year after surgery.

Regarding LASER DCR, Young MW et. al. 2002<sup>14</sup> mentioned in their study that the result of endoscopic DCR was similar at 6 months and 12 months postoperatively in contrast to laser assisted DCR in which the effectiveness of procedure decreases with time. This can be explained by the fact that in endoscopic DCR the mucosal window is of the same size as bone window which is removed by rongeur avoiding a rim of devitalized bone which is created by laser , these edges increase fibrosis and decrease reepithelialization.

The failure rate of EnDCR in this study was 2.85%; we have 2 eyes out of total 70 required revision surgeries due to intra operative bleeding, difficult localization of lacrimal fossa and inadequate removal of bone which ended by adhesion and stenosis. These 2 patients underwent later on successful revision surgery with same endoscopic technique 2 years after 1<sup>st</sup> surgery which is another advantage of this technique over the external approach as the previous scar carries risk of orbital and lateral nasal wall trauma with scarring.

On comparison, Kirtane MV et. al. 2011<sup>15</sup> using same endoscopic approach in addition to suturing of flap using a 5.0 vicryl or vascular clips which were used to put the mucosal flap and medial sac wall together had 5% failure rate. Furthermore, Karen et. al. 2019<sup>16</sup> in their study on 183 eyes had failure rate of 17% due to various causes like adhesion, granulations or fibrosis.

The stent in this study was inserted to all patients with different ages, sexes and level or cause of obstruction. Saeed BM 2011<sup>17</sup> in his study on 53 patients put a criteria for using catheter or not and this criteria ensure that the level of obstruction was postsaccal with good surgical procedure of maximal sac exposure and marsupialization. When all criteria are present the stent was not inserted with success rate of 100%. Moreover, Ayoob M et al 2013<sup>18</sup> in their study on 50 patients who had endoscopic DCR without intubation had success rate of 92%. Furthermore, Harugop AS et. al. 2008<sup>19</sup> in their study on 2 groups of patients the first group had EnDCR without stent & the second group with stenting found that the success rate was 93.3% and 96% respectively.

The complication rate in this study was close to the numbers of similar studies with hemorrhage , formation of granulation tissue and synechia were the most common ones with no serious orbital complication<sup>10,16,18,20</sup>.

We have one patient developed cheese wiring which is relatively rare complication due to canalicular laceration after prolong catheterization for more than 9 months because the patients missed the last postoperative visits. Karaca U et al 2019 reported peculiar three cases who had canalicular laceration or cheese wiring for the same cause<sup>21</sup>.

## CONCLUSION

Endoscopic dacryocystorhinostomy EnDCR carries very good success rate with relatively low complication rate. Moreover, it has the advantage of overlooking unnecessary scar, the ability to operate both sides simultaneously and revising the operation in case of failure of surgery.

## ACKNOWLEDGEMENTS

The authors would like to acknowledge Assistant Prof. Dr. Humam Ghanim I. Zubeer, PhD in community medicine, College of Medicine, University of Mosul, for conducting the statistical analysis of data collected in the present study.

## REFERENCES

1. Adappa ND and Palmer JN .Disorders of the orbit. In: Watkinson JC and Clark RW, editors. Scott-Brown's Otorhinolaryngology Head and Neck Surgery Vol.1. 8<sup>th</sup> edition. CRC Press Taylor & Francis Group; 2018. p. 1290-1300.
2. S. Tonya Stefko ST and Snyderman CH. Dacryocystorhinostomy. In: Myers EN, editor. Operative Otolaryngology Head and Neck Surgery. 2<sup>nd</sup> Edition. Saunders Elsevier; 2009 .p. 967-972.
3. Neil Fergie, Nicholas S Jones. Dacryocystorhinostomy. In: Scott-Brown 's Otorhinolaryngology,Head and Neck Surgery 7<sup>th</sup> edition.Vol 2. 2008 Edward Arnold (Publishers) Ltd.
- 4.4 Strong EB .Endoscopic Dacryocystorhinostomy. Craniomaxillofac Trauma Reconstruction. 2013;6:67-74.
5. Massaro BM, Gonnering RS and Harris GJ. Endonasal laser dacryocystorhinostomy; a new approach to nasolacrimal duct obstruction. Archives of Ophthalmology. 1990; 108: 1172-6.
6. Gonnering RS, Lyon DB and Fisher JC. Endoscopic laser assisted lacrimal surgery. American Journal of Ophthalmology. 1991; 111: 152-7.
7. Saeed BM, Rajab AY, Najeeb NN, Al-Gani AA. Endoscopic dacryocystorhinostomy : the outcome of 25 patients. Ann. Coll. Med. Mosul 2008; 34(2): 81-86.
8. Royal College of Ophthalmologists. Guideline for clinical governance in ophthalmology.London:RCO, April 1999.
9. Jim HR, Yeon JY, Cho MJ. Endoscopic dacryocystorhinostomy: creation of large marsupialized lacrimal sac. J Korean Med Sci. 2006; 21:719-723.
10. Chougule SS, Suligavi SS, Hiremath CS, Doddamani SS. Endoscopic dacryocystorhinostomy: our experience. Clin Rhinol: Int J. 2010;3(3):131-3.

11. Saeed BM and Tawalbeh M. Pediatric Endoscopic DCR: The Outcome in 50 Patients. *Indian J Otolaryngol Head Neck Surg.* 2014; 66(3):276-280.
12. Sung JY, Lee YH, Kim KN, Kang TS, Lee SB. Surgical outcomes of endoscopic dacryocystorhinostomy: analysis of age effect. *Scientific Reports.* 2019;9(1):1-6. DOI.org/10.1038/s41598-019-56491-y.
13. Leong SC, Karkos PD, Burgess P, Halliwell M and Hampall SA. Comparison of outcomes between non laser endoscopic endonasal and external dacryocystorhinostomy : single centre experience and a review of British trend . *Am J Otolaryngol.* 2010; 31:32-37.
14. Yung MW and Hardman-Lea S. Analysis of the results of surgical endoscopic dacryocystorhinostomy: effect of the level of obstruction. *Br J Ophthalmol.* 2002; 86:792–794.
15. Kirtane MV, Lall A, Chavan K and Satwalekar D. Endoscopic dacryocystorhinostomy with flap suturing. *Indian J Otolaryngol Head Neck Surg.* 2013;65(2):236-241.
16. Keren S, Abergel A, Manor A, Rosenblatt A, Koenigstein D, Leibovitch I, Cnaan RB. Endoscopic dacryocystorhinostomy: reasons for failure. *Eye.* 2020 May;34(5):948-53. DOI.org/10.1038/s41433-019-0612-y.
17. Saeed BMN. Endoscopic DCR without stents: clinical guidelines and procedure. *Eur Arch Otorhinolaryngol.* 2012; 269:545–549. DOI: 10.1007/s00405-011-1727-3.
18. Ayoob M, Mahida K, Qurat-ul-ain and Dawood Z. Outcome and complications of endoscopic dacryocystorhinostomy without stenting. *Pak J Med Sci.* 2013; 29(5):1236-1239.
19. Harugop AS, Mudhol RS, Rekha BK and Maheswaran M. Endonasal dacryocystorhinostomy: a prospective study. *Indian J. Otolaryngol. Head Neck Surg.* 2008; 60:335–340.
20. Saeed, B.M. Endoscopic DCR: a 10 years personal experience. *Indian J Otolaryngol Head Neck Surg* (2018). DOI.org/10.1007/s12070-018-1458-5.
21. Karaca U, Genc H, Usta G. Canalicular laceration (cheese wiring) with a silicone tube after endoscopic dacryocystorhinostomy: when to remove the tube?. *GMS ophthalmology cases.* 2019;9. DOI: 10.3205/oc000124.