

Histological and Histochemical Study of Pyloric Region in Abomasum of Adult Local Buffalos (*Bubalus Bubalis*)

Nazeha Sultan Ahmed, Thekra Fadel Saleh* and Ahmed Nazar Abed aljawad

Department of Anatomy, College of Veterinary Medicine, University of Mosul.

*Corresponding Author: 521976thekra@gmail.com, ORCID:0000-0001-7272-5260

Doi: <https://doi.org/10.37940/AJVS.2022.15.2.3>

Received: 2/7/2022 Accepted:18/10/2022

This article is licensed under a CC BY (Creative Commons Attribution 4.0)

<http://creativecommons.org/licenses/by/4.0/>.

Abstract

The current study was conducted to demonstrate the histological feature of the pyloric region of the abomasum in local buffalos and to focus on the distribution of different types of carbohydrates in the pylorus wall, where digestion has a great impact on animal production and economical outcome. Six samples of abomasum were collected from adult healthy local buffalos from the Mosul abattoir. then the pylorus region samples were sectioned from the pylorus, histologically processed, and stained with hematoxylin & eosin stain, Masson's trichrome, periodic acid Schiff and alcian blue. The histological findings of the pyloric region revealed that the mucosal wall of pylorus has depressions called gastric pits, these pits occupied the most of lamina propria receiving the mucus secretion of pyloric glands, which appeared short, tortuous, tubular in the anterior part of the pylorus, and became longer, straight in the middle part of the pylorus. The submucosa is characterized by the presence of lymphatic nodules. The histochemical findings revealed the presence of neutral and acidic (mixed) glycoprotein in the pyloric region, where acidic glycoprotein was found in terminal pyloric glands, while neutral glycoprotein was present mainly in gastric pits. The mid gland of the anterior part is distinguished by neutral glycoprotein, where as the acidic glycoprotein was evident in the mid gland of the middle part of the pylorus. The surface epithelium is characterized by the presence of both neutral and acidic types of glycoprotein. Furthermore, glycogen is present in both gastric pits in the caudal part and terminal pyloric glands of the anterior part. Glycosaminoglycans were predominant at the terminal part of pyloric glands and present in little amounts in the middle part and absent in gastric pits. In conclusion presence of acidic glycoprotein in pyloric glands confirm the presence of mucus neck cells due to their acidic secretion, while the presence of neutral glycoprotein mainly in gastric pits indicates the formation of the mucosal gastric barrier.

Keywords: Abomasum, Buffalos, Glycoproteins, Glycosaminoglycans

دراسة نسيجية ونسجية كيميائية للمنطقة البوابية لمنفحة الجاموس المحلي البالغ

أجريت الدراسة الحالية لأظهار الملامح النسيجية للمنطقة البوابية لجدار منفحة الجاموس المحلي و تسليط الضوء على توزيع المواد الكربوهيدراتية المختلفة في جدار البوابة ، حيث أن الهضم يلعب دوراً بارزاً في إنتاجية الحيوان والمردود الاقتصادي. جمعت (6) عينات للمنفحة من الجاموس البالغ والسليم سريرياً من مجزرة الموصل، قطعت عينات من منطقة البوابة ، مررت روتينياً ثم صبغت المقاطع النسيجية بملون الهيماتوكسيلين والايوسين ، ملون ماسون ثلاثي الكروم ، ملون حمض شيف الدوري والاليشين الأزرق. اوضحت الدراسة النسيجية لجدار المنطقة البوابية للمنفحة ان الغلالة المخاطية تحتوي على انخفاضات تدعى الوهات المعدي تحتل معظم الصفحة اللبائية للغلالة المخاطية حيث تستلم الوهات المعدي الافرازات المخاطية القادمة من الغدد البوابية، والتي بدت نبيبية ملتفة في الثلث الامامي ، وأصبحت الغدد البوابية أكثر طولاً واستقامة في الثلث الوسطي لجدار المنطقة البوابية للمنفحة، تمتاز الغلالة تحت المخاطية بوجود تجمعات لعقيدات لمفاوية. اكدت دراسة الكيمياء النسيجية للمنطقة البوابية لجدار المنفحة وجود بروتينات سكرية مختلطة (متعادلة وحمضية) في الغلالة المخاطية ، حيث وجد البروتين السكري الحامضي بصورة رئيسية في قاعدة الغدد المعدي بينما وجد البروتين السكري المتعادل بصورة رئيسية في الوهات المعدي لجدار المنطقة البوابية للمنفحة، تميزت منطقة وسط الغدد البوابية باحتوائها على بروتين سكري متعادل بصورة اساسية في الثلث الامامي اما البروتين السكري الحامضي فقد وجد بصورة اساسية في الثلث الوسطي لجدار المنطقة البوابية للمنفحة في حين تميزت الظهارة السطحية باحتوائها على كميات قليلة من البروتين السكري المتعادل و الحامضي. اكدت الدراسة احتواء كل من الوهات المعدي في الثلث الخلفي وقاعدة الغدد للثلث الامامي على كميات كبيرة من الجلايكوجين، اما السكريات السامانية السكرية فقد وجدت بكميات كبيرة في قاعدة الغدد وبكميات أقل في وسط الغدد البوابية وغير موجودة في الوهات المعدي لكافة أجزاء المنطقة البوابية لجدار المنفحة. وبالنتيجة فان تواجد البروتين السكري الحامضي يعززه تواجد الخلايا المخاطية العنقية، في حين يتركز البروتين السكري المتعادل على الوهات المعدي بشكل خاص لعمل الحاجز المخاطي المعدي.

Introduction

The abomasum is the functional digestive stomach of ruminants which acts like human and non-ruminants' stomach, the main function is the acid hydrolysis of microbial and dietary protein, preparing these protein sources for further digestion and absorption in the small intestine achieved by gastric juices secreted by the abomasal wall glands(1). Anatomically abomasum divided into three portions, cardiac anterior portion, fundic middle portion and pyloric posterior portion (2) whereas abomasal wall composed of 4 main tunic mucosa, submucosa, muscularis and serosa (3). The Gastric glands are present in the lamina propria of the mucosal layer which lined by mucous neck cells, the submucosa contains loose connective tissue, many blood vessels and unilocular adipocytes, submucosa characterized by presence of large lymphatic nodule (4). Furthermore, the abomasum is heavily coated by mucous, where mucoïd (glycoprotein) secretion covering the wall, has great importance for protection against chemical damage. Moreover, authors mentioned that glycoproteins are either neutral or acidic type, where acidic type confirms the integrity of mucus neck cells, while neutral type mucus is essential for ingredient mucosal gastric barrier also determination of glycoprotein type facilitate the evaluation of abomasal activity(5,6). For economical and productional importance of local Iraqi buffalos and insufficient histological and histochemical description studies of digestive system generally and

abomasum specially study was done.

Material and methods:

Six samples of abomasum from healthy, diseased free, adult local buffalos obtained from the Mosul abattoir, samples were cleaned and washed with water to remove waste and dirt then sample kept for 48 hours in 10% neutral buffer formalin solution. Routine histological processings performed for samples including dehydration, clearance, and paraffin embedding to obtain casted blocks, later samples were cut using rotary microtome to 5 micrometers thick slides. For general histological study slides were stained with Harris hematoxylin and eosin, Masson trichrome stain to differentiate between connective tissue fibers and muscle fibers, some slides were further stained with periodic acid Schiff reagent for detection of neutral glycoproteins and alcian blue 2.5 stain for detection of acidic glycoproteins, other groups of slides stained with best carmine to observe glycogen and toluidine blue for detection of glycosaminoglycans (7).

Results and discussion

The present study showed pylorus wall of buffalo abomasum formed of four main tunics : mucosa, sub mucosa, muscularis, serosa; the tunica mucosa lined with simple columnar epithelium and having mucosal depressions called gastric pits lined with simple columnar cells (fig 1), which receive the secretion from pyloric glands, this result is similar to that present in abomasum

pylorus of other ruminants, and in pylorus of horse and dog monolocular stomach, where gastric pits lined with simple columnar cells (3, 8). The study showed that the gastric pits mostly occupied the lamina propria of tunica mucosa, this results similar to what's found in ruminants, goats and local sheep (3,9,10). Tunica sub mucosa of pylorus region of buffalo abomasum characterized by presence of lymphoid nodules(fig2), this result agrees with what present in yaks, gaddi sheep and goats (4,11,12). Lymphocytes represent defence mechanism for GIT wall. The study explained that tunica sub mucosa characterized by presence of pyloric glands that are simple, branched, tubular tortuous, secret mucin, open directly to gastric pits, this results similar to what's found in other ruminants (8,9,10). This study confirmed that pyloric glands lined with mucus neck cells and endocrine cells (fig 3), these results agree with what present in cow (13). The study proofed that tunica muscularis distinguished by presence of inner circular layer (fig2) and outer longitudinal layer of smooth muscle fibers, while tunica serosa formed of loose connective tissue covered by mesothelia, this is similar to that present in abomasum of other ruminants (8). The histochemical study confirmed that pyloric region contains mixed glycoprotein of both acidic and neutral types, where acidic glycoprotein is the main type present in terminal glands with few amounts of neutral glycoprotein,(fig4), (table 1), this result is similar to what had seen in kids ,rams ,bull , gaddi sheep , sheep fetuses and cat

(4,11,14,15,16), Result disagrees with what's found in abomasum pylorus of camels (17) and in pylorus of human stomach, where pyloric glands contains neutral glycoprotein only, which responsible for the protective gel barrier (18), and disagree with what's found in pylorus of dogs' stomach, where pyloric glands contain large amounts of neutral glycoprotein and very little amounts of acidic glycoprotein (19), this variation regard to food habits, as mentioned by (20), who notice that the pyloric glands of herbivorus contained predominant amounts of acidic glycoprotein and little amounts of neutral glycoprotein, where as pyloric glands in carnivorous contain predominant amounts of neutral glycoprotein and little amounts of acidic glycoprotein that confirms our results in local buffalos. Current study showed that the mid of pyloric glands in anterior and middle part of pylorus contain large amounts of neutral glycoprotein and little amounts of acidic glycoprotein (fig 5/A), while the mid of pyloric glands contains mainly acidic glycoprotein in the posterior part of pylorus (fig 5/B), this result disagrees with what had seen in gaddi sheep, where mid of glands contains an equal amounts of both neutral and acidic glycoprotein (11), and differ from what's found in ram and bull where acidic glycoprotein present in little amounts in mid of glands (14) and unlike what's revealed in kids, where the mid of glands contains large amounts of both neutral and acidic glycoprotein. Studies (21, 22) showed that acid glycoprotein increased in pyloric glands with aging, this

confirms our results that pyloric glands in adult buffalos contains mainly acidic glycoprotein . Neutral glycoprotein is the main glycoprotein present in gastric pits (fig 6),(table 1),especially in the middle and posterior parts of pyloric region. (fig 7,8), these results agree with what had seen in yak, rams, bull, sheep fetuses , kids and Guinea pigs(4,14,15,16,19).

Surface epithelium of pylorus in local buffalos contains little amounts of neutral and acidic glycoprotein, this result similar to what's founds in (9,21,22).The types of glycoprotein in GIT depending on different parts of GIT, species cell type and function (20). Neutral glycoprotein secreted by pyloric glands is the main component of mucosal gastric barrier, act to protect the wall of pylorus from hydrolysis and from bacterial and viral infections (1,5 ,23). Acidic glycoprotein seems to be a regulatory factor for the mucous viscosity (24), and provides resistance of mucus against the bacterial and viral infections (25). Present study showed glycogen present in large amounts in terminal glands of anterior part of pylorus (fig9/A) and in moderate amounts in middle and posterior parts of pylorus (fig 9/B). Gastric pits contain large amounts of glycogen in the middle and posterior parts of pylorus (fig10/A),(table 2), more than glycogen amount of the anterior part of pylorus (fig10/B). Studies (20,22) showed that the amount of glycogen present in the epithelium of digestive tract may be related to active cellular metabolism in embryonic development .Present study improved that glycosaminoglycans present in terminal

glands in amounts more than that of the middle of the glands (fig 11),(Tab 3), this result agrees with what's presents in dogs and cats where pyloric glands have strongly metachromatic reaction (18,29).

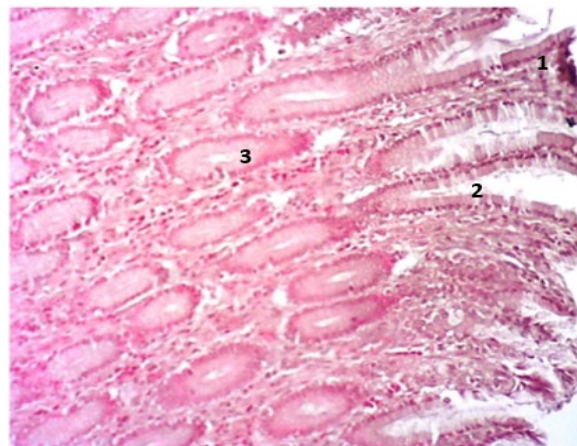


Figure 1:Histological section of pylorus shows: surface epithelium(1), gastric pits(2), pyloric glands(3), H&E 100X.

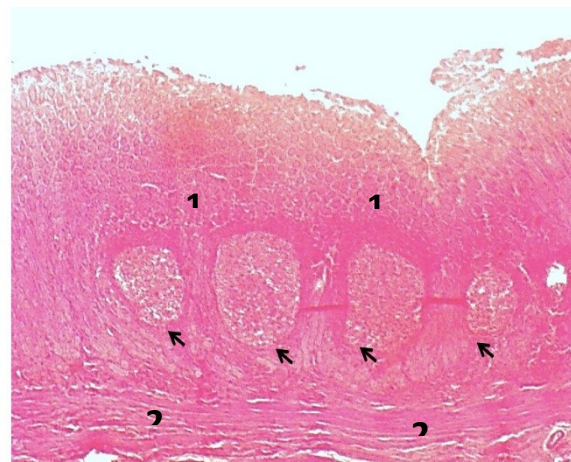


Figure 2:Histological section of the posterior part of abomasum pylorus shows lymph nodules (arrows), pyloric glands (1), inner circular layer of tunica muscularis (2), H&E stain ,40X.

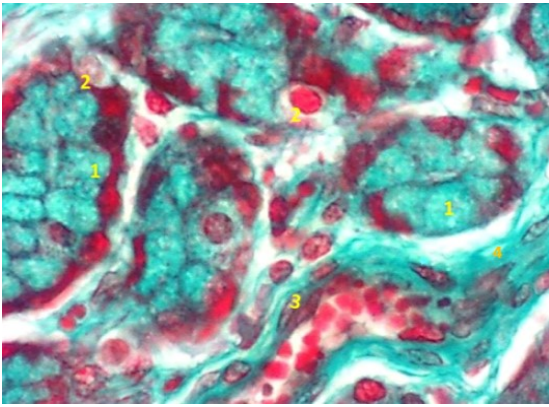


Figure 3: Histological section of pylorus shows pyloric glands lined with : mucous neck cells(1) , endocrine cells(2) ,presence of pericyte around capillary (3),collagen fiber in lamina propria (4), trichrome stain , 400X.

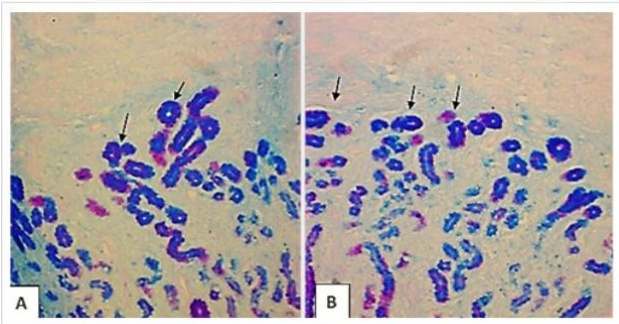


Figure 4: Histological section of pylorus shows terminal pyloric glands(arrow) at anterior part (A), middle part of pylorus (B) ,mixed glands neutral(magenta), acidic(blue), PAS-alcian blue 2.5,100X.

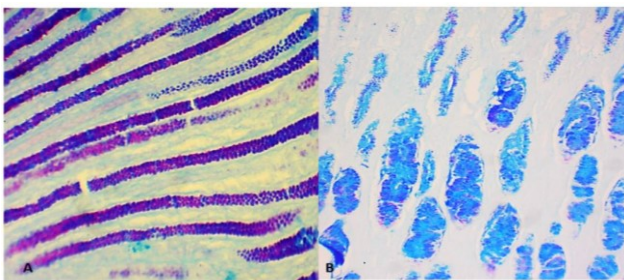


Figure 5: Histological section of pylorus shows neutral (magenta) and acidic (blue) glycoprotein in mid of glands, anterior part (A) , posterior part (B) ,PAS-alcian blue stain ,100X.

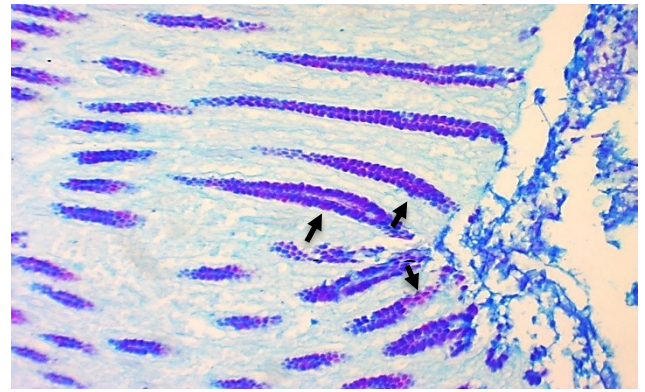


Figure 6 : Histological section of anterior part of pylorus shows gastric pits, acidic glycoprotein(1)(blue) ,neutral glycoprotein(2)(magenta) ,PAS-AB 2.5 ,100X.

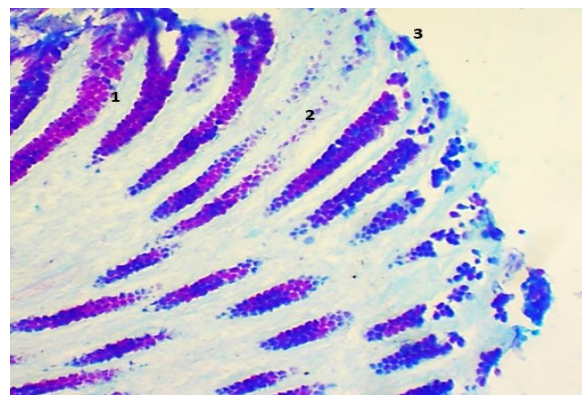


Figure 7: : histological s section of middle part of pyloric shows gastric pit, ,(1) neutral glycoprotein(magenta),(2) acidic glycoprotein (blue) ,(3) surface of epithelium contains acidic glycoprotein PAS,AB 2.5, 100X .

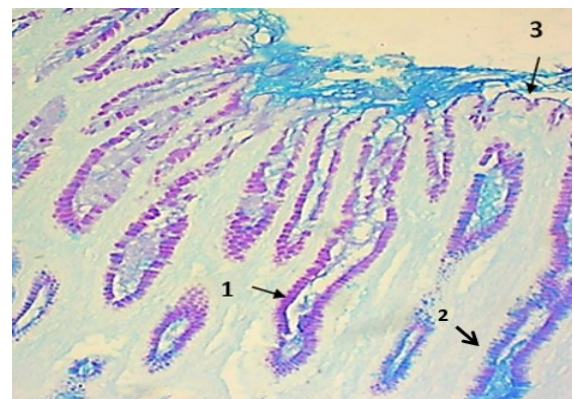


Figure 8: Histological section of posterior part of pylorus shows gastric pits contain neutral glycoprotein(1) with magenta color , acidic glycoprotein(2) with blue color . Surface epithelium contains little amounts of neutral glycoprotein (3), PAS-AB 2.5 ,100X.

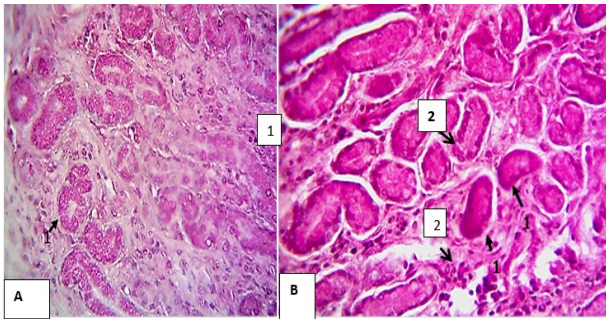


Figure 9: Histological section of pylorus shows terminal glands in anterior part(A) ,and in posterior part(B) , shows glycogen(1) , best carmine stain ,100X.

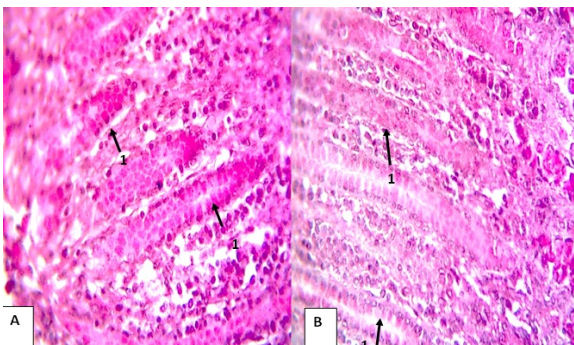


Figure 10: histological section of pylorus shows gastric pits in the anterior part(A) and gastric pit in the middle and posterior part (B), shows glycogen(1) , best carmine stain, 100X.

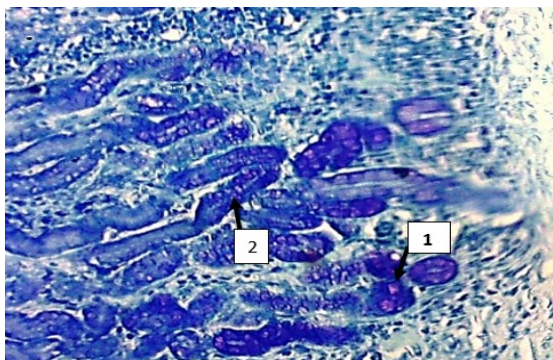


Figure 11: Histological section of pylorus shows glycosaminoglycans present in terminal glands(1), mid of gland(2), toluidine blue stain , 100X.

Table 1: Histochemical response of abomasal tissues to PAS -AB 2.5

Partition of pylorus	Terminal	Mid	Gastric pits	Surface epithelium
Anterior part	Neutral +	Neutral +++	Neutral ++	Neutral ±
	Acidic +++	Acidic ++	Acidic ++	Acidic +
Middle part	Neutral +	Neutral +++	Neutral +++	Neutral ±
	Acidic +++	Acidic +	Acidic ++	Acidic +
Posterior part	Neutral +	Neutral +	Neutral +++	Neutral ±
	Acidic +++	Acidic +++	Acidic +	Acidic -

Table 2: Histochemical response of abomasal tissues to best carmine (glycogen)

Partition of pylorus	Terminal	Mid	Gastric pits
Anterior part	+++	++	++
Middle part	++	++	+++
Posterior part	++	++	+++

Table 3: Histochemical response of abomasal tissues to toluidine blue (glycosaminoglycans)

Partition of pylorus	Terminal	Mid	Gastric pits
Anterior part	++	+	-
Middle part	++	+	-
Posterior part	++	+	-

Conclusion

Presence of neutral glycoprotein mainly in gastric pits confirms that neutral glycoprotein is the main part of mucosal gastric barrier, while presence of acidic glycoprotein mainly in terminal glands confirms presence of mucous neck cells which

Conflict of interest

Authors declared that there is no conflict of interests.

References:

- 1-Parish J. Ruminant digestive anatomy and function. Beef Production Strategies. 2011. Pp 2-3.
- 2-Dyce, K.M., Sack, W.O. And Wensing, C.J.G. Textbook Of Veterinary Anatomy-E-Book. Elsevier Health Sciences. 2009 :Pp 134-139
- 3-Eurell, J.A. And Frappier, B.L. Eds., 2013. Dellmann's Textbook Of Veterinary Histology. John Wiley & Sons. 2013; 253-263
- 4- Wang, J., Zhang, R., Zhang, L., Wang, C., Shao, B. And Wang, J., 2015. Histomorphometric Adaptation Of Yak (*Bos Grunniens*) Abomasum To The Qinghai-Tibetan Plateau Environment. International Journal Of Morphology, 33(2).. [Http://Dx.Doi.Org/10.4067/S0717-95022015000200055](http://Dx.Doi.Org/10.4067/S0717-95022015000200055)
- 5-Linden SK, Sutton P, Karlsson NG, Korolik V, McGuckin MA. Mucins in the mucosal barrier to infection. Mucosal immunology. 2008 May;1(3):183-97.
- 6-Culling, C.F.A., Allison, R.T. And Barr, W.T. Cellular Pathology Technique. Elsevier. 2014.4th ed. London .Better Woth company:212-214
- 7-Luna, L.G.,. Manual Of Histologic Staining Methods Of The Armed Forces Institute Of Pathology. New York, Mcgrowhill,3rdedition.1968:12-16
- 8-Dellman, H. And Brown, E.M.,. Textbook In Histology. Lea & Febiger, Philadelphia, Pa. 1994; Pp.345.
- 9-Ahmad N.S, Histological and morphological and histochemical study of abomasum in local sheep and goat .Master thesis.1995 college of veterinary medicine .Mosul university.Iraq:81-80
- 10-Al-Haaik AG. Comparative histological and morphometrical study on the mucosa of pylorus in the abomasum of local sheep and goat. Iraqi Journal of Veterinary Sciences. 2009;23(Suppl. 1).
- 11-Malik SA, Rajput R, Farooq UB, Rafiq M. Histomorphological, Micrometrical and Histochemical Characteristics of Abomasum in Gaddi Sheep (*Ovis aries*). the indian journal of veterinary sciences and biotechnology. 2018 Apr 8;13(04):20-5.
- 12-Mahesh R, Singh G, Kumar P. Light microscopic studies on the abomasum of goat (*Capra hircus*). Veterinary Res. 2017 Jan;5(1):21-7.[Http://Jakraya.Com/Journal/Pdf/15-Vriarticle_4.Pdf](http://Jakraya.Com/Journal/Pdf/15-Vriarticle_4.Pdf)
- 13-Aage HM, Bhosale NS, Kadam SD, Kapadnis

- PJ. Histomorphological study of abomasum in cattle. *Indian Journal of Animal Research*. 2007;41(3):192-5.
<https://Arccjournals.Com/Journal/Indian-Journal-Of-Animal-Research/ARCC3208>
- 14- Karakoç Z, Sağsöz H, Ketani MA. Mucin profiles of the abomasum in bulls and rams: A comparative study. *Microscopy Research and Technique*. 2016 Sep;79(9):856-68.
<https://doi.org/10.1002/Jemt.22713>
- 15- Özbek M, Ergün E, Beyaz F, Ergün L, Özgenç Ö, Erhan F. Prenatal development and histochemical characteristics of gastrointestinal mucins in sheep fetuses. *Microscopy Research and Technique*. 2018 Jun;81(6):630-48.
- 16-Shibata T, Imai M, Moriguchi K, Takada Y. Comparative histology and histochemistry of the gastric glands of cats and dogs. *Okajimas folia anatomica japonica*. 1990 Oct 20;67(4):249-
- 17- Raji AR. Morphological and histochemical investigation of the camel (*Camelus dromedarius*) abomasal mucous membrane by light and scanning electron microscopy (SEM).
<https://dx.doi.org/10.22099/Ijvr.2011.81>
- 18- Poddar S, Jacob S. Mucosubstance histochemistry of Brunner's glands, pyloric glands and duodenal goblet cells in the ferret. *Histochemistry*. 1979 Jan;65(1):67-81.
<https://doi.org/10.1007/BF00496687>.
- 19-Spicer SS, Sun DC. Carbohydrate histochemistry of gastric epithelial secretions in dog. *Annals of the New York Academy of Sciences*. 1967 Jan;140(2):762-83.
<https://doi.org/10.1111/J.1749-6632.1967.tb51002.x>
- 20-Burkle W., unter suchunge under die pylorus and duodenal drusen .*zmiker .anat. forsch*.1950; 56,327-414 .
- 21- Karakoç Z, Topaloğlu U, Ketani MA. Composition of abomasal mucins in hair goats. *Biotechnic & Histochemistry*. 2021 Jul 4;96(5):384-93.
- 22- Singh O, Kumar A, Roy KS, Sethi RS. Histomorphological study on abomasum of buffalo during prenatal development. *Indian Journal of Animal Sciences*. 2012 Jun 1;79(6):571.
<https://www.cabdirect.org/cabdirect/abstract/20093186261>
- 23- Paracosh P.R., Malik, M.R., , A quantitative histological study of abomasum of buffalos and cow, *Ind.j.Anim.sci*, 1977; 47
- 24- Liquori G.L., Mastrodonta M., Zizza M, Ferri S., glycoconjugated histochemistry of digestive system in torturous conifex , *J.Histology.Mol*. 2007;83(3):191-199.
- 25-Corfield AP. The interaction of the gut microbiota with the mucus barrier in health and disease in human. *Microorganisms*. 2018 Aug 2;6(3):78.
- 26- Slomiany BL, Liao YH, Li Q, Fekete Z, Slomiany A. Role of sulphation in post-translational processing of rat salivary mucins.

Archives of oral biology. 1991 Jan 1;36(11):785-90.

27- Smith LS. Digestive functions in teleost fishes. Fish nutrition. USA San Diego ,Academic press. 1989:331-421.

28- Lev R. A histochemical study of glycogen and mucin in developing human foetal epithelia.The Histochemical Journal. 1968;1(2):152-65.

<https://doi.org/10.1007/BF01002585>

29-Franco, A.J., Masot, A.J., Aguado, M.C., Gómez, L. And Redondo, E., Morphometric And Immunohistochemical Study Of The Rumen Of Red Deer During Prenatal Development. Journal Of Anatomy. 2004,204(6), Pp.501-513.

[.https://dx.doi.org/10.1111%2Fj.1469-7580.2007.00772.x](https://dx.doi.org/10.1111%2Fj.1469-7580.2007.00772.x)