

Dynamic Contrast Enhanced Magnetic Resonance Imaging in Pathological Nipple Discharge

Balsam Muzahim Balasim, Sahar Basim Ahmed***

ABSTRACT:

BACKGROUND:

Generally, nipple discharge represents a benign etiology. In the case where the discharge is unilateral, uniductal, spontaneous, persistent, serous or bloody, and in the case where it occurs in conjunction with a mass, the risk of malignancy is increased. Ductal ectasia and papilloma are the most common causes of pathological nipple discharges. Malignancy is a possibility, most often ductal carcinoma in situ.

OBJECTIVE:

To determine the value regarding dynamic contrast improved magnetic resonance imaging (MRI) in diagnosing suspicious nipple discharge.

METHOD AND PATIENTS:

Dynamic contrast MRI was used to assess 35 patients who have pathological nipple discharges. The features of MRI have been studied and associated to the histo-pathology.

RESULTS:

Histopathology indicated 11 high-risk, 17 benign, and 7 malignant lesions. The presence of non-mass and mass enhancements, as well as T2 weighted MRI images, had statistical significance in distinguishing malignant from benign causes of the pathological nipple discharges ($P_{\text{value}}=0.004$ and 0.008) (0.018, 0.008, 0.004).

94.1% specificity and 94.4% sensitivity in distinguishing benign from malignant pathological nipple discharge causes, and 94.3% accuracy in diagnosing breast lesions, with positive predictive value of 94.4% as well as a negative predictive value of 94.1%.

CONCLUSION:

MRI is a powerful technique for determining the cause of pathological nipple discharge.

KEYWORDS: Pathological, Nipple discharge, MRI.

INTRODUCTION:

Nipple discharge:

Nipple discharges are very prevalent, with a 5% to 10% prevalence, and is the 3rd most common breast complaint following the lumps and pain^(1,2). In the case where it happens in a spontaneous manner and is persistent, bloody, serous, or unilateral along with people who aren't breastfeeding or pregnant, it is regarded concerning. The most common benign nipple discharge cause is the benign lesions like ductal ectasia (which affects 6-59% of the cases) and papilloma (which affects 35-56% of cases)⁽³⁾. The probability of an underlying malignancy isn't insignificant, where it ranges between (5 and 23) %.⁽²⁾

Intraductal papilloma: Intraductal papilloma can be defined as one of the benign tumors that develops in the ducts of the breast. The growth is caused by the abnormal proliferation of ductal epithelial cells. In addition, solitary intraductal papilloma affecting the central duct is typically seen centrally posterior to the nipple. Multiple intraductal papillomas damage the peripheral ducts and can be detected in any breast quadrant⁽⁴⁾. Because of its links to ductal carcinoma in situ (DCIS), atypia, and carcinoma, it has been classed as high-risk precursor lesion⁽⁴⁾. The suggested treatment is surgical excision with full tumor removal⁽⁵⁾.

Mammary duct ectasia (MDE):

MDE affects the areola complex and nipple and is one of the non-proliferative inflammatory disorders regarding large duct (i.e. milk duct) of breast⁽⁶⁾.

*Al Sheikh Zayid Hospital, Baghdad, Iraq

**Al Yarmouk Teaching Hospital, Baghdad, Iraq

MAGNETIC RESONANCE IMAGING IN PATHOLOGICAL NIPPLE DISCHARGE

In GLM (i.e. granulomatous lobular mastitis), a disease which can be linked to the ectasia of mammary duct, ulceration and skin necrosis are the significantly more common. Nonetheless, with GLM, the palpable mass extends out from nipple-areola complex. In the case where you get a secondary bacterial infection, you could get an abscess or a subareolar infection (7,1). On non-contrasted MRI, the morphologic features of MDE are vague, yet on dynamic contrast-enhanced (DCE)-MRI, thick-walled lesions that have circular enhancement without any enhancements in center, which resembles thicker pipe, depicting thickened duct. The delayed phase shows no enhancement, but malignant masses show heterogeneity with apparent irregular borders. (8).

Fibrocystic breast disease:

The most frequent benign type of breast disease is fibrocystic breast disease (9). Throughout hormonal fluctuations, the primary components of the breast are susceptible to fibrocystic changes (10). The researchers discovered two types of fibrocystic changes in the breast: focal type and diffuse type. Each kind has distinct morphological characteristics, with the diffuse type exhibiting non-mass enhancement and the focused type exhibiting mass enhancement. In the case when FCC appeared with a non-mass type lesion, particularly regional enhancement, the enhancement kinetics were typically benign, with a low magnitude of the enhancement on the MRI, while the majority of focal type FCC lesions had malignant kinetics that are similar to the breast cancers (11).

High risk lesion:

Breast atypical hyperplasia is described as abnormal epithelial proliferative lesions that are neither quantitatively nor qualitatively abnormal enough to be diagnosed as carcinoma in situ. Atypical hyperplasia represents a type of premalignant hyperplasia that can affect either the ductal or lobular epithelium (12).

Ductal carcinoma in situ (DCIS):

The malignant epithelial cells' proliferation inside mammary ductal system without affecting the basement membrane is known as DCIS. There's no sign of invasion into the stroma around it. This lesion, which represents a precursor to the invasive ductal carcinoma, is a precursor to invasive ductal carcinoma (13). DCIS is responsible for 20–25% of all of the newly-diagnosed breast cancer cases (14).

Invasive carcinoma:

According to its relationship to the basement membrane, breast cancer can be non-invasive or invasive. The two predominant kinds of noninvasive breast neoplasms are DCIS and lobular carcinoma in situ (LCIS) (15).

Magnetic Resonance Mammography (MRM):

Even though ultrasound and mammography are the most often utilized techniques for breast imaging, contrast enhanced MRI is becoming more and more important, owing to its high sensitivity for detecting invasive breast cancer (16). In addition, breast MRI has been used to evaluate mammographically occult lesions of the breast, detect recurrences of the tumor, and screen people who have high-risk cancers and the ones who have breast implants (17).

Morphological MRI assessment:

T1WI pre-contrast examination is useful for detecting lesions and providing extra information on structural changes, architectural distortions, therapy-induced and/or artificial changes, and fatty inclusions within ambiguous lesions (18). Non-enhancing lesions and enhancing lesions are the two types of MRI lesions that could be assessed. The findings of the enhancing lesions are categorized into three categories: mass, focus, and non-mass enhancement (NME) (19).

1. *Focus/Foci:* A focus is an enhancing dot, typically not more than 5 mm, that is too small to describe morphologically and does not appear on the pre-contrast scan (19).
2. *Masses* (19). A mass is a 3-D space-occupying lesion which must be assessed for the following characteristics: the mass shape might be oval (including lobulated), irregular, or round. It is possible to not circumscribe or circumscribe a mass margin (spiculated, irregular). Generally, circumscribed masses are indicative of benign lesions, whereas non-circumscribed masses are indicative of carcinoma (19). Internal mass enhancements can include heterogeneous or homogeneous enhancements, along with rim enhancement and dark internal septations which do not improve.

A benign process is indicated by homogeneous and non-enhancing dark internal septation. Malignant lesions are more characterized by heterogeneous and rim enhancement. Non-enhancing masses with benign form almost often turn out to be benign (19)

MAGNETIC RESONANCE IMAGING IN PATHOLOGICAL NIPPLE DISCHARGE

3. Non mass like Enhancement NME: This is a type of enhancing abnormality which differs from BPE in that it lacks a three-dimensional volume, margin, or shape—in other words, it lacks the qualities that allow it to be classified as a mass. Characterization of enhancement distribution and internal properties are part of the investigation of such lesions⁽²⁰⁾. The enhancement is defined as a focal area, segmental, linear, regional, many regions, or diffuse, according on how it is distributed. NME's patterns of internal enhancement have been classified into heterogeneous, homogeneous, clumped, or clustered rings. The clustered ring enhancement pattern is critical to notice since it is most frequently linked with ductal carcinoma in situ⁽²²⁾.

Kinetic Curve Assessment DCE-MRI is a type of MRI that uses a curve of time-signal intensity, which has also been referred to as a kinetic curve, that is acquired by the repeated images of MRI following contrast agent injections. TICs (time-signal intensity curves) have been created. The shape of TICs is commonly classified as persistent enhancing (Type1), plateau (Type2), or washout (Type3) in this approach⁽²³⁾.

PATIENTS AND METHODS STUDY SAMPLE:

A cross section analytic study was performed at Al-Yarmouk Teaching Hospital in Baghdad within the period from Jan. 2020 to Jan. 2021. A total of 35 females with pathological nipple discharge the study include Female complaining from pathological nipple discharges which occur spontaneously, bloody, serous or unilateral in patient. Age from 31 to 62 years with an average age of 44.91 years and standard deviation (SD) of ± 8.86 .

IMAGING ANALYSIS:

On the workstation, all of the images were examined. On the dynamic subtracted image, T1, T2, and T2 fat suppression weighted images, each lesion was recognized. The intensity of the lesion signal and the pattern of enhancement have been investigated. On dynamic MR images, the time-signal intensity curves have been constructed by placing ROI at the lesion's most enhancing area. The results of an MRI scan were evaluated. Image analysis was done by two radiologist blinded to the histopathology results for the unusual SPAIR signal intensity, the existence of mass, ductal, or non-mass enhancements of the lesions that have been detected. Each lesion's enhancement kinetics

were assessed, and curve types have been identified based on delayed-phase enhancements as type I=persistent, II-plateau, and III-washout curves.

Pattern of Enhancement Analysis:

Lesions were arranged into enhancing lesion either a focus, a mass or a non-mass-like enhancement area and non-enhancing lesion. The enhancement kinetic curve was used to analyze the enhancing mass and non-mass. Curve types have been characterized based on the delayed phase enhancements as persistent curve of Type I (constant signal intensity increase on every one of the successive images that have been contrast-enhanced), plateau Type II curve (initial signal intensity increase has been succeeded by an enhancement curve flattening), washout Type III curve (initial increase as well as a consequent decrease in the value of the signal intensity). Masses that are rounded, round, with a well-circumscribed margin, non-enhancing lesion, high signal on T1 or T2 imaging, fat SI on T1WI, and non-mass improvements in the regional or focal distributions are all regarded benign findings. None-the-less, existence of masses that are irregular in shape or irregular and spiculated margin with heterogeneous enhancements, and non-mass enhancements of linear or segmental distribution especially those with clumped internal enhancement pattern, were considered as a feature suggestive of malignant finding.

Regarding the kinetic analysis, persistent curve was defined as probable benign. On the other hand, washout curve was considered as probable malignant finding while the plateau curve was considered as intermediate finding and interpreted according to the morphological analysis.

Lastly, the dynamic contrast improved MR image have been interpreted based on BIRADs criteria on bases of morphological and kinetic findings, lesions have been classified into one of 5 BI- RAD categories:

(BI-RADs I,II,III considered benign), (BI-RADs IV, V considered malignant) categories. When there was non enhancing lesions or BI-RAD I has not been included in the study.

Statistical Analyses

Data had been analyzed with the use of the Statistical Package for Social Sciences (SPSS) v. 25.

MAGNETIC RESONANCE IMAGING IN PATHOLOGICAL NIPPLE DISCHARGE

RESULTS:

A total of 35 females have participated as subjects of this study. All of them were complaining from pathological nipple discharge.

Clinical Characteristics

The distribution of study patients by certain clinical characteristics as mentioned in the following:

Patients' age has been ranging from 31 to 62 years with an average of 44.91 years and standard deviation (SD) of ± 8.86 years. More than half of females (58.8%) were found in the age group of (40-50) years. Nipple discharge was left sided in

20 (57.1%) of females, right sided in 15 (42.8%), and regarding type of nipple discharge, bloody

discharge was found in 14 (40%) of patients, while serous and serosanguinous discharge was found in 12 (34.3%) and 9 (25.7%) of patients, respectively.

Histological findings :

The distribution of study patients according to histological findings is shown in table (1). Benign lesions were 10 (28.6%) duct ectasia, 4 (11.4%) fibrocystic change, and 3 (8.6%) duct papilloma. High risk lesions were 11 (31.4%) atypical epithelial hyperplasia, while malignant lesions were 5 (14.3%) IDC, and 2 (5.7%) DCIS.

Table 1: Distribution of the study patients according to histological findings.

Histopathological Findings	No. (n= 35)	Percentage (%)
Benign Lesions		
Duct Ectasia	10	28.6
Duct Papilloma	3	8.6
Fibrocystic Changes	4	11.4
High Risk Lesion		
Atypical Epithelial Hyperplasia	11	31.4
Malignant Lesions		
IDC	5	14.3
DCIS	2	5.7

MRI The distribution of study patients by histological diagnosis and MRI findings is shown in table (2). There has been statistically significant association ($P= 0.008$) between the histological diagnosis and type of mass enhancement, all of

the patients with heterogeneous and rim enhancements had malignant lesions. Concerning non- mass improvement, the proportion of linear enhancement has been considerably higher in malignant lesions (71.4%, $P= 0.008$).

Table 2: Distributions of the histopathological diagnosis by type of enhancement.

Type of Enhancement	Histopathological Diagnosis		Total (%) n= 35	P- Value
	Malignant Lesions (%) n= 18	Benign Lesions (%) n= 17		
Mass Enhancement				
n= 8				
Homogenous	0 (0)	3 (100.0)	3 (8.57)	0.018
Heterogeneous	2 (100.0)	0 (0)	2 (2.85)	
Rim	3 (100.0)	0 (0)	3 (8.57)	
Shape				
Rounded	1(33.3)	2(66.6)	3	
Oval	1(50.0)	1(50.0)	2	
Irregular	3(100)	0(0)	3	
Margin Circumscribed	2(40)	3(60)	5	
Margin Non circumscribed	3(100)	0(0)	3	
Non- Mass Enhancement				
Segmental	6 (85.7)	1 (14.2)	7 (20)	0.008
Linear	5 (71.4)	2 (28.5)	7 (20)	
Foci	0 (0)	3 (100.0)	3 (14.2)	
Focal	2(100)	0(0)	2(7.4)	
Regional	2 (25.0)	6 (75.0)	8 (22.9)	

MAGNETIC RESONANCE IMAGING IN PATHOLOGICAL NIPPLE DISCHARGE

In this study, there was a significant association (P= 0.004) between histological diagnosis and T2 image. All of the seven females with hypo-intense T2 images had malignant lesions (Table 3). A statistically significant correlation has been found between histological diagnosis and type of kinetic curve. The proportion of type III was significantly higher among the malignant lesions (85.7%, P=

0.046). In this study, there was a significant association (P= 0.004) between histological diagnosis and T2 image. All of the seven females with hypo-intense T2 images had malignant lesions (Table 3). A statistically significant correlation has been noticed between histological diagnosis and type of kinetic curve. The proportion of type III was significantly higher among the malignant lesions (85.7%, P= 0.046)

Table 3: Distribution of histopathological diagnosis by MRI sequence, type of kinetic curve.

MRI Sequence	Histopathological Diagnosis		Total (%) n= 35	P- Value
	Malignant Lesions (%) n= 18	Benign Lesions (%) n= 17		
T1				
Hypo-intense	17 (51.5)	16 (48.5)	33 (94.3)	0.967
Hyper-intense	1 (50.0)	1 (50.0)	2 (5.7)	
T2				
Hypo-intense	7 (100.0)	0 (0)	7 (20.0)	0.004
Hyper-intense	11 (39.3)	17 (60.7)	28 (80.0)	
SPAIR T2				
Hypo-intense	0 (0)	1 (100.0)	1 (2.9)	0.296
Hyper intense	18(52.9)	16(47.1)	34(97.1)	
Type of Kinetic Curve				
Type1	5 (31.3)	11 (68.8)	16 (45.7)	0.046
Type2	7 (58.3)	5 (41.7)	12 (34.3)	
Type3	6 (85.7)	1 (14.3)	7 (20)	

Dynamic post contrast MRI (show 10 /35 BIRAD II & 7 of 35 were categorized as BI-RAD III only one was malignant), while (14 of 35 BI-RAD IV eleven of them were high risk and two were malignant IDC and DCIS) and (all cases three out

of 35 were BI-RADV were diagnosed as malignant IDC and DCIS).

So, in conclusion of this study, MRI was 94.4% sensitive, 94.1% specific, and 94.3% accurate in diagnosis of breast lesions, with PPV of 94.4%, and NPV of 94.10%.

MAGNETIC RESONANCE IMAGING IN PATHOLOGICAL NIPPLE DISCHARGE

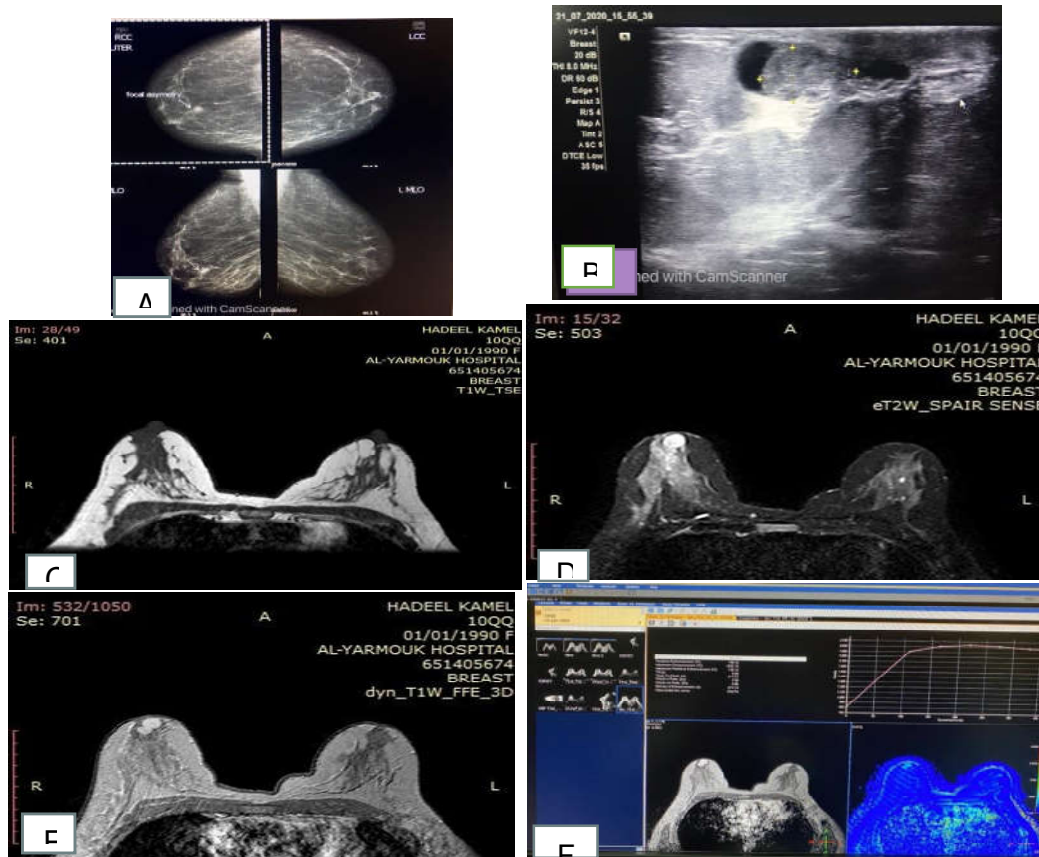


Figure1: 31 years old female with spontaneous right sided bloody nipple discharge (A)craniocaudal and Medio lateral view mammography showing focal asymmetry in the inner lower aspect of rt breast (B) transverse scan B mode US showing small intra-ductal soft tissue in Rt retro areolar region (c)T1 weighted (D)T2 weighted with the suppression of the fat (E) dynamic T1 WI (F)time intensity image: Rt retroareolar well circumscribed obulated lesion hypointense in T1 hyperintense in T2 SPAIR homogenous enhanced in dynamic T1 with type I II plateau curve .Histopathological results after core biopsy revealed intraductal papilloma

DISCUSSION:

In clinical practice, nipple discharges are a fairly common symptom, and it's typically caused by benign condition. Yet, in the case where it's particularly spontaneous and has bloody serous-bloody content, indicating pathological type, it must be thoroughly examined to rule out malignancies. In this investigation, benign diseases (48.6%) were shown to be the most common pathological nipple discharge cause, whereas high-risk lesions (31.4%) and malignancy (20%) were also observed.

According to Zaky et al. (24), the most common cause of PDN was benign diseases (74.2%), with

high-risk lesions and malignancy accounting for 25.80% of the cases. According to Paul *et al.* (25), the most common nipple discharge causes have been benign lesions of the breast like the ductal ectasia (6–59% of the cases) and papilloma (35–56% of the cases). The risks of an underlying malignancy are not insignificant, ranging between 5 and 23%. On MRI, papilloma manifested as enhanced mass, enhanced focus, and non-mass enhancements with various kinetics, according to Zaky et al. (24). Previous research has found some similarities in MRI results between papillomatosis, papilloma, and carcinoma (4,26).

MAGNETIC RESONANCE IMAGING IN PATHOLOGICAL NIPPLE DISCHARGE

In this study, there was a statistically significance association between the histological diagnosis and type of mass enhancement all of the patients with heterogenous and rim enhancement had malignant lesions.

Concerning non-mass enhancements, the proportion of linear enhancement has been found significantly higher in malignant lesions of about (71.4%).

It has been noted that there is a higher rate of lesion detections by the MRIs with agreement with pathological finding.

Dynamic MRI detects (17/18) of lesions and linear non mass enhancement of roughly (5/17) of the 50.4% of malignant and high-risk lesions confirmed by histopathology in this work (n=18). Giovanna et al (27). Conventional imaging techniques failed to detect the existence of cancer in 34% of malignant lesions that have been confirmed by the histology (10/29), and five individuals were later diagnosed with DCIS and three with a malignancy with an in-situ component. MRI indicated the presence of linear NME in all of such instances. In a case of negative conventional imaging, Bahl *etal.* (28) showed that the breast MRIs are an important additional diagnostic tool. Furthermore, in such symptomatic population, a negative MRI could eliminate the necessity for invasive surgeries.

In this study, MRI feature of the IDC with the DCIS, all of them masses are irregular in their shape with heterogenous or rim enhancement (100%) respectively or non-mass enhancement of linear(71%) or segmental(85%) distributions and clumped pattern on post contrast study also high percent of about (71.4%) of non -mass enhancement seen more in bloody nipple discharge, the proportion of type III kinetic curve has been significantly higher among malignant lesion which (85.7%) and also there has been a significant correlation between the T2 image and histopathological diagnoses, due to all seven female with hypo intense T2 image had malignant lesions.

On post contrast analysis, Zaky *etal* (24) discovered that all masses in IDC with DCIS have been of irregular shape with non-circumscribed margins and have shown either heterogeneous or rim enhancements with related non-mass enhancements of the clumped pattern.

Manganaro et al.(29) discovered a statistically significant link between mass enhancement and papilloma (P less than 0.001), ductal improvement and papillomatosis (P less than 0.001), segmental enhancement and DCIS (P = 0.0070), and linear enhancement and papillary cancer (P = 0.011). The researcher also discovered that the use of T2 and T1 precontrast sequences, MRI revealed imaging findings that did not allow us to identify underlying disease alone that was leading to the pathologic discharge, yet, also the enhancement of the surrounding parenchyma. This aspect provided an overall assessment of the condition.

Recent researches have highlighted the usefulness of dynamic MRI in patients with pathological nipple discharge whose condition cannot be detected using standard imaging techniques. In our work, MRI had a specificity of 94.1%, sensitivity of 94.4%, and a PPV of approximately (94.4%).

With an exception of findings that have been indicated via Manganaro, *etal.*, Giovanna et al. (27) specified that dynamic MRI had high level of sensitivity (93.10%, 27/29) for the detection and diagnosis of the breast lesion, supporting many earlier researches which have confirmed dynamic contrast enhancement MRI as most sensitive diagnostic technique for the detection of the breast cancer, and the specificity (90%, [45/50]) and PPV (84.30%, [27/32]) have been higher than previously indicated values (29). According to the study, MRI had a higher sensitivity (97.78% vs. 48.89% galactography sensitivity) for detecting ductal pathologies, whereas the two techniques had 100% specificity.

CONCLUSION:

Various causes of pathologic nipple discharge (malignant and benign) can be diagnosed using dynamic MRI

1. MRI is very effective tool in evaluation of pathological nipple discharge and can be used for further on patients work up if ultrasound is inconclusive to detect the intraductal lesions
2. In the case where there's intraductal echogenicity, confirm intra-ductal mass lesion and rule out inspissated secretion, particularly in young females, in order to preserve the duct system and distinguish the benign lesions from the suspicious ones.
3. When the breast parenchyma is heterogeneous and asymmetric, MRI could be more revealing in the United States.

REFERENCES:

1. Lippa N, Hurtevent-Labrot G, Ferron S, et al. Les écoulements mamelonnaires. *Journal de Radiologie Diagnostique et Interventionnelle*. 2015;96:434–450. [Google Scholar].
2. Chen L, Zhou WB, Zhao Y, et al. Bloody nipple discharge is a predictor of breast cancer risk: a meta-analysis. *Breast Cancer Res Treat*. 2012;132:9–14. [PubMed] [Google Scholar].
3. van Gelder L, Bisschops RH, Menke-Pluymers MB, et al. Magnetic resonance imaging in patients with unilateral bloody nipple discharge: useful when conventional diagnostic are negative? *World J Surg*. 2015;39:184–186. [PubMed] [Google Scholar].
4. Çetin K, Sıkar HE. Evaluation and management of pathological nipple discharges without using intraductal imaging methods. *Ir J Med Sci*. 2020 May;189(2):451-460. [PubMed].
5. Hamwi, M. Walid, and Ryan Winters. “Mammary Duct Ectasia.” In StatPearls. Treasure Island (FL): StatPearls Publishing, 2020.
6. Chen, Jeon-Hor, Hui Liu, Hyeon-Man Baek, Orhan Nalcioğlu, and Min-Ying Su. “MR Imaging Features of Fibrocystic Change of the Breast.” *Magnetic Resonance Imaging* 26, no. 9 (November, 2008): 1207–14. <https://doi.org/10.1016/j.mri.2008.02.004>.
7. Myers, David J., and Andrew L. Walls. “Atypical Breast Hyperplasia.” In StatPearls. Treasure Island (FL): StatPearls Publishing, 2021. <http://www.ncbi.nlm.nih.gov/books/NBK470258/>.
8. Vaidya, Yash, Pradeep Vaidya, and Tanvi Vaidya. “Ductal Carcinoma In Situ of the Breast.” *The Indian Journal of Surgery* 77, no. 2 (April 2015): 141–46. <https://doi.org/10.1007/s12262-013-0987-0>.
9. Alkabban, Fadi M., and Troy Ferguson. “Breast Cancer.” In StatPearls. Treasure Island (FL): StatPearls Publishing, 2020. <http://www.ncbi.nlm.nih.gov/books/NBK482286/>.
10. Morrogh M, Morris EA, Liberman L, et al. The predictive value of ductography and magnetic resonance imaging in the management of nipple discharge. *Ann Surg Oncol*. 2017;14:3369–3377. [PubMed] [Google Scholar]
11. Grainger RG, Allison DJ, Dixon AK, et al. Grainger & Allison's diagnostic radiology: a textbook of medical imaging. Edinburgh: Churchill livingstone/Elsevier; 2015.
12. Jiang L, Li X, Sun B, Ma T, Kong X, Yang Q. Clinicopathological features of granulomatous lobular mastitis and mammary duct ectasia. *Oncol Lett*. 2020 Jan;19(1):840-848. [PMC free article] [PubMed]
13. Sharma U, Sah RG, Agarwal K, et al. Potential of Diffusion-Weighted Imaging in the Characterization of Malignant, Benign, and Healthy Breast Tissues and Molecular Subtypes of Breast Cancer. *Frontiers in Oncology*. 2016; 6.
14. M. Lorenzon, C. Zuiani, A. Linda, V. Londero, R. Girometti, M. Bazzocchi. Magnetic resonance imaging in patients with nipple discharge: should we recommend it? *Eur Radiol*, 2011;21:899-907 CrossRefView Record in ScopusGoogle Scholar
15. Prince JL, Links JM. Medical imaging signals and systems. Upper Saddle River, NJ: Pearson Prentice Hall; 2006.
16. Yılmaz R, Bender O, Yabul FC et al (2017) Diagnosis of nipple discharge: value of magnetic resonance imaging and ultrasonography in comparison with ductoscopy. *Balkan Med J* 34:119–126
17. Zaky, Mona M., Asmaa Hafez, Marwa M. Zaky, Ashraf Shoma, Nermin Y. Soliman, and Ali H. Elmokadem. “MRI for Assessment of Pathologic Nipple Discharge: Is It Mandatory?” *Egyptian Journal of Radiology and Nuclear Medicine* 50, no. 1 (December 17, 2019): 92. <https://doi.org/10.1186/s43055-019-0105-9>
18. Yang, Shih-Neng, Fang-Jing Li, Jun-Ming Chen, Geoffrey Zhang, Yen-Hsiu Liao, and Tzung-Chi Huang. “Kinetic Curve Type Assessment for Classification of Breast Lesions Using Dynamic Contrast-Enhanced MR Imaging.” *PLoS ONE* 11, no. 4 (April 7, 2016). <https://doi.org/10.1371/journal.pone.0152827>
19. Dorsi CJ, Mendelson EB, Ikeda DM, et al. ACR breast imaging and reporting data system: breast imaging atlas. Reston, VA: American College of Radiology; 2013.

20. Breast Imaging Reporting & Data System | American College of Radiology.” Accessed April 11, 2021. <https://www.acr.org/Clinical-Resources/Reporting-and-Data-Systems/Bi-Rads>.
21. Glassman L, Hazewinkel M. The Radiology Assistant: Breast - MRI [Internet]. Radiology assistant. 2009 [cited 2017Dec30].
22. Uematsu T, Kasami M. High-spatial-resolution 3 Breast MRI of nonmass like enhancement lesions: An analysis of their feature sassing if I can't predictors of malignancy. *AJR Am J Roentgenol* 2012; 198:1223–30.
23. Kuhl C. The current status of breast MR imaging part I. Choice of technique, image interpretation, diagnostic accuracy, and transfer to clinical practice. *Radiology*. 2007; 244:356-78.
24. Zaky, Mona M., Asmaa Hafez, Marwa M. Zaky, Ashraf Shoma, Nermin Y. Soliman, and Ali H. Elmokadem. “MRI for Assessment of Pathologic Nipple Discharge: Is It Mandatory?” *Egyptian Journal of Radiology and Nuclear Medicine* 50, no. 1 (December 17, 2019): 92. <https://doi.org/10.1186/s43055-019-0105-9>.
25. Paula IB, Campos AM Breast imaging in patients with nipple discharge. *Radiol Bras* 2017; 50:383–88.
26. Sarica O, Ozturk E, Demirkurek HC et al Comparison of ductoscopy, galactography, and imaging modalities for the evaluation of intraductal lesions: a critical review. *Breast Care* 2013; 8:348–54.
27. Giovanna, Panzironi, Galati Francesca, Marzocca Flaminia, Kirchin Miles, and Pediconi Federica. “Diagnostic Accuracy of Breast MRI Compared with Conventional Imaging, in the Evaluation of Patients with Suspicious Nipple Discharge.” *International Journal of Biological Instrumentation* 1, no. 1 (December 31, 2018). <https://doi.org/10.35840/2631-5025/5103>.
28. Bahl M, Baker JA, Greenup RA, et al. Diagnostic value of ultrasound in female patients with nipple discharge. *AJR Am J Roentgenol*. 2015;205:203–208. [PubMed] [Google Scholar]
29. Manganaro, Lucia, Ilaria D’Ambrosio, Silvia Gigli, Francesca Di Pastena, Guglielmo Giraldi, Stefano Tardioli, Marialuisa Framarino, Lucio Maria Porfiri, and Laura Ballesio. “Breast MRI in Patients with Unilateral Bloody and Serous-Bloody Nipple Discharge: A Comparison with Galactography.” *BioMed Research International* 2015 (2015): 806368. <https://doi.org/10.1155/2015/80636833>.