

Surgical Outcome and Prognosis of Spinal Missile injuries

Ali Hikmat Azeez*, Nashwan Yaseen Sallama* , Saad A. Yahya Alsaqa*

*Unit of Neurosurgery , Ibn-Sina Teaching Hospital , Ninevah Health Directorate , Mosul , Iraq
Correspondence: alihikmat_aziz@yahoo.co.uk

(Ann Coll Med Mosul 2021; 43 (1):55-59).

Received: 5th Janu. 2021; Accepted: 1st March 2021.

ABSTRACT

Background: The spinal cord is so sensitive to injury. Once it is damaged; it shall lose its ability to repair itself. Unfortunately spinal cord injuries (SCI) are common in Iraq. It could be either complete or incomplete SCI. In the complete injury there is a total loss of sensation and motor function in the level below the site of the injury, while in the incomplete one there is some remaining neurological functions below the level of the injury.

Objectives: The aim of this study is to compare the surgical and conservative management of complete and incomplete spinal cord injuries due to missile in Mosul city.

Patients and methods: A case series study of (60) patients with missile cord injury of the spine who were managed in the Neurosurgical Department at Ibn-Sina Teaching Hospital in Mosul from August 2011 – August 2013. The mean patient age was 30 years. Thirty three (55%) patients were surgically treated. The mean time of follow up was 9 months ranged from 6-18 months. All patients had complete radiological assessment, CT scan and one patient with through and through bullet injury magnetic resonance imaging (MRI) was done after initial resuscitation.

Results: All patients with complete spinal cord injury did not improve after non-surgical management, after surgical removal of bullet and its pressure effect from the spinal cord just one case with conus medullaris injury gets improvement. Those with incomplete injuries show good improvement after surgical management.

Conclusion: Conus medullaris and cervical injuries show a better outcome in surgical treatment than those out surgical intervention in incomplete spinal cord injuries. There were no difference between the outcomes of surgical and non-surgical management of complete neurological injuries of the spinal cord.

Keywords: Missile injuries, spinal cord injuries, surgical management and non-surgical management.

النتائج الجراحية لمعالجة إصابات المقذوف الناري للحبل الشوكي والعمود الفقري

علي حكمت عزيز المولى* ، نشوان ياسين سلامة* ، سعد عبد الجبار السقا*
*شعبة جراحة الجملة العصبية ، مستشفى ابن سينا التعليمي ، الموصل ، العراق

الخلاصة

خلفية الدراسة : الحبل الشوكي عالي التحسس للإصابة ولا تستطيع خلاياه بناء نفسها بعد الإصابة . إصابات الحبل الشوكي لسوء الحظ كثيرة في العراق.

وتكون إما إصابة كاملة تؤدي إلى فقدان الحركة والحساس الكامل تحت موقع الإصابة . أو إصابة جزئية تؤدي إلى ضرر جزئي.
الاهداف : تم إجراء هذه الدراسة لتقييم نتيجة المعالجة الجراحية مقارنة مع المعالجة غير الجراحية للإصابات الناتجة عن العيارات النارية في العمود الفقري في مدينة الموصل.

المحيط : تم إجراء هذه الدراسة في وحدة الجراحة العصبية في مستشفى ابن سينا التعليمي في مدينة الموصل وللفترة من شهر آب ٢٠١١ وحتى شهر اب ٢٠١٣.

المرضى وطرق العمل: دراسة متسلسلة ل(٦٠) مريض مصابين بجروح ناجمة عن عيارات نارية في العمود الفقري. أجريت الجراحة ل(٣٣) مريض وتمت معالجة ال(٢٧) الآخرين بطريقة غير جراحية . معدل العمر للمرضى كان (٣٠) سنة وقد تراوح بين (١١-٥٤) سنة ومعدل فترة المتابعة كان (٩) أشهر تراوحت بين (٦-١٨) أشهر وقد تمت مقارنة مجموعتي المرضى طبقاً

للتحسن والوفيات. كل المرضى أخضعوا لفحص الرقائق الشعاعية للعمود الفقري وايضا أشعة المفراس الطبقي بعد الانعاش الأولي ومريض واحد اجري له فحص الرنين المغناطيسي حيث دخلت الرصاصية وخرجت.

النتائج : لم يحقق أي من المرضى الذين لديهم إصابات الحبل الشوكي الكاملة شفاء يذكر عند العلاج غير الجراحي. وبعد إزالة الرصاصية أو تخفيف الضغط في العلاج الجراحي هناك مريض واحد تحسنت حالته حيث كان لديه اصابة لنهاية الحبل الشوكي (المخروط النخاعي).

المرضى ذوي الاصابة غير الكاملة (الجزئية) هناك تحسن ملحوظ بعد المعالجة الجراحية

الاستنتاج : التحسن كان أكثر في الإصابات غير الكاملة التي عولجت جراحيا خاصة في المنطقة العنقية ومنطقة المخروط النخاعي من الحالات التي عولجت تحفظيا. ليس هنالك فرق في نوع المعالجة في الإصابات الكاملة .

الكلمات المفتاحية : طلق نارى ، اصابة الحبل الشوكى ، العلاج الجراحي وغير الجراحي .

INTRODUCTION

Although spinal missile injuries (MIs) are not so common in most countries, they are unfortunately common in cities of Iraq due to wars. Traumatic spinal cord injuries (SCI) are a catastrophe for the individual concerned. It leads to Para- or tetraplegia , sphincter and sexual dysfunction.¹

The first who described spinal injuries was an Egyptian Edwin Smith Papyrus from 2500 BC, as an untreatable condition. After that, Hindu wrote up about 1800 BC also mentioned SCI and described traction as an approach for treatment. Later on Hippocrates described SCI in his Corpus and described traction devices to straighten dislocated vertebrae.

In 1762, Andre Louis conducted surgical removal of a bullet from the lumbar spine of a victim, then he could move his legs successfully.²

Gilpin Smith half a century later, performed laminectomy for a patient with SCI with good result. Despite all this history, the idea that SCI is an untreatable condition remained dominant until the early in the past century.³

The spinal cord is very delicate, and does not have the ability to regenerate itself, if it is damaged. The SCI occur when there is damage to the spinal cord either from trauma, loss of its normal blood supply, or compression of any type.

SCI either complete or incomplete injury. In the complete one there is complete loss of motor function and sensation in the body below the level of the injury. In incomplete SCI there is some remaining function below the level of the injury.⁴

SCI in the neck can cause paralysis of both upper and lower limbs. If it is in the lower back, it could cause paraplegia of both lower limbs .

For diagnosis of a SCI, a medical history about the time of injury. since as soon as the patient obtains treatment, the better the likelihood of recovery. Past medical history of any prior back, neck or limb disease, any weakness , loss of

bladder or bowel control, loss of sensation , and any other medical conditions previously.⁵

Also physical examination should include sensation testing to see if touch is intact in the upper and lower limbs as well as testing power of muscles and reflexes in the upper and lower limbs. The patient should be kept on a spine backboard or in a cervical collar for immobilization, until to be sure whether or not the patient has an injury of the spinal cord.⁶

The decision considering the kind of treatment should be made deliberately, in regards to factors such as: grade of SCI, age of the patient , general condition and accompanying injuries. The initial treatment is an integral part of the trauma evaluation, dealing with airway, breathing and circulation in order to achieve stable patient condition(normal vital signs) should be the primary goal according to Advance trauma life support ATLAS.

The surgical intervention for patients with SCI is kept for patients with persistent CSF fistulae, progressive neurological deterioration, and incomplete spinal cord injuries with active neural compression from either an inter vertebral disk, a bullet, or a hematoma within the spinal canal.⁷ and for migrating bullet , lead toxicity, spinal instability as a late complication.

Otherwise conservative management is considered.

OBJECTIVES

The aim of study is to compare surgical and conservative management of complete and incomplete spinal cord injuries due to missile in Mosul city.

PATIENT AND METHODS

This is a case series study of sixty patients with MIs of the spine who were managed at the Neurosurgical unit, Ibn-Sina Teaching Hospital in Mosul for the period from August 2011 to August 2013.

Male to female ratio was 5.8:1 with mean age 30 years.

The distribution of injuries according to the anatomy of spine is shown in (figure 1) the cervical spine was (20%), the dorsal spine was (55%), and (25%) for the lumbosacral spine injuries.

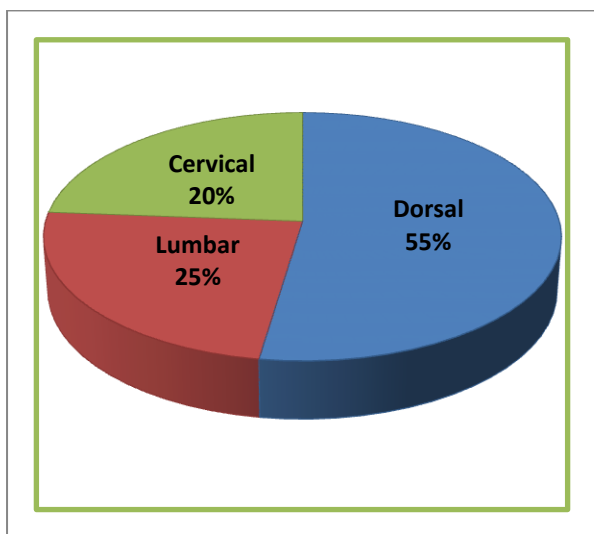


Figure (1) Frequency distribution of cases according to the anatomical level of injury

All patients were evaluated using plain radiograph, computed tomography (CT), magnetic resonance imaging (MRI) for one patient with through and through injury, and electrophysiological study were also performed for follow-up the progression of the lesion.⁸

Patients were divided into two groups :

Group (A) Those with incomplete injury including 33 patients (55%) of all cases with (MIs). 24 patients (72%) underwent surgery, while the rest were managed non-surgically as shown in (Table 1 and 2).

Group (B) Those with complete injury (complete loss of all motor and sensory function below the level of injury). They were 27 patients out of all cases with spinal MIs received (45%). 9 patients (33%) were explored surgically, while the others 18 patients (67%) were managed non-surgically.

Table 1 : distribution of injuries in the studied patients according to anatomical level of injury and severity

| Level of injury | Complete injury | | Incomplete injury | | Total | |
|-----------------|-----------------|------|-------------------|------|-------|-------|
| | NO. | % | NO. | % | NO. | % |
| Cervical | 5 | 18.5 | 7 | 21.3 | 12 | 20.25 |
| Dorsal | 19 | 70.3 | 14 | 42.4 | 33 | 56.0 |
| Lumbar | 3 | 11.2 | 12 | 36.3 | 15 | 23.75 |
| Total | 27 | 100 | 33 | 100 | 60 | 100 |

Timing of Surgery The proper time of deciding surgery in cases with SCI depends on the associated injuries. However, surgery should be performed at convenient time once systemic stabilization is achieved usually within 5-10 days.⁹

Post-operative period management Upon reversal of anesthesia base line assessment of patient condition was performed. The post-operative care includes: drainage of pulmonary secretions and promoting venous drainage from lower extremities and protecting skin integrity. Patients received at least 14 days course of antibiotics especially if there has been trans-pleural or trans-peritoneal trajectory with bowel injury where rapid mobilization was essential and multidisciplinary rehabilitation instituted within (24 – 48) hours post-operatively. The follow up of all cases was 9 months ranged from (6-18) month

Statistical Analysis Fisher exact test was used to compare the correlation between the surgical and conservative groups, and groups, which were subdivided according to anatomical regions.

RESULT

After surgical intervention of the 24 cases with incomplete injuries, improvement was encountered in 12 patients (50%). On the other hand other 9 patients with non-surgical management one patient had improvement as shown in Table 2.

On the other hand, only one patient out of nine (11.1%) with complete injury who were managed surgically has got an observable improvement. Meanwhile, no improvement to those were managed conservatively as shown in Table 3.

Table 2 The clinical improvement in patients with incomplete spinal cord injuries due to missile according to the type of management and anatomical level.

| Level of injury GSWs | Surgical management | | | Non-surgical management | | | *p-value |
|----------------------|---------------------|-----------------|------|-------------------------|-----------------|------|----------|
| | NO. | No. of improved | % | NO. | NO. of improved | % | |
| Cervical | 6 | 5 | 83.3 | 1 | 0 | 0.0 | 0.001 |
| Dorsal | 9 | 1 | 11.1 | 5 | 0 | 0.0 | 0.001 |
| Lumbar | 9 | 6 | 66.7 | 3 | 1 | 33.3 | 0.001 |
| Total | 24 | 12 | 50 | 9 | 1 | 11.1 | 0.001 |

Fisher test*

Table 3 The clinical improvement in patients with complete spinal cord injuries due to missiles according to the type of management and anatomical level.

| Level of injury | Surgical management | | | Non-surgical management | | | p-value* |
|-----------------|---------------------|-----------------|------|-------------------------|-----------------|-----|----------|
| | NO. | No. of improved | % | NO. | NO. of improved | % | |
| Cervical | 1 | 0 | 0.0 | 4 | 0 | 0.0 | 1.00 |
| Dorsal | 5 | 0 | 0.0 | 14 | 0 | 0.0 | 1.000 |
| Lumbar | 3 | 1 | 33.3 | 0 | 0 | 0.0 | 0 |
| Total | 9 | 1 | 11.1 | 18 | 0 | 0.0 | 1.000 |

* Fisher test

DISCUSSION

There has been a dramatic increase in the number of MIs managed in the Unit of Neurosurgery at Ibn-Sina Teaching Hospital in Mosul city, Iraq. The long- term functional disability as a sequence of SCI resulting from missile injury to the spine is an important problem in our city that needs to be addressed in our society.

Although SCI are not so common in most countries, they are unfortunately common in cities of Iraq due to wars, this results disagree with AS Otom et al¹⁰ who have no cases of SCI resulted from war injury because Jordan has a peaceful period for more than 20 years.

The male to female ratio was 5.8:1 which is higher than in other study¹¹ as far as male serves in military and more to be outside house, where most of the women are housewives.

As in a study reported by Karamehmetoglu¹², the peak incidence of SCI is within the "age group

of 30 ± 10 years". Thoracic SCI was the most common level of SCI with a frequency 55%, Lumbar SCI frequency 25 % and Cervical SCI 20%.as in Fig 1

Table 2 and 3 shows the thoracic spine is the most affected (55 % of patients) but there is no significant clinical improvement(p=1.000) in patients with Complete spinal injuries due to missiles at this region because of the risk of large vessel damage, lung, and heart, a small number of patients can be transmitted to department of neurosurgery after a thoracic injury.

Until evaluation of vessel or visceral organ injuries and stabilization of vital signs is completed, Spinal injuries stay secondarily managed, these results agree with Agarwal et al.¹³

In this study table 2 show significant improvement in incomplete SCI at cervical, dorsal and lumbar regions this results agree with Stauffer et al¹⁴, who treated 79 patients with SCI with gun shots with incomplete neurological deficit of these,

71% had some neurological improvements after surgery.

This study indicates that surgical intervention may not significantly produce the final functional recovery, when the spinal cord damage is complete. The most important indication for conducting surgery was to relieve spinal cord compression caused by primary or secondary injury.

A finding which is similar to the result obtained in other researchers.¹⁵

CONCLUSION

- ❖ There were no significant differences in the outcome of surgical and non-surgical management of complete spinal cord injury due to missiles.
- ❖ The bullet fragment in the cervical or conus medullaris region in the presence of incomplete neurological injury should be explored if there is evidence of compression with neurological deterioration.
- ❖ Surgical management offers better result than would non-surgical management do.

REFERENCES

1. Lifshutz, J., Colohan, A. brief history of therapy for traumatic spinal cord injury". *Neurosurgery Focus*. 16 (1 E5): E5. doi:10.3171/foc.2004;16.1.6. PMID 15264783.
2. National Spinal Cord Injury Statistical Center, Fact and Figures at a Glance. Birmingham, AL; University of Alabama at Birmingham, 2016
3. Holtz MD, PhD Richard Levi, MD, PhD 20 -7-2010. Spinal Cord Injury Andersp 5-6.
4. Chittibonia P., Banerjee AD., Zhang, S., Caldito, G., Willis, B., How bullet trajectory affect outcomes of civilian gunshot injury to the spine. *Journal of clinical neuroscience* .2011; 18:1630-1633.
5. Morganti-Kossmann, Raghupathi & Maas 2012, "Traumatic Brain and Spinal Cord Injury challenges and developments" Cambridge University press first published 2012p. 229.
6. Fallah, Dance & Burns 2012 *Advanced Critical Care Nursing* , p. 235 .
7. Gupta, S., Senger, RL., Wandering intra-spinal bullet. *Br J Neurosurg* 1999; 13:606–607.
8. Bell, RS., Neal, CJ., Tingo, J., et al: Traumatic brain and spinal column injury: a 5-year study of the impact blast and other military grade weaponry on the central nervous system. *Trauma* 66(4):S104-S111, 2009
9. Edward, C., *Benzel SPINE SURGERY* third edit. Publish June 2012 p717.
10. Otom, AS., Doughan, AM., Kavar, JS., and Hattar, EZ., Traumatic spinal cord injuries in Jordan ± an epidemiological study. *The Royal Jordanian Rehabilitation Centre, King Hussein Medical Centre, Amman-Jordan*. 1997; 35, 253 ± 255.
11. Jenkins, D., Dougherty, P., *The Effects of Bullets*. Edited by: Mahoney, PF., Ryan, JM., Brooks, AJ., Schwab, CW., *Ballistic Trauma*. London: Springer Verlag; 2005: 40-44.
12. Karamehmetoglu, SS. et al. Traumatic spinal cord injuries in Istanbul, Turkey: an epidemiological study. *Paraplegia* 2000; 33: 469 ± 471.
13. Agarwal, P., John, F., Kalil G., piazza, M., Brian, P., Jayesh, P., Neil R., et al: *Surgical Neurology International* 2016 page S1069-S1098. Bono, CM., Heary RF. Gunshot wounds to the spine. *Spine J*. 2004;4:230– 40.
14. Stauffer, ES., Wood, RW., Kelly, EG., Gunshot wounds of the spine: the effects of laminectomy. *J Bone Joint Surg Am* 1979; 61: 389–392.
15. Bagnall, AM., Jones, L., Duffy, S., Riemsma, RP., (2008) Spinal fixation surgery for acute traumatic spinal cord injury. *Cochrane Database Syst Rev* (1): CD004725.