

# The Biocompatibility of eugenol after an intraosseous implantation

Al-Sarraf M. Khulood\*

Received 26/10/2005 ; accepted 28/11/2005

## الخلاصة

التوافق الاحيائي لزيت القرنفل و الذي هو أحد المواد الشائعة الاستعمال في حشوات جذور الأسنان قد تم اختباره من خلال زرعه في عظمة الفك لحيوان الهامستر .  
أربعون حيوان هامستر قسمت الى خمسة مجاميع ، مجموعة قياسية تحتوي على ثمانية حيوانات و أربع مجاميع أخرى هي مجاميع التجارب تحتوي كل منها على ثمانية حيوانات .  
بعد أن تم تخدير الحيوان ، تمت إزالة الجلد وتم عمل ثقب صغير 2 ملم قطراً و 2 ملم عمقاً في الفك السفلي للحيوان ثم وضعت عجينة من زيت القرنفل و اوكسيد الزنك في هذا الثقب وتم خياطة الجلد فوق مكان الزرع وترك في محله لكل مجاميع التجارب الأربع. تركت المجموعة الأولى اسبوعاً واحداً و تركت الثانية اسبوعان و الثالثة ثلاثة أسابيع و الأخيرة الرابعة أربعة أسابيع قبل قتل الحيوان.  
بعد قتل الحيوان تم فحص موقع الزرع نسيجياً . بينت النتائج أن زيت القرنفل قد أدى إلى ردة فعل شديدة جداً بعد سبعة أيام من زرعها و أزداد رد الفعل الى درجة أكبر بعد 14 يوم في حين ابتدأت ردة الفعل بالنقصان لتصبح تقريباً كما كانت عليه بعد 7 أيام. إن هذه الحالة تناقصت لتصبح متوسطة الشدة بعد 28 يوماً. نستنتج من ذلك بان زيت القرنفل هو مادة مخرشة حيوياً حتى بعد أربعة أسابيع من زرعها في العظم.

## ABSTRACT

The biocompatibility of the Eugenol, as one of the commonest root canal filling (RCF), material was evaluated through an intraosseous implantation of this material in the mandible of the Syrian hamsters.

Forty Syrian hamsters were divided into 5 groups, 8 animals in each group, group 1 as control, and group 2, 3, 4, 5 as experimental groups.

After the animal was anesthetised, the skin was reflected and a hole of 2mm. diameter X 2mm. depth was drilled in all the hamster mandibles.

A mixture of Eugenol and Zinc oxide as a paste was placed in that hole of each animal of the experimental groups and left for different periods, 7 days, 14 days, 21 days, and 28 days. After the hamsters were sacrificed, a histological examination of the implantation site was performed, the results showed that Eugenol elicited a severe inflammatory reaction at day 7, and this inflammatory reaction is increased to become more severe at day 14, and the reaction begin to decrease with the 21 day giving about the same histopathological picture of after 7 days to become moderate after 28 days. Our conclusion is that the Eugenol is a biologically irritant material even after 4 weeks of its intraosseous implantation.

## INTRODUCTION :

The mandible of the hamster is usually used in this type of experiments of intraosseous implantation<sup>(1)</sup>. The intraosseous implantation method was used to study the biocompatibility of different materials used in contact with bone for a very long period of time as in RCF material<sup>(2)</sup>. In RCF treatment the obliterating material should be shorter than the apex. The eugenol because it is a volatile oil, its effect will extend beyond apex causing different types of effects. Because of this effect the Eugenol should be studied thoroughly to perform a successful RCF treatment.

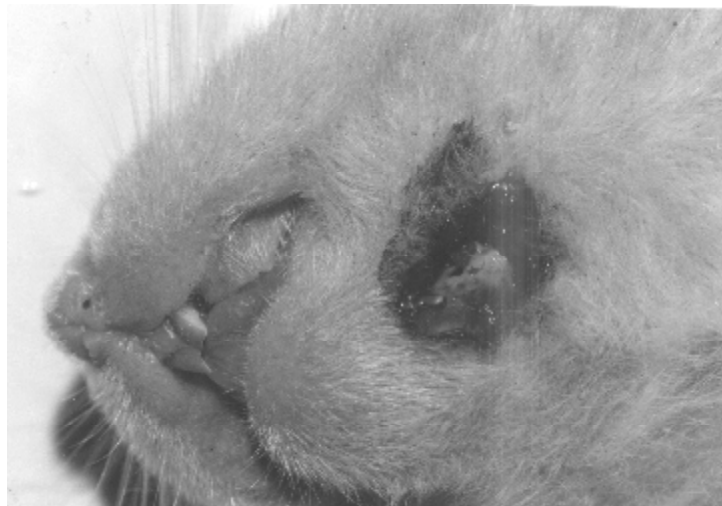\* Basic Sciences Department, College of Dentistry, Baghdad University, Baghdad – Iraq.

In general, the Zinc oxide-Eugenol (Z.O.E) based sealer is one of the commonest material used in the RCF treatment. Erausquin and Muruzabal, in 1967<sup>(3)</sup> found that Z.O.E based sealer was highly irritant to periapical tissue causing necrosis. This fact conflict with the findings of Barker and Lockett, in 1972.<sup>(4)</sup>

This study was performed to clairify the controversy concerning the effect of the Eugenol on the bone.

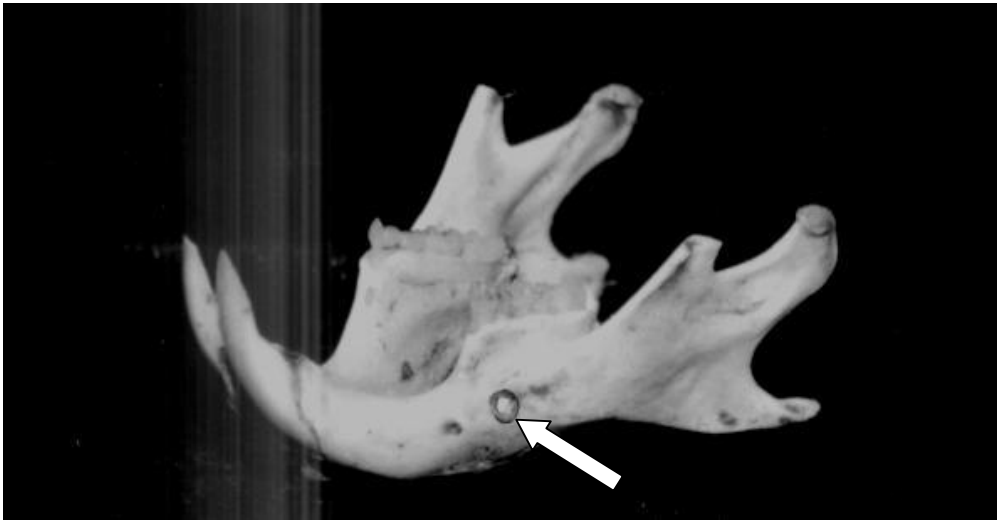
#### **MATERIALS AND METHODS:**

Forty adults male Syrian hamsters of 2 months old, weighing 105-153gms. They were fed normal diet of laboratory pellets and tap water and they were kept at room temperature of 22-25 C. The animals were divided into 5 groups: 8 animals in each group, group 1 as a control, 2, 3, 4, 5 a as experimental groups. The second group killed 1 week after operation, group 3, 2 weeks after operation, group 4, 3 weeks after operation and the last group was sacrificed 4 weeks after operation. Ketamin Hydrochloride was used as an anesthetic agent at a dose of 88 mg/kg body weight injected i.m. in the hamster leg (the lethal dose is 250mg/kg body weight). The anesthetized animals were placed on its back on a surgical board, the incision site was shaved and swabbed with alcohol (90%), an oblique incision of about 1 cm. was made in the skin at the lower borer of the mandible, periosteum was reflected and the bone was exposed (Fig.1).



*FIG 1 . THE DRILLED CAVITY IN THE HAMSTER MANDIBLE*

A small cavity was made at the labial side of the mandibular bone using a slow running round bur cooled with running normal saline. The end result is a cavity of 2mm diameter X 2 mm depth (Fig 2).



*FIG 2 . THE HAMSTER MANDIBLE (THE ARROW SHOW THE IMPLANTATION SITE)*

The mixture of Eugenol and zinc oxide was achieved according to the manufacturer directions. The hamsters were euthanized by diethyl ether in a glass jar for 10 minutes. The mandibles were separated from the head fixed in 10% formalin for 48 hours, decalcified in formic acid. Multiple sections of 5 $\mu$ m were prepared and then stained with H&E.

The histological examination performed according to the following:

1-Number and type of inflammatory cells infiltration, Very severe (500-600 cell count/mm<sup>2</sup>), Severe (300-500), Moderate (150-300), Mild (1-150) & None with zero cells count. The cell observed were lymphocyte, Polymorph nuclear leukocytes, Macrophages, Multinucleated giant cells, Plasmocytes & Fibroblasts.

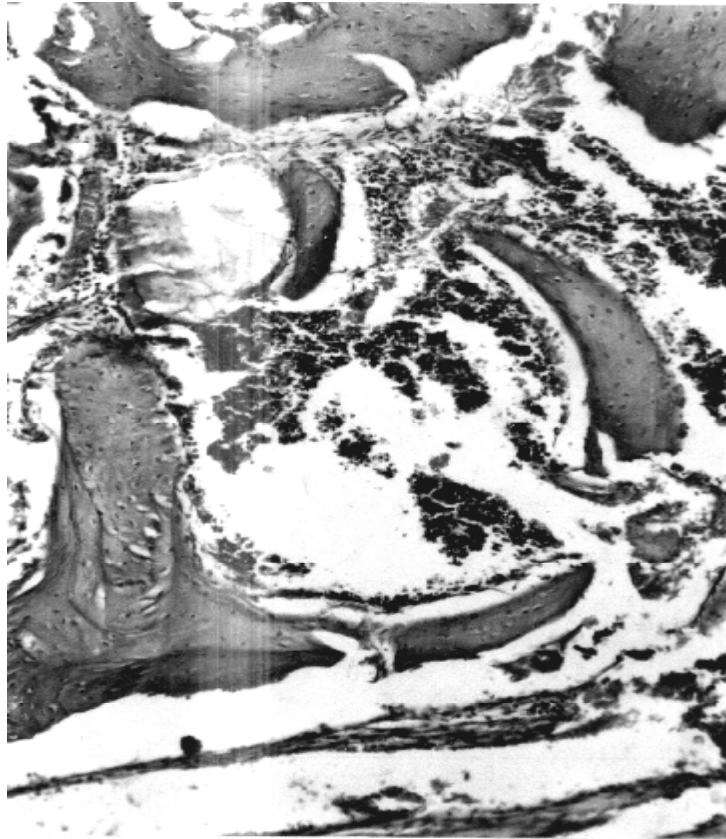
2-The presence or absence of bone necrosis.

3- The presence or absence of new bone formation.

## **RESULTS:**

Control group, seven days


Hemorrhage appear around the cavity, bone sequestra appear at the surgical site with the presence of osteoclasts. The inflammatory cells were moderate, of both types, acute and chronic inflammatory cells were observed (Fig 3).



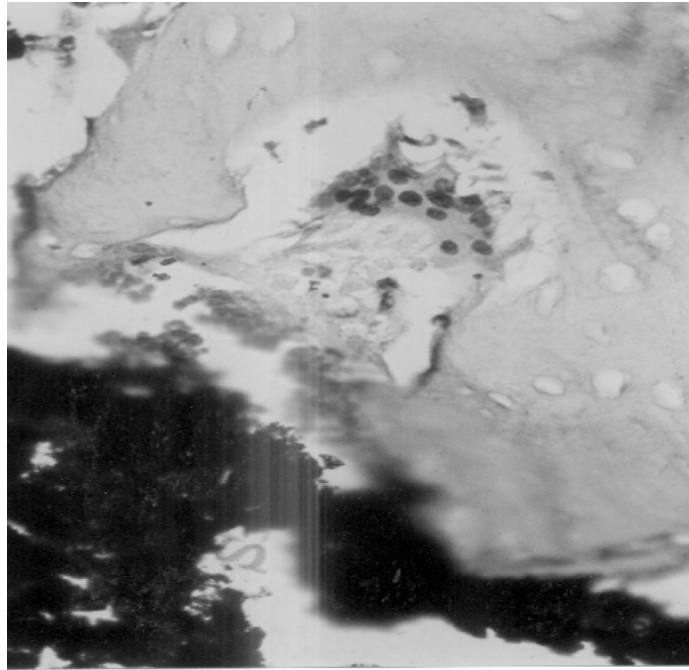
*FIG 3 . HISTOLOGICAL SECTION, AFTER 7 DAYS, OF THE CONTROL SITE DEMONSTRATING A BONE SEQUESTRUM AND HEAMORRAGE*

Experimental group, seven days

The Eugenol produce an inflammatory zone with the presence of acute and chronic inflammatory cells with a severe degree of inflammation (Fig 4&5)



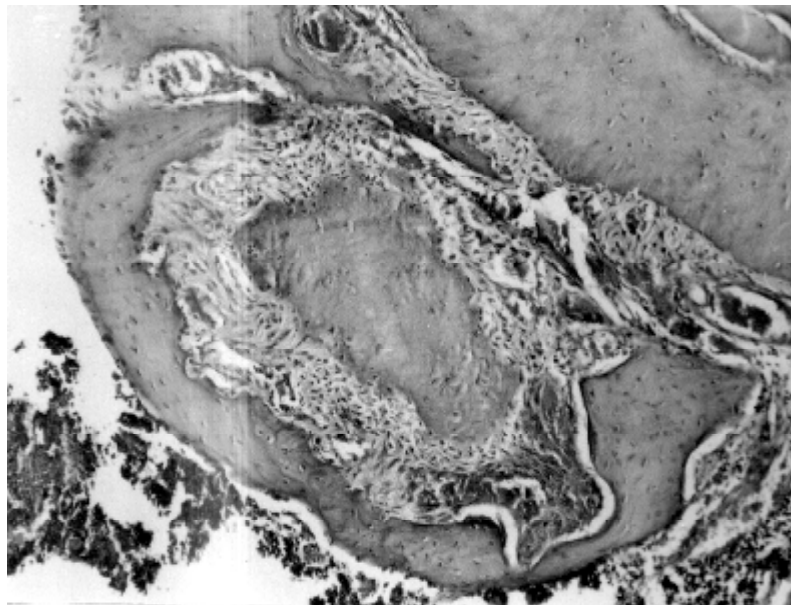
*FIG 4 . SEVEN DAYS AFTER IMPLANT SHOWING PROLIFIRATION OF GRANULATION TISSUE ARROUND THE IMPLANT (X 100)*



*FIG 5 . THIS HISTOLOGICAL SECTION OF THE IMPLANT AFTER 7 DAYS SHOWS OSTEOCLASTIC ACTIVITY AROUND BONE SEQUESTRUM (X400)*

#### Control group, fourteen days

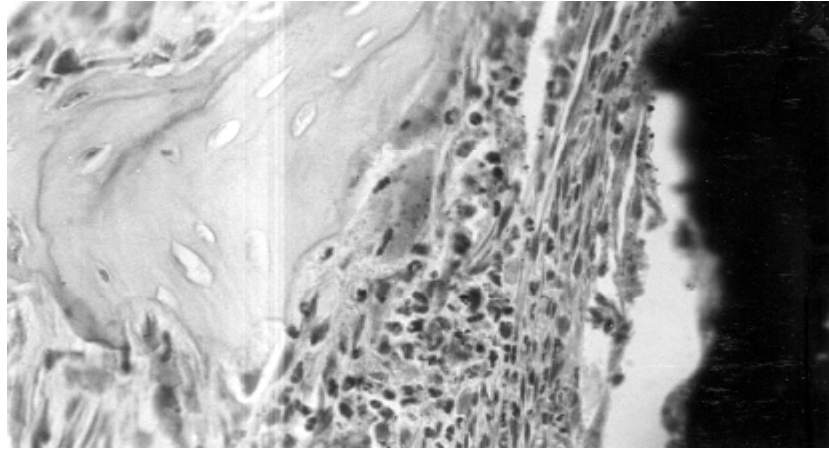
All the site was surrounded with fibrous connective tissue. A new bone formation was evident. Chronic inflammatory cells were observed. (Fig 6).



*FIG 6 . A HISTOLOGICAL APPEARANCE OF THE CONTROL SITE AFTER 14 DAYS SHOWING MODERATE INFLAMMATORY CELLS INFILTRATION WITH FIBROUS CONNECTIVE TISSUE FORMATION (X100)*

#### Experimental group, fourteen days

The presence of signs of inflammatory cells surrounding the implantation site, large number of neutrophilic leukocytes were distinguished at the site. Considerable amount of bone destruction and an empty lacunae were seen around the implantation site with the degree of very severe inflammation. (Fig 7).



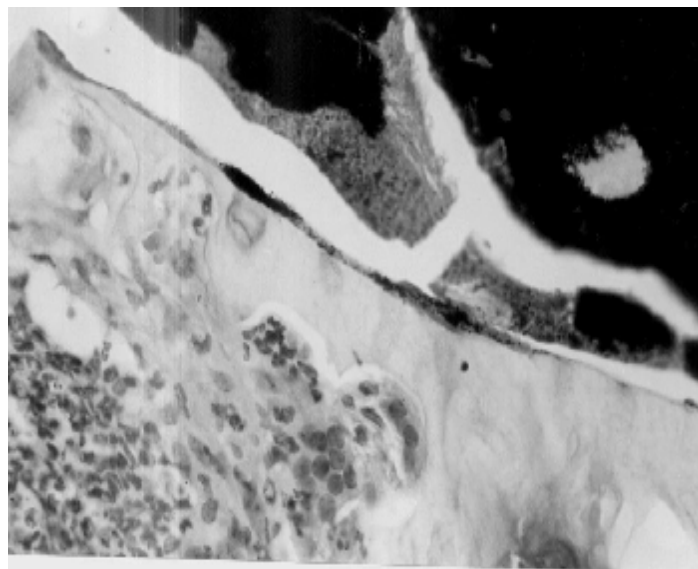
*FIG 7 . OSTEOCLASTIC ACTIVITY AROUND BONE SEQUESTRUM, 14 DAYS AFTER IMPLANT (X400)*

#### Control group, twenty one days

All the drilling site was surrounded by fibrous connective tissue with a mild inflammatory reaction. A new bone formation was clear at this stage .

#### EXPERIMENTAL GROUP, TWENTY ONE DAYS

There was a slight decrease of the inflammatory cells was observed. Macrophages, Lymphocytes, giant cells and few neutrophils were found, (changing from acute to chronic state). Young fibroblasts and newly formed collagen fibers were evident. An osteoclastic activity was still going on. The inflammation still to be very severe. (Fig 8)



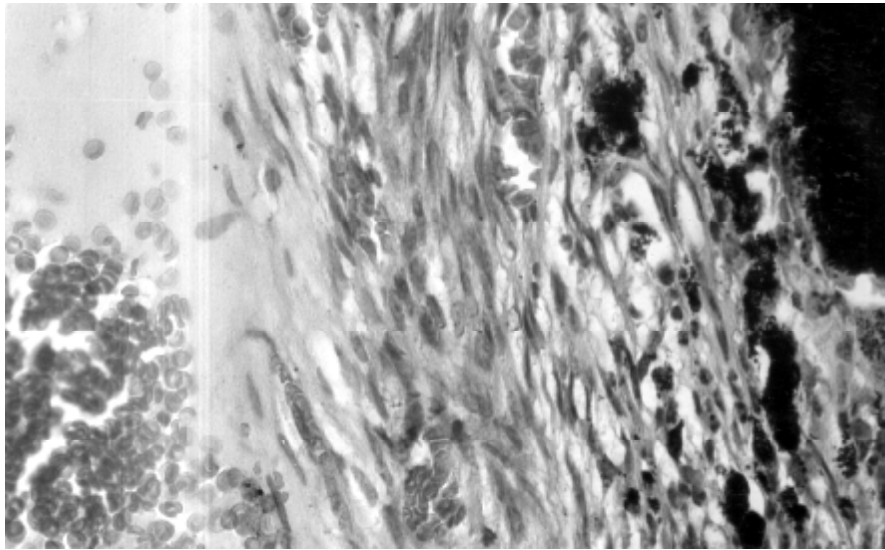
*FIG 8 . THE HISTOLOGICAL SECTION SHOWS OSTEOCLASTIC ACTIVITY, 21 DAYS AFTER IMPLANT (X400)*

### Control group, twenty eight days

The drilling site was healed with the presence of newly bone and bone marrow formation

### Experimental group, twenty eight days

The site was surrounded by thicker fibrous connective tissue that include inflammatory cells. The inflammatory reaction become moderate. Number of empty lacunae reduced considerably, but still osteoclastic activity present. The degree of the inflammation was moderate and the number of chronic cells was decreased considerably. (Fig 9).



*FIG 9 . A HISTOLOGICAL APPERANCE OF THE IMPLANT SITE 28 DAYS AFTER IMPLANT, FIBROUS CONNECTIVE TISSUE WITH INFLAMMATORY CELLS INFILTRATION IS SEEN ARROUND THE IMPLANT*

### **DISCUSSION:**

The mandible of the hamster was used by many investigators to study surgical problems<sup>(5,6)</sup>. The hamster was chosen in this experiment because the size and thickness of the mandible was suitable to carry out the drilling and implantation.

The implantation of the eugenol in the bone caused a very severe reaction in the host tissue after 7 days and this condition continued for the 14 days, the inflammation was very severe with the presence of bone sequestrum and osteoclastic activity.

This findinig consist with the results found by Spangberg in 1974<sup>(7)</sup>. He implanted Z.O.E. based sealer in the mandible of the Guinea pigs and found that a maximum necrosis within one week and persisted for 2 weeks.

In 1974 Langland did implanted the Z.O.E. in the Guinea pigs mandible and found a severe tissue destruction , and severe infiltration of inflammatory cells which coincide with the results obtained in this investigation<sup>(8)</sup>.

The results obtained by other workers who performed the same experiments on different animals also showed the same observations<sup>(9,10)</sup>.

These results coincide with the results obtained by many workers concerning the period 21 – 28 days<sup>(11,12,13)</sup>. Our results showed that even after one month still there was a moderate inflammation although the material was surrounded by a fibrous connective tissue which indicate that the implant is relatively tolerated by the host tissue.

Something interesting should be mentioned here that some reserchers consider the eugenol as an analgesic agent localy used to different inflammed tissues<sup>(14)</sup>.

In addition to that the Eugenol is considered as antibiotic<sup>(15)</sup>.

As a conclusion it seems that although the eugenol was eventually tolerated by the host tissue, it's an irritant material when implanted intraosseously at least up to one month.

## REFERENCES:

1. Hervé Tassery, DCD, Wilhelm-Joseph Pertot, DCD, Jean Camps, DCD, Jean Pierre Proust, DCD, and Jacques Déjou, DCD, (1999), Comparison of Two Implantation Sites for Testing Intraosseous Biocompatibility. JOE Volume 25, Number 9.
2. Blackman, R. ;Gross, M. & Seltzer, S. (1989). An evaluation of biocompatibility of a glass-inomer silver cement in rat connective tissue. J.O.Endodontics, 15(2):76-79.
3. Erausquin, J. & Muruzabal, M. (1967). Root canal fillings with Zinc oxide Eugenol cement in the rat molar. Oral Surg., 24(4):547-558.
4. Barker, B.C.W. & Lockett, B.C. (1972). Reaction of dog tissue to immediate root filling with Zinc oxide cement & gutta-percha. Australian Dental Journal, 17:1-8.
5. Mesrobian A.Z. & Shakler G. (1960) , quoted by Navia J.M. (1977). Animal models in dental research p.380 the University of Alabama, School of Dentistry.
6. Mahmod , R.I. (1989) Intraosseous implantation of skin autografts in hamster. AN experimental investigation into the pathogenesis of keratocyst , an M.Sc. thesis, Baghdad University, College of Dentistry.
7. Spangberg L. (1974). Biological effects of root canal filling materials. The effect of bone tissue of of two formaldehyde containing root canal filling pastes N2 & Rieblers paste. Oral Surg.,38:934-944.
8. Langland K. (1974). Root canal sealants & pastes., Dental Clinic of North America, 18:309-327.
9. Langland K.; Guttuso, J.; Langland L.K. & TobonG. ,(1969). Methods in the study of biological responses to endodontic materials. Oral Surg., 27(4):522-541.
10. Langland K.: Olsson B. & Pascon E.A.(1981).Biologic evaluation of hydron. J.O.E., 7:196-203
11. Hoover J. ; Thoma, G. W. & Madden, R.M. (1980). The effect of the endodontic sealers on bone J.O.E., 6:586-590.
12. Friend L.A. & Browne R.M. (1969), Tissue reaction to some root filling materials implanted in the bone of rabbits . Arch. Oral Biol., 14:629-637.
13. Pertot W.J. ; Camps J.; Remusat, M.; Proust J.P. (1992). In vivo comparison of of the biocopatibility of two root canal sealers implanted into the mandible bone of rabbits . Oral Surg., 73:613-620.
14. [Lee MH](#), [Yeon KY](#), [Park CK](#), [Li HY](#), [Fang Z](#), [Kim MS](#), [Choi SY](#), [Lee SJ](#), [Lee S](#), [Park K](#), [Lee JH](#), [Kim JS](#), [Oh SB](#). . (2005) Eugenol inhibits calcium currents in dental afferent neurons J. Dent Res. ;84(9):848-51.
15. André K. Mickel, DDS, MSD, and E. Ronald Wright, (1999) ,Growth Inhibition of Streptococcus anginosus (milleri) by Three Calcium Hydroxide Sealers and One Zinc Oxide-Eugenol Sealer JOE Volume 25, Number 1.