

The Value of Diffusion-Weighted Magnetic Resonance Image in the Evaluation of Temporal Bone Cholesteatoma

Sura Jwad, Mohammed AL Hilly***

ABSTRACT:

BACK GROUND :

Cholesteatoma is non-neoplastic destructive lesion .MRI including diffusion weighted imaging (DWI) is helpful, since high content of keratin is associated with restricted diffusion.

AIM OF STUDY:

To determine the value of DWMRI and apparent diffusion coefficient (ADC) value in diagnosis of temporal bone cholesteatoma .

PATIENTS AND METHOD :

A prospective study conducted 33 patients with clinical suspicious of cholestatoma using 1.5tesla MRI scanner ,DWI with bvalue 1000 sec/ mm².ADC was reconstructed and mean value measured in mm²/sec for each lesion .Enhancing image obtained after intravenous contrast administration with early and delay images in suspected recurrent cases .

RESULT:

DWI accurately detect 22 of 25 cholesteatoma lesions (sensitivity = 88% and specificity = 100%).Positive predictive value and negative predictive value were 100% and76.9% respectively with accuracy rate 91.4%. ADC value revealed (0.469 x10⁻³ to 0.823 x10⁻³ mm²/sec) for restricted lesions with mean value (0.653 x10⁻³ ± 0.09092 SD mm² /sec)which is significantly difference from non restricted lesions(P value less than 0.001) .T1W post contrast images also give high accuracy in diagnosis of cholesteatoma 23 from 25 cases (sensitivity =92.59 %, specificity = 100).

CONCLUSION:

MRDWI give high accuracy in detection of cholestatoma in patient with chronic ear discharge.

KEYWORDS: Cholesteatoma , Magnetic resonance image ,Diffusion weighted image , Temporal bone

INTRODUCTION:

Cholesteatoma is non-neoplastic destructive cystic lesion, characterized by accumulation of desquamated keratin epithelium in the middle ear cavity or in other pneumatized portions of temporal bone. Histologically cholesteatoma have two components:acellular keratinize debris which form content of the sac and matrix which is biologically active component forming sac lining .The epithelial layer produce the keratin where as the perimatrix contain mesenchymal cells that produce proteolytic enzymes which can resorb and destructed bone, surgery therefore necessary to eradicated cholesteatoma.^(1,2) Most common type is acquired (98%) and minority is congenital type(2%).Patients with acquired cholesteatoma have history of recurrent ear disease , Eustachian tube obstruction ,atelectasis of middle ear and reduce pneumatization of mastoid.⁽³⁾ Congenital cholesteatoma may be an incidental

finding in asymptomatic patient or may present with conductive hearing impairment.⁽⁴⁾ The diagnosis is generally based on clinical presentation, Otosopic examination, and audiometry.CT scan is used routinely to assess disease extension ,possible osseous destruction, anatomical abnormalities and other complications.⁽⁵⁾ Studies employ high spatial resolution , high sensitivity ,high negative predictive value but low specificity in the case mass lesion because it may correspond to granulation tissue ,secretion ,cholesterol granuloma or neoplasm.⁽⁶⁾ The distinction between cholesteatoma and inflammatory tissue based on CT finding may be quite difficult if not impossible.MRI diffusion weighted image (DWI) is very useful in such context ,since high content of keratin is associated with restricted diffusion^(3,6). DWI has shown to high sensitivity and specificity for detection of cholesteatoma which appear high signal intensity on DWI obtained with b factor of 800 or 1000 sec/mm²

*Welfare Teaching Hospital, Medical City, Baghdad, Iraq

**Al Shaheed Ghazi AL Hairri Teaching Hospital, Medical City, Baghdad, Iraq

where granulation tissue has low signal intensity, attributed partly to restricted water and predominately to T2 shine through of lesion as revealed by calculated ADC value^(2,3,7). The point is that only cholesteatoma show high signal intensity on DWI, other tissue that can be found in temporal bone such as granulation tissue, fibrous tissue, cholesterol granuloma or serous fluid showing low signal intensity on DWI⁽⁸⁾.

As cholesteatoma is a non-vascularised lesion, it is not enhanced after intravenous gadolinium administration or give peripheral rim enhancement on T1 post intravenous contrast administration. In suspected recurrent cases, with early scanning slow enhancing fibrous tissue can be mistaken for cholesteatoma, causing false positive results so it is necessary to obtain delay contrast enhance images with delay (30-45 minutes), fibrous tissue showing homogenous enhancement while cholesteatoma remain unenhanced^(8,9). Unfortunately the typical contrast uptake pattern of cholesteatoma is not very visible on CT especially if lesion is small, contrast administration is not required because of its relatively low density resolution in such a small anatomical region of interest and beam hardening artifact^(3,6).

Aim of this study is to determine the value of DWMRI and ADC value in diagnosis of cholesteatoma in patient with chronic ear discharge.

PATIENTS AND METHOD:

1. Patients: This an analytic cross sectional prospective study was conducted at the radiology department at Al -Shaheed Ghazi Al Hariri teaching hospital in the medical city complex during the period from February 2016 to beginning of January 2017, thirty three patients were included categorizing them into: patients with chronic ear discharge had clinical suspicion of cholesteatoma with no history of previous surgery forming 19 patients and patients had history of previous surgery for cholesteatoma with clinical suspicion of recurrent /residual cholesteatoma forming 14 patients. Informed verbal consent was obtained from all patients.

1.1 Inclusion criterion:

1. Patients had chronic ear discharge with clinical suspicion of temporal bone cholesteatoma (according to history, clinical examination and positive CT scan finding).

2. Patients undergoing mastoid surgery for cholesteatoma with clinical suspicion of recurrence or residual disease.

1.2 Exclusion criterion:

1. General contraindications to MRI: claustrophobic patients, patients with electrical implants and electronic devices (implanted hearing aids, intracranial metal clips, metallic bodies in the eye, heart pacemaker.), pregnant lady within first trimester.
2. Pediatric age group less than 5 years.
3. Recent surgery (give false positive result from hemorrhage and edema).
4. Ear containing Silastic sheets material, bone prosthesis, myringostomy tube (causing artifacts and distortion of image).
5. Patients with clinical suspicion of abscess

2. Methodology and data collections:

all patients referred from specialized otologist with details patient history including demographic state, history of ear discharge: duration, site and type, response of trials medication treatment and any associated signs and symptoms (headache, vertigo, facial numbness ...), history of mastoid surgery (type, date from last interval), post operative symptoms (duration, response to medical treatments). Complete otoscopic examination done by expert otologist and pure tone audiometric assessment conducted to all patients. High resolution CT scan of temporal bone available with each patient reveal positive finding for cholesteatoma suspicion: opacification of middle ear cavity, lesion anatomical site and extension, bony erosion, state of inner ear and EAC structures, the image consider negative when middle ear cavity filled with air or show minimal thickening. Laboratory examination for blood urea and serum creatinin was routinely done to each patient to assess renal function prior to contrast administration. MRI study of temporal bone was done, reporting finding then refer to Otologist according to whole result plan for management, surgical and histopathological results was included in the data.

3. MRI protocol:

MRI examination performed with Avantomagnetom 1.5 tesla scanner Siemens Medical system using 8 channel sensitivity encoding head coil, MRI protocol includes:

VALUE OF DW IN TEMPORAL BONE CHOLESTEATOMA

1. Pre contrast T1 weighted (T1W) axial images: Repetition time (TR): 675 msec; time to echo (TE): 8.7 msec field of view (FOV): 230 mm, slice thickness: 2 mm.
2. T2 weighted (T2W) axial images: TR: 4190 msec, TE:106 msec, FOV: 230 mm, slice thickness: 2 mm.
3. Fluid attenuation recovery (FLAIR) coronal images: TR: 9000msec , TE:92 msec, FOV :240 mm ,slice thickness 2mm .
4. DW images were obtained in the axial plane, echo planar sequence TR: 3700.0 msec, TE:114 msec, slice thickness 5 mm, FOV =270mm , signals acquired with b-value : zero, 500 and 1000 mm² /s ,time acquisition 3:03 minutes.

ADC cartography was derived automatically on a voxel-by-voxel basis with use of these acquisition parameters, Calculated ADC values are expressed in square millimeters per second.

5. Axial and coronal spine -echo T1-weighted sequences immediately and delay post contrast images (DPI) after 45 minutes (in suspected recurrent case) from intravenous injection of gadodiamide (omniscan), dose 0.1 mmol /kg of body weight : TR : 818 msec, TE: 8.7msec ,FOV =230mm (for axial) and 240 mm (for coronal) .

4. Image analysis: all cases interpreted by two consultant radiologists. For DWI, the diagnosis of cholesteatoma was made on increase intensity signals (restriction area) at b=1000 s/mm²in the axial planes compared with base line trace image b value =zero and ADC . Calculating ADC value in a selected region of interest (ROI) on the cartography on the Avanto workstation (Siemens) The image for ROI placement was selected to avoid the edges of the lesion and partial volume averaging, so the central aspect of the lesion was targeted within area matching suspected cholesteatoma according to usual sequences. If this was not possible because of small size of the lesion, the mean ADC of the lesion was taken from ROIs on the two contiguous sections. Once the image section of the lesion was selected, ROI

was contoured within the inner border of the lesion on the image .The ROI measurements were repeated three times on the image for each case, and the median ADC (mm² /sec) was obtained. For DPI after 45 minutes the diagnosis of residual cholesteatoma made on low to intermediate signals unenhanced on DPI other types of tissue showing homogenous uniform enhancement, both axial and coronal sequences cautiously observed together to eliminate susceptibility artifacts .All the cases followed after surgery with close cooperation with the referring consultant ENT surgeon.

RESULTS:

The final analysis included 33patients, 16 were females (48.4 %) and 17were males (51.6%), their age range from (8 to 46 years) with mean age (25.1 ±12 .9) year. Two patients carry two lesions so 35 lesions were the totally included ,19 patients had no history of previous mastoid surgery, one of them carry lesion in each ear so total lesions 20 (57.14%), 14 patients had history of previous mastoid surgery for cholesteatoma with clinical suspicion of recurrent ,one patient carry two lesions in same ear so total lesions 15 (42.85 %). All these cases had positive finding on temporal CT scan as opacification of middle ear cavity with different degree of bony erosion or opacification of previous operated cavity, only one had petrous apex osseous lesion.

An MRI DWI sequence reveal 22 lesions was restricted (62.857%) and 13 lesions was not restricted (37.142%), as shown in table (1). Additional evaluations for conventional MRI sequences revealed :all lesions 35 (100%) carry high signal intensity in T2WI ,intermediate signal intensity 18 lesions (51.428 %) and 17 high signal intensity lesions (48.571%) in FLAIR sequences and T1 WI reveal 20 hypo intense lesions (57.142%)and15 intermediate signal intensity lesions (42.857%). The size for restricted lesions range from 5 mm as smallest diameter to 40 mm in largest diameter with mean diameter (14 ± 6 mm).

Table 1: MRI / DWI for restricted and non restricted lesions.

DWI	No.	%
Restricted	22	62.857
Not restricted	13	37.142
Total	35	100

VALUE OF DW IN TEMPORAL BONE CHOLESTEATOMA

ADC value was calculated in each suspected lesion and revealed (0.469 x10⁻³ to 0.823 x10⁻³ mm²/sec) for restricted lesions with its mean value: (0.653 x10⁻³ ± 0.09092 SD mm²/sec) and (1.534 x10⁻³ to 2.967 x10⁻³ mm²/sec) for non restricted lesions with its mean value:

(2.211x10⁻³ ±0.485 SD mm²/sec) as shown in table(2).There is high significant different in ADC value between restricted and not restricted lesions (p value less than 0.001). Cutoff values are calculated for restricted lesions as confidence interval which equal to (0.653 x10⁻³ ± 0.1818 mm²/sec).

Table 2: The difference in ADC value between restricted and not restricted lesions.

DWI finding	ADC value		P value
	Mean	Std. Deviation	
Not restricted	2.21146 *10 ⁻³	0.485857 *10 ⁻³	0.001
Restricted	0.65368 *10 ⁻³	0.098092 *10 ⁻³	

For a correct diagnosis was made according to surgery and histopathology reveal: 25 lesions (71.428%) diagnosed as true positives for cholesteatoma and 10 lesions (28.571%) as true negatives for cholesteatoma revealed as granulation tissue as shown in table (3). DWI detected 22 lesions from 25,three lesions DWI failed in detecting which verified as

cholesteatoma according to surgery and histopathology (false negative).DWI give very high specificity for detection cholesteatoma tissue reaching (100%) with sensitivity (88%),positive predictive value (100%) and negative predictive value (76.9%) and Accuracy rate (91.4%) as shown in table (5).

Table 3 : DWI finding in correlated with histopathology.

DWI finding	Histopathology		
	Positive	Negative	Total
Positive	22	0	22
Negative	3	10	13
Total	25	10	35

T1 weighted post contrast images also give high accuracy in diagnosis of cholesteatoma 23 from 25 lesions according to surgery and histopathology as: 6 nonenhanced lesions (17.1%),17marginal enhanced lesions (48.6%),two lesions failed to detected by post contrast study (false negative), all patients without cholesteatoma correctly interpreted as showing diffuse enhancement, T1WI post contrast study

give 92.59 % sensitivity and 100 % specificity for detection of cholesteatoma with the positive predictive value and negative predictive value were (100% and 83.33%) respectively with Accuracy rate (94.59%). as shown in tables(4),(5).There is a significant association between T1W post contrast image and DWI finding (P value =0.001) as it shown in table (6).

Table 4:T1W post contrast image in correlation with histopathology.

T1 post contrast	Histopathology		
	Positive	Negative	Total
Positive	23	0	23
Negative	2	10	12
Total	25	10	35

VALUE OF DW IN TEMPORAL BONE CHOLESTEATOMA

Table 5: Sensitivity and specificity of DWI and T1Wpostcontrast image in diagnosis of cholesteatoma.

Examination	sensitivity	specificity	PPV	NPV	accuracy
MR DWI	88%	100%	100%	76.9%	91.4%
T1postcontrast image	92.59%	100%	100%	83.3%	94.59%
Histopathology	100%	100%	100%	100%	100%

Table 6: Association between T1 post contrast and DWI finding.

T1 post contrast	DWI finding		Total n=35 (%)	P Value
	Restricted n=22 (%)	Not restricted n=13 (%)		
Not enhanced	5 (83.3)	1 (16.7)	6 (17.1)	0.001
Marginal enhancement	17 (100)	0 (0)	17 (48.6)	
Enhanced	0 (0)	12 (100)	12 (34.3)	

For patients whom had history of previous mastoid surgery with clinical suspicion of recurrent: 11 lesions revealed as recurrent /residual cholesteatoma (73.33%) and 4 lesions revealed as granulation tissue (26.66%) according to surgery and histopathology, DWI reveal 10 lesions restricted (66.66%) and 5 lesions not restricted (33.33%) ,one false negative result then was revealed on complementary T1 DPI after 45minuts as marginal enhancement that was not detected on DWI .

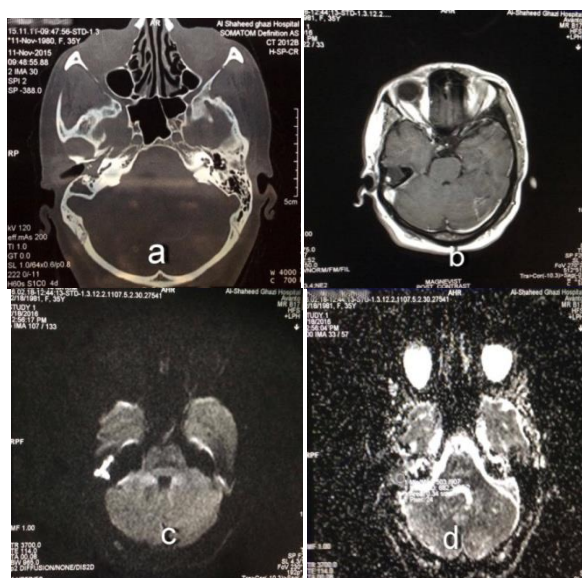


Figure 1: Female with history of chronic purulent right ear discharge
 (a) CT scan axial section reveal opacification of middle ear cavity with bony erosion
 (b) T1W post contrast study showing non enhancing lesion
 (c) DWI at b=1000 sec/mm² lesion showing restricted signal intensity
 (d) ADC value of 0.682 x 10⁻³ mm²/sec (cholesteatoma confirmed on surgery).

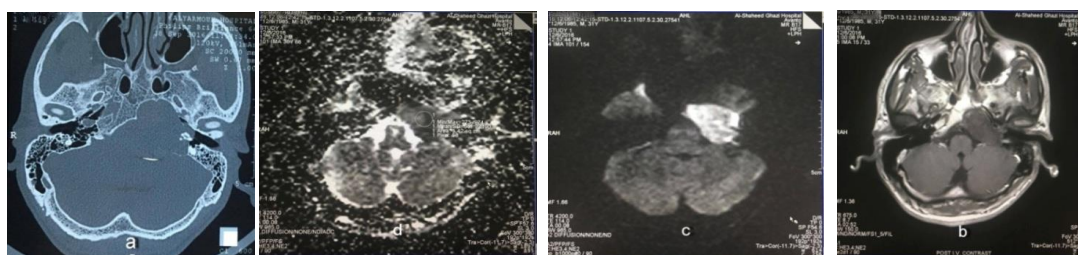


Figure 2: 31 years old male with history of occipital headache and left sided hearing impairment associated with left sided facial numbness
(a) CT scan axial section showing left petrous apex lesion with thinning of bony cortex
(b) MRI T1W post contrast study non enhanced hypo intense lesion
(c) DWI at b value 1000 sec/mm² lesion with restricted signal intensity
(d) Mean ADC value of 0.541 x10⁻³ mm²/sec ,diagnosis as petrous apex cholesteatoma confirmed on surgery and histopathology .

DISCUSSION:

MRDWI is an efficient imaging technique with high specificity for detection of cholesteatoma reaching 100% in our study ,all cases where positive in DWI was positive in surgery (PPV 100 %) ,only 3 lesions where DWI failed to detected which were positive on surgery (this give 88% sensitivity and 76.9 % NPV ,with Accuracy rate 91.4 %) , this result agreement with KhedrSAet al⁽¹⁰⁾, VaidSanjay et al⁽¹¹⁾ and Stasolla A et al⁽¹²⁾.These 3 false negative lesions were :one open sac cholesteatoma (where its contain drain out either from auto evacuation or iatrogenic from frequents suction) and others two lesions were small in size less than 5 mm which not detected on EP DWI ,possibly from field inhomogeneities at air/bone interface and relatively thick slice section , these may contribute in missing the lesions and effect on the image interpretation , this results similar to VaidSanjay et al⁽¹¹⁾ ,Fitzek Clemens et al⁽¹³⁾ and KhedrSAl et al⁽¹⁰⁾.No false positive result in our study similar to VaidSanjay et al⁽¹¹⁾ and Khedr SA et al⁽¹⁰⁾,unlike to Elefante A et al⁽⁷⁾ were report 2 false positive result in DWI where no cholesteatoma found on surgery and YiğiterAliCihanet al⁽¹⁴⁾also found 2false positive result .Abscess /empyema, recent hemorrhage, cerumen in the ear canal and Silastic sheet may give false positive result on DWI(in our study we put them in the exclusion criteria). Our study reveal high sensitivity (92.59 %) and specificity(100%) in using contrast study imaging with high accuracy rate (94.59 %) ,two lesions failed to be detected : one small lesion was masked by enhancing surrounded granulation tissue , other one was open sac cholesteatoma where its content drain out and mixed with adjacent enhancing granulation tissue, this results give agreement with Khedr

SA et al⁽¹⁰⁾and J.A. BLANCO CABELLOS1 et al⁽¹⁵⁾and VaidSanjayet al⁽¹¹⁾, they used combined T1 post contrast study and DWI to increase MRI sensitivity in detection of cholesteatoma . For recurrent cases : 11 lesions out of 15 lesions according to surgery and histopathology while DWI found 10 lesions as restricted ,failed to detect one case (small size less than 5mm missed from artifacts) which was confirmed on DPI as non enhanced component ,this results with agreement with Khedr SA et al⁽¹⁰⁾ andJ.A. BLANCO CABELLOS1 et al⁽¹⁵⁾were used combined DPI and DWI in detection of cholesteatoma among recurrent group . There is a significant association (P=0.001) between using T1 post contrast image and DWI finding in detection of cholesteatoma. The mean ADC value for restricted lesions(0.653± 0.098 x 10⁻³)mm²/sec carrying significant difference from non restricted lesions, were their mean ADC value (2.221 ±0.485 x 10⁻³) mm²/sec which is statistically significant (P value less than 0.001) and very accurate in detection ofcholesteatoma , this results near as we compare with Fitzek Clemens et al (13) and lingam et al⁽¹⁶⁾.

Limitation: 1.Using EPI-DWI seems to be main limitation as susceptibility artifact , low resolution, relatively thick sections and lack to obtain two orthogonal plane on DWI sequence (no coronal section ,only axial)which may obscuring details and challenge in diagnosis of small size cholesteatoma .Fallow up with serial MR DWI may solve this problem . 2.DWI lack the clear visualization of the anatomical landmark of temporal bone and identification ossicular erosion ,CT of temporal bone is complementary a for accurate localization and identifying early bone erosion and integrity of ossicular chains.

CONCLUSION:

1. MRI DWI show high accuracy in the preoperative evaluation and the postoperative follow-up for cholesteatoma.
2. Low ADC value for cholesteatomawith its cut off value is great significant difference from non cholesteatoma tissue .The cut off value is $0.653 \times 10^{-3} \pm 0.1818 \text{ mm}^2/\text{sec}$.
3. Delayed T1W1 Post contrast study also give high accuracy rate in detecting recurrent cholesteatoma .
4. 5.2 Recommendation :
5. We recommended MRDWI in the diagnosis of cholesteatoma prior to surgery as complementary to CT scan imaging
6. To do DWI sequences in suspected recurrent cases to avoid unnecessary second look surgery

REFERENCES:

1. Lecler A, Lenoir M, Peron J, Denoyelle F, Garabedian EN, le Pointe HD, Nevoux J. Magnetic resonance imaging at one year for detection of postoperative residual cholesteatoma in children: Is it too early?. *International journal of pediatric otorhinolaryngology*. 2015;79:1268-74.
2. Juliano AF, Ginat DT, Moonis G. Imaging review of the temporal bone: part I. Anatomy and inflammatory and neoplastic processes. *Radiology*. 2013;269:17-33.
3. Baráth K, Huber AM, Stämpfli P, Varga Z, Kollias S. *Neuroradiology of cholesteatomas*. *American Journal of Neuroradiology*. 2011;32:221-29.
4. Harnsberger HR. *Diagnostic imaging: head and neck*. Amirsys Incorporated; 2004.
5. Más-Estellés F, Mateos-Fernández M, Carrascosa-Bisquert B, Facal de Castro F, Puchades-Román I, Morera-Pérez C. Contemporary non-echo-planar diffusion-weighted imaging of middle ear cholesteatomas. *Radiographics*. 2012;32:1197-213.
6. Sreedhar S, Pujary K, Agarwal AC, Balakrishnan R. Role of high-resolution computed tomography scan in the evaluation of cholesteatoma: A correlation of high-resolution computed tomography with intra-operative findings. *Indian Journal of Otology*. 2015;21:103.
7. Elefante A, Cavaliere M, Russo C, Caliendo G, Marseglia M, Cicala D, Piccolo D, Di Lullo A, Brunetti L, Palma A, Iengo M. Diffusion weighted MR imaging of primary and recurrent middle ear cholesteatoma: an assessment by readers with different expertise. *BioMed research international*. 2015;2015.
8. Dubrulle F, Souillard R, Chechin D, Vaneecloo FM, Desaulty A, Vincent C. Diffusion-weighted MR Imaging Sequence in the Detection of Postoperative Recurrent Cholesteatoma 1. *Radiology*. 2006;238:604-10.
9. Vercruysse JP, De Foer B, Somers T, Casselman J, Offeciers E. Magnetic resonance imaging of cholesteatoma: an update. *B-ENT*. 2009;5:233-40.
10. Khedr SA, Adly AM, Fathi A, El Fiky L, Obaid A. Role of diffusion-weighted MRI in the detection of cholesteatoma after tympanoplasty. *Egyptian Journal of Ear, Nose, Throat and Allied Sciences*. 2011;12:141-48.
11. Vaid S, Kamble Y, Vaid N, Bhatti S, Rawat S, Nanivadekar A, Karmarkar S. Role of magnetic resonance imaging in cholesteatoma: the Indian experience. *Indian Journal of Otolaryngology and Head & Neck Surgery*. 2013;65:485-92.
12. Stasolla A, Magliulo G, Parrotto D, Luppi G, Marini M. Detection of postoperative relapsing/residual cholesteatomas with diffusion-weighted echo-planar magnetic resonance imaging. *Otology & Neurotology*. 2004;25:879-84.
13. Fitzek C, Mewes T, Fitzek S, Mentzel HJ, Hunsche S, Stoeter P. Diffusion-weighted MRI of cholesteatomas of the petrous bone. *Journal of Magnetic Resonance Imaging*. 2002;15:636-41.
14. Yiğiter AC, Pinar E, İmre A, Erdoğan N. Value of Echo-Planar Diffusion-Weighted Magnetic Resonance Imaging for Detecting Tympanomastoid Cholesteatoma. *The journal of international advanced otology*. 2015;11:53-57.
15. Cabellos JB, Vélez SO, Cáceres IA, Lluch ES, Monje JG. CT and MRI Correlations in Patients with Suspected Cholesteatoma after Surgery. *The neuroradiology journal*. 2011;24:367-78.
16. Lingam RK, Khatri P, Hughes J, Singh A. Apparent diffusion coefficients for detection of postoperative middle ear cholesteatoma on non-echo-planar diffusion-weighted images. *Radiology*. 2013;269:504-10.