

## The effect of nandrolone decanoate on liver of rabbits using histological and ultrasound methods

Rand A. Hasso\*, Mohammed Taib Tahir\*, Sameer Abdullateef\*\*

\*Department of Anatomy, \*\* Department of Radiology, College of Medicine, University of Mosul.

(Ann. Coll. Med. Mosul 2009; 35(2): 160-166).  
Received: 17<sup>th</sup> Jun 2009; Accepted: 24<sup>th</sup> Mar 2010.

### ABSTRACT

**Objective:** To compare the effects of nandrolone decanoate on the liver structure in male and female rabbits using histological and ultrasound examinations.

**Materials and methods:** Forty-eight adult rabbits were divided into two groups, male and female groups, each included 24 adult healthy rabbits. The male group was subdivided into 4 subgroups, group A was the control group which received only normal saline, group B was given nandrolone decanoate 2mg/kg body weight, group C was given 4 mg/kg body weight of nandrolone decanoate, while group D was given 6 mg/kg body weight of the drug. The female group was also subdivided into 4 subgroups, group A1 was the control group, group B1 was given 2 mg/kg body weight, group C1 was given 4 mg/kg body weight, group D1 was given 6 mg/kg body weight of nandrolone decanoate.

**Results:** All treated groups of both sexes showed a significant increase in body and liver weights in addition to dose related pathological changes ranging from mild to severe form, including vacuolar degeneration and fatty degenerative changes of hepatocytes. In addition, there was a dilatation and congestion of sinusoids, central venules and portal veins with mononuclear inflammatory cells infiltration. Focal areas of necrosis with chronic inflammatory cells infiltration were also noticed in different hepatic lobules. In spite of these histological changes in the liver no abnormal ultrasound findings of the liver were noticed.

**Conclusion:** These changes indicate that the histological effects of the anabolic androgenic steroid nandrolone decanoate on the liver of adult male and female rabbits is the same in both sexes, but the treated female rabbit groups of medium and high doses (C1 and D1) showed more increase in body weight than male rabbit groups. There is no correlation between histological and ultrasound findings.

**Keywords:** Nandrolone decanoate, liver histology, rabbits.

### الخلاصة

**أهداف الدراسة:** لمقارنة التأثير الدوائي للناندرولون ديكانويت على الكبد بين ذكور وإناث الأرانب باستعمال الوسائل النسيجية والأمواج فوق الصوتية.

**الطريقة:** ٤٨ أرنب بالغ تم تقسيمهم إلى مجموعتين ذكور وإناث كل مجموعة تحوي على ٢٤ أرنب بالغ معافى. مجموعة الذكور قسمت إلى ٤ مجاميع، مجموعة (أ) هي مجموعة السيطرة وقد حقنت بمحلول الملح القياسي فقط، مجموعة (ب) حقنت بالناندرولون ديكانويت ٢مغ/كغم/أسبوع، مجموعة (ج) حقنت ب ٤مغ/كغم/أسبوع، مجموعة (د) حقنت ب ٦مغ/كغم/أسبوع. مجموعة الإناث أيضا قسمت إلى ٤ مجاميع، مجموعة (أ١) هي مجموعة السيطرة وقد حقنت بمحلول الملح القياسي فقط، مجموعة (ب١) حقنت بالناندرولون ديكانويت ٢مغ/كغم/أسبوع، مجموعة (ج١) حقنت ب ٤مغ/كغم/أسبوع، مجموعة (د١) حقنت ب ٦مغ/كغم/أسبوع.

**النتائج:** جميع المجاميع المعالجة لكلا الجنسين أظهرت زيادة ملحوظة في أوزان الجسم والكبد بالإضافة إلى تغييرات مرضية متعلقة بالجرعة تتراوح بين معتدل إلى شديد الشكل تتضمن تنكس فجوي و تنكس دهني في الخلايا الكبدية. بالإضافة إلى توسع واحتقان في الأوردة الجيبية، الأوردة المركزية والأوردة البابية مع وجود مناطق بؤرية نخرية تحوي خلايا التهابية مزمنة في فصيصات كبدية مختلفة، ولا يوجد تشابه بين التغييرات النسيجية الحاصلة وفحوصات الموجات فوق الصوتية.

**الخلاصة:** التأثير النسيجي والمرضي للناندرولون ديكانويت على كبد ذكور وإناث الأرناب البالغة هو مماثل في كلا الجنسين. إن مجموعات الأرناب الإناث المعالجة بالجرعة المتوسطة والعالية (ج ١, د ١) أظهرت زيادة أكثر في وزن الجسم من مجموعات الأرناب الذكور. وعلى الرغم من حدوث هذه التغييرات النسيجية كانت فحوصات الأمواج فوق الصوتية طبيعية للكبد والدورة الكبدية وعدم وجود علاقة بين التغييرات النسيجية للكبد والفحص بالأمواج فوق الصوتية للكبد حيث كانت النتائج طبيعية.

**مفتاح الكلمات:** ناندرولون ديكانويت، أنسجة الكبد، الأرناب.

**A**nabolic-androgenic steroids can exert strong effects on the human body and are commonly used at high doses by body builders and athletes to improve performance levels<sup>(1)</sup>. The primary clinical application of the androgens is in the management of androgen deficiency in males. The principal adverse effects are virilization and hepatotoxicity<sup>(2)</sup>. Most laboratory studies did not investigate the actual doses of anabolic androgenic steroids currently abused in the field<sup>(3)</sup>.

According to surveys and media reports, the legal and illegal use of these drugs is gaining popularity. The androgen hormones are produced by the testes, ovaries, and adrenal cortex. The major endogenous androgen is testosterone. Androgens are noted most for their ability to promote expression of male sex characteristics. However, androgens also influence sexuality in females. In addition, androgens have significant physiologic effects and pharmacologic effects unrelated to sex<sup>(4)</sup>.

Androgens increase the synthesis of clotting factors, hepatic triglyceride lipase, sialic acid,  $\alpha$ 1 antitrypsin, and haptoglobin. Conversely, androgens decrease the production of sex hormone –binding globulin, other hormone-binding proteins, transferrin, and fibrinogen. But, hepatic dysfunction is a known side effect of treatment with anabolic androgenic steroid<sup>(5)</sup>.

Testosterone has stimulatory effects on bones, muscles, erythropoietin, libido, mood and cognition centers in the brain and penile erection. It is reduced in metabolic syndrome

and diabetes. The best measure is bio-available testosterone which is the fraction of testosterone not bound to sex hormone binding globulin<sup>(6)</sup>.

The aims of the study are to study and compare the toxic effect of nandrolone decanoate on the liver tissue between male and female groups of rabbits with the aids of histological and ultrasound methods, and to establish its effect on the body and liver weights in both sexes.

### Materials and methods

Forty-eight adult mature rabbits aged (10-14 months); their weights (1600-2000g), were divided into male and female groups, each included 24 rabbits. The male group subdivided into 4 subgroups, group A was the normal control group which received only normal saline, group B was given nandrolone decanoate (Deca- Vinone, Hikma pharmaceuticals, Amman- Jordan) 2mg/kg body weight, group C was given 4 mg/kg body weight of nandrolone decanoate, and group D was given 6 mg/kg body weight of the drug.

The female group was also subdivided into 4 subgroups, group A1 was the normal control group, group B1 was given 2mg/kg body weight, group C1 was given 4mg/kg body weight, group D1 was given 6mg/kg body weight.

Antihelmintic drug (Ivermectin) 2mg/kg body weight was given subcutaneously to act against internal and external parasitic infections<sup>(7)</sup>.

After a week of acclimatization, the animals were given anabolic androgenic steroids or the control vehicle once a week for 3 months by deep intramuscular injections.

Animals were weighed before and after each injection. Each two rabbits were housed in individual cage and given access to food and tap water. Animals were examined daily for clinical manifestations of jaundice and behavioral abnormality.

After one week from the date of the last dose of nandrolone decanoate, the rabbits were sacrificed after ether inhalation; for tissue sampling; dissection of the abdomen was done, the liver was extracted and the weight of the liver was recorded.

The specimens of liver were washed with normal saline, and then each liver was cut into small slices of 4-5 mm thickness. Samples were fixed for more than 24 hour in 10% neutral buffered formalin. The tissues were dehydrated in ascending grades of ethanol, using 70% ethanol for 1 hour, two changes of 90% ethanol with a period of 1 hour for each, then followed by two changes of absolute ethanol; the second one was over night. The slices cleared by two changes of xylene with a period of one hour for each. Embedding of the slices in three changes of paraffin with 57-59 C° melting point, 1 hour each. Two blocks from each specimen were used, and cross sections with an average thickness of 5 micrometer using Reichert Rotary Microtome were cut serially. The sections mounted on the glass slides, and kept for 30 minutes in the vacuum-drying oven at 60 C°. Deparaffinization of the sections in two changes of xylene for 5 minutes. Rehydration by transferring sections into graded ethanol, absolute, 95%, and 70% ethanol, two minutes each. Sections transferred into distilled water for two minutes to be ready for staining. Paraffin sections were stained with Mayar's hematoxylin and eosin, and microscopical examination was done using light microscope<sup>(8)</sup>.

Statistical analysis was done using unpaired T- test at P-value  $\leq 0.05$ <sup>(9)</sup>. At the end of the study and after completion of treatment an ultrasonic investigation of the liver was done for all treated animals. Kretz ultrasound unit

with high frequency linear probe (7.5 M. Hz) was used.

### Observations and results

The body weights were recorded for all animals of both male and female groups every week (Table 1, 2). All animals gained weight during the 12 weeks of treatment and they showed a very good appetite and physical activity. No signs of fatigue or abnormal weakness were observed on the animals and they had normal hair coat and no signs of jaundice were seen among the treated groups. Aggressive behavior was very evident among subgroups C and C1, in addition to D and D1. Animals of these subgroups quarreled with each other and abnormal homosexual behavior was noticed among the subgroups C and D and even bleeding from wounds were noticed especially around the anal region. This is evident only among the male treated groups C and D, but not with the female group which showed only little signs of aggression.

There was a significant difference between group A in which their mean body weight was  $(1821.25 \pm 128.33)$  and group A1  $(1660.00 \pm 83.47)$  and the P-value was (0.014). Also there was a significant difference between groups B  $(1830.00 \pm 108.10)$  and B1  $(1700.00 \pm 86.60)$  and their P-value was (0.025), a little difference was noticed between group C  $(1907.50 \pm 180.53)$  and C1  $(1756.86 \pm 78.20)$  in which their P-value was (0.062) and group D  $(1927.50 \pm 104.84)$  and D1  $(1867.14 \pm 78.25)$  and their P- value was (0.234)(for details see Table 1).

There was an evident increase in the mean weight of the livers in both male and female treated subgroups D and D1 when compared to other subgroups; in all no statistical difference was noticed in the mean liver weight between both male and female subgroups (for details see Table 2).

### Histological findings

In spite of the fact that nandrolone decanoate is an androgenic hormone, almost similar findings were found in both sexes. Sections of liver taken from group B and B1 showed the same changes. They had normal architecture of liver. Sinusoids, central venules and portal

veins were dilated and congested and infiltrated with mononuclear inflammatory cells. Focal areas of necrosis infiltrated by chronic inflammatory cells were also seen. Mild vacuolar degeneration affecting hepatocytes around the central venule were noticed too (Fig.1 & 2).

Groups C and C1 also showed the same histological changes. The architecture of liver was preserved. Sinusoids, central venules and portal veins were dilated and congested and infiltrated with mononuclear inflammatory cells. Moderate vacuolar degeneration was also seen affecting mainly the hepatocytes around the central venule. Focal areas of necrosis infiltrated by chronic inflammatory cells were also seen in different lobules (Fig.3 & 4).

In groups D and D1 the vacuolar degeneration was markedly seen and it was severe in the way that it affected the majority of the hepatocytes in all liver lobules and fatty degenerative changes were also seen, except for a very small area around the portal tract in which the hepatocytes were preserved or mildly affected. Sinusoids, central venules and portal veins were dilated and congested, with mononuclear inflammatory cells infiltration. Focal areas of necrosis with chronic inflammatory cells infiltration were also noticed in different hepatic lobules. Binucleation of some hepatocytes was common and evident in these two groups (Fig.5).

#### Ultrasound Examination

At the end of the three months all the treated animals were examined by ultrasound device before they were killed, the liver showed normal homogenous echoes without space occupying lesion or enlargement in liver size. No dilatation of gall bladder. Intra-hepatic and extra hepatic billiary passages were normal (Fig. 6).

Table (1): Showing the mean body weights of both male and female groups.

Groups	Mean $\pm$ SD		P- Value
	Male (n=8) Mean body weight $\pm$ SD	Female(n=7) Mean body weight $\pm$ SD	
A , A1	1821.25 $\pm$ 128.33	1660.00 $\pm$ 83.47	0.014
B , B1	1830.00 $\pm$ 108.10	1700.00 $\pm$ 86.60	0.025
C , C1	1907.50 $\pm$ 180.53	1756.86 $\pm$ 78.20	0.062
D , D1	1927.50 $\pm$ 104.84	1867.14 $\pm$ 78.25	0.234

Unpaired T- test was used

Table (2): Showing the mean liver weights of both male and female groups.

Groups	Mean $\pm$ SD		P- Value
	Male (n=8) Mean liver weight $\pm$ SD	Mean liver weight $\pm$ SD	
A , A1	69.15 $\pm$ 2.61	65.45 $\pm$ 2.01	0.458
B , B1	70.13 $\pm$ 12.60	68.79 $\pm$ 1.87	0.786
C , C1	72.34 $\pm$ 14.70	72.64 $\pm$ 1.71	0.958
D , D1	81.93 $\pm$ 13.75	78.50 $\pm$ 3.02	0.5310

Unpaired T- test was used

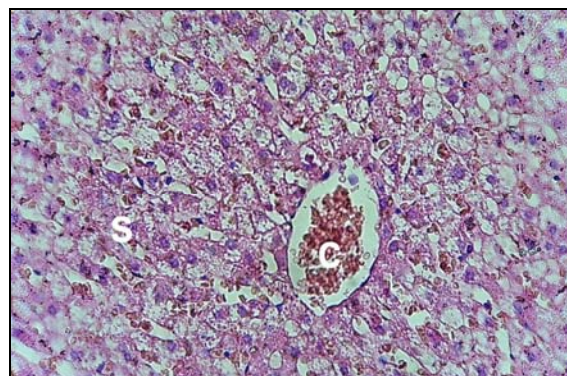


Fig. (1): Photomicrograph of liver of group B showing the congested central venule (C) and sinusoids(S). (H & E X 400).



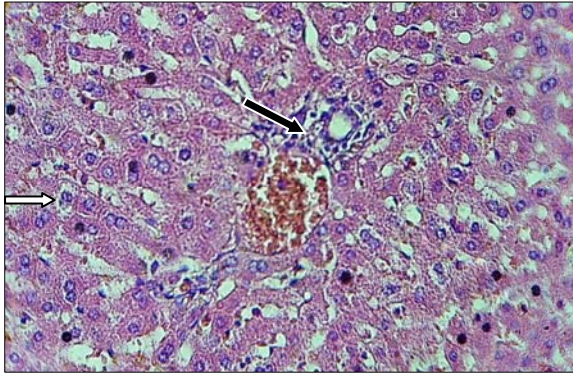


Fig. (2): Photomicrograph of liver of group B1 showing the portal area with mild vacuolar degeneration affecting the hepatocytes (white arrow) with mononuclear inflammatory cells infiltration (black arrow). (H & E X 400).

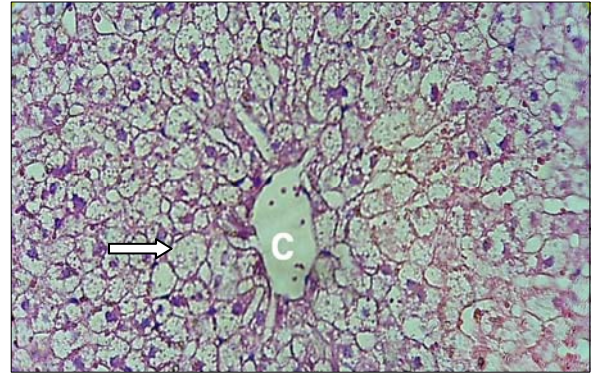


Fig. (5): Photomicrograph of liver group D showing the severe ballooning degeneration affecting the majority of hepatocytes around the central venule (C). (H & E X 400).

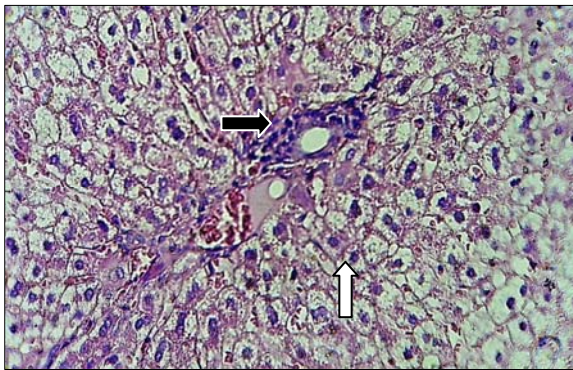


Fig. (3): Photomicrograph of liver group C showing the portal area with moderate ballooning degeneration (white arrow) and mononuclear inflammatory cells infiltration around the bile duct (black arrow). (H & E X 400).

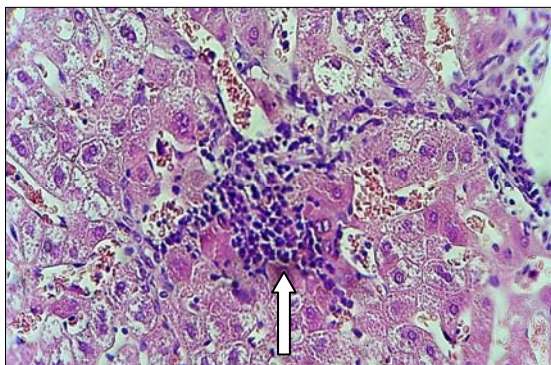


Fig. (4): Photomicrograph of liver group C1 showing the focal area of necrosis with mononuclear inflammatory cells infiltration. (H & E X 400).

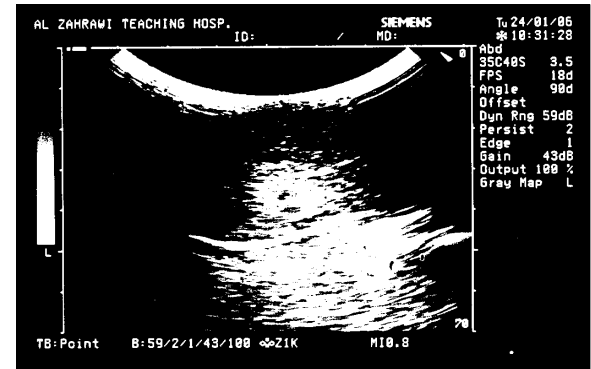


Fig. (6): Abdominal ultrasound of group D showing normal hepatic echoes, no abnormal masses.

## Discussion

Almost any subject abusing androgenic-anabolic steroids will experience some adverse effects. Among these adverse effects is liver toxicity<sup>(10)</sup>.

Because of the secrecy surrounding the use of high doses of androgens, few data are available on the relation of adverse effects to the doses or compounds used. In addition whereas some effects are due to androgenic or estrogenic actions, others may be due to the toxic (non hormonal) effects of the androgen or its metabolites, especially when the dose is very large<sup>(11)</sup>.

The liver is morphologically and functionally modulated by sex hormones. Long-term use of oral contraceptives and anabolic-androgenic steroids can both induce (hemangioma,

adenoma, focal nodular hyperplasia and hepatocellular carcinoma). Hepatic adenomas are rare, benign neoplasms usually occur in young women. The human liver expresses estrogen and androgen receptors and experimentally both androgens and estrogens have been implicated in stimulating hepatocytes proliferation and may act as liver tumor inducers or promoters<sup>(12)</sup>.

In the current study, we noticed that there was a significant difference in the mean body weight of group A which was the male control group and group A1 which was the female control group and this occurred because the male rabbits had more muscular body and larger body build than the female group.

Groups B and B1 which received the lowest dose (2mg/kg/week) of the drug also showed significant difference in their mean body weight, but animals of groups C and C1 which received 4mg/kg/week showed no significant difference between male and female rabbits, and the same for rabbits that received the highest dose of nandrolone decanoate which was 6mg/kg/week. They revealed no significant difference between male and female rabbits of these two groups. This means that the groups received the lowest dose were the same as the control group of both sexes and at this low dose the body weight did not increase significantly in the female group. While groups (C and C1) which received 4mg/kg/week showed no significant difference, because the mean body weights of the female group at this dose start to increase and make no significant difference with the male group which received the same dose. This is also evident for the high dose treated groups of both sexes (D and D1) in which the body weight of the female group was increased and make no difference with the male group that received the same dose, and this is because this drug is an appetizer and has anabolic effect through the stimulation of protein synthesis<sup>(13)</sup>.

Concerning the microscopical changes, both groups B and B1 showed the same microscopical picture; only few hepatocytes showed vacuolar degeneration, while in groups C and C1 the vacuolar degeneration

affected more hepatocytes especially those around the central venules as these cells were more exposed to hypoxia than those around the portal area<sup>(14)</sup>. In groups D and D1 which received higher dose of the drug (6mg/kg/week) the vacuolar degeneration affected nearly all the hepatocytes and areas of focal necrosis were infiltrated with mononuclear inflammatory cells were commonly seen. This is in agreement with Boada's<sup>(15)</sup> findings, who observed the presence of centrilobular degeneration and lipidic vacuolization in male rats treated with high doses of anabolic androgenic steroids. Vieira *et al.*<sup>(16)</sup> found that subchronic treatment with nandrolone decanoate, mainly administered at higher doses, are potentially deleterious to the liver and cause fibrosis. Patil *et al.*<sup>(1)</sup> reported a case of spontaneous hepatic rupture with life-threatening hemorrhage associated with a past history of anabolic steroid intake.

Ultrasound examination performed shortly after the end of the treatment, showed no evidence of hepatomegaly or hyperechogenic masses. Boada *et al.*<sup>(17)</sup> reported a case of a young man who had been using anabolic-androgenic steroids for six months and the hepatic ultrasound showed mild hepatomegaly, with hyperechogenic nodules close together.

In spite of the fact that nandrolone is androgenic hormone, the histological findings of the liver in both sexes were more or less the same. This suggests that there is no variation in the toxic effect of nandrolone decanoate on both sexes. No correlation between the severity of histological findings and ultrasonic examinations of liver, gall bladder, and biliary ducts was found.

## References

1. Patil JJ, O'Donohoe B, Loyden CF, Shanahan D. Near-fatal spontaneous hepatic rupture associated with anabolic androgenic steroid use: a case report. *Br. J. Sports Med.* 2007; 41(7): 4623.
2. McCullough MC, Namias N, Schulman C, Gomez E, Manning R, Goldberg S, Pizano L, Ward GC. Incidence of hepatic dysfunction is equivalent in burn patients

- receiving oxandrolone and controls. *J. Br. Care Res.* 2007; 28(3): 412-420.
3. Hartgens F, Kuipers H. Effects of androgenic anabolic steroids in athletes. *Sports Med.* 2004; 34(8): 513-514.
  4. Evans N.A. Current concepts in anabolic-androgenic steroids. *Am. J. Sports Med.* 2004; 32(2): 534-542.
  5. Mc Pherron AC, Lee SG. Double muscling in cattle due to mutations in the myostatin gene. *Proc. Natl. Acad. Sci.* 1997; 94: 12457-12461.
  6. Bain J. The many faces of testosterone. *Clin. Interv. Aging* 2007; 2(4): 567-76.
  7. Koolhaas J. The Laboratory Rabbits. The UFAW handbook on the care and management of laboratory animals 1999 7<sup>th</sup> ed. , Vol. 1:pp313.
  8. Luna LG. Manual of Histologic Staining Methods of the Armed Forces Institute of Pathology 1968, 3<sup>rd</sup> ed., McGraw Hill Book CO., USA, P3-158.
  9. Harris M. and Teylor G. Medical statistics made easy. Martin Dunitz company 2004; London, UK, pp: 24-34.
  10. Osorio M, Rojo A, Benitez B, Torre A, Uribe M. Anabolic-androgenic steroids and liver injury. *Liver Int.* 2008; 28(2): 278-282.
  11. Bagatell CJ, Bremner WJ. Androgens in men- uses and abuses. *N. Engl. J. Med.* 1996; 334(11): 707-715.
  12. Giannitrapani L, Soresi M, La Spada E, Cervello M, D'Alessandro N, Montalto G. Sex hormones and risk of liver tumor. *Ann. N. Y. Acad. Sci.* 2006; 1089: 228-236.
  13. Demling R, Oxandrolone, an anabolic steroid, enhances the healing of a cutaneous wound in the rat. *Wound Repair Regen* 2000; 8: 97-102.
  14. Strugill G, Lambert H. Xenobiotic-induced hepatotoxicity: mechanisms of liver injury and methods of monitoring hepatic function. *Am. Assoc. Clin. Chem.* 1997; 34: 1512-1526.
  15. Boada LD, Zumbado M, Torres S, Lopez A, Diaz-chico BN, Cabrera JJ, Luzardo OP. Evauation of acute and chronic hepatotoxic effects exerted by anabolic androgenic steroid stanozolol in adult male rats. *Arch. Toxicol.* 1999; 73: 465-472.
  16. Vieira PR, Franca RF, Damaceno-Rodrigues NR, Dolhnikoff M, Caldini EG, Carvalho CR, Ribeiro W. Dose- dependent hepatic response to subchronic administration of nandrolone decanoate. *Med. Sci. Sports Exerc.* 2008; 11: 33-43.
  17. Boada LD, Socas L, Zumbado M, Ramos A, Hernandez JR. Hepatocellular adenomas associated with anabolic androgenic steroid abuse in body builders: a report of tow cases and a review of the literature. *Br. J. Sports Med.* 2005; 39: 27.