

The Diagnostic Accuracy of MRCP and Transabdominal Ultrasound in Patients with Obstructive Jaundice in Correlation with ERCP

*Hiba Mohammed Abdulwahid**, *Ammar Mosa Al-Mosawe***,
*Jinan Abdul Kareem Jabbar****, *Qusay Tayseer Nayyef*****

ABSTRACT:

BACKGROUND:

The validation of the non-invasive radiological tools to replace invasive procedures like Endoscopic retrograde cholangiopancreatography (ERCP) for diagnosis of biliary obstructive disease become essential in modern medical practice. Magnetic resonance cholangiopancreatography (MRCP) is best alternative for ERCP regarding diagnostic aspects.

AIM OF STUDY:

To assess the diagnostic accuracy of MRCP and transabdominal US in identifying the cause of biliary dilatation in correlation with Endoscopic retrograde cholangiopancreatography as the gold standard.

METHODS:

A prospective cross sectional analytic study that involved 64 patients with obstructive jaundice. Abdominal US and MRCP were performed and the cause of obstruction were recorded and correlated with a subsequent ERCP results which were considered as the gold standard. Accuracy, sensitivity, specificity, positive and negative predictive values and P value were calculated for each test.

RESULTS:

Cholelithiasis was the commonest cause of biliary obstruction (45%). The detection rate for MRCP was 96.6% and for ultrasound was 41.4% regarding CBD stones. The diagnostic performance of MRCP for malignant pathologies was (91.7%) sensitivity, 100% specificity, 91.7% accuracy with significant level for detection (P value <0.001). While trans-abdominal ultrasound had lower diagnostic parameters for malignancy detection with 75% sensitivity, 66.7% specificity, 41.6% accuracy and P value (0.228).

CONCLUSION:

MRCP is a non-invasive technique that can detect level and cause of biliary obstruction with high diagnostic performance especially in cholelithiasis and malignancies. MRCP can replace the invasive ERCP as a diagnostic tool in most cases. Also if no cause was identified in MRCP, ERCP can be avoided in most cases

KEYWORDS: MRCP, ultrasound, obstructive jaundice, biliary dilatation, ERCP

INTRODUCTION:

Obstructive jaundice is a common condition that affects the hepatobiliary system, in which there is blockage of bile flow from the liver to the duodenum. The main role of radiologist is to differentiate between hepatocellular and obstructive jaundice, confirm the presence of

obstruction and to identify its cause, location, nature, and extent of lesion pre-operatively^(1,2). Despite continuing technological evolution and increasing availability of imaging tests, such as endoscopic ultrasound, computed tomography (CT), and magnetic resonance imaging (MRI); accurate detection of the cause of biliary dilatation remains a challenge for clinicians and radiologists⁽³⁾. The ease of access to US makes it the first option for the initial radiological examination for patients with biliary obstruction⁽⁴⁾. MRCP is the next option for assessing biliary obstruction and it provides advantages allowing for a better view of pancreatico-biliary tracts⁽⁵⁾.

*Radiology Specialist, Lecturer at the College of Medicine/University of Baghdad.

**Radiology Specialist, Assistant prof at the College of Medicine/Al-Nahrain University.

***Radiology Specialist, Oncology Teaching Hospital/Medical City /Baghdad.

****Medical Technician. Oncology Teaching Hospital/Medical City /Baghdad.

ACCURACY OF MRCP AND TRANSABDOMINAL ULTRASOUND

AIM OF STUDY:

To assess and compare the diagnostic accuracy of trans-abdominal US and MRCP in identifying the cause of biliary dilatation in correlation with Endoscopic retrograde cholangiopancreatography (ERCP) results which were considered as the gold standard.

METHODS:

Study design

A prospective cross sectional analytic study that involved 64 patients with obstructive jaundice. Initially, trans-abdominal ultrasound and MRCP were performed for all patients, then ERCP was proceeded, done by a specialist gastroenterologist, then the cause of obstruction was determined. The results obtained by the U/S and MRCP were recorded and compared with each other relative to the ERCP gold standard results.

Study setting

The study was carried out in the department of radiology of oncology teaching hospital—during the period from August 2018 to December 2019.

Inclusion criteria

- Patients with obstructive jaundice
- age above 15 years

Exclusion criteria

- Previous surgery on the biliary system
- Known case of malignancy

- Patients with contraindication to MRCP and /or ERCP

Participants

Patients were referred from GIT outpatient clinic with clinical & laboratory results suggestive of obstructive jaundice. 64 patients were included in the study whom their U/S examination confirmed a biliary dilatation, MRCP then done for those patients followed by ERCP. They were 36 females and 28 males with ages range 20-90 years and a mean age of 54.8 years.

Transabdominal Ultrasound

Abdominal US was done by specialist radiologist using Philips US machine with curvilinear probe (2-5 MHz). The calibers of both intrahepatic bile ducts and common bile duct (CBD) at porta hepatis level were measured. Tissue harmonic imaging and quiet compression were used to improve visualization of lower CBD and to identify the etiology.

MRCP examination

All MRCP examinations were performed using a 1.5 Tesla MRI (Siemens machine) with phased array coil. The sequences used were: T2WI coronal, T2 haste coronal, T2WI haste coronal thin slice with breath-hold technique and 3D reformatting. Sequences parameters were illustrated in table 1.

Table 1: Parameter used for MRCP protocol.

Parameters	T2WI	T2WI haste	T2WI thin slice with breath hold and 3D reformat
TR	2500	1300	1200
TE	703	91	79
FOV	380	400	350
Slice thickness	1mm	6	4mm

TR: time to repetition, TE : time to echo , FOV: field of view
MRCP Image interpretation

All MRCP images were assessed by two independent specialist radiologists. Bile duct dilatation was considered when intrahepatic main bile duct diameter more than 3mm, and CBD more than 6-7mm. Post-cholecystectomy CBD more than 10mm is considered dilated. The level of biliary obstruction was assessed. Then etiology was classified into benign and malignant. Benign causes include biliary stone(choledocolithiasis), benign stricture, choledocalcyst, etc. Benign stricture appears as short smooth concentric narrowing usually without mass. Stone is

diagnosed when there is signal void structure inside high signal dilated bile duct. Malignant stricture appears as long irregular narrowing with abrupt cutoff, often with presence of mass.

Ethical consideration

Written informed consent was obtained from each participant, under the institutional regulation board committee of department of radiology, oncology teaching hospital, the study followed the Declaration of Helsinki 2008 for research on human subjects.

ACCURACY OF MRCP AND TRANSABDOMINAL ULTRASOUND

Statistical analysis

The sensitivity, specificity, accuracy, positive predictive value, negative predictive value, P value were calculated to determine the diagnostic performance for both ultrasound and MRCP.

All the analysis was performed using MedCalc® version 14.8.1.

RESULTS:

During the study period, 64 patients were included in the study. The mean age was 54.8 ranging from 20 to 90 years. The mean age for benign cases was 40.7 and for malignant cases was 66.5.

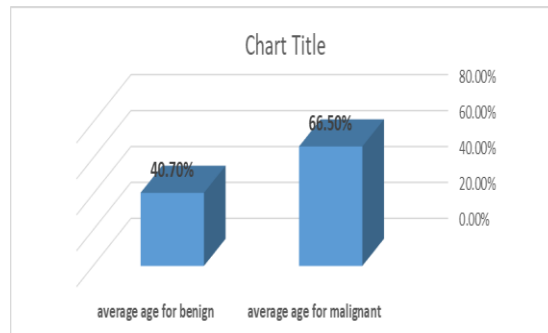


Figure 1: The average age for benign and malignant cases.

Causes of biliary dilatation were as following according to ERCP results: 29 cases (45%) were due to choledocholithiasis, 24 (38%) due to

malignancy, 7 (11%) due to benign lesions, and 4 (6%) no definitive cause was identified and being classified as idiopathic.

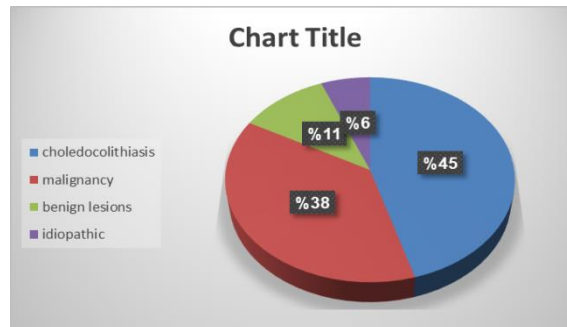


Figure 2: Causes of biliary tract dilatation.

Benign causes of biliary obstruction were 36 cases, of them choledocholithiasis was the most common cause and found in 29 cases in ERCP

(45%) as illustrated in table 2. MRCP diagnosed 28 cases (96.6%) and missed one while ultrasound could diagnose 12 cases only (41.4%).

Table 2: Final pathological diagnosis of benign cases (36 cases).

Diagnosis	ERCP	MRCP	US
Choledocal cyst	2	2	2
Benign stricture	4	2	0
Sclerosing cholangitis	1	1	0
Choledocholithiasis	29	28	12
Total	36	33	14

ERCP: Endoscopic retrograde cholangiopancreatography, MRCP: Magnetic resonance cholangiopancreatography, US: ultrasound

ACCURACY OF MRCP AND TRANSABDOMINAL ULTRASOUND

Malignancy was confirmed in 24 cases (37%). MRCP detected 22 cases and was statistically significant (p value <0.001), while ultrasound diagnosed only 6 (p value =0.22); the different causes of malignancy are illustrated in table 3.

Table 3: Final pathological diagnosis of malignant cases (24 cases).

Diagnosis	ERCP	MRCP	US
Periampullary cancer	9	7	2
Distal cholangiocarcinoma	7	7	0
Klatskin cholangiocarcinoma	3	3	2
Pancreatic head cancer	5	5	2
Total	24	22 (91.6%)	6 (25%)

Four cases (out of 64 cases) with obstructive jaundice were classified as idiopathic in ERCP. MRCP; truly; did not find a cause in 3 of them, but one case was falsely diagnosed as CBD stone. On the other hand; US falsely suspected 2 cases as periampullary tumor and distal CBD stonerespectively and did not demonstrate a cause

in other two cases so further evaluation was requested.

The sensitivity, specificity, accuracy, PPV &NPV of MRCP and the significance level (P value) for detection of both malignant and benign pathologies are illustrated in table 4, figure 3 and 4.

Table 4: Diagnostic performance of MRCP.

	AUC	SN	SP	AC	PPV	NPV	P value
Malignancy	0.958	91.7%	100%	91.7%	100%	60%	<0.001*
Benign	0.833	91.7%	75%	66.7%	97.1%	50%	0.009

AUC: area under the curve, SN: sensitivity, SP: specificity, AC: accuracy, PPV: positive predictive value, NPV: negative predictive value and P value
*significant

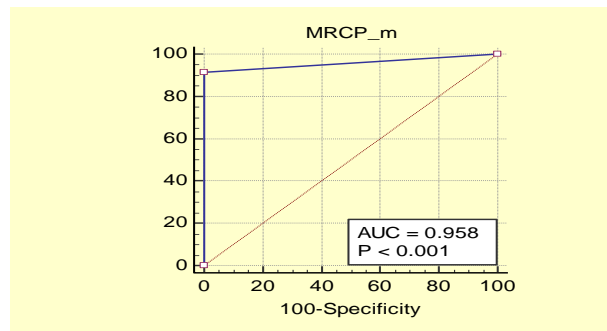


Figure 3: ROC test for MRCP for detection of malignant causes.

ACCURACY OF MRCP AND TRANSABDOMINAL ULTRASOUND

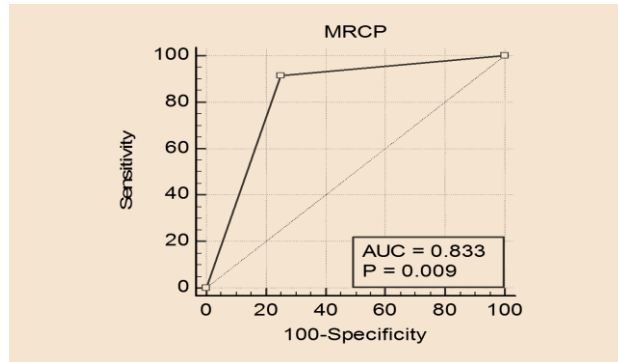


Figure 4: ROC test of MRCP for the detection of benign causes.

The sensitivity, specificity, accuracy, PPV & NPV of transabdominal US and significance level (p value) for detection for both malignant and benign pathologies are illustrated in table 5, figure 5 and 6

Table 5: Diagnostic performance of transabdominal US.

	AUC	SN	SP	AC	PPV	NPV	P value
Malignancy	0.708	75%	66.7%	41.6%	94.7%	25%	0.228
Benign	0.569	38.9%	75%	27%	93.3%	12%	0.5

AUC: area under the curve, SN: sensitivity, SP: specificity, AC: accuracy, PPV: positive predictive value, NPV: negative predictive value

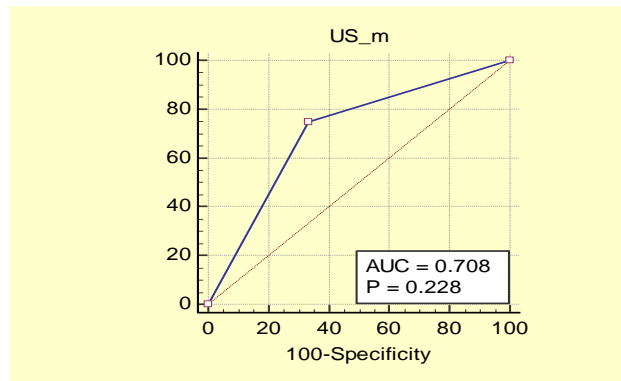


Figure 5: ROC test of ultrasound for the detection of malignant causes.

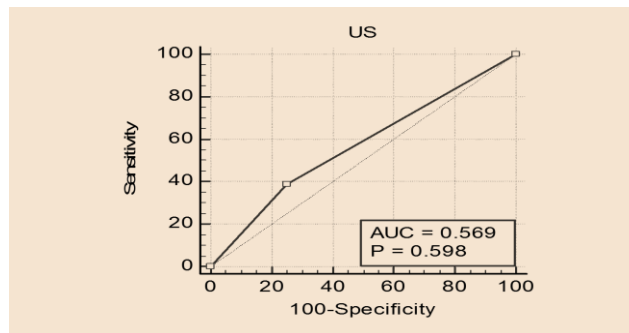


Figure 6: ROC test of trans-abdominal ultrasound for detection of benign causes.

ACCURACY OF MRCP AND TRANSABDOMINAL ULTRASOUND

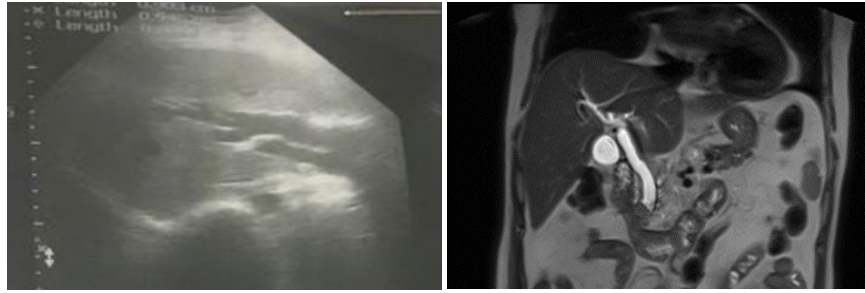


Figure 7: Abdominal ultrasound of 65 yearsmale with obstructive jaundice revealed dilated proximal CBD but distally obscured by bowel gasses. Coronal T2WI MRI revealed dilated CBD with distal abrupt cutoff. Cholangiocarcinoma was confirmed subsequently.

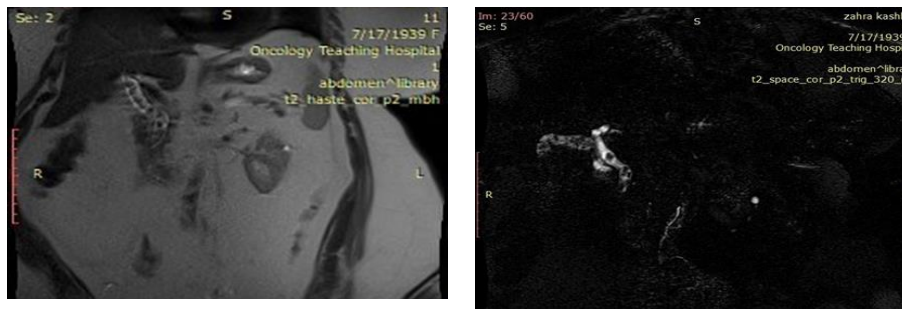

Figure 8: 45-years female with obstructive jaundice. Coronal T2WI and 3D MRCP revealed dilated CBD along its length with multiple stones which were subsequently confirmed at ERCP.

DISCUSSION:

Biliary dilatation is commonly seen by abdominal ultrasound in both symptomatic as well as asymptomatic patients and is one of the most common causes for referral to MRCP or ERCP. Van Hoe noted an increment in CBD diameter in people over 50 years by about 1 mm per decade. This phenomenon was explained by atrophy of elastic fibers within bile duct walls⁽⁶⁾.

Ultrasound can be used as an initial and simple imaging tool to detect biliary obstruction, but unfortunately; many factors affect the accurate diagnosis like overlying bowel gas, acoustic shadowing caused by gall bladder calculi, obesity and breathing artifacts. All these reasons limit the diagnostic accuracy of US in defining the cause in obstructive jaundice⁽²⁾.

MRCP is an important technique for assessment of biliary dilatation. It is a non-invasive tool, does not utilize ionizing radiation or contrast media, and does not need anesthesia. It can visualize bile ducts proximal to the obstruction and can detect the extra-biliary pathologies that might be the cause of patient symptoms. Its limitations include: Lack of

functional information, technical artifacts, and relatively low resolution^(7, 8).

In this study, choledocholithiasis was the commonest cause of biliary dilatation (45%) and the second cause was malignancy (38%). MRCP detected 28 out of 29 cases (96.5%), these results were in concordance with Palmucci et al. who reported that MRCP had diagnosed all the 15 cases with stone-related obstruction in their study⁽⁹⁾.

Munir et al in 2004 reported 15 out of 17 stone-related obstructions⁽¹⁰⁾, while Bhatt C et al in 2005 reported that MRCP did confirm all cases diagnosed with choledocholithiasis in their study⁽¹¹⁾.

The explanation for non-detection of CBD stone in one case by MRCP was mostly due to its small size which was confirmed later only by ERCP. Sequeiros E et al in 2011 reported that it was difficult to detect choledocholithiasis caused by stones <5 mm in diameter using MRCP⁽¹²⁾. Another reason is the location of stone which was impacted at the ampulla. Ultrasound diagnosed 12 out of 29 cases with CBD stones. These results were lower than reported by other studies^(13,14).

Cases with choledocholithiasis detected by US in this study were either in proximal CBD or its size was large enough to be detected. The visualization of lower CBD was largely limited by the overlying bowel gasses.

Malignancy was the second most common cause of biliary dilatation in this study which was confirmed in 24 cases. MRCP detected 22 cases (91.6% detection rate) with diagnostic sensitivity of 91.7%, specificity 100%, accuracy 91.7%, PPV 100% and NPV 60%. These findings were similar to those reported by other studies like Singh et al study in which MRCP had diagnostic sensitivity of 83.3%, specificity 100%, and accuracy 98% for diagnosing Cholangiocarcinoma⁽¹⁴⁾ and Palmucci et al study where MRCP had sensitivity 91.9%, specificity 75%, and accuracy 88.9%⁽⁹⁾. So MRCP revealed high diagnostic accuracy and can be used as alternative tools to ERCP in most cases when the indication is only diagnostic

Ultrasound on the other hand; has diagnosed only 6 cases with malignant causes (detection rate 25%).trans-abdominal US had showed much lower diagnostic parameters with 75% sensitivity, 66.7% specificity, 41.6% accuracy, 94.7% PPV and 25% NPV for the detection of malignant pathologies.

Periampullary carcinoma was the commonest malignant cause which was reported in 9cases. MRCP diagnosed 7 of them (78%)with typical appearance of CBD dilatation anddistal abrupt cutoff. Kushwah et al and Khopde et al found that MRCP had an accuracy of 98% and 100% respectively in diagnosing periampullary growth^(13,15).Ultrasound diagnosed only 2 of periampullary carcinoma,which was comparable to the results reported by Khopde et al⁽¹³⁾.

Cholangiocarcinoma was reported in 10 cases (3 of them were klatskin tumor). MRCP diagnosed all these cases, while ultrasound diagnosed only two and showed only biliary dilatation in the remaining. These results were well-matched with the results of Khopde et al⁽¹³⁾.

Pancreatic head cancer was found in 5 cases. MRCP diagnosed all these cases, while ultrasound diagnosed only 2.

MRCP can identify and distinguish between malignant and benign etiologies with significant level of detection (p value was<0.001 and =0.009 respectively). Diwanjiet al who studied the role of MRCP in pancreatico-biliary disorders concluded that MRCP is providing useful criteria in differentiating benign from malignant causes⁽¹⁶⁾.

CONCLUSION:

MRCP is a non-invasive technique that can detect the level and the cause of biliary obstruction with high diagnostic performance especially in choledocolithiasis and malignant neoplastic process. MRCPcan replace the invasive ERCP as a diagnostic tool in most of these cases. Also if no cause of biliary dilatation was identified in MRCP, the ERCP can be avoided in most cases

MRCP is highly accurate as compared with transabdominal ultrasound in obese patients and in those with lower CBD obstruction.

MRCP is excellent in assessing biliary stricture regarding its length, margin and in differentiating benign from malignant strictures

Abdominal ultrasound was effective in detecting both intrahepatic ducts and proximal CBD dilatations, but of lower diagnostic accuracy in delineating the cause of biliary obstruction.

REFERENCES:

1. Bhargava SK, Usha T, Bhatt S, Kumari R, Bhargava S. Imaging in obstructive jaundice: A review with our experience. *JIMSA*. 2013;26:43-6.
2. Joshi A, Rajpal K, Kakadiya K, Bansal A. Role of CT and MRCP in Evaluation of Biliary Tract Obstruction. *Current Radiology Reports*. 2014;2:72. <https://dx.doi.org/10.1007/s40134-014-0072-x>
3. Rahman R, Ju J, Shamma's J, Goebel S, Sundaram U. Correlation between MRCP and ERCP findings at a tertiary care hospital. *The West Virginia medical journal*. 2010;106:14-9.
4. Hakansson K, Ekberg O, Hakansson HO, Leander P. MR and ultrasound in screening of patients with suspected biliary tract disease. *Acta radiologica (Stockholm, Sweden)* : 1987. 2002;43:80-86. <https://doi.org/10.1034/j.1600-0455.2002.430116.x>
5. Patel HT, Shah AJ, Khandelwal SR, Patel HF, Patel MD. MR cholangiopancreatography at 3.0 T. *Radiographics* : a review publication of the Radiological Society of North America, Inc. 2009;29:1689-706. <https://doi.org/10.1148/rg.296095505>
6. Van Hoe L, Vanbeckevoort D, Van Steenberg W: Atlas of cross-sectional and projective MR cholangio-pancreatography. Springer-Verlag, Berlin Heidelberg, 2006; 56–410.

7. Lomanto D, Pavone P, Laghi A, Panebianco V, Mazzocchi P, Fiocca F, et al. Magnetic resonance-cholangiopancreatography in the diagnosis of biliopancreatic diseases. *American journal of surgery*. 1997;174:33-8. [https://dx.doi.org/10.1016/s0002-9610\(97\)00022-6](https://dx.doi.org/10.1016/s0002-9610(97)00022-6)
8. Sohns JM, Staab W, Dabir D, Spiro JE, Bergau L, Schwarz A, et al. Current role and future potential of magnetic resonance cholangiopancreatography with an emphasis on incidental findings. *Clinical imaging*. 2014;38(1):35-41. <https://dx.doi.org/10.1016/j.clinimag.2013.08.015>
9. Palmucci S, Mauro LA, La Scola S, Incarbone S, Bonanno G, Milone P, et al. Magnetic resonance cholangiopancreatography and contrast-enhanced magnetic resonance cholangiopancreatography versus endoscopic ultrasonography in the diagnosis of extrahepatic biliary pathology. *La Radiologia medica*. 2010;115:732-46. <https://doi.org/10.1007/s11547-010-0526-z>
10. Munir K, Bari V, Yaqoob J, Khan DB, Usman MU. The role of magnetic resonance cholangiopancreatography (MRCP) in obstructive jaundice. *JPM The Journal of the Pakistan Medical Association*. 2004;54:128-32.
11. Bhatt C, Shah P, Prajapati H, Modi J. Comparison of diagnostic accuracy between USG and MRCP in biliary and pancreatic pathology. *Indian Journal of Radiology and Imaging*. 2005;15:177-81. <https://dx.doi.org/10.4103/0971-3026.28796>
12. Vazquez-Sequeiros E, Gonzalez-Panizo Tamargo F, Boixeda-Miquel D, Milicua JM. Diagnostic accuracy and therapeutic impact of endoscopic ultrasonography in patients with intermediate suspicion of choledocholithiasis and absence of findings in magnetic resonance cholangiography. *Revista española de enfermedades digestivas : organo oficial de la Sociedad Española de Patología Digestiva*. 2011;103:464-71. <https://dx.doi.org/10.4321/s1130-01082011000900005>
13. Khopde PA, Kelkar A, Joshi P, Bandgar A, Mahajan M. Pancreatico-biliary pathologies: correlation of USG and MRCP. 2019;6:6. <https://dx.doi.org/10.18203/2349-2902.isj20192969>
14. Singh A, Mann HS, Thukral CL, Singh NR. Diagnostic Accuracy of MRCP as Compared to Ultrasound/CT in Patients with Obstructive Jaundice. *Journal of clinical and diagnostic research : JCDR*. 2014;8:103-7. <https://dx.doi.org/10.7860/JCDR/2014/8149.4120>
15. Kushwah A, Jain S, Agarwal R, Tomar SP. Biliary tract obstructive diseases: a comparative evaluation by ultrasonography and magnetic resonance cholangiopancreatography (magnetic resonance imaging). *Int J Sci Study*. 2015;3:149-53.
16. Diwanji N, Dibbad RB, Sastri M, Desai E. The study of role of magnetic resonance cholangiopancreatography (MRCP) in pancreato-biliary disorders. *Int J Med Sci Public Health*. 2016;5:2635-40. <http://dx.doi.org/10.5455/ijmsph.2016.14072016578>.

ACCURACY OF MRCP AND TRANSABDOMINAL ULTRASOUND
