



MDJ

Modification of Right-Angle Technique in Detection Third Dimensional Radiograph

Dr. Mona A. Alsafi*

*Assis. Professor at Al-Farabi University College, Dean of Dentistry Department, Iraq. B.D.S., M.Sc., Diagnosis and Maxillofacial Radiology, Ph.D. Orthodontics.

Abstract

Aim of the study: The main goal of this study was to evaluate using of right-angle technique for detecting the impacted objects in maxilla and mandible arches in three dimensional radiographs.

Material and Methods: eighteen patients, seventeen were males, with one female age ranging from eighteen to twenty-four years (according to patients who attend to oral radiology dental clinic). The two radiographs are taken at the right angle to each other. This will indicate the tooth's position in the superior-inferior and anteroposterior relationships. Another radiograph was taken in true occlusal (cross-section) projection using an occlusal/periapical film will show the buccal (labial)- lingual and anteroposterior relationship.

Results: the contrast value for the radiographs, in this case, is the following number which is ≤ 0.5 . It was significant it means acceptable from a statistics point of view, which the numbering is ≥ 0.5 it was non-significant which means most cases are highly significant from in statistic point of view.

Conclusion: according to values of outcomes and their significance can be used to the patient effectively detect this kind of impaction. Right angle technique is an effective to detect third dimension of impacted tooth (the depth) if it is buccally, linguallly, mesially, distally or transverse. According to outcomes and its significance can be used to the patient effectively detect this kind of impaction.

Keywords: Impacted teeth, Periapical X-ray, Right Angle radiograph, Cone beam, Phosphoric plate film, Radiographic Techniques.

Introduction

Background

Three-dimensional radiographs arose from X-Ray and Digital Cone Beam Computed Tomography (CBCT). These aids can assist in the diagnostic evaluation of impacted, transposed, or additional teeth or other complicated dental cases. [1,2]

The right-angle technique is a simple, easy, and low-cost method to find out where an impacted tooth is located or

any foreign object in the oral and maxillofacial region. This technique is primarily used for locating objects in the mandibular arch such displaced fragments of bone in the floor of the mouth after trauma to the jaws. [3,4]

Limitations of periapical radiograph

Reliable limitations are seen with conventional radiographs. While a three-dimensional object exposure to x-ray beams, the depiction will appear as a two-dimensional image. Consequently, they reveal a failure to determine the depth of the depicted images. In order to acquire as much information as possible from a radiograph, a dentist must perceive the precise three-dimensional image of the intended anatomic area according to one or more trials of two – dimensional images (radiographs). [5]

Advantages of the right-angle technique

The studied radiographic technique is primarily used to detect:

- 1 – Radiopaque foreign bodies.
- 2– Remnants of the teeth or those that have displaced toward the surrounding tissues.
- 3– Impacted tooth and hyperdontia.
- 4 – Compound odontoma.
- 5 – Lee forte 1 and mandible Fractures.
- 6 – Buccally and Lingually wall expansion of the jaw.

7 – Relationship of invisible dental parts to adjacent critical structures (nasal cavity, maxillary sinus, and inferior alveolar nerve). [6] The presence of an impacted tooth may be revealed by chance radiographically, or it may be detected radiographically post-clinical examination.

The treatment plan of the impacted teeth is achieved, which requires either orthodontic therapy (alignment in the arch) or surgical extraction. The economic benefit of this technique comparing with other digital devices is an encouraging factor for adopting this method. To locate the position of the tooth by this technique: Using the different reference planes to achieve two radiographs. (Right angle or Miller's Technique). The principle of this technique depends on two radiographs at a right angle to each other, the position of the target is related with three dimensions in this way. [7,8]

The right-angle technique is a simple, easy, and low-cost method to locate the impacted tooth or any foreign objects in the oral and maxillofacial region. As the name implies, two radiographs are taken at a right angle to each other, either a periapical or panoramic view would show the impacted tooth. These two shots will reveal the position of the target object in the superior-inferior and anteroposterior relationships, another radiograph taken in a true occlusal (cross-section). [9]

The periapical film imagines the buccal (labial)-lingual and antero-posterior relationship. By observing these two different views taken at the right angle to each other. one can clearly locate the position of the object in buccal (labial) or lingual aspect and in the antero-posterior direction. This technique is primarily used to locate the Bucco-lingual position of an impacted tooth especially the third molar. [8,9,10] A comparison between miller method (Right angle technique) & clarck method (tube shift technique) has shown in (table 1.1). The main goal of this study to

evaluate using of right-angle technique for locating impacted objects in both jaw arches in three dimensions.

Material and Method

Step wedge (handmade) consist of twenty plates of Aluminum, each plate 1mm thickness, used for measuring visual contrast. (Figure 2.1.a, b, c, d, e). Phosphoric plate film size No.2 (figure 2.2). The contributors in this study were eighteen patients, seventeen were males, with one female age ranging from eighteen to twenty-four years (according to patients attend to oral radiology dental clinic).

Methods:

This study was approved by the Dentistry Department, Al-Farabi University College, Baghdad, Iraq. Many processes have been achieved in protocol of this study.

Periapically:

- The investigated tooth should be in contact with receptor, or close together.
- the parallelism between the tooth and the image receptor.
- The position of the image receptor should be vertically for anterior teeth (incisors and canines), while it should be horizontally with premolars and molars, and adequate receptor include the apices to depict the apical tissues.
- The position of X-ray tube head fulfills the condition, that beam meets the tooth and the image receptor at right angles in both planes vertically and horizontally.
- The positioning should be repeatable (figure 2.3)

Occlusally: the seat of patient as the head supported, since the occlusal plane adjust horizontally and parallelly to the floor, also the patient is asked to hold a protective thyroid shield. The image beam receptor as proper barrier wrapped, is fitted flat into the mouth and introduce to the occlusal surfaces of the mandibular teeth. The patient bites together gently. The image receptor is positioned in central region of the mouth with its long axis junctions in adults and anteroposterior position in children.

Anterior maxilla: the X-ray tube head is aimed toward the patient in the midline, directing downwards through the septum of the nose at an angle of 65° – 70° with the receptor. (Figure 2.4).

Posterior maxilla: the parallel long axis directs to the facial surfaces of the posterior teeth, to obtain maxillary lateral occlusal image. The central beam is aimed toward a vertical angle of $(+60)$ to $(+70)$ degrees and centered slightly inferior to the corner of the eye. (Figure 2.5).

Anterior mandible: the lower jaw anterior occlusal radiograph is done with the long axis anteroposterior position or horizontally, which made on both adults and children. the central beam is directed with a vertical angle of (-55) to (-60) degrees, a horizontal plane of 0 degrees and positioned on the chin, (figure 2.6).

Posterior mandible: the film is fitted parallel with the long axis to the facial surfaces of the posterior teeth. The central ray is aimed with a vertical angle of (-50) degrees through the center of interest (often the molar or premolar region), (figure 2.7). Parameters determined in our method:

- 1- Peak kilovoltage (KVP): 12

- 2- Milliampere (mA): 15
- 3- Time :30 s.

Processing has achieved at room temperature. Time of processing reduced in summer to 60s while in winter 120s. X-ray machine model: DL-201 Serial: RPC-22102017.

Results

In this study, four parametric features were used to choose which technique is more accurate; Distortion, Elongation, Shortening and Overlapping. The results are including derived radiographic images and three tables as following:

Features

Distortion: PIO: α OIO is 0.05 % and its mean that $p \leq 0.05$ so it is significant.

Magnification: PIO: α OIO is 0.06 % and its mean that $p \leq 0.05$ so it is NOT significant.

Unsharpness: PIO: α OIO is 0.03 % and its mean that $p \leq 0.05$ so it is significant

Elongation: PIO: α OIO is 0.03 % and its mean that $p \leq 0.05$ so it is significant

Shortness: PIO: α OIO is 0.04 % and its mean that $p \leq 0.05$ so it is significant

Con cut: PIO: α OIO is 0.11 % and its mean that $p \leq 0.05$ so it is NOT significant

Dropping film: PIO: α OIO is 0.12 % and its mean that $p \leq 0.05$ so it is NOT significant

Discoloration: PIO: α OIO is 0.13 % and its mean that $p \leq 0.05$ so it is NOT significant.

Scratching: PIO: α OIO is 0.03 % and its mean that $p \leq 0.05$ so it is significant.

According to table (III) it shows the contrast value for the radiographs in this case as following the number which is ≤ 0.5 . It was a significant it means acceptable

from statistics point of view, which the numbering is ≥ 0.5 it was non-significant that mean most cases are highly significant in statistic point of view. The final radiographic images appear the exact location of target object. (Figure 3.1, 3.2, 3.3).

Discussion

The expected reasons for localizing impacted third molar or other hidden objects through the maxilla and mandible, with methods of localization have been described. One of suggestable radiographic method to localize the hidden object, the right-angle technique. According to Stanley G, Jacobs SG, Ericson and (Wolf JE, Mattila Becker A.). Significance of distance: two distances are important in localization (Ericson S, Kurol J.). [11,19]

The distance between crown and apical portion of the tooth, and the distance between its width, (transverse and longitudinal) whatever the impaction it is according to (Keur, et al 1994.). Because the difficulty of impaction can be identified if it's buccally, lingually, drifted menially, distally or transverse, applying this tech. to identify what is the impaction. [15, 20]

Goaz PW and White indicate the depth of the object as important need in the aid of diagnosis that give agreement with other studies. Comparing between two images is achieved for locating the target body in three-dimensions. This protocol can be effectively done for the upper impacted canine (with periapical and maxillary occlusal projection), or in case of fracture of the mandible to locate any displacement (with panoramic, lateral

oblique projection and mandibular occlusal projection). [10, 20, 21]

Different radiographic techniques have evolved from time to time to be accurately used in localization, but none of them could provide 100% reliability. Finally, a combination of more than one procedure was used to improve the accuracy of each radiographic method. [24-31]

Conclusion

Right angle technique is an effective to detect third dimension of impacted tooth (the depth) if it is buccally, lingually, mesially, distally or transverse. According to outcomes and its significance can be used to the patient effectively detect this kind of impaction.

Acknowledgement

The authors would like to acknowledge facilities from Al-Farabi University College in Baghdad also grateful for practical support of the department of dentistry staff.

Conflicts of Interest

The author reported that there is no conflict of interest

References:

1. Venkatesh E, Elluru SV. Cone beam computed tomography: basics and applications in dentistry. *J Istanbul Univ Fac Dent*. 2017;51(3 Suppl1):102-21.
2. Signorelli L, Patcas R, Peltomäki T, Schätzle M. Radiation dose of cone-beam computed tomography compared to conventional radiographs in orthodontics. *J Orofac Orthop*. 2016;77(1):9-15.
3. Bell GW, Rodgers JM, Grime RJ, Edwards KL, Hahn MR, Dorman ML, Keen WD, Stewart DJ, Hampton N (2003) The accuracy of dental panoramic tomographs in determining the root morphology of mandibular third molar teeth before surgery. *Oral Surg Oral Med Oral Pathol Oral Radiol Endod* 95(1):119–125.
4. The American Dental Association Council on Scientific Affairs. The use of cone-beam computed tomography in dentistry. *J Am Dent Assoc* 2012;143(8):899-202.
5. Whaites E, Drage N (2013-06-20). *Essentials of dental radiography and radiology* (Fifth ed.). Edinburgh.
6. Liu DG, Zhang WL, Zhang ZY, Wu YT, Ma XC. Localization of Impacted
7. Maxillary Canines and Observation of Adjacent Incisor Resorption with ConeBeam Computed Tomography. *Oral Surgery, Oral Medicine and Oral Pathology, Oral Radiology and Endodontics* 2008; 105(1) 91-98 Ericson S, Kurol J. Early treatment of palatally erupting maxillary canines by extraction of the primary canines. *Eur J Orthod* 1988; 10:283-95.
8. Jacobs SG. Reducing the incidence of unerupted palatally displaced canines by extraction of deciduous canines: the history and application of this procedure with some case reports. *Aust Dent J*. 1998; 43:20-7.
9. . Boeddinghaus R, Whyte A. Current Concepts in Maxillofacial Imaging. *European Journal of Radiology* 2008; 66(3) 396-418
10. S, Kurol J. Incisor resorption caused by maxillary cuspids: a radiographic study. *Angle Orthod* 1987; 57:332-46.

11. study. Wolf JE, Mattila;57:332-46. 6. Preda L, La Fianza A, Di Maggio EM, Dore R, Schifino MR, Campani R, et al. The use of spiral computed tomography in the localization of impacted maxillary canines. *Dentomaxillofac Radiol* 1997; 26:236-41.
12. Goaz PW, White SC. *Oral radiology: principles and 21 interpretation*, 3rd ed. St Louis: Mosby; 1994. p. 102-5.
13. Keur JJ. Radiographic localization techniques. *Aust Dent J* 1986; 31:86-90.
14. Jacobs SG. Localisation of the unerupted maxillary canine: additional observations. *Aust Orthod J* 1994; 13:71-5.
15. Isaacson KG, Jones ML, editors. *Orthodontic radiography: guidelines*. London: British Orthodontic Society; 1994.
16. Bedoya MM, Park JH. A review of the diagnosis and management of impacted maxillary canines. *J Am Dent Assoc* 2009;140:1485-93. Jordan RE, Abrams L, Kraus BS, editors. *Kraus' dental anatomy and occlusion*, 2nd ed. St Louis: Mosby; 1992. p. 30, 43.
17. Jacobs SG. The impacted maxillary canine: further observations on aetiology, radiographic localisation, prevention/interception of impactions, and when to suspect impaction. *Aust Dent J* 1996;41:310-6.
18. Ericson S, Kurol J. Longitudinal study and analysis of clinical supervision of maxillary canine eruption. *Community Dent Oral Epidemiol* 1986;14:172-6.
19. Peck S, Peck L, Kataja M. The palatally displaced canine as a dental anomaly of genetic origin. *Angle Orthod* 1994;64:249-56.
20. A. Kolokythas, E. Olech, and M. Miloro, "Alveolar osteitis: a comprehensive review of concepts and controversies," *International Journal of Dentistry*, vol. 2010, Article ID 249073, 10 pages, 2010.
21. A. Lucchese and M. Manuelli, "Prognosis of third molar eruption: a comparison of three predictive methods," *Progress in orthodontics*, vol. 4, no. 2, pp. 4–19, 2003.
22. J. D. Mancuso, J. W. Bennion, M. J. Hull, and B. W. Winterholler, "Platelet-rich plasma: a preliminary report in routine impacted mandibular third molar surgery and the prevention of alveolar osteitis," *Journal of Oral and Maxillofacial Surgery*, vol. 61, no. 8, article 40, 2003.
23. C. A. Babbush, S. V. Kevy, and M. S. Jacobson, "An in vitro and in vivo evaluation of autologous platelet concentrate in oral reconstruction," *Implant dentistry*, vol. 12, no. 1, pp. 24–34, 2003.
24. R. E. Marx and A. Garg, *Dental and Crainofacial Applications of Platelet-Rich Plasma*, Quintessence, Chicago, Ill, USA, 2005.
25. R. C. Moriano, W. M. de Melo, and C. Carneiro-Avelino, "Comparative radiographic evaluation of alveolar bone healing associated with autologous platelet-rich plasma after impacted mandibular third molar surgery," *Journal of Oral and Maxillofacial Surgery*, vol. 70, no. 1, pp. 19–24, 2012.
26. V. Sollazzo, A. Lucchese, A. Palmieri et al., "Calcium sulfate stimulates pulp stem cells towards osteoblasts differentiation," *International Journal of Immunopathology and Pharmacology*, vol. 24, no. 2 supplement, pp. 51S–57S, 2011.
27. D. M. Dohan, J. Choukroun, A. Diss et al., "Platelet-rich fibrin (PRF): a second-

generation platelet concentrate—part I: technological concepts and evolution,” *Oral Surgery, Oral Medicine, Oral Pathology, Oral Radiology and Endodontology*, vol. 101, no. 3, pp. E37–E44, 2006.

28. D. M. Dohan, J. Choukroun, A. Diss et al., “Platelet-rich fibrin (PRF): a second-generation platelet concentrate—part II: platelet-related biologic features,” *Oral Surgery, Oral Medicine, Oral Pathology, Oral Radiology and Endodontology*, vol. 101, no. 3, pp. E45–E50, 2006.
29. R. E. Marx, E. R. Carlson, R. M. Eichstaedt, S. R. Schimmele, J. E. Strauss, and K. R. Georgeff, “Platelet-rich plasma: growth factor enhancement for bone grafts,” *Oral Surgery, Oral Medicine, Oral Pathology, Oral Radiology, and Endodontics*, vol. 85, no. 6, pp. 638–646, 1998.
30. J. Choukroun, A. Diss, A. Simonpieri et al., “Platelet-rich fibrin (PRF): a second-generation platelet concentrate—part IV: clinical effects on tissue healing,” *Oral Surgery, Oral Medicine, Oral Pathology, Oral Radiology and Endodontology*, vol. 101, no. 3, pp. E56–E60, 2006.
31. P. J. Vezeau, “Dental extraction wound management: Medicating postextraction sockets,” *Journal of Oral and Maxillofacial Surgery*, vol. 58, no. 5, pp. 531–537, 2000.

Table 1.1 A comparison between miller method (Right angle technique) & clarck method (tube shift technique)

<u>Right angle technique</u>	<u>Tube shift technique</u>
1-Used for intraoral and extraoral tech.	Used for intraoral tech *
2- Can be used for upper and lower jaw	Only expected for lower jaw because of curve of spee
3- Not interfere with curve of spee (easier)	Should follow curve of spee (more difficult)
4 – indicated for the full mouth Series (14 P.A + 2 occlusal +2 bit + R.A)	Not indicated *

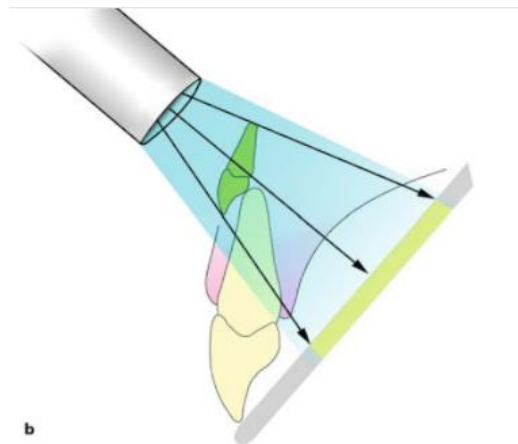


Figure 1.1 periapical radiograph tech.

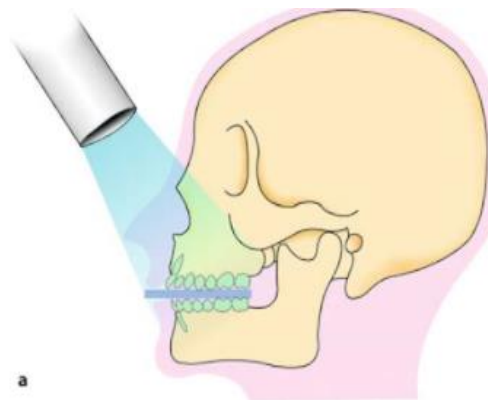


Figure 1.2 occlusal radiograph tech.



(Figure 2.1.a) Aluminum step wedge top view



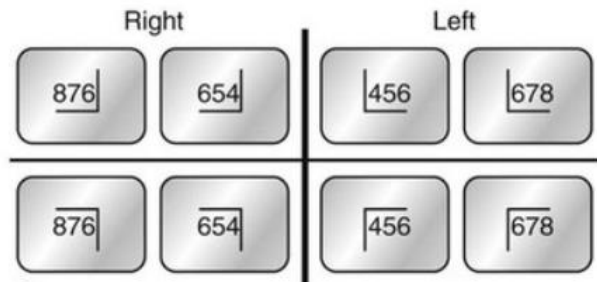
(Figure 2.1.b)Aluminum step wedge side view .



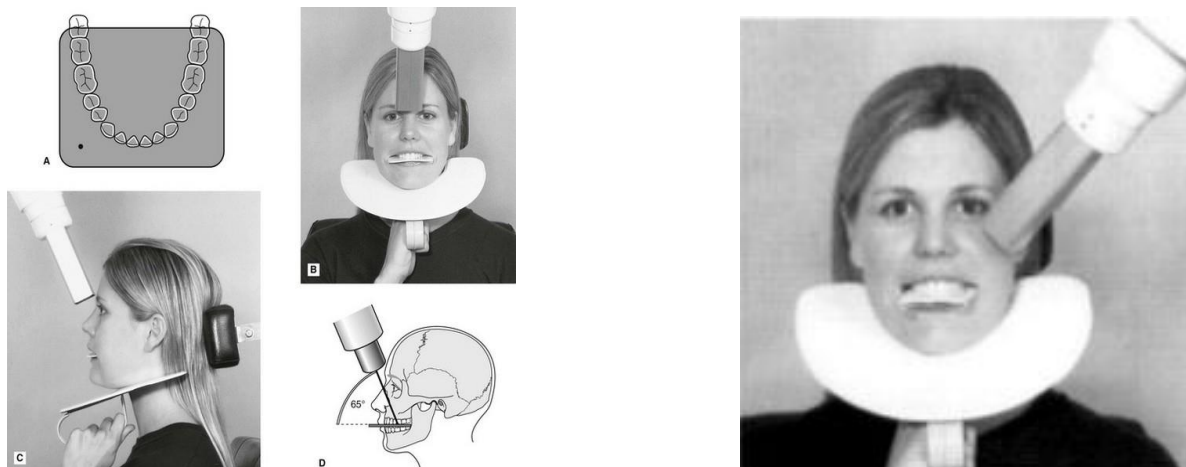
(Figure2.1.c, d, e) Aluminum step wedge



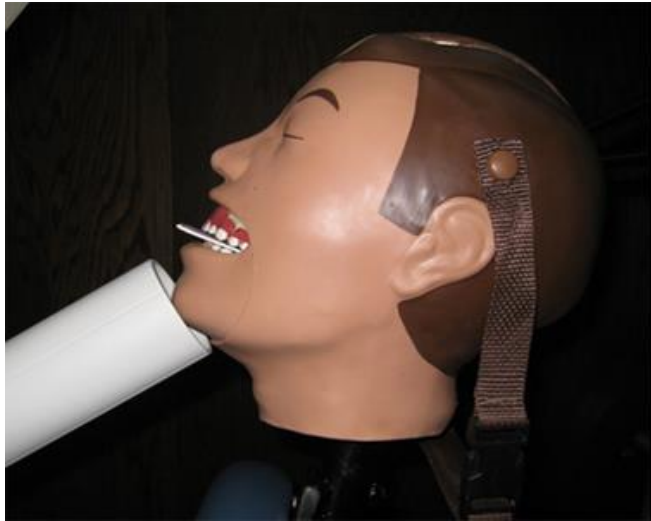(Figure2.2) film



(Figure 2.3) film position in the mouth



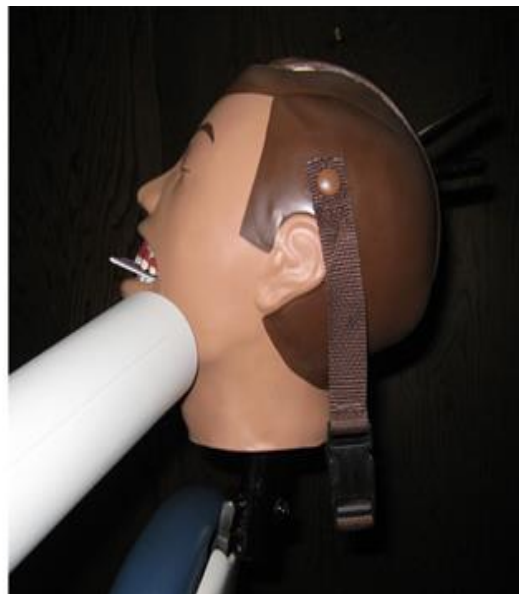
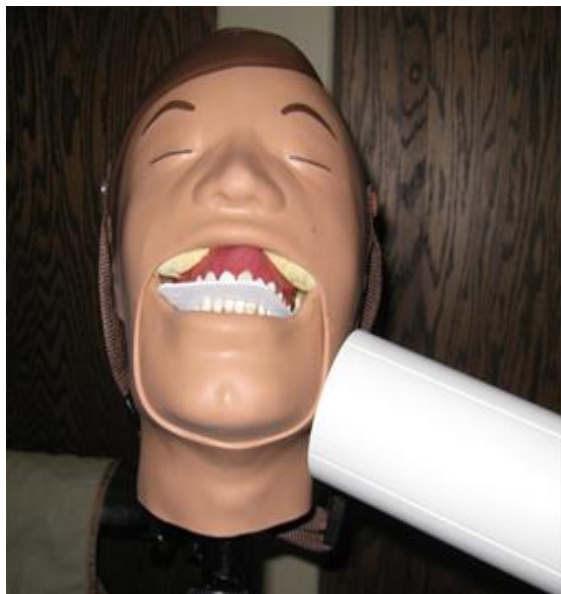(Figure 2.4) Anterior maxilla



(Figure 2.5) Posterior maxilla



(Figure 2.6) Anterior mandible



(Figure 2.7) Posterior mandible

(Table I): The patients who contributed according to gender.

No. patient	Gender	Age/Years
18	17 ♂ 1 ♀	18-24

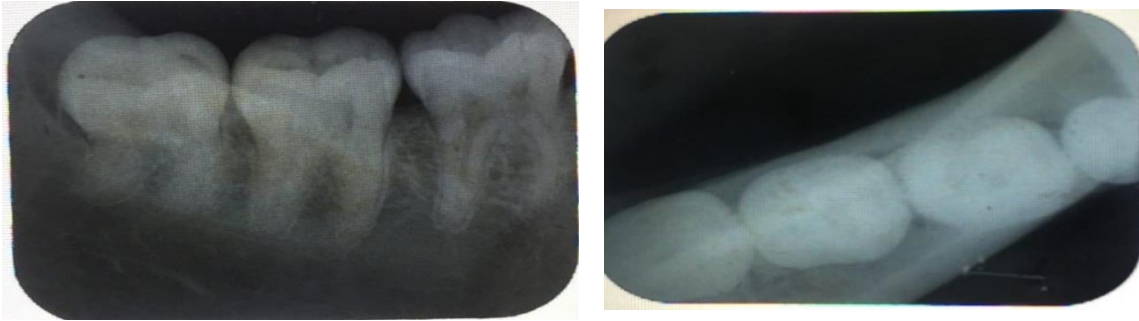
(Table II): Geometrical results

Distortion	Magnification	Unsharpness	Elongation	Shortness
PIO = 3 OIO =2 MEAN=0.05	PIO = 2 OIO = 4 MEAN=0.06	PIO=1 OIO=3 MEAN=0.03	PIO=2 OIO=1 MEAN=0.03	PIO=1 OIO=3 MEAN=0.04


Con cut	Dropping film	Discoloration	Scratching	Mean
PIO=4 OIO=7 MEAN=0.11	PIO=5 OIO=7 MEAN=0.12	PIO=5 OIO=8 MEAN=0.13	PIO=1 OIO=2 MEAN=0.03	0.066%

(Table III): Percentage and logarithm value of each case According to Aluminum step wedge, and the equation $L_{\max} - L_{\min} / L_{\text{background}}$. Post-radiographic results:

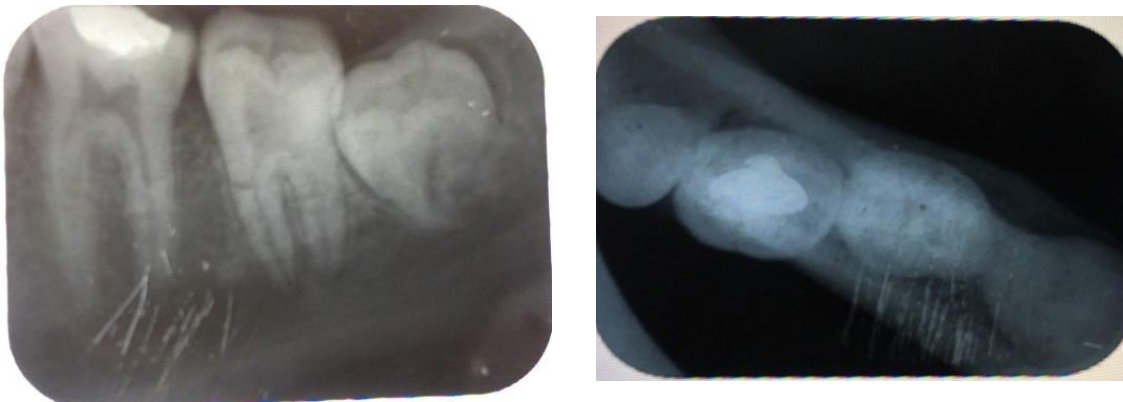
P.N.	Contrast of films	Log.	p. value
1	P.I.O. 13 I.O.O. 14	0.0625	Significant
2	P.I.O. 15 I.O.O. 6	0.5625	Significant
3	P.I.O. 17 I.O.O. 9	0.5	Significant
4	P.I.O. 13 I.O.O. 12	0.0625	Significant
5	P.I.O. 19 I.O.O. 19	0	Highly significant
6	P.I.O. 17 I.O.O. 7	0.625	
7	P.I.O. 18 I.O.O. 16	0.125	Significant
8	P.I.O. 13 I.O.O. 9	0.25	Significant
9	P.I.O. 14 I.O.O. 10	0.25	Significant
10	P.I.O. 17 I.O.O. 16	0.0625	Significant
11	P.I.O. 17 I.O.O. 9	0.5	Significant
12	P.I.O. 17 I.O.O. 16	0.0625	Significant
13	P.I.O. 17 I.O.O. 9	0.5	Significant
14	P.I.O. 17 I.O.O. 3	0.875	
15	P.I.O. 17 I.O.O. 7	0.6875	
16	P.I.O. 16 I.O.O. 19	0.0625	Significant
17	P.I.O. 18 I.O.O. 17	0.0625	Significant
18	P.I.O. 16 I.O.O. 17	0.0625	Significant



(Figure 3.1) Case No.1



(Figure 3.2) Case No.2



(Figure 3.2) Case No.3