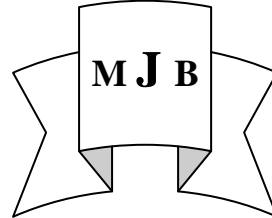


Etiological Agents of Pruritus Vulvae in Prepubertal Girls, In Hilla City

Kareema A. Al-Khafajji Ban Alwash Huda Hadi Al-Hassnawi
College of Medicine, University of Babylon, Hilla, Iraq.



Abstract

Vulvar pruritus is a common complaint in females of all ages. However, little has been published on pruritus vulvae in children as a primary symptom. A total of 70 cases of pre pubertal girls collected from private clinics, aged 8 months to 9 years at the time period from June 2009 to January 2010. History was taken regarding family history, economic state, present history and presence of other diseases. The chief complaint of them was pruritus vulvae, from which 20 cases (28.57%) had dysuria, as well as clinical examination revealed; redness of vulvae was found in 48 cases (68.57%), vaginal discharge in 10 cases (14.28%) and vaginal bleeding in two case (2.8%). Vulval and perianal *Molloscum contagiosum* lesion in 8 cases (11.4%) while the least vulval and perianal genital warts in (7.1%). On laboratory diagnosis using tape test searching for pin worm ova, only 30 cases (42.9%) out of the 70 cases had positive result. Gram stain of swabs have been taken from the 10 cases of vaginal discharge who were suspected sexually abused children reveals gram negative diplococci of gonorrhea in 6 cases and demonstration of pseudohyphae on the smear was taken from the red vulvae on 4 cases.

Isolation and identification of bacterial isolates were found in 18 cases, and *Candida* species in 4 cases. The most frequently isolated bacteria were *Streptococcus faecalis* and *Neisseria gonorrhoeae* in 6 cases (21.4%), *Escherichia coli* 4 cases (14.3%), *Staphylococcus aureus* 3 cases (10.7%), *Streptococcus agalactiae* and *Streptococcus pyogenes* 2 cases (7.1%) for each, *Proteus mirabilis* 1 case (3.6%) and *Candida* spp. 4 cases (14.3%).

الخلاصة

الحكة المهبليّة مشكلة شائعة في النساء بكل الأعمار، ومع ذلك القليل سجل عن الحكة المهبليّة في الأطفال كأعراض أولية. من مجموع 70 بنت في سن قبل المراهقة جمع من العيادة الخاصّة تتراوح أعمارهم بين 8 شهور و 9 سنة، للفترة من شهر حزيران 2009 إلى كانون الثاني 2010. تمّ الاستجواب الجيد عن تاريخ العائلة والحالة المعاشية والتاريخ الحالي للمرض ووجود أمراض أخرى. الشكوى الرئيسيّة للمريضات حكة مهبليّة شديده، ومنها 20 حاله (28.57%) يعانون من حرقة أثناء التبول، إضافة إلى ذلك دلّ الفحص الطبي على وجود احمرار في المهبل في 48 حاله (68.57%)، إفرازات مهبليّة في 10 حالات (14.28%)، ونزف مهبلي في حلتين (2.8%)، داء اللؤلؤ الساري حول الشرج والمهبل في 8 حالات (11.4%) و تأليل جنسية حول فتحة الشرج والمهبل في 8 حالات (11.4%). الفحص المختبري باستعمال tape test للبحث عن وجود بيوض الديدان الديدوسية، فقط 30 حاله (42.9%) من مجموع 70 بنت أظهرت نتائج موجبه، صبغة كرام للعينات المأخوذه ل 10 حالات يعانون من إفرازات مهبليّة والمشبوه بأنهم مستغلين جنسيا أعطت سالبة الغرام لتابعه لتثائي المكورات الخاصه بمرض السيلان ل 6 حالات مع وجود الخيوط الفطريه الكاذبه من المسح المأخوذه من المهبل المحمر ل 4 حالات. عزل وتشخيص عزل البكتريا في 18 حاله وأجناس المبيضات في 4 حالات. أكثر عزل البكتريا انتشارا كانت *Streptococcus faecalis* and *Neisseria gonorrhoeae* عزلت من حالات 6 (21.4%) ثم *Streptococcus agalactiae* and *Streptococcus pyogenes* في 3 حالات (10.7%)، ثم *Proteus mirabilis* في حاله واحده (3.6%)، وأجناس المبيضات في 4 حالات (14.3%).

Introduction

Vulvovaginitis in the prepubertal child is the most common gynecological complaint seen

in Pediatric and dermatological practice [1]. Vulvovaginal complaints in prepubertal children may be the result of infection, congenital abnormalities,

trauma, or dermatologic conditions[2]. Vaginitis may have a nonspecific etiology or may be due to known pathogens.

Symptoms include vaginal discharge, erythema, soreness, pruritus, dysuria, and bleeding. Occasionally, urinary tract or bowel symptoms may be interpreted by a child as vulvar or vaginal complaints. vulvovaginal infections may be caused by specific infections originated from: respiratory ,enteric pathogens, or sexually acquired organisms as a result of sexual abuse [3]

Non- specific vulvovaginitis is responsible for 25 to 75 percent of vulvovaginitis in prepubertal girls. There are a number of potential factors in children that increase their risk of vulvovaginitis: lack of labial development, unestrogenized thin mucosa, more alkaline pH (pH 7) than postmenarchal girls/women, poor hygiene, bubble baths, shampoos, deodorant soaps, obesity, foreign bodies, and choice of clothing (leotards, tights, and blue jeans). Lack of protective hair and labial fat pad and lack of protective lactobacilli promotes infection [2,3].

Improper wiping of the vaginal area after voiding, masturbation, and simply sitting in tights for a few hours may cause erythema, skin breakdown and discomfort in the vulval area. The vulval inflammation may progress and lead to a secondary vaginitis .Skin disorders such as atopic dermatitis, scabies, chicken pox, are other causes of non- specific prepubertal vulvovaginitis [4,5].

Group A Beta-hemolytic streptococcus (GABHS) is not an uncommon cause of vulvovaginitis. It is often accompanied by an anal streptococcal proctitis (which presents as a beefy, red, well demarcated ring the size of a quarter around the anal area). GABHS vulvovaginitis presents with a purulent vaginal discharge

which may simply manifest itself as soiling on the child s panties.. Candida vulvovaginitis is extremely uncommon in the prepubertal child who is no longer wearing diapers. It must be remembered however that some of these children do wear diapers at night only (nocturnal enuresis) until they are well beyond 5 years of age and they may be susceptible to a Candidal vulvovaginitis [1]. The sexually acquired infections seen in the prepubertal child include *N. gonorrhoea*, *Gardnerella vaginalis*, *Trichomonas*, *C. Trachomatis*, *Herpes Simplex* and *Condyloma accuminata*. These are all extremely unusual organisms to find in the prepubertal child and must immediately raise the suspicion of possible sexual abuse [2].

Vaginal foreign bodies must be considered in all cases of recurrent vulvovaginitis. The most common foreign bodies in the vagina are wads of toilet paper (which are not radio-opaque). Pinworm infestations are not infrequently associated with vulvovaginal irritation [6]. Lichen sclerosis is rare in the prepubertal child but has a characteristic white parchment-like epithelium that often appears in a figure of eight pattern around the vagina and anus [7,8].

Patients and Method

A total of 70 cases of pre pubertal girls collected from private clinics, aged 8 months to 9 years at the time period from June 2009 to January 2010. Initial history should include home remedies, prescription creams or other medications that may have already been used .Medical history of eczema, contact dermatitis, other recent upper respiratory, pharyngeal or gastrointestinal infections, and diabetes should also be assessed. The question of sexual abuse should not be overlooked, and when indicated, a review of the social situation should be conducted to record who is involved or

comes in contact with the child on a daily basis [9]. After a complete physical examination, a genital examination can be performed in the frog-leg or knee-chest position, and using a smaller caliber urethral swab is better tolerated than a typical cotton-tipped swab. one swab was rubbed on a glass slide with drop of KOH for direct examination by microscopy for clue cells, pseudohyphae, leukocytes, and bacteria according to the standard laboratory methods [10,11], while the other swab was immediately cultured onto a number of agar plates especially human blood, and Sabauroud's agar plates were incubated aerobically at 37°C for 48 hours and the isolates were identified using standard procedures assessed according to (MacFaddin,, 2000) [12].

The patients with vaginal discharge were especially screened for *Neisseria gonorrhoeae*, *Trichomonas vaginalis* and *Candida* by gram stain and culture.[13,14,15]. Ultrasound and hormonal assay was done for the two patients presented with pruritus vulvae and bleeding.

Results and Discussion

Most cases of vulvovaginitis in the pediatric population are nonspecific in nature ,and have no significant bacterial cause. These cases are most

commonly present with a history of vulvovaginal irritation and erythema for months to years that may have responded to broad-spectrum antibiotics, but then recur. In many cases, the neutral pH of the vagina allows rectal bacteria to overgrow in the vagina and create these symptoms even when there is an attempt at adequate hygiene. These cases are best treated with symptomatic relief with one to two soaks in warm tub water daily and post bath use of a barrier cream such as zinc oxide or another diaper rash ointment. If there is not relief within 48-72 h, or there is a discharge, a specific cause should be ruled out with a culture [12].

Among the seventy patients collected in our study; 20 cases (28.57%) had dysuria in addition to the chief complaint Pruritis vulvae. Regarding the economic state of our patients; 66.7% had high economic state, while the remaining (33.3%) of them were of low state. On the clinical examination we found presence of redness of external genetlia in 48 cases (68.57%), vaginal discharge in 10 cases (14.28%), and vaginal bleeding in two case (2.8%), Vulval and perianal molloscum contagiosum lesion in 8cases (11.4) while vulval and perianal genital warts in 5 cases (7.1%) Table (1).

Table 1 Presentation of patients with Pruritis vulvae in prepubertal age group

Types of clinical features	No. of patients	Percentage (%)
Pruritis	70	100
Redness	48	68.57
Dysurea	20	28.57
Discharge	10	14.28
Perianal and genital Molloscum contagiosum	8	11.4
Genital warts	5	7.1
Vaginal bleeding	2	2.8

Vulvovaginitis caused by specific organisms can be divided into nonsexual and sexually transmitted etiologies. Isolation of the predominant organism is important, and testing for

the presence of gonorrhea and chlamydia should be performed when appropriate. Normal vaginal flora includes mixed aerobes and anaerobes, commonly *Staphylococcus*

epidermidis, diphtheroids, lactobacilli and anaerobic bacteria such as bacteroides. [17] Typically, no treatment is indicated for this mixed picture of commonly occurring organisms. The predominant bacterial flora isolated in cases of vulvovaginitis include *Streptococcus pyogenes*, *Staphylococcus aureus*, *Proteus mirabilis*, *Neisseria meningitidis*, *Streptococcus pneumoniae*, *Enterococci*, *Escherichia coli* and *Gardnerella vaginalis*. Bacterial-associated vaginitis is best treated by antibiotics directed toward the specific organism [18].

In study the two patients presented with pruritus vulvae and bleeding, ultrasound examination and hormonal assay revealed no abnormality, and clinical examination revealed the blood

is menstrual in origin. Microbial pathogens were isolated from culture the vulvas swab specimens of 22 girls (31.4%), while the rest 48 (68.6%) gave negative results. Among the total number of our patients 70 (100%), infection with a single bacterium was identified in 22 cases, while *Candida* spp. were isolated from in 4 cases. The most frequently isolated bacteria were *Streptococcus faecalis* and *Neisseria gonorrhoeae* 6 cases (21.4%), *Escherichia coli* 4 cases (14.3%), *Staphylococcus aureus* 3 cases (10.7%), *Streptococcus agalactiae* and *Streptococcus pyogenes* 2 cases (7.1%) for each, *Proteus mirabilis* 1 case (3.6%). And *Candida* 4 cases (14.3%). (Table 2).

Table 2 Shows types of bacterial and fungal isolates from patients with pruritus vulvae.

Types of bacteria	Number	Percentage (%)
<i>Streptococcus faecalis</i>	6	21.4
<i>Neisseria gonorrhoeae</i>	6	21.4
<i>Escherichia coli</i>	4	14.3
<i>Staphylococcus aureus</i>	3	10.7
<i>Streptococcus agalactiae</i>	2	7.1
<i>Streptococcus pyogenes</i>	2	7.1
<i>Proteus mirabilis</i>	1	3.6
<i>Candida</i>	4	14.3
Total	28	100

Candida albicans can be found in healthy patients on the skin, mouth, colon and vaginal mucosa. This fungus is responsible for diaper dermatitis that presents with erythematous skin in the diaper area involving the inguinal folds. There may also be scattered satellite lesions. Fungal vulvovaginitis is much more common in the postadolescent female. In children, candidal infections are uncommon outside of the diaper period. Presenting symptoms of candidiasis includes

pruritus, erythematous mucosa and thick white vaginal discharge. Inflammation may be severe enough to produce erosive changes to the vulva that cause burning with urination. Diagnosis is made by visualization of hyphae or budding yeast on potassium hydroxide preparation. Treatment consists of topical antifungal creams including nystatin, miconazole, clotrimazole or terconazole creams. If erythema is intense, adding a topical hydrocortisone preparation may be

helpful. Children who are immunosuppressed can receive oral fluconazole suspension, via a 4.5mg/kg single dose. [19].

Sexually transmitted infections include *Neisseria gonorrhoea*, *Chlamydia trachomatis* and *Trichomonas vaginalis*. *Trichomonas* is rare in children or adolescents unless they have been sexually abused, as this pathogen generally prefers a vagina exposed to the action of estrogens [20]. Diagnosis is made by wet mount and treated with metronidazole 15 mg/kg/day three-times daily for 7 days. In sexually abused children, the incidence of gono-coccal infections ranges from 5 to 20%, while the incidence of chlamydial infections ranges from 2 to 13% [16]. In our study the family denied any sexual exposure of their children.

In one prospective study evaluating vulvovaginitis in patients 12 months to 12 years of age, infections from streptococcus, particularly *S. pyogenes*, were the most common infection diagnosed [21]. In another study of 80 prepubertal girls with vulvovaginitis, *S.*

pyogenes was the pathogen in 59%, her infection should respond to appropriate oral antibiotic therapy, such as penicillin or ampicillin. Recurrent vulvovaginitis with *S. pyogenes* has been documented from asymptomatic bacterial carriage within the nasopharynx [22,23].

Other studies have shown that the evaluation of constipation should be included as part of the management of vulvovaginitis. Constipation is commonly present in children with vulvovaginitis, and may contribute to vulvar and vaginal colonization of coliform bacteria. Painful vaginitis may also lead to the child withholding bowel movements, which further complicates the problem [24]. When compared with women of childbearing age and menopausal women, the highest occurrence of vaginal Gram-negative bacteria, mainly *E. coli*, was in prepubescent girls [25].

In the direct examination of smears of anal swabs (tape test) we detected the presence of pin worm's ova in 36.4%. On the other hand 63.6% had negative result (Table 3).

Table 3 Number and percentage of patients presented with pin worms ova by tape test

Tape test (No.)	Pin worms ova (positive)	Percentage (%)	Pin worms ova (negative)	Percentage (%)	Total
70	30	42.9	40	57.1	100

Surveys in Canada in the 1960s show a prevalence of pinworms' infestation was found in 40-60% in schoolchildren, and 30% in preschool children [26]. Much more recent surveys in Swedish children have put the figure at about a quarter of children 8-11 [27]. Infection rates start to rise in October and tend to reach a peak in midwinter [28]. Nearly half the parents who report threadworm infection in

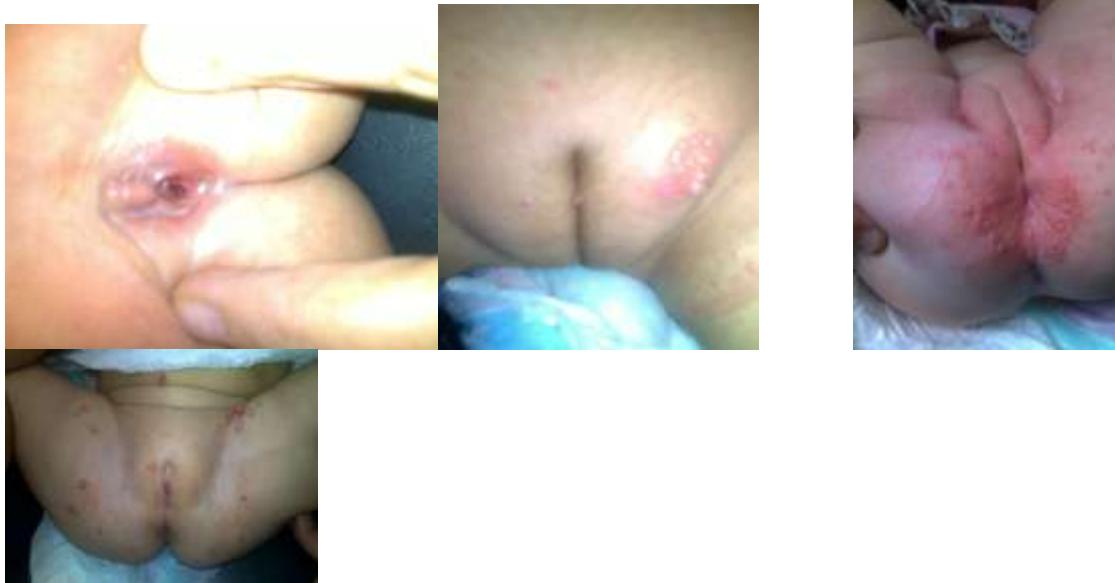their child report that the infection returns in the same year [29].

The isolation of *N gonorrhoeae* from a prepubertal child is probably the most useful indicator of sexual abuse or activity. It has generally been recommended that all children suspected of being sexually abused have cultures obtained from genitals, rectum, and pharynx [6]. *Condylomata cumanata* have been reported in 1-2% of abused children and 50% to 75% of

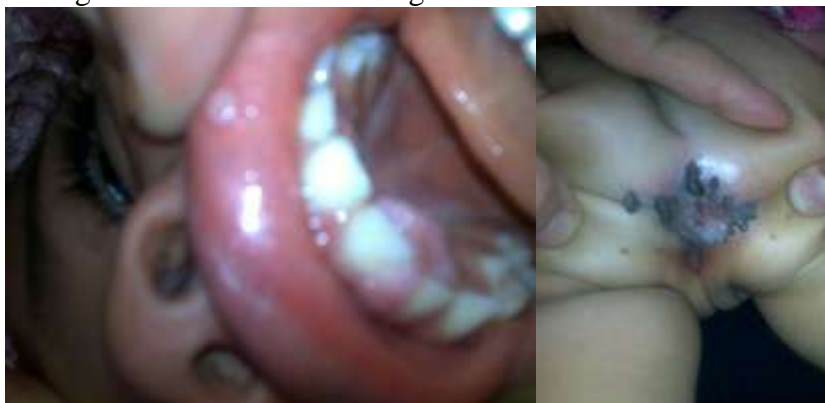cases of genital warts in children reported in the literature appear to be the result of abuse. Like *C trachomatis*, HPV can be acquired perinatally, leading to juvenile laryngeal papillomatosis and genital warts; however, data on the risk of transmission are limited. There is a large asymptomatic reservoir, Whilst of those infected with genital HPV it is estimated that only a "small percentage" (between 1% and 5%)

develop genital warts, those infected can still transmit the virus[6]. Molluscum contagiosum is a disease caused by a poxvirus of the Molluscipox virus genus that produces a benign self-limited papular eruption of multiple umbilicated cutaneous tumors. Less than 5% of the children in the United States are believed to be infected [30].

Pictures for collected cases



Vaginal discharge and erythema genital Molluscum contagiosum perianal Molluscum contagiosum Molluscum contagiosum



This patient has oral, genital and perianal warts

Conclusion

The gynecological problems encountered in children and adolescents are often both medically and psychologically complex and thus require a highly skilled and coherent

approach. There is a large spectrum of diagnoses that cause vulvovaginitis. Careful history and examination should be performed to rule out vaginitis from sexual abuse, or from chemical or dermatologic causes. Vaginitis from

specific organisms can be treated with appropriate antibiotics, and in persistent cases an examination under anesthesia is indicated to rule out the presence of a foreign body or anatomic cause of the discharge.

References

- 1- Paek C. Sandra, Merritt F. Diane and Mallory B. Susan. Pruritis vulvae in prepubertal children. *Jornal of American Academy of Dermatology*, 2001, May, volume 44, Issue 5, 795-802.
- 2- Joishy M. Ashtekar, Jain A. Gonsalves R. Do we need to treat vulvovaginitis in prepubertal girls? *BMJ* 2005; 330: 186.
- 3- Emans SJ: Vulvovaginitis in the child and adolescent. *Pediatrics in Review* 1986, 8: 1, 12 -19.
- 4- Van Eyk N, Allen L, Giesbrecht E, et al. Pediatric vulvovaginal disorders: a diagnostic approach and review of the literature. *J. Obstet Gynaecol Can.* 2009;31(9):850-862.
- 5- Merritt DF. Genital trauma in the pediatric and adolescent female. *Obstet Gynaecol Clin North Am.* 2009; 36 (1): 85-98.
- 6- Hammerschlag R. Margare. Sexually transmitted diseases in sexually abused children: medical and legal implications, In *Sex Transm Inf* 1998; 74: 167-174.
- 7- Piippo S. Lenko H., Vuento R. Vulvar symptoms in Paediatric and adolescent patients . *Acta Paediatr* .200;89:431.
- 8- Loening-Bauecke V. Lichen sclerosus et atrophicus in children. *Am J Dis Child* 1991;145:1058-1061.
- 9- Farrington PF. Pediatric vulvovaginitis. *Clin. Obstet. Gynecol.* 40(1), 135-140 (1997).
- 10- Emans SJ. Vulvovaginal problems in the prepubertal child. In: *Pediatric and Adolescent Gynecology (Fifth Edition)*. Emans SJ, Laufer MR, Goldstein DP (Eds). Lippincott Williams and Wilkins, PA. USA, 83-103 (2005).
- 11- Smith YR, Berman DR, Quint EH. Premarchal vaginal discharge: findings of procedures to rule out foreign bodies. *Pediatr. Adolesc. Gynecol.* 13, 227-230. (2002).
- 12- Matytsina LA., Kuznetsova YI. Vaginal biocoenosis in prepubertal and adolescent girls. In: Chayka V., Matytsina L., eds. *Actual problems of rehabilitation of reproductive health*. Donetsk: Lebed, 2004: 116.
- 13- Kuznetsova Y, Zeltonozenko L. Role of bacterioscopic investigation in diagnostic inflammatory diseases of genitals in girl and adolescent girl. In: Chayka V, Matytsina L, eds. *Actual problem of rehabilitation of reproductive health*. Donetsk: Lebed, 2004: 115-117.
- 14- Siegel R, Schubert C, Myers P, Shapiro R. The prevalence of sexually transmitted diseases in children and adolescents evaluated for sexual abuse in Cincinnati: rationale for limited STD testing in prepubertal girls. *Pediatrics* 1995;96:1090-1094.
- 15- Palusci VJ, McHugh MT. Abuse in the child and adolescent. In: DE Greydanus, DR Patel, HD Pratt, eds. *Behavioral Pediatrics*, 2nd ed. NY: iUniverse Publishers, 2006: 769-811.
- 16- Gerstner GJ, Grungerger W, Boschitsch E, Rotter M. Vaginal organisms in prepubertal children with and without vulvovaginitis. *Arch. Gynecol.* 231, 247-252 (1982). 30(3), 653-661 (1987).
- 17- Sanfilippo JS, Wakim NG. Bleeding and vulvovaginitis in the pediatric age group. *Clin. Obstet. Gynecol.* 30(3), 653-661 (1987).
- 18- Caputo RV. Fungal infections in children. *Dermatol. Clin.* 4(1), 137-149 (1986).
- 19- Deligeoroglou E, Salakos N, Makrakis E, Chassiakos D, Hassan EA, Christopoulos P. Infections of the lower female genital tract during childhood and adolescence. *Clin. Exp. Obstet. Gynecol.* 31(3), 175-178 (2004).
- 20- Tibaldi C, Cappello N, Latino

- MA, Masuelli G, Marini S, Benedetto C. Vaginal and endocervical microorganisms in symptomatic and asymptomatic non-pregnant females: risk factors and rates of occurrence. *Clin. Microbiol. Infect.* 15(7), 670-679 (2009).
- 21- Shapiro RA, Schubert CJ, Siegel RM. *Neisseria gonorrhoea* infections in girls younger than 12 years of age evaluated for vaginitis. *Pediatrics* 104(6), e72 (1999).
- 22- Heymann W. Streptococcal vulvovaginitis. *J. Am. Acad. Dermatol.* 61, 94-95 (2009).
- 23- Hansen MT, Sanchez VT, Eyster K, Hansen KA. *Streptococcus pyogenes* pharyngeal colonization resulting in recurrent prepubertal vulvovaginitis. *J. Pediatr. Gynecol.* 20, 315-317 (2007).
- 24- Yerkes EB. Urologic issues in the pediatric and adolescent gynecology patient. *Obstet. Gynecol. Clin. North Am.* 36, 69-84 (2009).
- 25- Tibaldi C, Cappello N, Latino MA, Masuelli G, Marini S, Benedetto C. Vaginal and endocervical microorganisms in symptomatic and asymptomatic non-pregnant females: risk factors and rates of occurrence. *Clin. Microbiol. Infect.* 15(7), 670-679 (2009).
- 26- Royer A, Berdnikoff K. Pinworm infestation in children: the problem and its treatment. *Can Med Ass J* 1962;86:60-5.
- 27- Herrström P, Friström A, Karlsson A, Högstedt B. Enterobius vermicularis and finger sucking in young Swedish children. *Scand J Prim Health Care* 1997;15:146-48.
- 28- Tanowitz HB, Weiss LM., Wittner M. Diagnosis and treatment of common intestinal helminths. II: common intestinal nematodes. *The Gastroenterologist* 1994; 2: 39 -49.
- 29- Ibarra J. (1989a) Towards a viable approach to the thread-worm problem. *Health at School* 1989; 5:54 -7.
- 30- Schwartz JJ, Myskowski PL: Molluscum contagiosum in patients with human immunodeficiency virus infection. *J Am Acad Dermatol* 1992;27:583.