

DOI: <http://doi.org/10.32792/utq.jceps.10.01.01>

Effect of Monosodium Glutamate (MSG) On Tissue and Function of Liver and Kidney and Body Weight in Male Albino Mice

Zahraa Zuhair Muslim – Kut Technical Institute

Received 17/09/2018, Accepted 9/1/2018 Published 20/1/2020



This work is licensed under a [Creative Commons Attribution 4.0 International License](https://creativecommons.org/licenses/by/4.0/).

Abstract:

Monosodium glutamate is wider used for additive and as a flavor enhancer. This study aimed to evaluate the effect of MSG on liver and kidneys of albino mice by measuring of biochemical parameter (ALT, AST, Urea and Creatinine) , (body , liver and kidney) weight were measured in this study and histological examination of liver and kidneys tissues, twenty albino mice were used in this present which randomly divided in to two group, the experimental group (10 mice) received MSG 100 mg /kg daily for 30 days, the results showed significance increase in the body weight in MSG treated group compared to the control group, MSG cause increases in liver and kidney weight in treated group compared to the control group. The results also showed significant increase in ALT and AST in treated group compared to the control group, also the urea and creatinine increased in experimental group compared to control group. The histological examination of liver tissues showed mild inflammation of portal area, necrosis in the hepatocytes, abnormal hepatic parenchyma architecture, congested hepatic vein and dilated central hepatic vein, while the, histological examination of kidney tissues shows hydropic degeneration of tubular cells of the kidney dilated tubules of kidney hyalinization and hyaline cast of renal tubules, interstitial mononuclear” inflammatory cells and partial sclerosis of glomerulus.

Keywords: Monosodium glutamate, liver, kidneys, urea, creatinine.

Introduction:

Monosodium glutamate (MSG) also known as Ajinomoto (**Eweka et al., 2011**). MSG is the sodium salt of glutamic acid, a non-essential amino acid, found in some foods like tomatoes, milk and cheese and produced in the human body in small amounts (**Walker and Lupien 2000**). It is found naturally in many peptides and proteins of most tissues. Monosodium glutamate plays an important role in the metabolism of human body (**Schaumburg et al., 1969**). Monosodium glutamate differ other known four classic tastes of salt, bitter, sweet and sour, it enhances a complex flavors of vegetable and meet and is commonly used in Chinese and Japanese foods and is commercially used worldwide in many types of foods (**Rogers et al., 1990**). Monosodium glutamate is a stable colorless in solid form that is degraded by strong oxidizing agents. MSG also stimuluses appetite and promotes body weight gain (**P. Johnson 1995**).

Liver is the largest gland in the mammalian body, the liver cell has metabolic functions that manage very important processes such as detoxification, deamination, transamination, removal of ammonia from the body by synthesis of urea, biosynthesis of the non-essential amino acids and plasma

proteins, glycogenesis, glycogenolysis, gluconeogenesis, synthesis of lipoproteins, phospholipids and cholesterol (D. Nelson and M. Cox 2000). Hepatocytes also store the iron in the form of ferritin as well as store vitamins A, B12 and D (A. Go Wenlock 2000). There are several enzymes that can evaluate hepatic state such as alanine amino transferase (ALT) and aspartate amino transferase (AST) (C. Burtis and E. Ashwood 1999; L. Stryer 1995).

The Kidneys are paired organs situated in the posterior abdominal wall, their major functions include the elimination of toxic metabolites and waste products out of the blood. They also play an essential role in the fluid and electrolytes balance in the mammalian body. Routine testing of the urine (urinalysis) and measurement of blood urea and serum creatinine can give good idea about the functions of the kidney (R. Montgomery *et al.*, 1990; Garattiini S 2000). Monosodium glutamate is metabolized in liver and the kidney play a central role in its elimination (Adrienne 1999).

MSG could produce symptoms such as weakness, numbness, sweating, flushing, headaches and dizziness. In addition, ingestion of MSG has been found to cause or exacerbate asthma and atopic dermatitis (Eweka and Adjene 2007). Monosodium glutamate causes retinal degeneration, endocrine diseases, stroke, addiction, epilepsy, neuropathic pain, anxiety, schizophrenia and depression, MSG can also cause Alzheimer's disease, Parkinson's disease and other neurological disorders (Singh and Ahluwalia 2003; A. Leung and S. Foster 1996). Chinese restaurant syndrome is a constellation of symptoms including chest tightness, headache and flushing of face, the syndrome was firstly described in 1968 and caused by eating food that had been treated with MSG (Schaumburg *et al.*, 1969). The current research work is carried out to study the histological and biochemical changes in the liver and kidneys of adult mice treated with monosodium glutamate (100 mg / kg B.W)

1. Materials and methods:

a. Animals:

A twenty albino mice were used in the current study, their weight ranged from 20-25 gm. The animals were housed in cages in animal house of Al- Kut technical institute and left it 2 weeks for adapt before investigation. Animals were kept at a suitable temperature 22 ± 2 C and natural photoperiod state and has free access to food and water during the course of the experiment.

b. Chemical:

The chemical used monosodium glutamate (C₅H₉NO₄Na) purity 99% NT, it was sold from Baghdad. Other chemical were used in an investigation methylene blue, xylene, hematoxylin, eosin, paraffin, formalin, Canada balsam, normal saline and absolute alcohol.

c. Experimental design:

The investigated lasted for 30 days. The mice are divided randomly in to two groups:

Group I: The control group (10 mice) in which animals were only administrated distilled water along with regular diet.

Group II: The experimental group (10 mice) in which animals were administrated orally the therapeutic dose of monosodium glutamate (100 mg / kg body weight) daily for 30 days.

d. Body weight:

e. The body weight of animals is taken at the beginning of experiment and in the end of treatment by using electrical balance. While liver and kidney weight which taken at the end of experiment after the animals dissected from control and treated groups by using electrical balance.

f. Blood collection:

At the end of treatment period the animals were dissected and the blood collected from heart directionally and then collected in jelly tube. Serum was separated by centrifugation at 3000 rpm for 10 min and stored -20 C° to be used for measurement blood urea, serum creatinine, serum alanine aminotransferase (ALT) and aspartate aminotransferase (AST).

g. Histopathological finding:

After dissection, kidneys and liver were removed immediately and fixed in 10% formal saline. After fixation, kidneys and liver were embedded in paraffin blocks and processed for the preparation of 5 μ thickness sections. These sections were subjected for the following stains; Hematoxylin and Eosin (H&E) as described by **Wilson and Gamble, 2002**.

h. Statistical Analysis

Statistical significance on the dose 25 mg/kg b.wt was taken at P< 0.05 by using SPSS analysis system and were presented as mean + SD (**Dean et al., 2000**).

2. Results:

Table (1) explained the effect of administration of MSG on body weight of albino mice, the result showed a significant increase in body weight of treated animals (32.3 ± 3.83) compared to control group (27.2 ± 2.25) and showed a significant increase in the liver weight of the mice which treated with monosodium glutamate and have means (1.39 ± 0.03), (3.03 ± 0.41) in control and treated group respectively, the result also showed a significant increase in kidney weight which observed in treated group compared to control group and have mean (0.40 ± 0.03), (0.47 ± 0.06) of control and experimental group respectively.

Table (1) show the effect of monosodium glutamate on body weight and liver and kidney weight on male albino mice.

Groups	Body weight (gm)	Liver weight (mg)	Kidney weight (gm)
Group I (control)	27.2 ± 2.25	1.39 ± 0.03	0.40 ± 0.03
Group II	$32.3 \pm 3.83^*$	$3.03 \pm 0.41^*$	$0.47 \pm 0.06^*$

* refer to significant differences groups at level $p < 0.05$

Table (2) showed the effect of monosodium glutamate on urea level that were measured in serum sample. A significant increase in the urea was observed in the MSG-treated group compared to the control group. Urea had activities means of ($43.3 \pm 12.6 - 63.1 \pm 23.5$) U/L in serum of the control and MSG treated mice respectively. Also there was a significant increase in serum creatinine was observed in the MSG-treated group compared to the control group. Creatinine had activities means of ($0.32 \pm 0.08 - 0.49 \pm 0.19$) U/L in serum of the control and MSG treated adult mice respectively (**table 2**).

Table (2) show the effect of monosodium glutamate MSG on blood urea and serum creatinine

Groups	Blood urea (mg/dl)	Serum creatinine (mg/dl)
Group I (control)	43.3 ± 12.6	0.32 ± 0.08
Group II	$63.1 \pm 23.5^*$	$0.49 \pm 0.19^*$

* refer to significant differences between groups at level $p < 0.05$

Table (3) show the effect of monosodium glutamate on activities of ALT enzyme that were measured in serum sample. A significant increase in ALT and AST of treated group compared with control group. Alanine aminotransferase (ALT) had activities means of (33.5 ± 9.6 - 57.3 ± 24.4) U/L in serum of the control and MSG treated adult mice respectively. While highly significant increases in the serum aspartate aminotransferase was detected in the MSG-treated group compared to the control group. Aspartate aminotransferase (AST) had activities means of (60.0 ± 7.02 - 374.9 ± 103) U/L in serum of the control and MSG treated adult mice respectively (**table 3**).

Table (3) show effect of monosodium glutamate MSG on serum alanine aminotransferase (ALT)

Groups	ALT	AST
Group I (control)	33.5 ± 9.6	60.0 ± 7.02
Group II	$57.3 \pm 24.4^*$	$374.9 \pm 103^{**}$

and serum aspartate aminotransferase (AST)

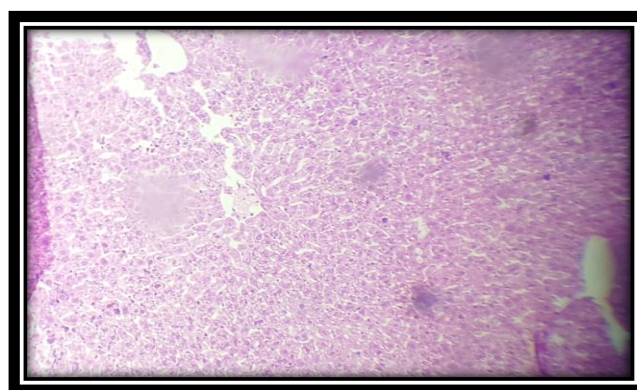
* refer to significant differences between groups at level $p < 0.05$

**refer to highly significant differences between groups at level $p < 0.05$

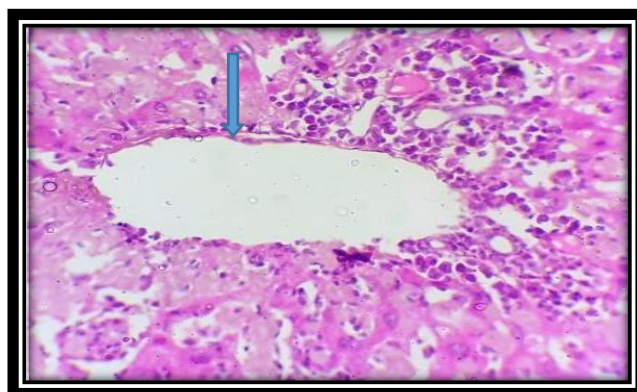
1. Histopathological observation:

The histological examination of liver section of the control group showed central vein with normal hepatic cords composed of one layer hepatocytes, in addition to normal appearing portal tract (**picture 1**) while the histological examination of liver of the treated mice with monosodium glutamate (MSG) for 30 days, showed mild inflammation of portal area, necrosis in the hepatocytes, abnormal hepatic parenchyma architecture, congested hepatic vein, dilated central hepatic vein, (**pictures 2,3,4,5,6**).

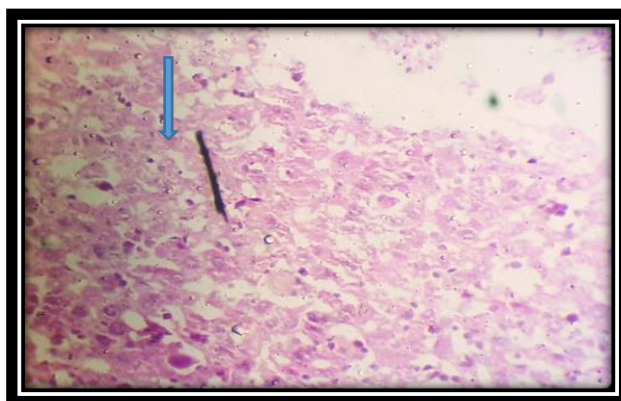
The kidneys of mice of control group showed normal histological picture while histological observation of kidneys of the mice after 30 days of treatment showed hydropic degeneration of tubular cells of the kidney, dilated tubules of kidney, interstitial mononuclear inflammatory cells, partial sclerosis of glomerulus, degenerative changes of renal tubules and hyalinization and hyaline cast of renal tubules (**7, 8, 9, 10, 11, 12, 13**).



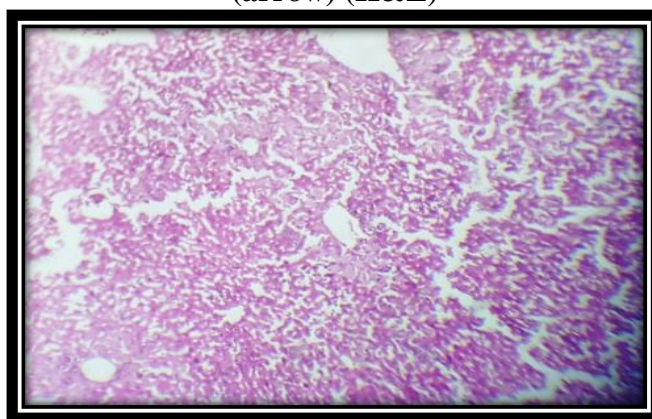
**picture (1): photomicrograph of liver section of control group show central vein with normal hepatic cords composed of one layer hepatocytes, in addition to normal appearing portal tract....
10x10 (H&E)**



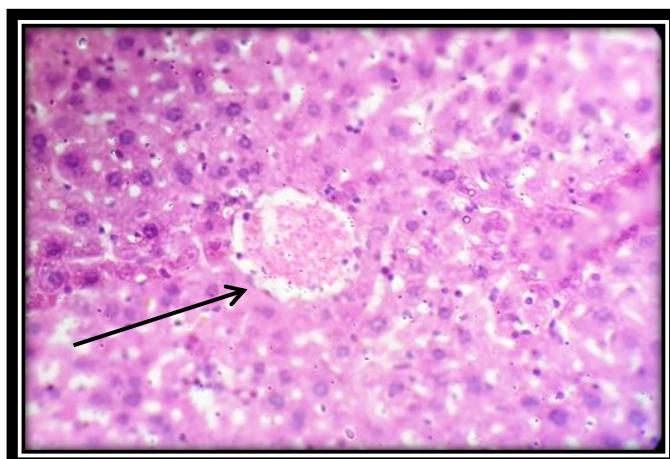
picture (2): photomicrograph of liver section of experimental group treated with 100 mg/kg body weight of MSG for 30 days (40x10) show mild inflammation of portal area (H&E).



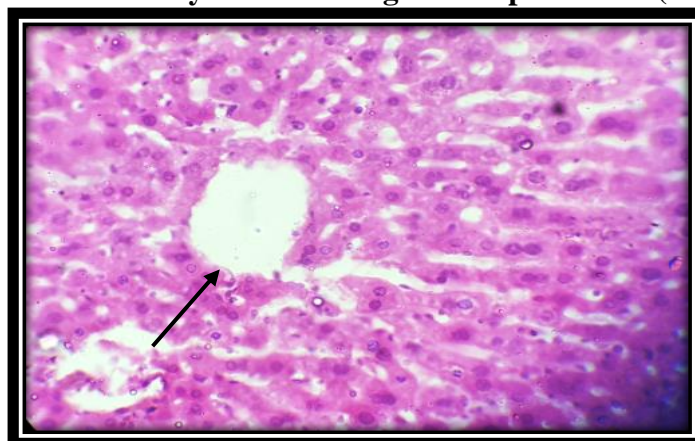
picture (3): photomicrograph of liver section of experimental group treated with 100 mg/kg body weight of MSG for 30 days' show necrosis in the hepatocytes in the right side of the picture (arrow) (H&E)



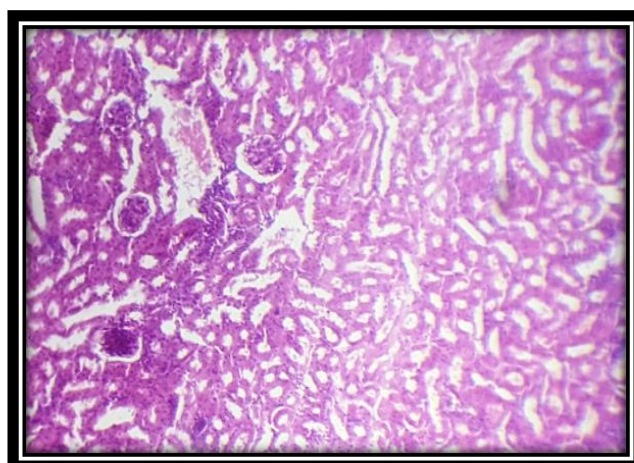
picture (4): photomicrograph of liver section of experimental group treated with 100 mg/kg body weight of MSG for 30 days showed abnormal hepatic parenchyma architecture.10x10 (H&E)



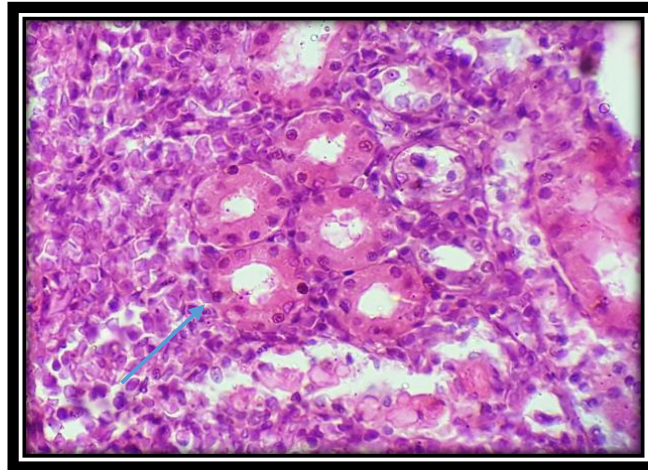
picture (5): photomicrograph of liver section of experimental group treated with 100 mg/kg body weight of MSG for 30 days showed congested hepatic vein. (40x10) (H&E)



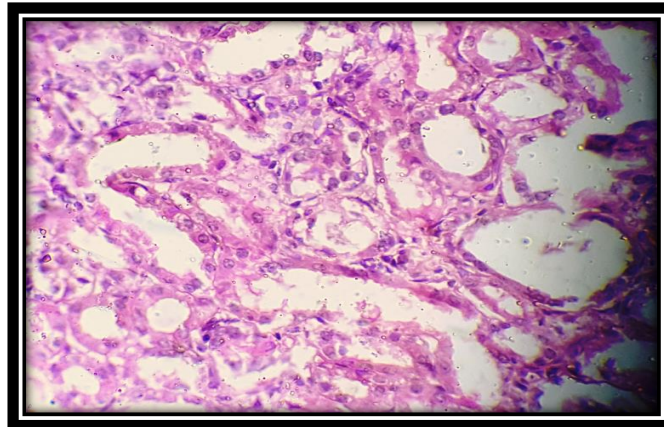
Picture (6): photomicrograph of liver section of experimental group treated with 100 mg/kg body weight of MSG for 30 days' showed dilated central hepatic vein...(40x10) (H&E)



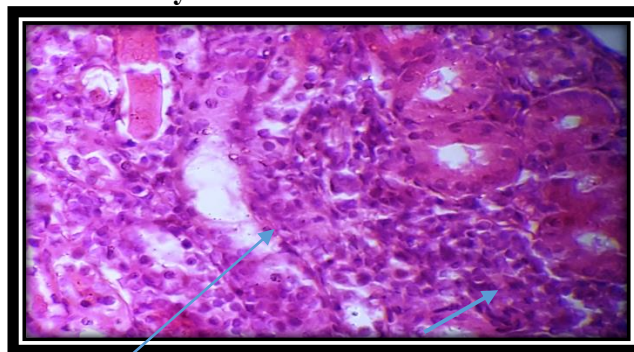
Picture (7): photomicrograph of kidneys section of control group showed normal appearing glomeruli and tubules of the kidney...(4x10) (H&E)



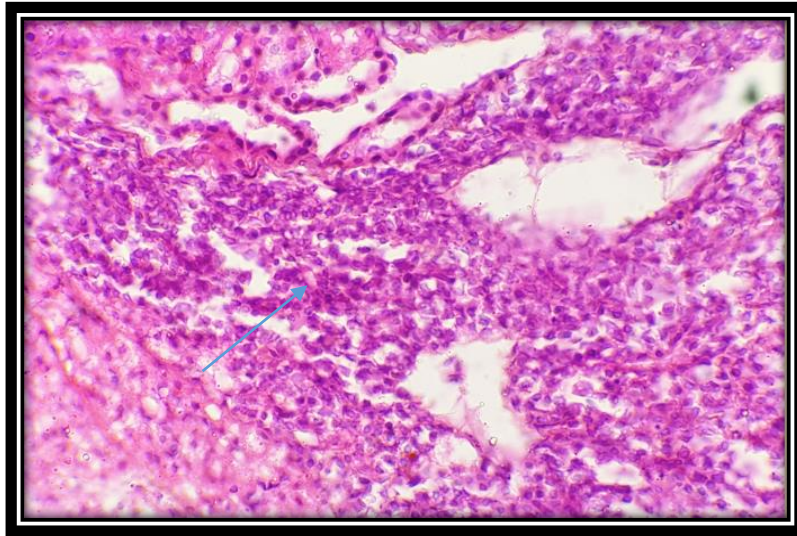
Picture (8): photomicrograph of kidney section of experimental group treated with 100 mg/kg body weight of MSG for 30 days showed hydropic degeneration of tubular cells of the kidney (40x10) (H&E)



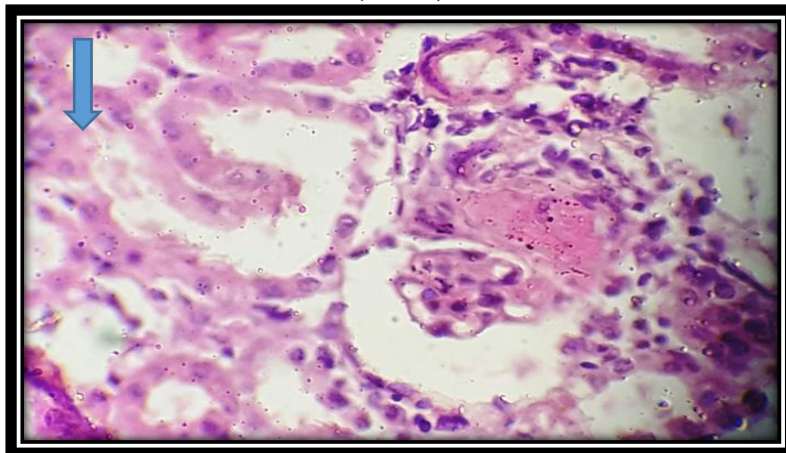
Picture (9) photomicrograph of kidney section of experimental group treated with 100 mg/kg body weight of MSG for 30 days showed dilated tubules of kidney...(40x10) (H&E)



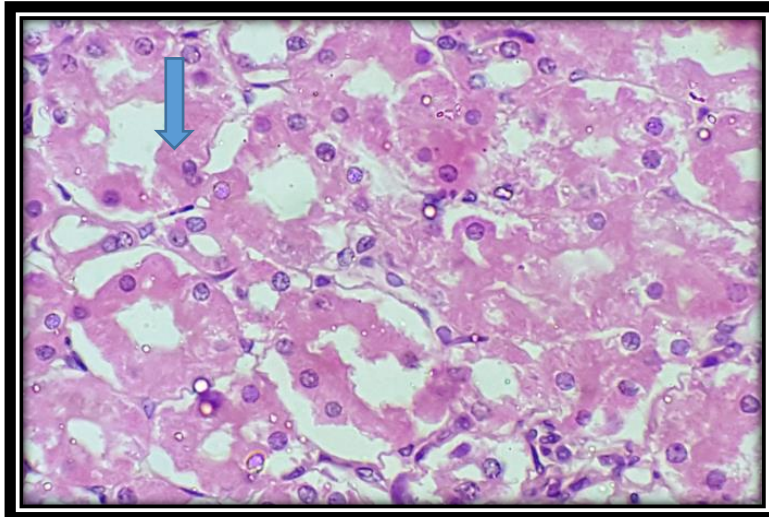
Picture (10) photomicrograph of kidney section of experimental group treated with 100 mg/kg body weight of MSG for 30 days' showed hyalinization and hyaline cast of renal tubules.... (40x10) (H&E)



Picture (11) photomicrograph of kidney section of experimental group treated with 100 mg/kg body weight of MSG for 30 days showed interstitial mononuclear inflammatory cells...(40x10) (H&E)



Picture (12) photomicrograph of kidney section of experimental group treated with 100 mg/kg body weight of MSG for 30 days showed partial sclerosis of glomerulus (arrow) (40x10) (H&E)



Picture (13) photomicrograph of kidney section of experimental group treated with 100 mg/kg body weight of MSG for 30 days showed degenerative changes of renal tubules (40x10) (H&E)

3. Discussion:

The results showed significant increase in the body weight which observed in treated group compared with control group, MSG intake could induce an increase in energy intake (**Bergen 1998**) which could lead to obesity (**S. Mozes et al., 2004**) or alter the levels of carbohydrates, lipids and proteins in rats (**Y. S. Diniz et al., 2004**). Our results agree with the previous work of **Oluba et al., 2011**, who find the constipation of monosodium glutamate increases body weight gain.

Our results show significant increase in the weight of liver and kidney of treatment group compared to the control group, thus attributed to the increase in activity on inflammatory agent that have results to inflammation of liver and kidney tissues (**J. S. Park et al., 2000.**)

The results of this study is consistent with a study showed hepatic impairment and elevated liver enzymes in rats after MSG administration for 14 days (**Tawfik, and Al-Badr, 2012**). The results were also consistent with other studies revealed increased level of ALT in MSG- treated rats with possibility of oxidative stress induced liver injury (**E. O. Farombi and O. O. Onyema 2006**). The increases of the levels of serum ALT and AST observed in the monosodium glutamate treated mice might be indicator of liver damage (**Tawfik, and Al-Badr, 2012; M. Al-Mamary 2002**). The possible mechanism behind the increase of ALT and AST could be due to damage of liver cells with accompanying release of ALT and AST enzymes because of overload of ammonium ions that occurs due to elevated level of glutamate after MSG intake (**Tawfik, and Al-Badr, 2012**). Ammonium ion overloads can also trigger the formation of oxygen free radicals, which react with poly-unsaturated fatty acids of the cell membrane resulting in impairment of plasma and mitochondrial membranes and thus leakage of liver enzymes like ALT and AST (**Poli et al., 1990**).

The present study showed significant elevation in blood urea and serum creatinine when compared with the control group. These increases in renal indices might be resulted from changes in the tubular reabsorption threshold, degenerative changes of renal tubules, renal blood flow and glomerular filtration rate (**El-Sheikh and Khali 2011**). Our results are consistent with (**Tawfik, and Al-Badr, 2012**), who found elevated blood urea and serum creatinine in monosodium glutamate in treated rats. Exposure to MSG can cause an adverse effect on the kidney function which might as a result of oxidative stress caused by MSG on the renal tissue.

Microscopic examination of the liver specimen of the mice of MSG group after 30 days of treatment showed variable pathological changes including mild inflammation of portal area (picture 2), this finding was also reported (**Bhattacharya et al., 2010**) who found infiltration of inflammatory cells in portal area in the liver of albino mice treated with MSG. Our study showed necrosis in hepatocyte (picture 3), this is consistent with (**Kumbhare et al., 2015**) who found focal necrosis of the hepatic cells in albino rats treated with monosodium glutamate for 45 days. Other studies also showed similar finding (**Hanaa, Saleh 2006; Waer 2006**), we also found in this study abnormal hepatic parenchyma architecture (picture 4) which is in agreement with (**El-Meghawry et al 2013**) who reported severe architectural distortions of the liver cells of MSG-treated rats for 45 days. Distortion of hepatic architecture were also reported by other studies (**Hanaa, Saleh 2006; Waer 2006**), The effects of MSG on the hepatic tissue also resulted in congested hepatic vein (picture 5) and dilated central hepatic vein (picture 6). Similar results were also reported by others (**Eweka et al 2011; El-Sheikh and Khali 2011; Bhattacharya et al 2010**) Regarding the histopathological changes in renal tissue, the present study revealed normal histological picture of the control group (picture 7), while in MSG-treated mice, the study showed variable histopathologic changes including degenerative changes of renal convoluted tubules (picture 8,13) dilated convoluted tubules (picture 9), hyalinization and hyaline cast of renal tubules (picture 10). These observations were similar

to these reported by **Amal et al., 2012**. They also found marked degenerative changes on many renal glomeruli and tubules which is explained by the toxic effects of MSG on renal tubules **Tisher and Brenner (1989)**. **Amod Sharma (2013)** found the hyaline casts with the flattening of the tubular epithelial cells in both MSG-treated and control groups. The finding of moderate mixed inflammatory cell infiltrate in the renal tissue (picture 11) reported by this study was also reported by other studies (**Abd El-Mawla and Osman 2011; Abass and Abd El-Haleem 2011**) that found inflammatory cell infiltration in the renal tissue. This observation indicates that the MSG administration can induce inflammatory process in the kidneys. (picture 12) show partial sclerosis of the glomerulus, this reported with **Thomas et al., (2009); Dixit et al., (2014)**.

REFERENCES:

- A. **Gowenlock, J. McMurray and D. McLauchlan. (1988):** "Var-ley's Practical Clinical Biochemistry," Redwood Burn Ltd., Wiltshire.
- A. **Leung and S. Foster. (1996):** "Encyclopedia of Common Natural Ingredient Used in Food," Drugs and Cosmetics, New York, Wiley, pp. 373-375.
4. **Abass, M.A. and Abd El-Haleem, M. R. (2011):** Evaluation of Monosodium Glutamate Induced Neurotoxicity and Nephrotoxicity in Adult Male Albino Rats, Journal of American Science, 7(8): 264-76.
5. **Abd El-Mawla, A. M. and Osman, H. E. H. (2011):** HPLC analysis and role of the Saudi Arabian propolis in improving the pathological changes of kidney treated with monosodium glutamate. Spatula DD, 1(3): 119-27.
6. **Adrienne, S. (1999):** The Toxicity Safety of MSG A study in suppression of information, Acct. Res., 6(4):259-310.
7. **Amal A. Afeefy Marwa S. Mahmoud and Mona A.A. Arafa. (2012):** Effect of Honey on Monosodium Glutamate Induced Nephrotoxicity (Histological and Electron Microscopic Studies). J Am Sci, 8(1s):146-156]. (ISSN: 1545-1003).
8. **Bhattacharya, T., Bhakta, A. and Ghosh, S.K. (2011):** Long term effect of monosodium glutamate in liver of albino mice after neonatal exposure, Nepal Medical College Journal, 13(1): 11-16.
- B. **Burtis and E. Ashwood. (1999):** "Tietz Textbook of Clinical Chemistry," W. B. Saunders Company, London.
- C. **Nelson and M. Cox. (2000):** "Lehninger Principles of Biochemistry," Worth Publishers, New York.
9. **Dean AG, Dean JA, Coulombier D and Brendel K A., 2000:** Epi-Info (6.1): A word processing data base and statistical program for epidemiology and micro-computer office, Center for disease control, Atlanta Georgia, USA.
10. **Dixit SG, Rani P, Anand A, Khatri K, Chauhan R, Bharihoke V. (2014):** To study the effect of monosodium glutamate on histomorphometry of cortex of kidney in adult albino rats. Ren Fail, 36(2):266-270.
- D. **O. Farombi and O. O. Onyema. (2006).** "Monosodium Glutamate Induced Oxidative Damage and Genotoxicity in Rat: Modulatory Role of Vitamin C, Vitamin E and Quercetin," Human and Experimental Toxicology, Vol. 25, pp. 251-259.
11. **El-Meghawry El-Kenawy, A., Osman, H. E. & Daghestani, M. H. (2013):** The effect of vitamin C administration on monosodium glutamate induced liver injury. An experimental study. Exp. Toxicol. Pathol. 65, 513-521.

12. **El-Sheikh, N.M. Khali, F.A. (2011).** L-Arginine and Lglutamine as immunonutrients and modulating agents for oxidative stress and toxicity induced by sodium nitrite in rats. *Food and Chemic.Toxico. J.* 49: 758–762.
13. **Eweka, A.O. and Adjene, J.O. (2007):** Histological studies of the effects of monosodium glutamate on the medial geniculate body of adult Wister rat, *Electrone. J. Biomed.*, 2: 9-13.
14. **Eweka, A.O., Igbigbi, P.S. and Ucheya, R.E. (2011):** Histochemical Studies of the Effects of Monosodium Glutamate on the Liver of Adult Wistar Rats. *Annals of Medical & Health Sciences Research*, 1, 21-29.
15. **Garattiini S. (2000).** Glutamic acid, twenty years later. *J Nutr*, 130: 9018-9.
16. **H. T. Bergen, T. M. Mizuno and J. Taylor. (1998).** “Hyperphagia and Weight Gain after Gold-Thioglucose and Monosodium Glutamate: Relation to Hypothalamic Neuropeptide,” *Endocrinology*, Vol. 139, No. 11, pp. 4483-4488
17. **Hanaa FW, Saleh E (2006):** The Effect of Monosodium Glutamate (MSG) On Rat Liver and The Ameliorating Effect of Guanidino Ethane Sulfonic acid (GES) (Histological, Histochemical and Electron Microscopy Studies). *The Egyptian Journal of Hospital Medicine.* 24: 524–538.
18. **J. S. Park, M. A. Choi, B. S. Kim, I.S. Han, T. Kurata and R. Yu. (2000).** “Capsaicin Protects against Ethanol-Induced Oxidative Injury in the Gastric Mucosa of Rats,” *Life Science*, Vol. 67, pp. 3087-3093.
19. **Kumbhare, V., Gajbe, U., Singh, B. R., Reddy, A. K. and Shukla, S. (2015):** Histological and Histochemical changes in liver of adult rats treated with monosodium glutamate: A light microscopic study. *International Journal of Pharmacy and Pharmaceutical Sciences*, 4: 898-911.
20. **L. Stryer. (1995).** “Biochemistry,” W.H. Freeman and Company, New York.
21. **M. Al-Mamary, M. Al-Habori, A. M. Al-Aghbari and M. M. Baker. (2002).** “Investigation into the Toxicological Effects of Catha Edulis Leaves: A Short-Term Study in Animals,” *Phytotherapy Research*, Vol. 16, pp. 127-132.
22. **Oluba O M., Onykeke, E C., Idonije B.O. and Eidangbe, G.O. (2011):** Effect of Soy Protein on Monosodium Glutamate (MSG) – induced Obesity in Rats. *asian. J. Pharma. Boil Res* 1 (1): 8-14.
23. **P. Johnson. (1995).** “The Assessment of Hepatic Function and Investigation of Jaundice,” In: W. Marshall and S. Ban-gert, (Eds.), *Clinical Biochemistry: Metabolic and Clinical Aspects*, Churchill Livingstone, New York, pp. 217-236.
24. **Poli, G., Albano, E. and Dianzani, M.U. (1990):** Lipid Peroxidation and Covalent Binding in the Early Functional Impairment of Liver Golgi Apparatus by Carbon Tetrachloride. *Cell Biochemistry and Function*, 8, 1-10.
25. **R. Montgomery, T. Conway and A. Spector. (1990).** “Biochemistry: A Case-Oriented Approach,” The C. V. Mosby Company, St. Louis.
26. **Rogers pp, Blundell JE. Umani and appetite. (1990).** Effect of monosodium glutamate on hunger and food intake in human subjects. *Phsiol Behave.*; 486: 801- 804.
27. **S. Mozes, Z. Sefcikova, L. Lenharde and L. Raek. (2004).** “Obesity and Changes of Alkaline Phosphatase Activity in the Small Intestine of 40-80-Day Old Subjects to Early Postnatal Overfeeding of Monosodium Glutamate,” *Physiological Research*, Vol. 53, pp. 177-186.
28. **Schaumburg HH, Byck R, Gerstl R, Mashman JH. (1969).** Monosodium L-Glutamate: Its pharmacology and role in Chinese restaurant syndrome. *Sci*, 163, 826- 8.
29. **Schaumburg HH, Byck R, Gerstl R, Mashman JH. (1969).** Monosodium L-Glutamate: Its pharmacology and role in Chinese restaurant syndrome. *Sci*, 163: 826- 8.

30. **Sharma A, Prasongwattana V, Cha'on U, Selmi C, Hipkaeo W, Boonnate P, et al. (2013).** Monosodium glutamate (MSG) consumption is associated with urolithiasis and urinary tract obstruction in rats. *PLoS One*, 8(9): e75546. doi: 10.1371/journal.pone.0075546.
31. **Singh, K. and Ahluwalia, P. (2003):** Studies on the effect of Monosodium Glutamate (MSG) administration on some antioxidant enzymes in the arterial tissue of adult male mice, *J. Nutr. Sci. Vitaminol (Tokyo)*, 49: 145.
32. **Tawfik, M.S. and Al-Badr, N. (2012):** Adverse Effects of Monosodium Glutamate on Liver and Kidney Functions in Adult Rats and Potential Protective Effect of Vitamins C and E. *Food and Nutrition Sciences*, 3, 651-659.
33. **Thomas M, Sujatha KS, George S. (2009).** Protective effect of Piper longum Linn. on monosodium glutamate induced oxidative stress in rats. *Indian J Exp Biol*, 47(3):186–192.
34. **Tisher, C. C.; Brenner, B. M. (1989):** Structure and function of the glomerulus. In: *Renal Pathology with Clinical and Functional Correlations*, Philadelphia, J.P. Lippincott, pp. 92–110.
35. **Waer HF, Edress S. (2006):** The effect of monosodium glutamate (MSG) on rat liver and the ameliorating effect of 'guanidino ethane sulfonic acid (GES)' (histological, histochemical and electron microscopy studies). *Egypt J Hosp Med*, 24 :524 -538.
36. **Walker R and Lupien J. (2000):** The safety evaluation of monosodium glutamate *J. Nut.*,130 :1049-1052.
37. **Wilson I and Gamble M., (2002).** The hematoxylin and eosins, In: *Theory and practice of histological techniques*, Bancroft JD and Gamble M (eds.), 5th ed., Churchill Livingstone, Elsevier Science Limited, London, UK, pp. 125-138.
38. **Y. S. Diniz, A. A. Fernando, K. E. Campos, F. Mani, B. D. Ribas and E. L. Novelli. (2004)** "Toxicity of Hyper Caloric Diet and Monosodium Glutamate: Oxidative Stress and Metabolic Shifting in Hepatic Tissue," *Food and Chemical Toxicology*, Vol. 42, pp. 319-325.