


DORSAL BUCCAL MUCOSAL GRAFT URETHROPLASTY OUTCOMES IN FEMALE URETHRAL STRICTURES.

Document Type : Original Article. Doi: <https://doi.org/10.33762/bsurg.2023.137608.1037>

[ERSHAD HUSSAIN GALETI](#) ¹, [Pogula Vedamurthy Reddy](#)², [Gousia Begum Sowdagar](#)³

¹ Senior Registrar, Department of Urology, Royal Stoke University Hospital, Stoke On Trent, ST4 6QG, United Kingdom.

² Professor, Dept of urology, Narayana Medical College, Nellore, India;

³ 3Consultant Anaesthetist, Balaji Hospital, Kurnool, Andhra Pradesh, India.

Corresponding Author [ERSHAD HUSSAIN GALETI](#) (<https://orcid.org/0000-0003-3857-5400>)

Email: ershad.galeti@uhn.nhs.uk

Article ID: BSURG-2301-1037

Receive Date: 03 January 2023

Revise Date: 19 November 2023

Accept Date: 06 December 2023

Publish Date: 30 December 2023

ABSTRACT

BACKGROUND: Female urethral strictures are infrequent, which explains why the literature on female urethral stricture therapies is scarce. We present the results and complications of dorsal buccal mucosa graft urethroplasty in female patients with urethral stricture.

METHODS: Between January 2017 and December 2019, 25 women aged 33 to 65 with urethral stricture disease underwent urethral restoration with a dorsal onlay buccal mucosa transplant. Uroflowmetry (Q max) and micturating cystourethrography were used to diagnose patients. To rule out bladder pathology, a urodynamic examination was performed. Following catheter removal, UFR was performed every three months for one year, then every six months. **RESULTS:** The average age of the patients was 52.48 years. A stricture's average length was 1.9 cm. Before and after surgery, the mean Q max was 6.7 ml/s and 19.6 ml/s, respectively. The majority of UFR patients following catheter removal had a Q max of more than 15ml/hr. After three months of catheter removal, three patients complained of inadequate flow, which was dealt with with urethral dilation twice a week, and their strictures were resolved after six months.

CONCLUSION: The dorsal technique with buccal mucosa transfer allowed us to successfully restore an appropriate urethra in females.

Keywords: Urethral Stricture; Females; Buccal Mucosa; Reconstruction

Introduction:

Female urethral strictures are management in women. Despite the lack of infrequent, which explains why there demonstrated effectiveness, urethral dilatation is is little literature on stricture nevertheless done often in women. In females,

GALETI, E. H., Vedamurthy Reddy, P., Sowdagar, G. Outcomes of dorsal buccal mucosal graft urethroplasty in female urethral strictures. *Basrah Journal of Surgery*, 2023; 29(2):66 -75. doi: 10.33762/bsurg.2023.137608.1037

repeated urethral dilatation and internal urethrotomy cause fibrosis owing to haemorrhage and extravasation¹. Infection, repetitive instrumentation, trauma, radiation for pelvic cancer, and idiopathic are the most prevalent causes of female urethral stricture².

Female urethral stricture has no precise diagnostic criteria due to its uncommon

Methods:

A prospective study was conducted on 25 female patients who had dorsal onlay BMG urethroplasty for urethral stricture. The research was done from January 2017 to December 2019. Cases were taken into the study between the ages of 33 to 65 years with urethral stricture. All patients complained of the poor preoperative flow of urine. At the clinical evaluation, the urethral meatus may appear stenotic or normal. A maximal urine flow rate of less than 10 ml/s and a

occurrence. According to Defreitas et al., females with a detrusor pressure (Pdet) of 25 cm of H₂O and a maximal urine flow rate (Q_{max}) of less than 12 ml/s have obstruction³. We discuss our single-center experience using Buccal mucosal graft for urethroplasty with only a dorsal onlay approach in female urethral stricture repair.

micturating cystourethrogram findings of a narrowed urethra with proximal dilatation are diagnostic criteria (Figure-1).

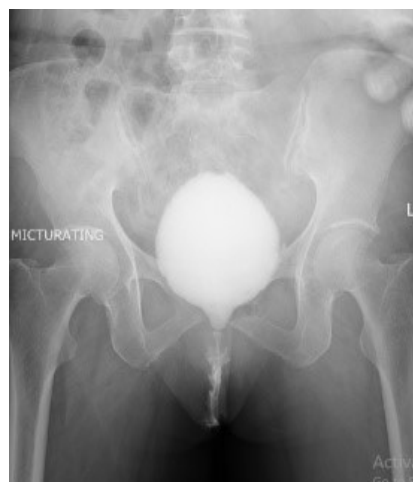

Figure 1 Micturating Cystourethrogram showing stricture urethra

The urodynamic assessment revealed a stable bladder with low flow and low detrusor pressure with Q_{max} less than 10 ml per second and detrusor pressure with Q_{max} greater than 20 cm H₂O.

Length of stricture was assessed by micturating cystourethrography. A number of urethral dilatation procedures had already been performed on 19 of 25 patients (Figure-2). In 18 patients, the cause of the stricture was idiopathic; in five, there had been prior recurrent instrumentation; and in two, there had been a traumatic urethral injury (Figure-3).

Operative Technique:

The procedure involves two parts: Harvesting the buccal graft and the urethral reconstruction. The buccal graft is harvested similar to the manner described by Morey and Mc Anich⁴. BMG is harvested from the inner cheek. A reversed U-shaped incision above the meatus from 3 o'clock to 9 o'clock exposes the dorsal part of the urethra (Figure-2).

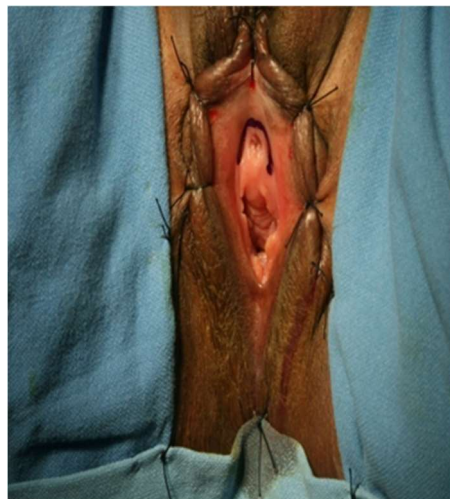


Fig. 4 : Reversed U-shape incision (3'o clock to 9'o clock) over the meatus

The urethra is isolated from the vulvar mucosa. To liberate the whole length of the urethra, a plane is formed between the urethra and the overlying clitoral cavernous tissue. Careful dissection of the

GALETI, E. H., Vedamurthy Reddy, P., Sowdagar, G. Outcomes of dorsal buccal mucosal graft urethroplasty in female urethral strictures. Basrah Journal of Surgery, 2023; 29(2):66 -75. doi: 10.33762/bsurg.2023.137608.1037

urethra was performed. The stricture was incised at 12 o'clock position until 1 cm distal to the bladder neck, and the buccal graft was sutured dorsally (Figure-3)

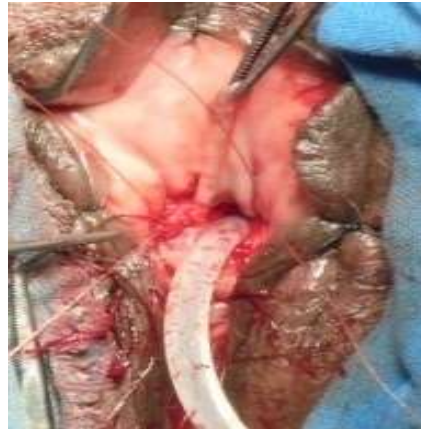

Fig. 3: Operative picture showing dorsal buccal mucosa graft placement.

with 4-0 vicryl interrupted sutures. After that, a BMG graft is used to stitch the urethra's right and left margins, and a 4-0 vicryl suture is used to stitch the urethra back into normal position (Figure 4).

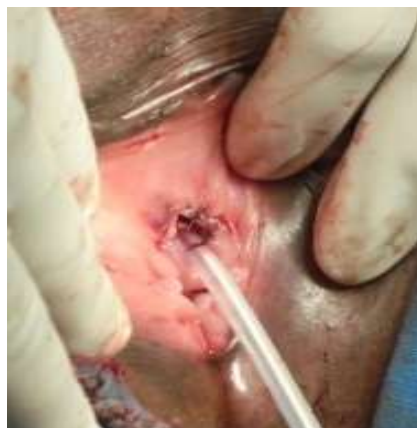

Fig 4: Final post operative appearance after suturing,urethra back to its normal position

To cover the new urethral roof, the expanded dorsal urethra is quilted to the clitoris body. Adequate bladder drainage with a catheter, antibiotic prophylaxis and watertight, non-overlapping and tension-free closure of the urethra was essential.

Follow up protocol: All patients were discharged with Foley’s catheter and were reviewed after 3 weeks. Uroflowmetry was done after catheter removal. Patients were followed up on every three months for the first year, then every six months.

Results:

All 25 patients had strictures at the mid and distal urethra. The patients' average age was 52.48 years (33-65years). The average stricture length measured 1.9 cm (1.2 cm-2.5cm). Mean Q max was 6.7 ml/s preoperatively and 19.6 ml/s postoperatively (Table-I).

Table 1: Descriptive statistics of the study subjects

Statistics	Age in years	Stricture Length in cms	UFR (ml/sec)
Mean	52.4800	1.9040	6.7120
Median	53.0000	2.0000	6.6000
Std. Deviation	8.77553	.40976	1.28722

No patients experienced either discoloration or other signs of graft necrosis. Patients were instructed to resume their regular everyday activities after 4 to 5 days. They had not experienced any major post - operative pain or discharge that may have indicated an infection.

Initially, 3 weeks after surgery, UFR indicated an increase in Qmax. A postoperative Qmax higher than 15 ml/sec was considered successful repair.

In our study, uroflowmetry was done every 3 months for one year and then every 6 months. At a one-year follow-up, 22 patients had Qmax >15 ml/sec with no voiding or storage lower urinary

tract symptoms, with the exception of three patients who had limited flow ($Q_{max} = 8$ ml/sec) and a sense of incomplete voiding (Table II).

Table II : Comparison of mean UFR before and after urethroplasty by paired t test

Variable	Mean	Paired difference		t-value	p-value
		Mean	SD		
UFR3 mths UFR (ml/sec)	20.0000 6.7120	13.28800	2.44068	27.222	.000
UFR 6 mths UFR (ml/sec)	19.6000 6.7120	12.88800	2.34455	27.485	.000
UFR 9 mths UFR (ml/sec)	19.5200 6.7120	12.80800	2.43001	26.354	.000
UFR 12 mths UFR (ml/sec)	18.3600 6.7120	11.64800	4.50898	12.916	.000
UFR 18 mths UFR (ml/sec)	19.3600 6.7120	12.64800	2.43877	25.931	.000
UFR 24 mths UFR (ml/sec)	18.8800 6.7120	12.16800	2.51772	24.165	.000

In all three patients, a cystoscopy revealed stricture immediately proximal to the graft region, which was dilated. Patients were kept on self-calibration with 14fr nelatons catheter on a twice-weekly schedule for six months. Later they were followed up regularly for 1 year and their Q_{max} was more than 15ml/sec suggestive of stabilization of the recurrent narrowing of the urethra proximal to the graft site. Comparing the results of our Dorsal BMG urethroplasty with other studies is mentioned in Table III.

Table III : Comparing the result of Dorsal BMG urethroplasty with other studies

Study Name	Number of cases	Stricture length	Mean follow-up (months)	Success rate
Önol FF et al 2011 ¹¹	2	--	30 months	100%
Migliari R 2006 ⁷	3	--	6 months	100%
Hampson 2019 ¹²	39	2cm	32 months	77%
Kowalik et al.2014 ¹³	4	--	24 months	100%
Goel et al 2014 ¹⁴	8	--	15 months	62.5%
Blaivas et al. 2012 ¹⁵	3	--	25 months	100%
Current study	25	1.5cm	24 months	88%

Discussion:

Female urethral stricture is a disorder that is underdiagnosed⁵. In the past, internal urethrotomies and recurrent urethral dilatations were used as treatments.

Dorsal onlay graft urethroplasty offers solid mechanical support, which allows it to fold on itself, decreasing the chance of neovascularization and the calibre of the reconstructed urethra. Moreover, sacculation at the graft site, which might further compromise the state of the adjacent urethra,

facilitating recurrent stricture disease, is avoided⁶.

The dorsal method for BMG grafts provides the advantages of strong mechanical support and a circulatory bed given by clitoral Cavernosal tissue, reducing the likelihood of diverticula formation. The procedure is actually a physiological repair that diverts the urine away from the vagina and preserves the ventral urethra for future anti-incontinence procedures⁷.

GALETI, E. H., Vedamurthy Reddy, P., Sowdagar, G. Outcomes of dorsal buccal mucosal graft urethroplasty in female urethral strictures. *Basrah Journal of Surgery*, 2023; 29(2):66 -75. doi: 10.33762/bsurg.2023.137608.1037

Berglund et al. published a case series of 2 patients who had ventral buccal graft urethroplasty. The urethra was made visible by a midline anterior vaginal incision. The graft was sutured into place after the stricture was incised along its ventral side. One patient experienced a relapse of symptoms after surgery. She had meatal stenosis distally to the graft repair, which required dilatation⁸. While in our study, there was no incidence of meatal stenosis in any case. Its success is comparable to genital skin grafts or flaps in terms of cure rate but has the advantage of avoiding cosmetic damage to local genital skin⁹. The morbidity from buccal mucosa harvesting is surprisingly minimal, and the scar is well concealed. Buccal mucosa has a thick epithelium with a high elastin fibre content, making it resilient and a thin and highly vascular lamina propria that facilitates inosculation⁹. In addition, it contracts minimally and is relatively resistant to infection.

Theoretically, an incision through the dorsal aspect of the corpus spongiosum should be associated with minor bleeding since this portion of the urethra is the thinnest and least vascular¹⁰.

The dorsal approach to the urethra is causing concern because of a probable injury of the neurovascular bundles to the clitoris. The massive clitoral neurovascular bundles ascend through the ischiopubic ramus to the midline undersurface of the pubic symphysis, where they continue along the clitoral body's cephalad side to the glans. As a result, they are located somewhat distant from the dissection region⁵. The advantage of this urethroplasty is that it leaves the ventral section of the mid urethra intact, allowing for a future anti-incontinence treatment on the mid urethra if necessary.

Conclusion:

A simple and effective method to prevent recurrent painful dilatations in females with mid- and distal urethral stricture is dorsal

onlay buccal graft urethroplasty. To validate the efficacy of this technique, additional research with even more patients and extended follow-up is required.

List Of Abbreviations

BMG-Buccal mucosal graft; UFR-Uroflowmetry; Q max- Maximum urinary flow rate

References

1. SMITH, A. L., FERLISE, V. J., & ROVNER, E. S. (2006). Female urethral strictures: successful management with long-term clean intermittent catheterization after urethral dilatation. *BJU International*, 98(1), 96-99. <https://doi.org/10.1111/j.1464-410X.2006.06206.x>
2. Kapoor, R., Kapoor, D., Kapoor, R., Srivastav, A., Chipde, S., & Singh, M. (2013). Dorsal onlay vaginal graft urethroplasty for female urethral stricture. *Indian Journal of Urology*, 29(2), 124. <https://doi.org/10.4103/0970-1591.114034>.
3. Defreitas, G. A., Zimmern, P. E., Lemack, G. E., & Shariat, S. F. (2004). Refining diagnosis of anatomic female bladder outlet obstruction: comparison of pressure-flow study parameters in clinically obstructed women with those of normal controls. *Urology*, 64(4), 675-679. <https://doi.org/10.1016/j.urology.2004.04.089>.
4. Defreitas, G. A., Zimmern, P. E., Lemack, G. E., & Shariat, S. F. (2004). Refining diagnosis of anatomic female bladder outlet obstruction: comparison of pressure-flow study parameters in clinically obstructed women with those of normal controls. *Urology*, 64(4), 675-679. <https://doi.org/10.1016/j.urology.2004.04.089>.
5. Keegan, K. A., Nanigian, D. K., & Stone, A. R. (2008). Female urethral stricture disease. *Current Urology Reports*, 9(5), 419-423. <https://doi.org/10.1007/s11934-008-0071-7>.
6. Migliari, R., Leone, P., Berdondini, E., De Angelis, M., Barbagli, G., & Palminteri, E. (2006). Dorsal Buccal Mucosa Graft Urethroplasty for Female Urethral Strictures. *Journal of Urology*, 176(4), 1473-1476. <https://doi.org/10.1016/j.juro.2006.06.043>.
7. Migliari, R., Leone, P., Berdondini, E., De Angelis, M., Barbagli, G., & Palminteri, E. (2006b). Dorsal Buccal Mucosa Graft Urethroplasty for Female Urethral Strictures. *Journal of Urology*, 176(4), 1473-1476. <https://doi.org/10.1016/j.juro.2006.06.043>.
8. Berglund, R. K., Vasavada, S., Angermeier, K., & Rackley, R. (2006). Buccal mucosa graft urethroplasty for recurrent stricture of female urethra. *Urology*, 67(5), 1069-1071. <https://doi.org/10.1016/j.urology.2005.12.010>.
9. Baskin LS, Duckett JW. Mucosal grafts in hypospadias and stricture management. *AUA Update Series* 1994;13:270-5..
10. KELLNER, D. S., FRACCHIA, J. A., & ARMENAKAS, N. A. (2004). Ventral Onlay Buccal Mucosal Grafts for Anterior Urethral Strictures: Long-Term Followup. *Journal of Urology*, 171(2), 726-729. <https://doi.org/10.1097/01.ju.0000103500.21743.89>.

GALETI, E. H., Vedamurthy Reddy, P., Sowdagar, G. Outcomes of dorsal buccal mucosal graft urethroplasty in female urethral strictures. *Basrah Journal of Surgery*, 2023; 29(2):66 -75. doi: 10.33762/bsurg.2023.137608.1037

11. Önoel, F. F., Antar, B., Köse, O., Erdem, M. R., & Önoel, I. Y. (2011). Techniques and Results of Urethroplasty for Female Urethral Strictures: Our Experience With 17 Patients. *Urology*, 77(6), 1318-1324. <https://doi.org/10.1016/j.urology.2011.01.017>.

12. Hampson, L. A., Myers, J. B., Vanni, A. J., Virasoro, R., Smith III, T. G., Capiel, L., Chandrapal, J., & Voelzke, B. B. (2019). Dorsal buccal graft urethroplasty in female urethral stricture disease: a multi-center experience. *Translational Andrology and Urology*, 8(S1), S6-S12. <https://doi.org/10.21037/tau.2019.03.02>.

13. Kowalik, C., Stoffel, J. T., Zinman, L., Vanni, A. J., & Buckley, J. C. (2014). Intermediate Outcomes After Female Urethral Reconstruction: Graft vs Flap. *Urology*, 83(5), 1181-1185. <https://doi.org/10.1016/j.urology.2013.12.052>.

14. Goel, A., Paul, S., Dalela, D., Sankhwar, P., Sankhwar, S. N., & Singh, V. (2013). Dorsal onlay buccal mucosal graft urethroplasty in female urethral stricture disease: a single-center experience. *International Urogynecology Journal*, 25(4), 525-530. <https://doi.org/10.1007/s00192-013-2249-x>.

15. Blaivas, J. G., Santos, J. A., Tsui, J. F., Deibert, C. M., Rutman, M. P., Purohit, R. S., & Weiss, J. P. (2012). Management of Urethral Stricture in Women. *Journal of Urology*, 188(5), 1778-1782. <https://doi.org/10.1016/j.juro.2012.07.042>.

Acknowledgements: We extend our sincere thanks to all the patients who participated in the study.

Conflicting interests: No conflict of interest

Funding: None

Informed consent: Written informed consent was obtained from all the patients

Ethical Approval: Approved by the institutional review board committee

Authors Contribution:

1. ERSHAD HUSSAIN GALETI; 2. Pogula Vedamurthy Reddy; 3. Gousia Begum Sowdagar

Concept and design: 2

Data collection and analysis: 1

Responsibility for statistical analysis: 1

Writing the article: 1,3

Critical review: 1,2,3

Final approval of the article: 1,2,3

Each author believes that the manuscript represents honest work and certifies that the article is original, is not under consideration by any other journal, and has not been previously published.

Availability of Data and Material:

The corresponding author is prompt to supply datasets generated during and/or analyzed during the current study on wise request.

This is an open access article under the CC BY 4.0 license: <http://creativecommons.org/licenses/by/4.0/>

Cite this article: GALETI, E. H., Vedamurthy Reddy, P., Sowdagar, G. Outcomes of dorsal buccal mucosal graft urethroplasty in female urethral strictures. *Basrah Journal of Surgery*, 2023; 29(2):66 -75. doi: 10.33762/bsurg.2023.137608.1037
