

# THE LONG TERM EVALUATION OF THE SEXUAL AND VOIDING FUNCTIONS IN ADOLESCENTS WITH THE TUBULARIZED INCISED PLATE URETHROPLASTY FOR DISTAL HYPOSPADIAS AT CHILDHOOD

DOI: [10.33762/bsurg.2023.132158.1014](https://doi.org/10.33762/bsurg.2023.132158.1014)

**Firas Shakir Attar<sup>1\*</sup>, Magid Asgher Mohammed<sup>1,2</sup>, Mohammad Sallama Mohammad<sup>3</sup>**

<sup>1</sup> university of Basrah, college of medicine, Surgery department.

<sup>2</sup>university of Basrah, college of Nursery

<sup>3</sup>Urology division, Basrah Teaching Hospital

Corresponding author

Firas Shakir Attar

Email: [firasshakir97@gmail.com](mailto:firasshakir97@gmail.com)

---

Receive Date: 08 March 2023

Revise Date: 21 June 2023

Accept Date: 28 June 2023

First Publish Date: 29 June 2023

---

## Abstract

Background: hypospadias is a congenital anomaly of the urethra that is seen increasingly in clinical practice. Distal hypospadias is the most common type of this anomaly and a variety of repairs had been used to correct the deformity. The tubularized incised plate urethroplasty (TIP) is one of the widely used techniques for this purpose .

The aim of this study was to evaluate the outcome of TIP repair in adolescents regarding sexual and voiding functions. patients and methods: A retrospective study including 38 male patients aged 15-16 years was done in multicenter from 2003 to 2020.All the patients were having a distal type of hypospadias which was repaired by TIP repair at childhood. The patients were assessed for the presence of complications and for their voiding function. In addition, they were asked about the occurrence of normal ejaculation.

Results: The mean age at surgery was 2.5 years .The study showed that 10 patients (26.3 %) gave a history of ejaculation with masturbation versus 28 (73.7 %) patients who denied the history of ejaculation. The results showed that urethrocutaneous fistula was seen in 4 patients (10.5 %).Three patients (7.9 %) had meatal stenosis, one patient (2.6 %) had urethral stenosis and another one (2.6%) had persistent chordee. Conclusion: Snodgrass (TIP) repair is considered as an appealing surgical technique for repair of distal type of hypospadias which accounts for the majority of hypospadias. It has very good results regarding the outcome of surgery even at the long term period.

---

Keywords: Distal hypospadias, long –term outcome, Snodgrass repair, Tubularized incised plate urethroplasty, Urethrocutaneous fistula

## Introduction

**H**ypospadias is a congenital anomaly of the male urethra with an incidence of 0.005 to 0.003 % of male newborns. This congenital anomaly results from incomplete fusion of the urethral folds and abnormal development of the foreskin with or without chordee<sup>1</sup>. Hypospadias is usually detected when circumcision is attempted during childhood and the repair is usually attempted at early childhood<sup>2</sup>. One of the widely established and applied techniques for the repair of distal type hypospadias is the tubularized incised plate urethroplasty (TIP) .This procedure was first described in 1994 and has been considered for many years as the option of repair for subcoronal and distal penile hypospadias<sup>3</sup>. There is a consensus that TIP repair has a superior cosmetic outcome with a low rate of complications<sup>4</sup>. Repair of hypospadias is usually done early in childhood, however, this repair has a great influence on the urinary and sexual function of the patients in adult life<sup>5</sup>. Literatures have extensively evaluated the short term and long term outcomes of different techniques of hypospadias<sup>6</sup>. When patients with hypospadias which was repaired in childhood grow into adulthood, they may experience delayed issues such as problems with urination, poor cosmetic appearance, psychologic issues, sexual dysfunction, and infertility<sup>7</sup>. Since the TIP repair is widely used for distal hypospadias repair, it seems that evaluating the long term outcome of this procedure is an interesting subject.

The aim of this study is to evaluate the long term results of TIP repair for distal hypospadias.

## Patients and methods

A retrospective cohort based analytical study, which was conducted on a group of patients in multi centers in Basrah province from 2003 to 2020. The surgery for the patients were done by five surgeons.

## Study population

The record data of adult young patients who underwent TIP repair during childhood were reviewed and assessed for different variables .Only patients who had undergone single stage TIP repair for distal hypospadias were included in the study. Patients with a history of proximal hypospadias or a report that documented the use of another procedure for the repair like Mathieu or MAGPI were excluded from the study. Also patients who were not followed up into adolescent period were excluded. The total number of patients involved in the study was 120 patients .The challenging point was the retrieval of the data and records for the patients who were having the surgery at childhood .This was done by extensive and thorough review to the hospital records that retrieved the name and address of the patients with their phones numbers .By contacting them, it was possible to see 65 patients .The remaining patients were followed retrospectively after being evaluated for other complains at adolescent like voiding difficulties after making sure that they had TIP repair at their childhood through their records.

## Outcome variables

The main outcome of this study was to assess the presence of long term complications of TIP repair including meatal stenosis, urethrocutaneous fistulas, urethral stricture and persistent chordee .In addition, assessment of the voiding and sexual functions were also performed. The sexual function of the

patients was assessed by asking about a history of ejaculation, no one of the patients in the studied cohort was married at time of performing the study. The voiding function was assessed by doing uroflowmetry for all patients and measurement of post-void residual urine volume by suprapubic ultrasound examination. If there was evidence suggestive of the presence of urethral

### Results

The study included 120 patients .The age of the patients was 15 years in 74 (61.7 %) patients and 16 years in 46 (38.3%).The age of the patients at time of surgery was ranging from one to four years (mean 2.5 year  $\pm$  0.5) [Table 1].During questioning about sexual

stricture like voiding difficulty or weak urine stream, then an urethrogram was performed.

### Statistical analysis

The data were analyzed in SPSS software (version 24) .Qualitative data were presented as frequencies and percentages, while quantitative data were displaced as mean  $\pm$  standard deviation.

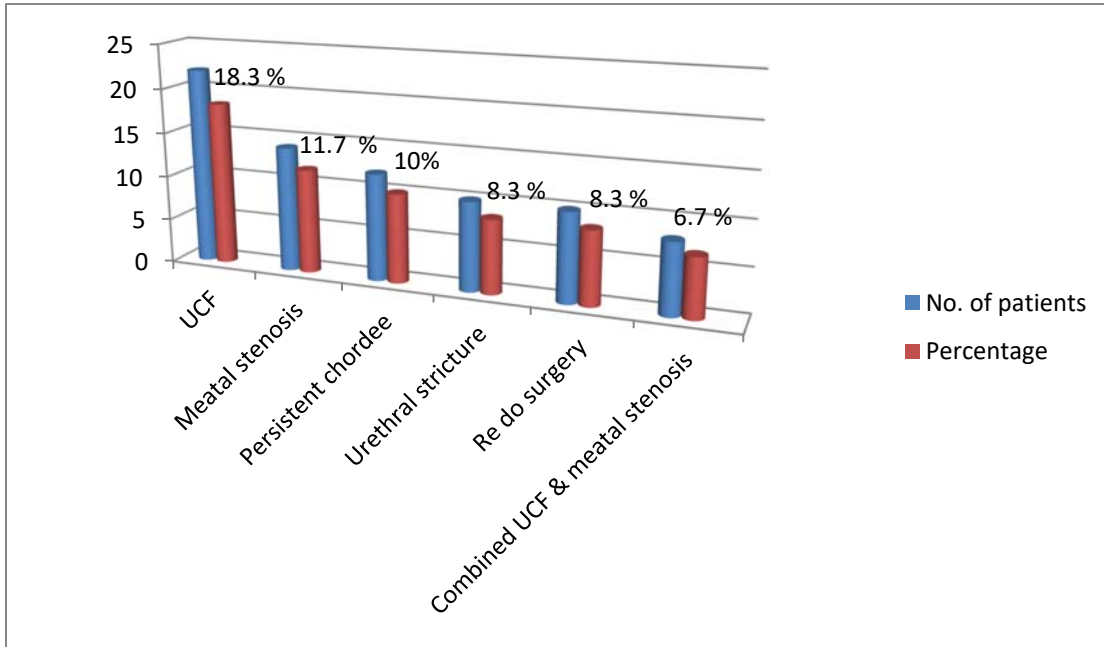
activity, 25 patients (20.8 %) gave a history of ejaculation with masturbation while 95 (79.2 %) patients denied any ejaculation. All the patients with a history of ejaculation reported the normal emission of the semen Table I.

**Table I: Characters of the patients**

Age	No. (%)
15 years	74 (61.7 %)
16 years	46 (38.3 %)
Age at surgery	1- 4 years ( mean 2.5 year $\pm$ 0.5 )
History of ejaculation	Yes 25 (20.8 %)
	No 95 (79.2 %)

Searching for the presence of complications in patients revealed that 58 patients (48.3 %) had some form of complications .Urethrocutaneous fistula was seen in 22 patients (18.3 %) ,14 patients (11.7 %) had meatal stenosis, 8 patients ( 6.7% ) had combined urethrocutaneous fistula and meatal

stenosis , 10 patients (8.3 %) had urethral stenosis and 12 patients (10 %) had persistent chordee Graph 1 .Among the patients with urethrocutaneous fistula , 10 patients (8.3 %) had a history of redo surgery which was done at age of four years that failed to repair the fistula Graph 1.



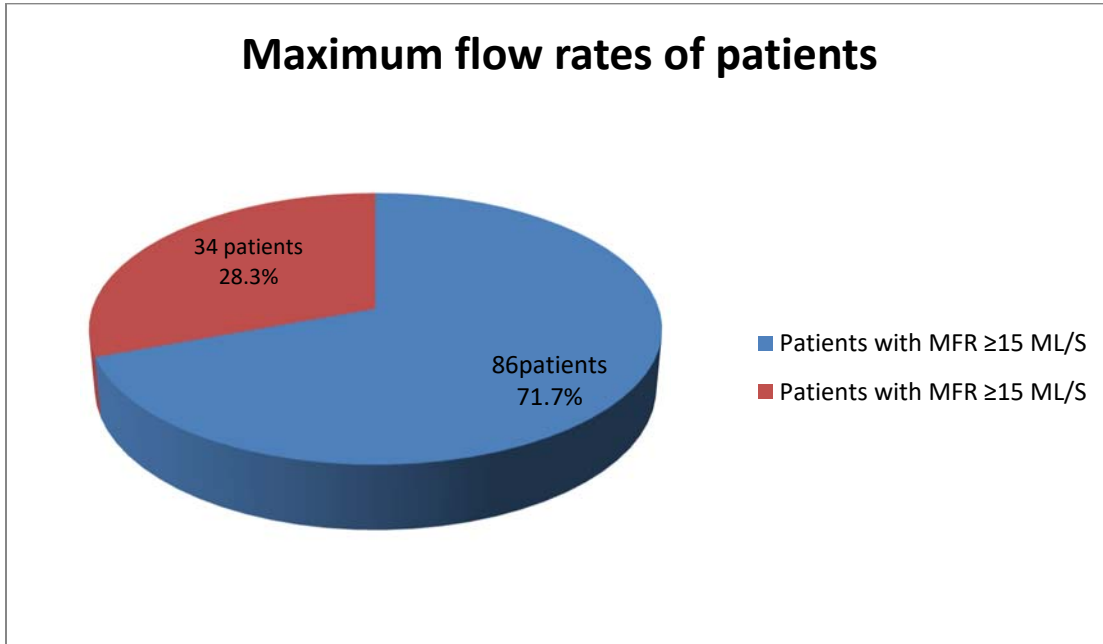
**Graph 1: Incidence of different complications of TIP repair for distal hypospadias**

Measuring the flow rate for patients showed that 86 (71.7 %) of them had a maximum flow rate  $\geq 15$  ml / s while 34 patients (28.3%) had a maximum flow

rate  $<15$  ml/s [Figure 1] .Among those patients with reduced flow rate, 12 patient (35.3 %) had a history of urethrocutaneous fistula, 15 patients

(12.5%) had meatal stenosis and 7 patients (5.8%) had urethral stricture.

However, no patients had significant post void residual urine.



**Figure 1: maximum flow rate of the patients**

### Discussion

One of the most important aspects that evaluate the success and reliability of a surgical procedure is to study and analyze the long term outcome and the presence of late complications of such a procedure. Hypospadias is one of the most common congenital anomalies in urological practice with an incidence of one in 300 male newborns<sup>8</sup>. So many surgical techniques were designed to repair hypospadias according to the site of the hypospadiac meatus<sup>9</sup>. The tubularized incised plate urethroplasty is a very versatile and widely used procedure overall the world<sup>10</sup>. Studies in the literature have evaluated the incidence of different complications of TIP repair especially early and medium occurring

complications and also comparing TIP repair with other techniques<sup>6,8&11</sup>. Studies have found that the success rate of TIP repair is so high and the cosmetic and functional outcomes are considerably successful<sup>12-14</sup>. In addition, literatures showed that complications of TIP repair have variable incidence and so many literatures suggested different steps and modifications to reduce the incidence of different complications<sup>15&16</sup>. Our study aimed to evaluate the long term outcome of TIP repair for distal hypospadias namely in adolescents. This seems very important subject in order to figure out the exact incidence of late complications and success rate of this repair. This study showed that the long term complications

of TIP repair for distal hypospadias are relatively low and the majority of patients in this cohort had an acceptable voiding function. Long term follow up for surgeries is not an easy task because it needs a well-developed health recording systems and co-operative patients. This probably a major problem and challenge all over the world. Poor follow up of surgical outcome is either related to patient or doctor factors. Patients may change their addresses as they get older or they have new jobs or because of studying. In addition, health recording systems' data may be achieved after a long period of time and become difficult to be accessed. Our study also showed that urethrocutaneous fistula was the main identified complication among the patients in this cohort with an incidence of (18.3%). Urethrocutaneous fistula is by far the most common complication of hypospadias repair and so many factors contribute for its development. Different modifications and suggestions were used to reduce the risk of fistula development as harvesting well vascularized flaps to cover the neourethra<sup>16-18</sup>. Meatal stenosis was also a common complication and occurred in ( 11.7 %) of patients. This complication is probably one of the factors that are responsible for the development of urethrocutaneous fistula and it occurs mainly due to very tight glanular wings closure or further advancement of the tubularization. The current study showed that about half of the patients in this cohort had some form of complications. In fact the relatively high incidence of late complications may be contributed to several factors like the experience of the surgeon with this procedure, the presence of recurrent urinary tract infections or the state of development of the external genitalia. Some studies showed that other procedures may show less complication

than TIP repair<sup>19</sup>, while other studies showed comparable results<sup>20</sup>. Assessment of the sexual function of the patients in this cohort seemed to be not sufficient because they were so young and had no regular sexual activity, however, some of them reported a history of ejaculation. The majority of patients (71.7%) in this cohort had a satisfactory voiding function with no specific complaints like interrupted stream or weak urinary stream and the flow rate of majority of them was acceptable. The aim of this study was peculiar in that it investigated a group of patients who underwent surgery several years ago and evaluated the presence of complications that they have at the time of the study. Literatures usually evaluate the short, median and long term outcomes of repair of hypospadias and addressing the main complications that can arise because of the repair like urethrocutaneous fistula and urethral stenosis or meatal stenosis, however, few studies may evaluate the long term outcomes of Snodgrass repair for distal hypospadias. The present study clearly confirmed that (TIP) repair is a good and versatile surgical technique that can give acceptable results even at the long-term outcome in adolescents who were having their repair at childhood. However, this technique is not devoid of late complications and a considerable percentage of patients are still suffering complications at the long-term run which may affect their voiding and sexual functions and necessitate further counseling and interventions.

#### Conclusion:

TIP is considered as appealing surgical technique for repair of distal type of hypospadias which accounts for the majority of hypospadias. This technique is not only having a high success rate at the short or medium-term outcomes but also it seems very successful in yielding good

results at the long-term outcome. Despite this fact, this procedure can have considerable complications which may need further interventions. It is suggested

that larger cohorts are to be involved in future studies which may be done several years later when these population of patients are getting older.

## References

- 1 .Springer A, Krois W, Horcher E: Trends in hypospadias surgery: results of a worldwide survey. *Eur Urol* 2011;60:1184-1189. [doi:10.1016/j.eururo.2011.08.031](https://doi.org/10.1016/j.eururo.2011.08.031)
- 2 .Snodgrass W (1994) Tubularized, incised plate urethroplasty for distal hypospadias. *J Urol* 151:464–465. [doi:10.1016/s0022-5347\(17\)34991-1](https://doi.org/10.1016/s0022-5347(17)34991-1)
- 3 .Steven L, Cherian A, Yankovic F, et al. Current practice in pediatric hypospadias surgery: A specialists survey. *J Pediatr Urol*.2013;9:1126-30.
- 4 .Rynja SP, de Jong TP, Bosch JL, de Kort LM. Functional, cosmetic and psychosexual results in adult men who underwent hypospadias correction in childhood. *J Pediatr Urol*. 2011;7:504–15. [doi:10.1016/j.jpuro.2011.02.008](https://doi.org/10.1016/j.jpuro.2011.02.008)
- 5 .Carmack A, Notini L, Earp BD. Should Surgery for Hypospadias Be Performed Before An Age of Consent?. *J Sex Res*. 2016 Oct. 53 (8):1047-1058. [Medline]. [doi:10.1080/00224499.2015.1066745](https://doi.org/10.1080/00224499.2015.1066745)
- 6 .Radi Alsharbaini , Hamdi Almaramy. Snodgrass urethroplasty for hypospadias repair: A retrospective comparison of two variations of the technique. *Journal of Taibah University Medical Sciences* .2014; 9( 1), March: 69-73. [doi:10.1016/j.jtumed.2013.10.002](https://doi.org/10.1016/j.jtumed.2013.10.002)
- 7 .H.M. Wood, D. Wood (Eds.), *Transition and lifelong care in congenital urology, current clinical urology*, Springer International Publishing, Switzerland (2015), pp. 35-42. [doi:10.1007/978-3-319-14042-1](https://doi.org/10.1007/978-3-319-14042-1)
- 8 .Duckett JW, Snyder HM. The MAGPI hypospadias repair in 1111 patients. *Ann Surg*, 1991; 213(6): 620-5. [doi:10.1097/00000658-199106000-00012](https://doi.org/10.1097/00000658-199106000-00012)
- 9 .Warren, Snodgrass. Hypospadias. *Pediatrics in Review* (the official journal of the American Academy of Pediatrics). 2004; 25:63-67.
- 10 .Deepak K Thakur. Outcome of Snodgrass Repair in Distal Hypospadias – An Institutional Experience. *Nepal JSSN* 2018; 21.(2) , [doi:10.3126/jssn.v21i2.24358](https://doi.org/10.3126/jssn.v21i2.24358)
- 11 .Mohammed LA Badr, Magdy A Loulah, Ahmed G Eltatawy, Allam SS Gamea. A comparative study between Snodgrass versus Mathieu with dartos flap urethroplasty for distal hypospadias repair. *MMJ*. 2019 ; 32 (2) : 489-493. [doi:10.4103/mmj.mmj\\_578\\_17](https://doi.org/10.4103/mmj.mmj_578_17)
- 12 .Pramod S, Prakash GS. Outcome of anterior hypospadias repair: A single center experience. *Arch Int Surg* 2018;8:10-5. [doi:10.4103/ais.ais\\_17\\_18](https://doi.org/10.4103/ais.ais_17_18)
- 13 .Ali Nawaz, Khanday Zaffer Saleem. An Observational Study between Snodgrass Urethroplasty and Modified Mathieu’s Repair in the Management of Distal Penile Hypospadias. *Annals of International medical and Dental Research*. 2018 Sep; 4(5): 13-16.
- 14 . Pardeep Bhatia, Avneet Singh Setia, Kushal Aggarwal et al. Hypospadias Repair; A Four Year Review. *New Indian J Surg*. 2019;10(2):183-186.
- 15 .Jayanthi VR (2003).The modified Snodgrass hypospadias repair: reducing the risk of fistula and meatal stenosis 170: 1603-1605. [doi:10.1097/01.ju.0000085260.52825.73](https://doi.org/10.1097/01.ju.0000085260.52825.73)
- 16 .ML Djordjevic, SV Perovic, Z Slavkovic, and N Djakovic (2006) “Longitudinal dorsal dartos flap for prevention of fistula after a Snodgrass hypospadias procedure,” *European Urology* 50:53–57 . [doi:10.1016/j.eururo.2006.04.014](https://doi.org/10.1016/j.eururo.2006.04.014)
- 17 .Sheng X, Xu D, Wu Y, Yu Y, Chen J, Qi J. The risk factors of Urethrocutaneous fistula after hypospadias surgery in the youth population. *BMC Urol*. 2018;18(1):64. [doi:10.1186/s12894-018-0366-z](https://doi.org/10.1186/s12894-018-0366-z)
- 18 .Adam S. Howe , Moneer K. Hanna. Management of 220 adolescents and adults with complications of hypospadias repair during childhood .*Asian journal of urology* , volume 4 ,issue 1,2017: pp.14-17. [doi:10.1016/j.ajur.2016.09.010](https://doi.org/10.1016/j.ajur.2016.09.010)
- 19 .El-Helaly HA, Youssef HA, Ibrahim HM, Aldaqadossi HA, Abdalla OM, Dogha MM. Distal hypospadias repair: Comparative study between snodgrass and transverse preputial onlay flap. *J Pediatr Urol*. 2022 Oct;18(5):610.e1-610.e6 [doi:10.1016/j.jpuro.2022.08.016](https://doi.org/10.1016/j.jpuro.2022.08.016)
- 20 .Rady, M., Abdalla, M., Abdelrahman, M., Mohamed, A. Outcomes of Snodgrass (TIP) versus Slit Like Adjusted Mathieu (SLAM) in distal penile hypospadias repair in pediatrics. *Minia Journal of Medical Research*, 2022; 33(2): 103-110 [doi:10.21608/mjmr.2022.249981](https://doi.org/10.21608/mjmr.2022.249981)

---

**Acknowledgement:** deepest appreciation goes to all the employees and staff in the data archive units in all the centers at which the study was performed for their generous support.  
**Funding:** This manuscript receives no funding or grants from any source.

Attar, F., Mohammed, M., Mohammad, M. The long term evaluation of the sexual and voiding functions in adolescents with the tubularized incised plate urethroplasty for distal hypospadias at childhood. *Basrah Journal of Surgery*, 2023; (1): 68-75. doi: 10.33762/bsurg.2023.132158.1014

**Conflict of interest :** Authors declare no conflict of interest

**Authors' Contributions:**

Author 1 - Conception, Design, Materials, Data Collection, Writing

Author 2 - Writing, Literature Review

Author 3 - Writing, Analysis And Interpretation, Literature Review

All authors have made a substantial, direct, and intellectual contribution to the work, and approved it for publication.

**Availability of Data and Material:**

The corresponding author is prompt to supply datasets generated during and/or analyzed during the current study on wise request.

---

This is an open access article under the CC BY 4.0 license:

<http://creativecommons.org/licenses/by/4.0/>

---

**Cite this article:** Attar, F., Mohammed, M., Mohammad, M. The long term evaluation of the sexual and voiding functions in adolescents with the tubularized incised plate urethroplasty for distal hypospadias at childhood. *Basrah Journal of Surgery*, 2023;29 (1): 68-75. doi: 10.33762/bsurg.2023.132158.1014

---