



## Assessment of Bone Density around Dental Implants Using Two Platelet-Rich Fibrin Protocols (A Comparative Clinical Study)

Rahma Atheed Kamal \*, Rayan Salim Hamed

Department of Oral and Maxillofacial Surgery, College of Dentistry, University of Mosul

### Article information

Received: 14 October, 2020

Accepted: 20 December, 2020

Available online: 5 September, 2022

### Keywords:

Platelet- Rich Fibrin,  
PRF,  
Platelet concentrates.

### \*Correspondence:

### E-mail:

rshh70@uomosul.edu.iq

### Abstract

**Aims:** The current study aimed to compare bone density means around dental implants covered with one of two platelet rich fibrin preparation protocols (Standard-Platelet Rich Fibrin and Advanced-Platelet Rich Fibrin) using standard intraoral digital periapical radiographs. **Materials and methods:** A total of ten male patients with an age range of 28-51 years participated in this split-mouth clinical study. The patients were divided into two groups based on the platelet rich fibrin (PRF) protocol to be used with dental implant insertion into positive control (S-PRF) and study group (A-PRF). Each patient represented the two groups in which he received 2 dental implants; ten implants for each group (a total of 20 dental implants) of standard length and diameter in the posterior mandibular extraction sites of ipsilateral or contralateral side. In the positive control group, the standard PRF protocol was to be used to prepare the PRF clot. In the study group, the advanced PRF protocol was to be used to prepare the PRF clot. Both PRF membranes were to be instilled inside the osteotomy bed during dental fixture installation. Following the installation of dental implants and as a basis for comparison between both groups, densitometric analysis of bone around dental implants at immediate, four, eight and twelve weeks scheduled visits were made. **Results:** Total densitometric analysis results showed no significant difference within S-PRF group, within A-PRF group and between both groups, with the highest mean (167.07) being at twelve weeks after surgery in the A-PRF group. **Conclusions:** Both S-PRF and A-PRF, similarly enhanced and maintained bone density (synergistic effect) throughout the of study and as disclosed by densitometric values. The use of PRF in its current forms seems to be an accepted minimally invasive approach with good clinical results.

### الخلاصة

**الأهداف:** مقارنة متوسط كثافة العظام حول زراعات الأسنان المغطاة باحدى خثرات الفيبرين الغني بالصفائح الدموية المحضرة باحدى الطريقتين (الفيبرين المعياري الغني بالصفائح الدموية والفيبرين المتقدم الغني بالصفائح الدموية) باستخدام صور شعاعية رقمية داخل الفم. **المواد وطرائق العمل:** شارك عشرة مرضى ذكور تتراوح أعمارهم بين 28-51 سنة في هذه الدراسة السريرية. تم تقسيم المرضى إلى مجموعتين؛ المجموعة الفعلية (المجموعة 1) والمجموعة الدراسية (المجموعة 2) بالاعتماد على طريقة تحضير الفيبرين الغني بالصفائح الدموية (PRF) المستخدم مع زرعة الأسنان. كل مريض يمثل المجموعتين معا لحصوله على زرعتي أسنان؛ عشرة زراعات لكل مجموعة (المجموع 20 زرعة أسنان) بطول وقطر معينين في اماكن الأسنان المقلوعة في الفك السفلي اما الجانب المائل أو المقابل. في المجموعة الفعلية، تم استخدام الطريقة المعيارية لإعداد خثرة PRF. في المجموعة الدراسية، تم استخدام الطريقة المتقدمة لتحضير خثرة PRF. تم غرس غشائي خثرة PRF داخل التجاويف العظمية المهينة للزراعات في اثناء تركيب زرعة الأسنان. بعد تركيب زراعات الأسنان وللمقارنة بين المجموعتين تم استخدام مقياس تحليل الأشعة لقياس كثافة العظام حول زراعات الأسنان على فترات منتظمة بيوم العملية الجراحية وبعدها بالاسبوع الرابع والثامن والثاني عشر. **النتائج:** أظهرت نتائج مقياس تحليل الأشعة لقياس كثافة العظام ما يلي: . في التحليل الكلي لقياس كثافة العظام، لم يكن هناك فرق كبير داخل المجموعة الفعلية S-PRF، والمجموعة الدراسية A-PRF وبين المجموعتين، حيث كان أعلى متوسط (167,07) في الاسبوع الثاني عشر بعد الجراحة في مجموعة A-PRF. **الاستنتاجات:** كلا من S-PRF و A-PRF يحافظون ويحسنون من كثافة العظام وبالتالي المحافظة على الاندماج العظمي (تأثير تآزري) طوال فترة الدراسة. استخدام خثرة PRF بأشكاله الحالية هو أسلوب مقبول بأقل تدخل جراحي مع نتائج سريرية جيدة.

DOI:10.33899/rden.2021.128683.1058, © 2022, College of Dentistry, University of Mosul.

This is an open access article under the CC BY 4.0 license (<http://creativecommons.org/licenses/by/4.0/>)

## INTRODUCTION

Achieving a short and uneventful implant osseointegration period could make immediate or early loading of a dental implant more reasonable and predictable. Platelet-rich fibrin (PRF) is frequently used to accelerate wound healing. The activated platelets in the PRF clot secrete growth factors, which in turn enhance cellular proliferation, collagen synthesis, and osteoid production <sup>(1)</sup>.

Platelet concentrates for topical use have evolved as surgical adjuncts or suspensions in the field of regenerative medicine. They are autologous blood extracts transplanted to an injured site to improve local healing. Improving healing is a constant issue in all surgical disciplines <sup>(2)</sup>.

Platelet Rich Fibrin (PRF), is a second-generation platelet concentrate developed by Choukroun et al. in 2000 in France <sup>(3)</sup>. Platelet -rich fibrin (PRF) is a simple, low cost and minimally invasive method to obtain a natural concentration of autologous growth factors that is widely used to accelerate soft and hard tissue healing, thus, PRF is used in different fields of medicine. Unlike its predecessor, platelet rich plasma (first generation), platelet rich fibrin is strictly an autologous fibrin matrix containing a large quantity of platelets and leukocytes with a simpler preparation technique that avoids artificial or exogenous biochemical modifications <sup>(4, 5, 6, 7, 8)</sup>.

The PRF preparation protocol is a simple technique by which a 10 ml sample of blood is collected in a vacutainer glass or glass coated plastic tube and immediately centrifuged at 3000 rpm for 10 minutes. At the completion of the centrifuge cycle, three parts can be localized in the tube: the red blood cells at the bottom, a fibrin clot that represents the PRF in the middle, and the acellular plasma at the top.<sup>(4)</sup>

To improve its quality and content, hence efficiency, two preparation protocols from the original one have been added and are currently being used:

1. Choukroun advanced PRF (A-PRF) where the centrifugation cycle is 1500 rpm / 14 minutes <sup>(9)</sup>.
2. Choukroun i-PRF (solution/gel) where the centrifugation cycle is 700 rpm / 3 minutes <sup>(10)</sup>.

The PRF can either be used as a membrane (S-PRF or A-PRF), liquid or injectable form (i-PRF), or can be cut in fragments, and applied either in stand-alone therapies; additive therapies; or used in combination therapies with other biomaterials<sup>(4,9,10)</sup>.

The current conducted study aimed to compare bone density means around dental implants using two platelet – rich fibrin protocols at four scheduled intervals with first (day of surgery) day as a baseline for comparison with 4, 8 and 12 weeks.

## MATERIALS AND METHODS

Approval of the study was from the Scientific Research Committee /

Department of Oral and Maxillofacial Surgery / College of Dentistry / Mosul University. The location settings for the current study were the Dental Implantology Unit / Department of Oral and Maxillofacial Surgery / College of Dentistry / University of Mosul / Mosul / IRAQ in the period extending from (December /2019 to March / 2020). A total of ten male patients seeking dental implant treatment with an age range of 28-51 years participated in this split-mouth clinical study. A verbal and written consent form (appendix) explaining the procedure, possible outcomes were handed over to each patient. To avoid operator mediated errors, all surgical procedures were performed by the same oral surgeon using a standardized surgical technique, and equipment.

The inclusion criteria for the clinical study included the following:

1. Patients that fulfilled the research demands including follow-up sessions and informed signing of consent.
2. Healed edentulous area for at least 6 months after extraction.
3. Sufficient inter-occlusal space between edentulous area and opposing teeth.
4. Patients with no evident systemic diseases.
5. Patients with no history of bleeding problems.
6. Patients not on chronic medications that would impair healing.

7. Sufficient bone volume (evident clinically and radiographically).
8. No parafunctional habits.
9. Non –smokers.
10. Good oral hygiene.

Any patient who failed to fulfil one of the aforementioned inclusion criteria was excluded. Before surgery, detailed personal and medical data was collected from all patients including: name, age, gender, occupation and address, past and present medical and dental history. A clinical examination was conducted to inspect oral and para oral tissues to assess: alveolar height, width, contour, soft tissue attachments for any signs of inflammation, ulceration or scar formation and existing pathology. Palpation of the alveolar ridge was performed to evaluate: Identification of both soft tissue and underlying bone characteristics, any loose and excessive soft tissue and identification of bony abnormalities obscured by soft tissue excess. Standard periapical radiograph films, orthopantomogram (OPG), were taken for all patients to determine bone height and density at the selected implant site. The patients were divided into two groups based on the platelet rich fibrin (PRF) protocol to be used with dental implant insertion into; positive control (**S-PRF**) and study group (**A-PRF**). Each patient represented the two groups in which he was to receive 2 dental implants / Superline / Implantium / Dentium Corporation, South Korea; ten implants for each group (total of 20) of standard length

and diameter (3.8\*10mm) in the posterior mandibular extraction sites of ipsilateral or contralateral side. In the positive control group, the standard PRF protocol was to be used to prepare the PRF clot. In the study group, the advanced PRF protocol was to be used to prepare the PRF clot. Both PRF membranes were to be instilled inside the osteotomy bed during dental fixture installation. The PRF preparation protocol were as follows; for each patient, a total of 4 tubes of 10ml peripheral blood were collected (two on each surgical occasion). The preferred vein chosen for venepuncture and blood collection is the larger and fuller median cubital vein in the antecubital fossa using a 21-gauge needle in glass coated plastic vacutainer tubes. The blood samples were then immediately placed in a preprogramed centrifuge (PC-O2, PROCESS for PRF, Nice, France). Centrifugation was performed according to the following two protocols designed for the current study:

- 1- Standard PRF: The centrifuge cycle is 3000 revolutions per minute (r.p.m) for 10 minutes.<sup>(4)</sup>
- 2- Advanced PRF: The centrifuge cycle is 1500 (r.p.m) for 14 minutes.<sup>(9)</sup>

At the completion of the designated centrifugation cycle, the two tubes were removed and placed in a plastic rack to allow the formed clots to rest and mature for 10 minutes. After ten minutes, the caps of tubes are removed and each PRF clot was gently picked up using sterile tweezers and laid on the PRF collection box grid

(Figure 1). The red blood cell layer was gently scraped off from each clot using scissors and a compression tray was laid over the clots for 5 minutes. This will release exudates from the clot turning it into a membrane with uniform thickness ready to be used during surgery.


### **Surgical Procedure**

The same surgical protocol was followed in both groups (S-PRF and A-PRF) groups. All patients were instructed to irrigate their mouths with a half cup filled 0.2% chlorhexidine mouth wash (Kin / Spain) for one minute before administration of the local anaesthetic agent. Routine regional anaesthesia was applied including inferior alveolar nerve block together with buccal infiltration anaesthesia. Two cartilages of 4% Articaine hydrochloride solution with 1:100.000 epinephrine (Colombia) were given. In order to avoid operator mediated errors, all surgeries were operated by the same oral surgeon under a standardized surgical technique and equipment. Following induction of local anaesthesia as assessed by clinical examination, a crestal incision (based slightly lingually) was made along the surgery site using scalpel blade (no 15) and a three sided mucoperiosteal flap was gently raised and reflected using a mucoperiosteal elevator. The crestal ridge was cleared and a standard surgical osteotomy for installation of a dental implant fixture as supplied from the manufacturer (Dentium / South Korea) was

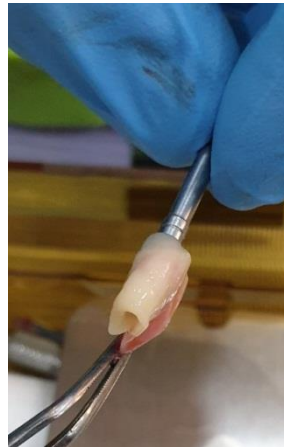prepared and as follows; a pilot drill mounted on an angled surgical handpiece with copious amounts of coolant was first used to guide the rest of the drills in correct position and angulations. Sequential larger size drills were used and based on the bone density encountered during drilling, either a final drill similar to the required diameter for the fixture or a smaller diameter than the final implant diameter (low density bone) was used according to manufacturer instructions. Before the instillation of the dental implant fixture, one PRF membrane was to be placed inside the bony socket. This was performed by gently rolling the membrane around the implant fixture <sup>(11)</sup> (Figure 2). With the implant fixture covered by the PRF membrane and mounted on a hand wrench, it was gently screwed into its osteotomy bed. Any excess of PRF membrane extruding out of socket following instillation of implant fixture was left in situ. At completion, a healing screw was placed (replaced later by a healing abutment of low profile) and flap repositioned and edges sutured using 3/0 black silk suture. Post-operative medications (Amoxil caps 500mg / 1\*3 + Ibuprofen tabs 400mg / 1\*3) were prescribed. Sutures were removed after 7 days.

Each dental implant was subjected to four scheduled radiological examinations (day of surgery, four weeks, eight weeks

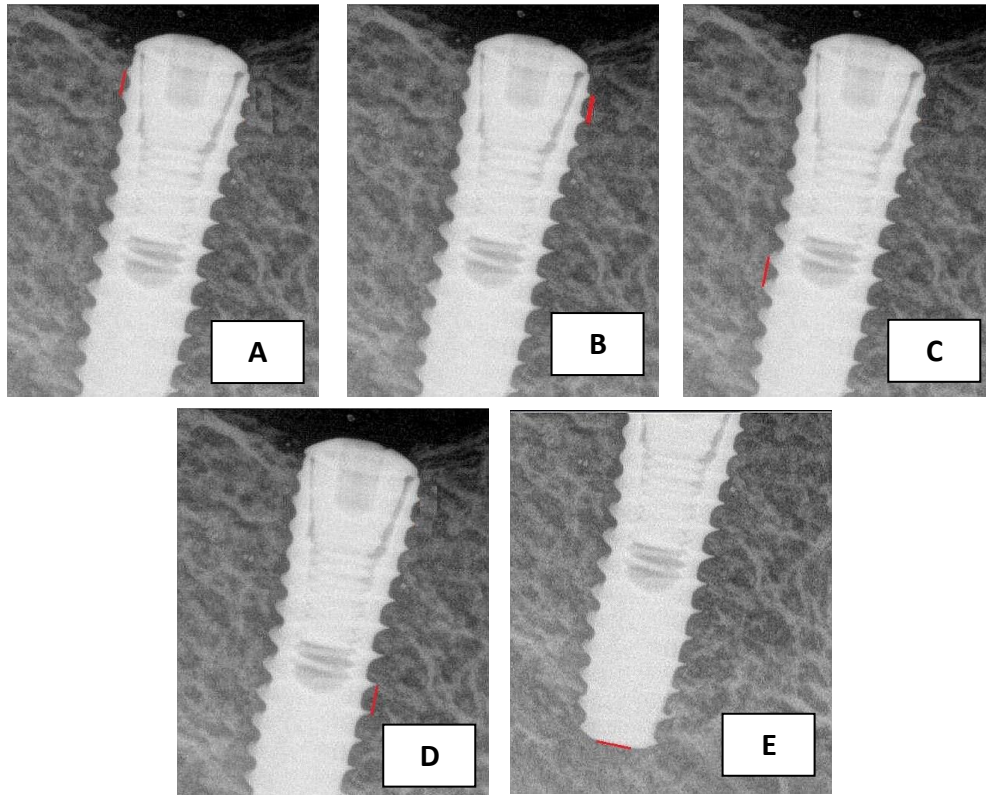
and twelve weeks post-surgery) using a digital dental radiographic machine in which X-ray images acquired were analysed using an imaging analysis software program (version 7.0.3) at Al-Rasheed Radiographic Centre / Mosul / IRAQ by an experienced radiologist. The parallel technique (to avoid elongation or shortening and any geometrical distortion in the image) was used as an imaging procedure. Power settings were a current of 50 mA/sec. and voltage (kilovolt) of 60 KV. The X-ray source – object distance was selected by fixing the sensor (size =1 Care stream, RVG 5200) on a digital sensor positioner, imagining the implant in the middle of the sensor and fixing the source five centimetres away from the sensor. The sensor was parallel to the long axis of the adjacent teeth with the central ray being perpendicular to the tooth and sensor surface horizontally and vertically. The goal was to assess densitometry values reflecting bone density surrounding each dental implant at four scheduled visits. Densitometry values are displayed as a graph with values ranging from 0 to 255; with the value (0) as black and value (255) as white. The field of interest (FOI) was the implant fixture and surrounding bone and was covered with the central x-ray centred on the implant fixture (Figure 3).



**Figure (1):** Platelet – rich fibrin clots before manipulation.



**Figure (2):** The PRF membrane is gently rolled around the dental implant fixture before installed in its osteotomy bed.



**Figure (3):** Linear (red line) selection for densitometric analysis of dental implant bony bed.

### Statistical analysis

Data were translated into a computerized database structure. All statistical analysis was performed using commercially available statistical software (**SPSS Version 23**). The following tests were used:

All variables to be assessed were considered non-parametric and hence the following tests were used:

- 1- **Descriptive analysis** to show minimum, maximum, means and standard deviations.
- 2- **Friedman test** for densitometric means at region of bone – dental implant.
- 3- **Mann-Whitney** test to show significance between groups for densitometric means at scheduled intervals.

A significant statistical difference was set at  $p \leq 0.05$ .

### RESULTS

The total number of patients enrolled in the current study included ten healthy male gender subjects with a mean age of 31 years. All surgeries performed were uneventful and no drastic complications followed throughout the period of study (survival rate of 100%) with the maintenance of a healthy gingival profile.

Bone quality around the dental implants was judged according to **Lekholm and Zarb** classification and as follows; 6 implants were placed in type 1 bone density, 12 implants in type 2 bone density and two in type 3 bone density. At completion of study period, all patients received ceramic – gold metal crown restorations.

Descriptive and Friedman test values of total densitometric means dental implant beds for S-PRF group protocol at four scheduled intervals showed a statistically significant difference among intervals with the highest mean being in the twelfth week after surgery (161.36) and as shown in (Table 1).

Descriptive and Friedman test values of total densitometric means dental implant beds for A-PRF group protocol at four scheduled intervals showed no statistically significant difference among intervals with the highest mean being in the twelfth week after surgery (167.07) and as shown in (Table 2).

When comparing total densitometric means of dental implant beds between both group protocols, the Mann Whitney test values of means showed no statistically significant difference between them at baseline day surgery, four weeks, eight weeks and twelve weeks post-surgery and as shown in (Table 3).

**Table (1):** Comparison of total densitometric means of dental implant beds for S-PRF protocol at four scheduled intervals.

Interval	N	Min.	Max.	Mean	$\pm$ SD	Mean Ranks	Friedman (Chi-Square)	Sig.
Baseline (day of Surgery)	10	119.80	166.00	142.32	19.79	1.60	10.408	0.015
Four weeks	10	129.60	165.80	151.20	18.33	2.20		
Eight weeks	10	144.60	169.00	156.60	11.34	2.90		
Twelve weeks	10	156.00	169.00	161.36	6.50	3.30		
Total	40	119.80	169.00	152.87	16.08			

Min.: Minimum / Max: Maximum / SD: Standard Deviation / Sig.: Significance at  $p \leq 0.05$ .

**Table (2):** Comparison of total densitometric means of dental implant beds for A-PRF protocol at four scheduled intervals.

Interval	N	Min.	Max.	Mean	$\pm$ SD	Mean Ranks	Friedman (Chi-Square)	Sig.
Baseline (day of Surgery)	10	120.60	195.00	158.50	33.26	2.70	7.320	0.062
Four weeks	10	132.80	185.20	156.16	21.49	1.60		
Eight weeks	10	143.00	189.20	164.40	19.18	2.60		
Twelve weeks	10	151.20	177.80	167.07	13.17	3.10		
Total	40	120.60	195.00	161.53	22.50			

Min.: Minimum / Max: Maximum / SD: Standard Deviation

**Table (3):** Comparison of total densitometric means of dental implant beds between S – PRF and A-PRF protocols at four scheduled intervals.

Interval	Protocol	N	Mean	$\pm$ SD	Mann-Whitney Chi-Square	Sig.
Baseline (day of Surgery)	S - PRF	10	142.32	19.79	0.839	0.360
	A - PRF	10	158.50	33.26		
Four weeks	S - PRF	10	151.20	18.33	0.023	0.879
	A – PRF	10	156.16	21.49		
Eight weeks	S – PRF	10	156.60	11.34	0.23	0.879
	A- PRF	10	164.40	19.18		
Twelve weeks	S – PRF	10	161.36	6.50	3.89	0.490
	A – PRF	10	167.07	13.17		

SD: Standard Deviation / Sig.: Significance at  $p \leq 0.05$ .



## DISCUSSION

Achieving a short and uneventful implant osseointegration period could make immediate or early loading of a dental implant more reasonable and predictable. Platelet-rich fibrin (PRF) is frequently used to accelerate wound healing. The activated platelets in the PRF clot secrete growth factors, which in turn enhance cellular proliferation, collagen synthesis, and osteoid production<sup>(9,10)</sup>. Several researches have been recognized dealing with standard platelet rich fibrin (S-PRF) to enhance osseointegration around dental implant beds and were defined as study groups for the basis of comparison<sup>(12,13,14)</sup> and a positive control group in another<sup>(15)</sup> whom considered the dental implant with S-PRF as a positive control group and a study group using diode laser to evaluate the bio-stimulatory effect of Low Level laser treatment on dental implants in bilaterally missing mandibular posterior teeth. Advanced platelet rich fibrin (A-PRF), a new concept in PRF has also become a topic of interest<sup>(16)</sup>. To the scope of our knowledge, this was the first study carried out comparing both protocols at the same time in relation to enhancing bone density. Concerning all surgical procedures, all selected patients underwent meticulous surgery and applying a delayed implant placement protocol. Ismail *et al.*<sup>(14)</sup> assessed radiographically the effect of S-

PRF on dental implant stability compared at day one surgery and 6 months post-surgery, the study revealed a significant difference between bone density values around the dental implant without PRF and with PRF plus the increase in bone density values after six months post-surgery. Sleem *et al.*<sup>(15)</sup> measured the relative per-implant bone density with S-PRF using intraoral digital radiographs at 4 time intervals (day one surgery and 1, 4 and 9 months post-surgery) and analyzed the radiographic images using DR software by drawing three lines (mesial, distal and apical) around the dental implant and revealed that the relative bone density values gradually increased at first month and forth month after surgery. Angelo *et al.*<sup>(17)</sup> who recommended the use of PRF around dental implant in an augmented maxillary bone for enhancing bone regeneration to improve its biomechanical quality with less human morbidity when compared with traditional methods. Boora *et al.*<sup>(12)</sup> recommended the strong clinical stimulation of bone formation when using S-PRF around dental implant in maxillary anterior region. Hafez *et al.*<sup>(18)</sup> used PRF membrane as primary coverage for the immediately inserted implants and found that this procedure is beneficial and may be used successfully to preserve the autogenous bone graft. Concerning A-PRF effectiveness, Ghanaati *et al.*<sup>(8)</sup> showed that A-PRF has an elevated number of neutrophils which share in

monocyte / macrophage differentiation with the presence of their growth factors. Kobayashi et al. <sup>(16)</sup> compared PRP, advanced PRF and standard PRF according to quantity of growth factors released and demonstrated that PRP releases the highest quantity in a very short early period whereas advanced PRF released a more gradual quantity of growth factors over time up to ten days and when compared with standard PRF, the A-PRF releases significantly higher growth factor quantity over time and may be clinically more efficient for regenerative surgical procedures. Clark et al. <sup>(19)</sup> used A-PRF with freeze-dried bone allograft to improve alveolar bone osseogenesis and stability of the inserted dental implants. Cabaro et al. <sup>(20)</sup> compared between standard and advanced rich fibrin according to quantity of growth factors released from the trapped leukocytes in the fibrin mesh and found that the A-PRF is the best candidate for hard and soft tissue repair. Caruana et al. <sup>(21)</sup> demonstrated that A-PRF not only has an increase in the neutrophils numbers but also in the time of growth factors release up to 10 days. This fact leads to better cellular conduction, migration, angiogenesis, and the natural tissue healing process. In the current study, no significant difference was disclosed in densitometric means at 12<sup>th</sup> - week interval between both protocols, yet both had a positive impact on enhancing and maintaining bone density in the peri-implant area.

## CONCLUSIONS

Within the limitations of the current study, and at the end point of the trial both **S-PRF** and **A-PRF** , similarly enhanced and maintained bone density hence (synergistic effect ) throughout the period of study and as disclosed by densitometric values.

**Conflicts of Interest:** "The authors declare that there are no conflicts of interest regarding the publication of this manuscript".

**Acknowledgements:** The researchers would like to thank Dr Asmaa Basheer / Department of Oral and Maxillofacial Surgery / College of Dentistry / University of Mosul for her assistance in radiographic image analysis.

## REFERENCES

1. ÖNCÜ, Elif; ALAADDINOGLU, E. Emine. The effect of platelet-rich fibrin on implant stability. *International Journal of Oral & Maxillofacial Implants*, 2015, 30.3.
2. CHICHARRO-ALCÁNTARA, Deborah, et al. Platelet rich plasma: new insights for cutaneous wound healing management. *Journal of functional biomaterials*, 2018, 9.1: 10.
3. Choukroun J et. Al "Une opportunité en paro-implantologie: le PRF. *Implantodontie*", 2000; 42: 55-62.
4. DOHAN, David M., et al. Platelet-rich fibrin (PRF): a second-generation platelet concentrate. Part I:

- technological concepts and evolution. *Oral Surgery, Oral Medicine, Oral Pathology, Oral Radiology, and Endodontology*, 2006, 101.3: e37-e44.
5. DOHAN, David M., et al. Platelet-rich fibrin (PRF): a second-generation platelet concentrate. Part II: platelet-related biologic features. *Oral Surgery, Oral Medicine, Oral Pathology, Oral Radiology, and Endodontology*, 2006, 101.3: e45-e50.
  6. DOHAN, David M., et al. Platelet-rich fibrin (PRF): a second-generation platelet concentrate. Part III: leucocyte activation: a new feature for platelet concentrates?. *Oral Surgery, Oral Medicine, Oral Pathology, Oral Radiology, and Endodontology*, 2006, 101.3: e51-e55.
  7. CHOUKROUN, Joseph, et al. Platelet-rich fibrin (PRF): a second-generation platelet concentrate. Part IV: clinical effects on tissue healing. *Oral Surgery, Oral Medicine, Oral Pathology, Oral Radiology, and Endodontology*, 2006, 101.3: e56-e60.
  8. CHOUKROUN, Joseph, et al. Platelet-rich fibrin (PRF): a second-generation platelet concentrate. Part V: histologic evaluations of PRF effects on bone allograft maturation in sinus lift. *Oral Surgery, Oral Medicine, Oral Pathology, Oral Radiology, and Endodontology*, 2006, 101.3: 299-303.
  9. GHANAATI, Shahram, et al. Advanced platelet-rich fibrin: a new concept for cell-based tissue engineering by means of inflammatory cells. *Journal of Oral Implantology*, 2014, 40.6: 679-689.
  10. MIRON, Richard J., et al. Injectable platelet rich fibrin (i-PRF): opportunities in regenerative dentistry?. *Clinical oral investigations*, 2017, 21.8: 2619-2627.
  11. SEHGAL, Manoti, et al. Immediate dental implants enriched with L-PRF in the esthetic zone. *Case reports in dentistry*, 2018, 2018.
  12. BOORA, Priyanka; RATHEE, Manu; BHORIA, Mohaneesh. Effect of platelet rich fibrin (PRF) on peri-implant soft tissue and crestal bone in one-stage implant placement: a randomized controlled trial. *Journal of clinical and diagnostic research: JCDR*, 2015, 9.4: ZC18.
  13. TABRIZI, R.; ARABION, H.; KARAGAH, T. Does platelet-rich fibrin increase the stability of implants in the posterior of the maxilla? A split-mouth randomized clinical trial. *International journal of oral and maxillofacial surgery*, 2018, 47.5: 672-675.
  14. ISMAIL, Radwa M.; SHOREIBAH, Eatemad A.; ATTIA, Mai S. Clinical and Radiographic Assessment of Platelet Rich Fibrin Effect in One-Stage Dental Implant. *Al-Azhar*

- Dental Journal for Girls*, 2019, 6.1: 19-24.
15. SLEEM S., et al. Evaluation of The Bio-Stimulatory Effect of Platelet Rich Fibrin Augmented by Diode LASER Compared to Platelet Rich Fibrin Alone on Dental Implant Replacing Posterior Mandibular Teeth. Randomised Clinical Trial: Split Mouth Study. *Open Access Macedonian Journal of Medical Sciences*. 2019, 7(5):869.
  16. KOBAYASHI, Eizaburo, et al. Comparative release of growth factors from PRP, PRF, and advanced-PRF. *Clinical oral investigations*, 2016, 20.9: 2353-2360.
  17. ANGELO, Troedhan, et al. Biomechanical stability of dental implants in augmented maxillary sites: results of a randomized clinical study with four different biomaterials and PRF and a biological view on guided bone regeneration. *BioMed Research International*, 2015, 2015.
  18. HAFEZ, W. K., et al. Platelet rich fibrin as a membrane for coverage of immediate implants: Case-series study on eight patients. *Tanta Dental Journal*, 2015, 12.3: 203-210.
  19. CLARK, Daniel, et al. Advanced platelet-rich fibrin and freeze-dried bone allograft for ridge preservation: a randomized controlled clinical trial. *Journal of periodontology*, 2018, 89.4: 379-387.
  20. CABARO, S., et al. White cell and platelet content affects the release of bioactive factors in different blood-derived scaffolds. *Platelets*, 2018, 29.5: 463-467.
  21. CARUANA, Andrea, et al. From platelet-rich plasma to advanced platelet-rich fibrin: biological achievements and clinical advances in modern surgery. *European journal of dentistry*, 2019, 13.02: 280-286.

