

## Vertebral Anatomic Variations in Thoroughbred Racehorses in Trinidad

Reda Mohamed

Department of Basic Veterinary Sciences, School of Veterinary Medicine, Faculty of Medical Sciences, The University of the West Indies, St. Augustine, Republic of Trinidad and Tobago.  
Corresponding e-mail: [kkidareda@yahoo.com](mailto:kkidareda@yahoo.com) ORCID ID: <https://orcid.org/0000-0002-5512-6175>

Doi: <https://doi.org/10.37940/AJVS.2021.14.2.1>

Received: 21/8/2021 Revised: 11/10/2021 Accepted:17/12/2021

This article is licensed under a CC BY (Creative Commons Attribution 4.0)

<http://creativecommons.org/licenses/by/4.0/>.

### Abstract

Reports of the occurrence of lumbar vertebrae variants in horses in Trinidad are rare in the literatures. Parts of the skeletons of two horses of unknown age and sex that died in a horse farm in Trinidad and Tobago were brought to the Anatomy laboratory. It was reported that specimens of fused left transverse processes of the 5<sup>th</sup> and 6<sup>th</sup> lumbar vertebrae and a blunted left transverse process of the 6<sup>th</sup> lumbar vertebra in thoroughbred racehorses in Trinidad.

**Keywords:** Lumbar vertebrae, anatomy, variant, horse

الاختلافات التشريحية الفقرية في خيول السباق الأصلية في ترينيداد

### الخلاصة

التقارير عن حدوث تغيير في الفقرات القطنية في الخيول في ترينيداد نادرة في المصادر. تم جلب اجزاء من الهيكلين العظمي لخيولين مجهولين العمر والجنس نفقى في مزرعة خيول في ترينيداد وتوباغو إلى مختبر التشريح. تم التوصل الى ان عينات من البروز العرضية اليسرى المندمجة للفقرتين القطنية الخامسة والسادسة وبروز عرضي يساري ضعيف للفقرة القطنية السادسة في خيول السباق الأصلية في ترينيداد

### Introduction

The vertebral column is important for locomotion, weight-bearing and soft tissue attachment sites. The domestic horse normally has 6 lumbar vertebrae (1). The lumbar vertebrae are characterized by elongated, horizontally flattened transverse processes for attachment with large dorsal paraspinal muscles and ventral psoas muscle group (2). There are no intertransverse joints at birth but they develop soon thereafter (1).

Domestic horses have intertransverse synovial articulations at the lumbosacral junction and between the transverse processes of the last two or three lumbar vertebrae (4, 5) which help in the transfer of propulsive forces from the hind limb to the vertebral column (2). The importance of the equine thoracolumbar vertebral column in orthopedic disorders is well recognized and diagnostic imaging becomes more feasible (6).

## Case details

Part of the skeletons of two horses of unknown age and sex that died in a horse farm in Trinidad and Tobago were brought to the Anatomy laboratory, School of Veterinary Medicine, Faculty of Medical Sciences, University of the West Indies, Trinidad and Tobago for demonstration of the axial skeleton to year I veterinary students. The skeletons were dissected, disarticulated, boiled, bleached in 3% hydrogen peroxide, and then air-dried. Photographs were taken for documentation using a Kodak digital camera. The transverse processes of the normal lumbar vertebrae were elongated, flattened and horizontal and gave the attachment site for the epaxial and hypaxial muscles. Normally there is a pair of intertransverse synovial articulations between the 5th and 6th lumbar vertebrae, however, there were specimens of anatomical variants in which there was a fusion of the left transverse processes of the 5th and 6th lumbar vertebrae in two specimens (Figure 1A&B). The left transverse process of the 6th lumbar vertebrae was peripherally blunted in one specimen (Figure 1B).

## Discussion

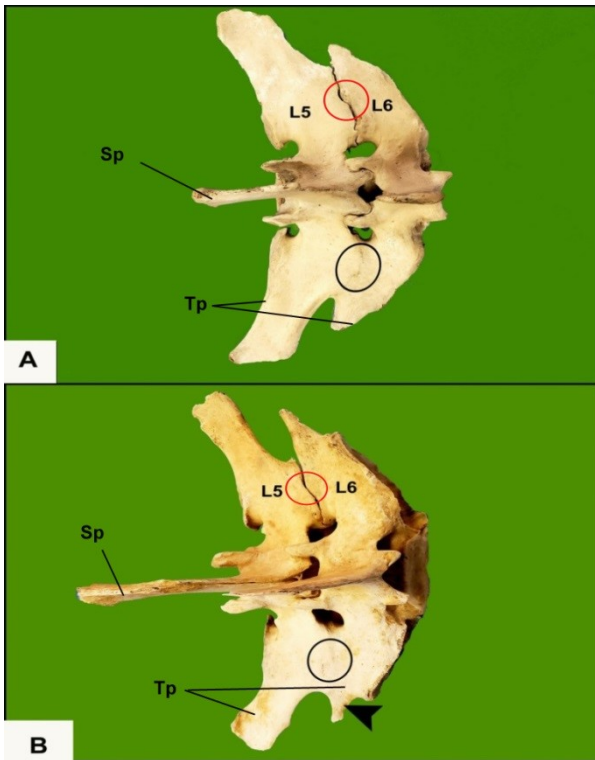
Most of the intertransverse synovial articulations of the lumbar vertebrae in the horse typically occur in pairs between the left and right transverse processes of the 5th and 6th lumbar vertebrae; a similar finding was in the horse (3, 5, 7, 8).

The intertransverse joints have a stabilizing function by limiting the range of lumbar motion, provide resistance to lateral bending and axial rotation of the spine and help in the transfer of propulsive forces from the hind limbs to vertebral column (5, 8, 9).

The current study reported that the right intertransverse synovial articulation was present in two specimens, while there was a fusion between the left transverse processes of the 5th and 6th lumbar vertebrae (ankylosis); similar findings were reported in the horse (3, 6, 7, 10). The asymmetry in the intertransverse joints might be possibly related to asymmetry in back motion (11). This fusion limits movements in the intertransverse joints (5). Intertransverse joint ankylosis is common either unilaterally or bilaterally and is probably not a significant cause of back pain in horses but may be for further adaptations to strain (5, 7). The current case report showed that the left transverse process of the 6th lumbar vertebrae was peripherally blunted in one case which is similar to the finding in the horse (10).

## Conclusion

Knowledge of normal spinal morphology and vertebral variation is of extreme clinical importance for surgeons and radiologists for distinction of pathologic change from normal anatomic variations



**Figure 1:** A photograph showing fused left transverse processes of the L5-L6 (black oval; A & B) and a left blunted transverse process of L6 (black arrowhead). L5-5<sup>th</sup> lumbar vertebra; L6-6<sup>th</sup> lumbar vertebra; Sp-Spinous process; Tp-Transverse process; Red oval-Intertansverse joint (ITJ)

## References

1. RM S. Anatomical variations of the spine in the horse. *Journal of Mammalogy*. 1926a; 43: 205–219.
2. Haussler KK. Anatomy of the thoracolumbar vertebral region. *Vet. Veterinary Clinics of North America: Equine Practice*. 1999; 1:13-26.
3. RM S. Lateral facets and lateral joints in the lumbar spine of the horse--a descriptive and statistical study.

*American journal of veterinary research*. 1962b Sep 1;23:939-47.

4. Getty R, Sisson S, Grossman J: Sisson and Grossman's *The Anatomy of the Domestic Animals*. 5th edn., W.B. Saunders Co., Philadelphia. 1975.
5. Townsend HG, Leach DH. Relationship between intervertebral joint morphology and mobility in the equine thoracolumbar spine. *Equine veterinary journal*. 1984 Sep;16(5):461-5.
6. Spoormakers TJ, Veraa S, Graat EA, van Weeren PR, Brommer H. A comparative study of breed differences in the anatomical configuration of the equine vertebral column. *Journal of Anatomy*. 2021 May 15.
7. Haussler KK, Stover SM, Willits NH. Developmental variation in lumbosacropelvic anatomy of Thoroughbred racehorses. *American Journal of Veterinary Research*. 1997; 58:1083-1091.
8. Haussler K. *Functional Anatomy and Biomechanics of the Caudal Trunk and Pelvis*. 2018. [http://www.valvt.org/resources/Documents/Moore\\_Proceedings%201.pdf](http://www.valvt.org/resources/Documents/Moore_Proceedings%201.pdf).
9. STECHER RM, Goss LJ. ANKYLOSING LESIONS OF SPINE OF HORSE. *Journal of the American Veterinary Medical Association*. 1961 Jan 1;138(5):248.

10. Collar EM, Zavodovskaya R, Spriet M, Hitchens PL, Wisner T, Uzal FA, Stover SM . Caudal lumbar vertebral fractures in California Quarter Horse and Thoroughbred racehorses. Equine Veterinary Journal. 2015; 47:573-9.
11. Faber M, Schamhardt H, Weeren RV, Johnston C, Roepstorff L, Barneveld AB. Basic three-dimensional kinematics of the vertebral column of horses walking on a treadmill. American journal of veterinary research. 2000 Apr 1;61(4):399-406.