

Amelioration effect of methanolic extract of *Cyperus rotundus* on type 2 diabetes mellitus, thyroid dysfunction and gall stone induce by dexamethasone in male rabbits

Muna H. AL-Saeed

Department of Physiology, Pharmacology and Chemical, College of Vet. Med.
University of Basrah, Basrah, Iraq.

Abstract

The research investigated the possible involvement of type2 diabetes mellitus, thyroid dysfunction and gall stone induce by dexamethasone, and therapeutic effect of *Cyperus rotundus* as antidiabetic potential. This study was carried out in the animal house of the College of Veterinary Medicine - Basrah University. The rabbit was used as a model to study the effects of type2 diabetes mellitus thyroid dysfunction and gall stone induce by dexamethasone, Twenty-four healthy adult domestic rabbits were divided randomly into four groups. The first group (C) had been regarded as control each rabbit in the control group was drenched 3ml of normal saline daily by using gastric tube for 15 days. The second group (DEX) was drenched (0.35 mg / Kg B.W. single dosage) of dexamethasone tablets which were powdered, dissolved in 3ml of normal saline daily for 15 days. The third group (DEX + *Cyperus rotundus*) was drenched (0.35 mg / Kg B.W. single dosage) of dexamethasone and *Cyperus rotundus* 0.5g / Kg B.W. single dosage, dissolved in 3ml of normal saline daily for 15 days. The fourth group (*Cyperus rotundus*) was drenched (0.5g / Kg B.W. single dosage) of *Cyperus rotundus*, dissolved in 3ml of normal saline daily for 15 days. *Cyperus rotundus* was administered to -induced hyperglycaemic male rabbit and the alterations in serum concentrations of thyroid hormones, total cholesterol, triglycerides and fasting glucose were studied. Simultaneously changes in lipid peroxidation, reduced glutathione (GSH) content, superoxide dismutase and catalase activities in serum (which are commonly affected in diabetes mellitus), were also investigated. Administration of dexamethasone (0.35mg/kg/day orally for 15 days) caused hyperglycaemia with a parallel increase in serum glucose, total cholesterol, triglycerides and lipid peroxidation with a decrease in serum levels of both the thyroid hormones (triiodothyronine, T₃ and thyroxine, T₄). However, *Cyperus rotundus* administration (0.5 g/kg/day orally for 15 days) along with an equivalent amount of dexamethasone reverted most of these changes, including a marked an increase in the serum levels of both thyroid hormones. The present findings reveal that the test extract ameliorates corticosteroid-induced type 2 diabetes mellitus through an increase in serum thyroid hormone concentrations.

Ker word: Type2 diabetes mellitus, *Cyperus rotundus* ,gallstone.

المستخلص الميثانولي لنبات السعد *Cyperus rotundus* تأثير محسن لداء السكر النوع الثاني والخلل وظيفي للغدة الدرقية وحصى المرارة المستحدث بواسطة عقار الدكساميثازون

منى حميد السعيد

فرع الفلسفة والأدوية والكيمياء, كلية الطب البيطري, جامعة البصرة.

الخلاصة

أوجدت هذه الدراسة إن المستخلص الميثانولي لنبات السعد له تأثير مضاد لداء السكر النوع الثاني, الخلل الوظيفي للغدة الدرقية وحصى المرارة المستحدث بواسطة عقار الدكساميثازون. وقد أجريت الدراسة في البيت الحيواني لكلية الطب البيطري- جامعة البصرة على 24 من ذكور الأرانب المحلية, قسمت حيوانات التجارب بصورة عشوائية إلى أربع مجموعات الأولى هي مجموعة الأرانب السيطرة عوملت بالمحلول الفسيولوجي (3مل) لمدة 15 يوم والمجموعة الثانية هي الأرانب التي عوملت بعقار الدكساميثازون بجرعة 0.35 ملغم/كغم من وزن الجسم لمدة 15 ايام لاستحداث النوع الثاني من داء السكر, إما المجموعة الثالثة فشملت الأرانب بعقار الدكساميثازون بجرعة 0.35 ملغم/كغم من وزن الجسم + 0.5 غم/كغم نبات السعد *Cyperus rotundus* والمجموعة الرابعة عوملت فقط بنبات السعد (0.5 غم/كغم). ولوحظ التأثير المحسن لنبات السعد *Cyperus rotundus* لهرمونات الدرقية وإفراز الصفراء إذ له القابلية في تقثيت لحصى المرارة ويخفض مستوى الكوليسترول الكلي ومستوى لكلسيريدات الثلاثية ويرفع مستوى الهرمونات الغدة الدرقية الثاروكسين وثلاثي ايبودو ثايرونين ويحسن مستوى اليوريا وحمض البوليك والكرياتين وكذلك المعادن مثل الزنك والسليسيوم والنحاس ومضاد للتأكسد عند اعطاءه بجرعة 0.5 غم/كغم لمدة 15 يوما.

Introduction

Diabetes mellitus is a loss of glucose homeostasis, it caused by inherited and or acquired deficiency in production of insulin by the pancreas, or by the ineffectiveness of the insulin produced both resulting in impaired metabolism of glucose and other energy-yielding fuels such as lipids, carbohydrates and protein, and increased risk of complication from various diseases such as heart diseases and stroke, high blood pressure, atherosclerosis, kidney and nerve damage, liver disease, amputations, endocrinepathies (endocrine system disorders), dental disease, sexual dysfunction and immunodeficiencies as well as blindness[1].

The aetiology of type 2 diabetes mellitus in which the β -cells of pancreas are usually functional, very often involves hormonal imbalance [2], including that of adrenal glands [3]. In fact, the hormones of the adrenal cortex are well known for their diabetogenic effects and are

responsible for most steroid diabetes [3,4]. Despite the fact that thyroid hormones also regulate glucose metabolism and alter the antioxidant system. Dexamethasone (DEX) is a potent synthetic member of the [glucocorticoid](#) class of [steroid](#) drugs. It acts as an [anti-inflammatory](#) and [immunosuppressant](#). It is 20 to 30 times more potent than the naturally occurring [hormone cortisol](#) [5].

Glucocorticoids caused an imbalance in lipid metabolism leading to hyperlipidemia and had more effect on causing hypertriglyceridemia but no significant effects were found on protein metabolism and induced variable effects on altering the liver enzymes including ALT and AST and produce more obvious elevations in these enzymes. Hypercholesterolemia and hypertriacylglycerilemia were detected in DEX treated rats. Administration of DEX produce causes a significant reduction in plasma concentrations of T_4 and T_3 , and these

changes are accompanied by a sustained hyperglycaemia [6].

Herbals medicines are used now by up to 50% of western population for the treatment or prevention of several diseases, especially digestive disorder[7].

Cyperus refers to a family of marsh-dwelling grass-like plants known as sedges. *Cyperus rotundus* has numerous chemical constituents, many of which may show pharmacological and biological activity including antidiabetic, antidiarrhoeal, anticandida, anti-inflammatory, cytoprotective, antimutagenic, antimicrobial, antibacterial, cytotoxic and apoptotic, anti-pyretic and analgesic activities. Its extract significantly lowered the blood glucose levels. This antihyperglycemic activity can be attributed to its antioxidant activity [8]. Oral administration of *Cyperus* extract significantly improved liver functions[9]. The aim of the present study was to reveal the possible involvement of thyroid hormones in the antihyperglycaemic and antihypercholesteremia effects of methanolic extract of *Cyperus rotundus* on diabetic rabbits induce by dexamethacin.

Material and Methods

Experimental Animals

Twenty-four healthy adult domestic rabbits (*Lepus cuniculus domestica*) were brought from the local markets/ Basrah, Iraq of (7.5-8) months age, body weight (1500-2000) gm. Rabbits were kept for an adaptation period 1 month in the animal house of Veterinary Medicine College / Basrah University. Experimental animals were kept in individual cages, provided with ration composed fodder in addition to green alfalfa (*Medicago sativa*) and tap water *ad libitum* and given a prophylaxis drug against

coccidiosis (Amprollium 1g/L of drinking water) and these animals maintained in air-conditioned quarters (24°C) under standard husbandry condition with alternate 12 hours light /dark period.

Extract preparation

The rhizomes of *Cyperus rotundus* were brought from the local markets/ Basrah, Iraq. The collected sample of rhizomes was air dried under shade and ground into fine powdered form. Plant material (50 g) was extracted with methanol (500 mL) in soxhlet extractor. After the extraction time the solvent was removed under reduced pressure and crude extract containing high fraction of total polyphenols was stored in refrigerator.

Experimental Design

- 1- The first group (**C**) had been regarded as control each rabbit in the control group was drenched 3ml of normal saline daily by using gastric tube for 15 days.
- 2- The second group (**DEX**) was drenched (0.35 mg / Kg B.W. single dosage) of dexamethasone tablets which were powdered, dissolved in 3ml of normal saline daily for 15 days.
- 3- The third group (**DEX + *Cyperus rotundus***) was drenched (0.35 mg / Kg B.W. single dosage) of dexamethasone and *Cyperus rotundus* 0.5g / Kg B.W. single dosage, dissolved in 3ml of normal saline daily for 15 days.
- 4- The forth group (***Cyperus rotundus***) was drenched (0.5g / Kg B.W. single dosage) of *Cyperus rotundus*, dissolved in 3ml of normal saline daily for 15 days.

Collection of Blood Samples:

Blood samples (5ml) were collected from fasted male rabbits(control and treat animals), before and during experimental weekly from the heart by heparinized capillary tubes in plain tubes, and allowed to be clotted at

room temperature and put in centrifuge at 5000rpm to obtain serum were stored in polyethylene eppendorff tubes at -20°C, for hormonal assay and biochemical analysis such as (minerals, metabolic profile, enzymes) by spectrophotometers using specific kits.

Hormonal Assay.

Serum samples and plasma semen were assayed for TSH, T4, T3, testosterone, using the enzyme-linked immunosorbent assay (ELISA) technique using the Fortress kit.

Statistical Analysis:

The data were analyzed by SPSS software using one way variance analysis ANOVA, Version16. In all

tests, a P-value of <0.05 was considered statistically significant [10].

Results

1-Effect of Dexamethasone and *Cyperus rotundus* on body weight of male rabbits.

In the Table [1] showed that effects of dexamethasone and *Cyperus rotundus* on body weight 1 are significant decreases (P≤0.05) in group treated with dexamethasone compared with control group and *Cyperus rotundus* group while group treated with dexamethasone + *Cyperus rotundus* showed no significant changes in body weight compared with control group and *Cyperus rotundus* group.

1- Effect of Dexamethasone and *Cyperus rotundus* on body weight of male rabbits.

(Mean±SD)

n=6

Parameters Treatments	Initial body weight (g)	Final body weight (g)	Body weight Gain(g)
Control (Normal salin)	1795 ± 86.4 A	1865 ± 93.54 A	70 ± 16.89 A
Dexamethasone (0.35 mg/kg B.W.)	1800 ± 75.23 A	1350 ± 67.9 C	- 450 ± 113.64 C
<i>Cyperus rotundus</i> (0.5 g/kg B.W.)	1815 ± 69.25 A	1890 ± 58.29 A	75 ± 35.51 A
Dexamethasone + <i>Cyperus rotundus</i>	1788 ± 55.4 A	1835± 49.36 B	57 ± 18.39 B

N=number of animals, A,B,C= differences between groups, P≤0.05 vs. control.

2- Effect of Dexamethasone and *Cyperus rotundus* on glucose and lipid profile of male rabbits.

In the Table [2] showed that effects of dexamethasone and *Cyperus rotundus* on glucose cholesterol, Triglyceride and LDL are significant increases (P≤0.05) in group treated with dexamethasone compared with control group and *Cyperus rotundus* group while group treated with dexamethasone + *Cyperus rotundus* showed no significant changes in glucose cholesterol, Triglyceride, HDL and LDL compared with control group and *Cyperus rotundus* group.

Table2 :- Effect of Dexamethasone and *Cyperus rotundus* on glucose and lipid profile of male rabbits. (Mean±SD) n=6

Parameters Treatments	Glucose (mg/dl)	Cholesterol (mg/dl)	Triglyceride (mg/dl)	HDL (mg/dl)	LDL (mg/dl)
Control (Normal saline)	108.11 ± 9.44B	123.53 ±5.60 B	60.78 ± 3.85 B	48.66±0.53 A	19.69±0.60 B
Dexamethasone (0.35 mg/kg B.W.)	175.83± 8.36 A	225.16± 7.35 A	85.71 ± 4.94 A	37.21±4.29 B	93.82±0.12 A
<i>Cyperus rotundus</i> (0.5 g/kg B.W.)	104.23± 5.62B	118.07±8.09 B	55.63 ± 2.42 B	49.27±2.16 A	16.12±2.27 B
Dexamethasone + <i>Cyperus rotundus</i>	112.27± 7.39B	125.89±5.63 B	65.49 ± 4.56 B	45.54± 0.44 A	21.01±0.14 B

N=number of animals, A,B,C= differences between groups, P≤0.05 vs. control.

3- Effect of Dexamethasone and *Cyperus rotundus* on TSH, T₄ and T₃ of male rabbits.

In the Table [3] showed that effects of dexamethasone and *Cyperus rotundus* on TSH T₄ and T₃ are significant decreases (P≤0.05) in group treated with dexamethasone compared with control group and *Cyperus rotundus* group while group treated with dexamethasone + *Cyperus rotundus* showed no significant TSH,T₄ and T₃ compared with control group and *Cyperus rotundus* group.

Table3 :-Effect of Dexamethasone and *Cyperus rotundus* on TSH,T₄ and T₃ of male rabbits. (Mean±SD) n=6

Parameters Treatments	TSH (µIU/ml)	T ₄ (µg/dl)	T ₃ (ng/ml)
Control (Normal saline)	0.68 ± 0.04 A	1.65± 0.06 AB	0.89 ± 0.02 A
Dexamethasone (0.35 mg/kg B.W.)	0.42 ± 0.02 C	0.95± 0.05 C	0.53 ± 0.01 C
<i>Cyperus rotundus</i> (0.5 g/kg B.W.)	0.71 ± 0.08 A	1.73± 0.07 A	0.90 ± 0.03 A
Dexamethasone + <i>Cyperus rotundus</i>	0.64 ± 0.05 B	1.45± 0.06 B	0.80± 0.07 B

N=number of animals, A,B,C= differences between groups, $P \leq 0.05$ vs. control.

4-Effect of Dexamethasone and *Cyperus rotundus* on Se, Zn and Cu of male rabbits.

In the Table [4] showed that effects of dexamethasone and *Cyperus rotundus* on Se, Zn and Cu are significant decreases ($P \leq 0.05$) in group treated with dexamethasone compared with control group and *Cyperus rotundus* group while group treated with dexamethasone + *Cyperus rotundus* showed no significant Se, Zn and Cu compared with control group and *Cyperus rotundus* group.

Table 4 :-Effect of Dexamethasone and *Cyperus rotundus* on Se, Zn and Cu of male rabbits. (Mean \pm SD)

n=6

Parameters Treatments	Se (mg/ml)	Zn (μ g/dl)	Cu (μ g/ml)
Control (Normal salin)	0.12 \pm 0.02A	123.79 \pm 18.17 A	1.06 \pm 0.28A
Dexamethasone (0.35 mg/kg B.W.)	0.42 \pm 0.02 C	50.90 \pm 1.56 C	0.53 \pm 0.01 C
<i>Cyperus rotundus</i> (0.5 g/kg B.W.)	0.71 \pm 0.08 A	127.50 \pm 6.69 A	0.90 \pm 0.03 A
Dexamethasone + <i>Cyperus rotundus</i>	0.64 \pm 0.05 B	85.55 \pm 1.89 B	1.58 \pm 0.04B

N=number of animals, A,B,C= differences between groups, $P \leq 0.05$ vs. control.

5-Effect of Dexamethasone and *Cyperus rotundus* on GSH, SOD, MDA and CAT of male rabbits.

In the Table [5] showed that effects of dexamethasone and *Cyperus rotundus* on MDA are significant increases ($P \leq 0.05$) in group treated with dexamethasone compared with control group and *Cyperus rotundus* group while GSH, SOD and CAT showed the significant decreases ($P \leq 0.05$) in group treated with dexamethasone. The group treated with dexamethasone+*Cyperus rotundus* showed no significant changes in GSH, SOD,MDA and CAT compared with control group and *Cyperus rotundus* group.

Table 5:-Effect of Dexamethasone and *Cyperus rotundus* on GSH, SOD,MDA and CAT of male rabbits. (Mean±SD) n=6

Parameters Treatments	GSH μmol/L	SOD U/ml	MDA μmol/L	CAT U/L
Control (Normal saline)	6.22 ± 0.51 B	7.15 ± 0.12 B	0.54 ± 0.05 B	7.13±0.24A
Dexamethasone (0.35 mg/kg B.W.)	4.56±0.48 C	3.69 ± 0.72 C	3.78±0.62 A	5.21 ±0.17 B
<i>Cyperus rotundus</i> (0.5 g/kg B.W.)	8.12 ± 0.73 A	8.34 ± 0.34 A	0.50 ± 0.09 B	7.79±0.52A
Dexamethasone + <i>Cyperus rotundus</i>	6.07 ± 0.48 B	6.89 ± 0.45 B	0.52 ± 0.01 B	7.05±0.11A

N=number of animals, A,B,C= differences between groups, P≤0.05 vs. control.

6- Dexamethasone and *Cyperus rotundus* on Urea, Uric acid and Creatinin of male rabbits.

In the Table [6] showed that effects of dexamethasone and *Cyperus rotundus* on urea, uric acid and creatinine are significant increases (P≤0.05) in group treated with dexamethasone compared with control group and *Cyperus rotundus* group while group treated with dexamethasone + *Cyperus rotundus* showed no significant urea, uric acid and creatinine compared with control group and *Cyperus rotundus* group.

Table 6 :-Effect of Dexamethasone and *Cyperus rotundus* on Urea, Uric acid and Creatinine of male rabbits. (Mean±SD) n=6

Parameters Treatments	Urea (mg/dl)	Uric acid (mg/dl)	Creatinine (mg/dl)
Control (Normal salin)	25.34 ± 2.90 B	1.35 ± 0.10 C	3.61 ± 0.89 C
Dexamethasone (0.35 mg/kg B.W.)	37.58 ± 2.67 A	2.59 ± 0.52 A	5.73 ± 1.96 A
<i>Cyperus rotundus</i> (0.5 g/kg B.W.)	25.19 ± 2.10 B	1.32 ± 0.15 C	3.50 ± 0.71 C
Dexamethasone + <i>Cyperus rotundus</i>	25.05 ± 1.12 B	1.95 ± 0.14 B	4.28 ± 1.24 B

N=number of animals, A,B,C= differences between groups, $P \leq 0.05$ vs. control.

7-Histological Examination.

7-1Pancreas:-

The pancreas of **control** rabbits appeared to be divided into two different types of glandular tissue, exocrine and endocrine, embedded between the exocrine units lie clusters of endocrine cells called pancreatic islets figure (3) normal of langerhan's islets while the pancreas of rabbit treated with **DEX** revealed histopathological changes. The changes included vacuolation and degeneration of langerhan's islets as shown in figure (4). But the pancreas of rabbits treated with *Cyperus rotundus* showed normal architecture of islets langerhan's figure (6). In addition to the pancreas of rabbits treated with **DEX+ Cyperus rotundus** showed amelioration of this section compared to pancreas treatment with **DEX** alone, clear langerhan's islets as shown in figure(7).

7-2Thyroid gland:

The thyroid gland of **control** group rabbits appeared normal thyroid tissue composed of thyroid follicles of varies size and filled with colloid and lined by cuboidal thyriocytes, parafollicular cells can be distinguished as shown in figure(8). In addition thyroid gland of rabbit treated with **DEX** revealed microfollicular hyperplasia and vacuolation of some follicle of colloid,

depletion of parafollicular cells as shown in figure(9). But the thyroid gland of rabbit treated with *Cyperus rotundus* appeared normal thyroid tissue as compared with control group as shown in figure(10).

thyroid gland of treated male rabbits with **DEX+ Cyperus rotundus**. Showing colloid-rich (C) uniform thyroid follicles are lined by a layer of cuboidal epithelial cells and arafollicular cells can be distinguished(11).

7-3Liver:-

The Liver of **control** group male rabbit appeared normal of hepatocyte (observed of radiation cellular structure), clear the central hepatic vein and observed of hepatic sinusoids figure (17) while the liver of male rabbit treated with **DEX** exhibited damage of hepatocyte (absent of radiation cellular structure), clear congestion of the central hepatic vein, absent of hepatic sinusoids and very clear fatty infiltration figure (18). But the liver of rabbits treated with *Cyperus rotundus* showed normal architecture of hepatocyte (observed of radiation cellular structure), clear the central hepatic vein, observed of hepatic sinusoids. In addition to the liver of rabbits treated with **DEX+ Cyperus rotundus** showed amelioration of this section compared to liver treatment with **DEX** alone,figure (19).

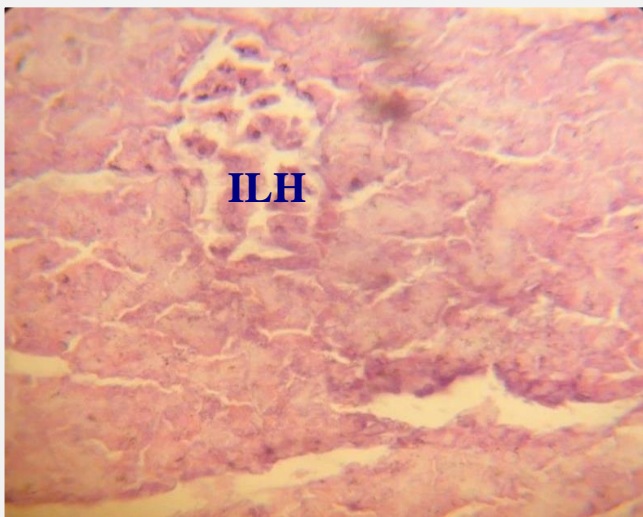

Fig.3:Section of pancreas of control male rabbits. Showing islet langerhans normal (ILH). E&H stain 400X.

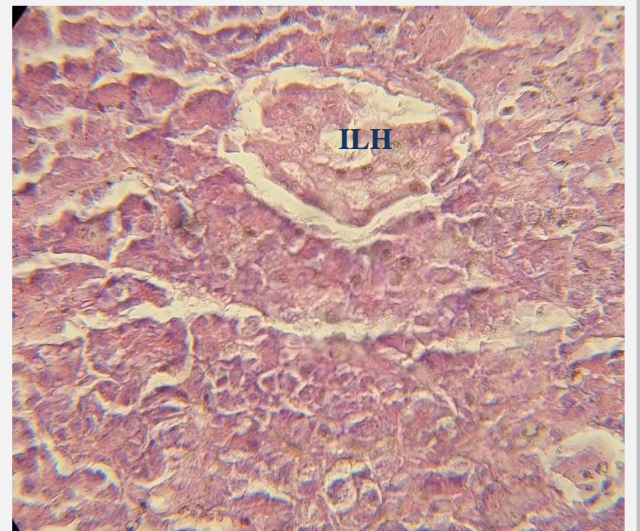


Fig.4:Section of pancreas of male rabbits treated with DEX. Showing vacuolation & degeneration (V&D) of

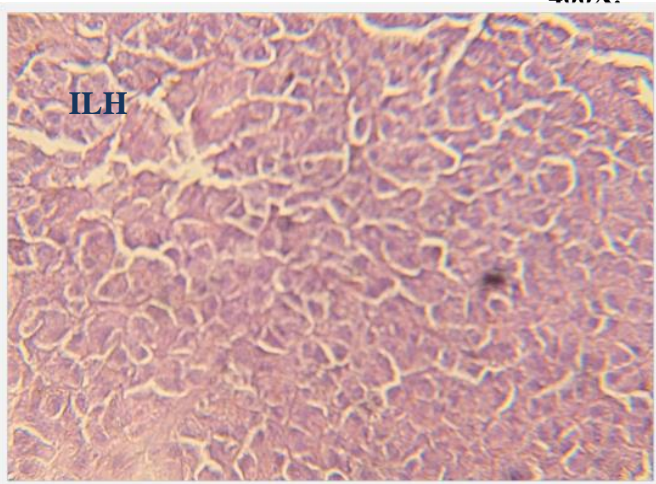


Fig.5:Section of pancreas of male rabbits treated with *Cyperus rotundus* alone. Showing normal of islets of langerhan's(ILH), stain(H&E) 400X.

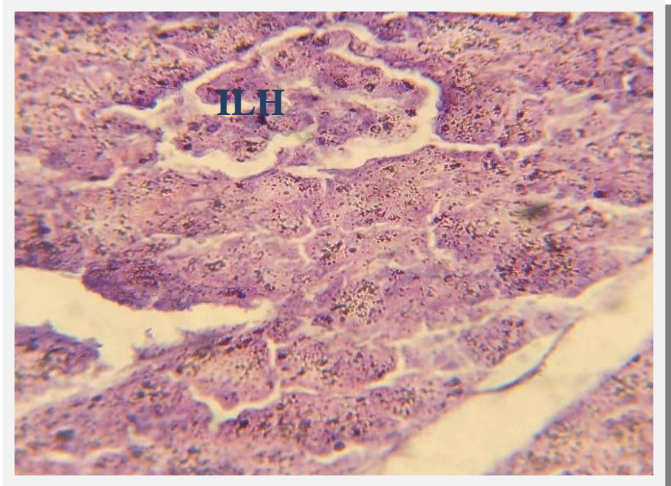


Fig.6:Section of pancreas of treated male rabbits with DEX+ *Cyperus rotundus*. Showing normal islet langerhans(ILH). E&H stain 400X.

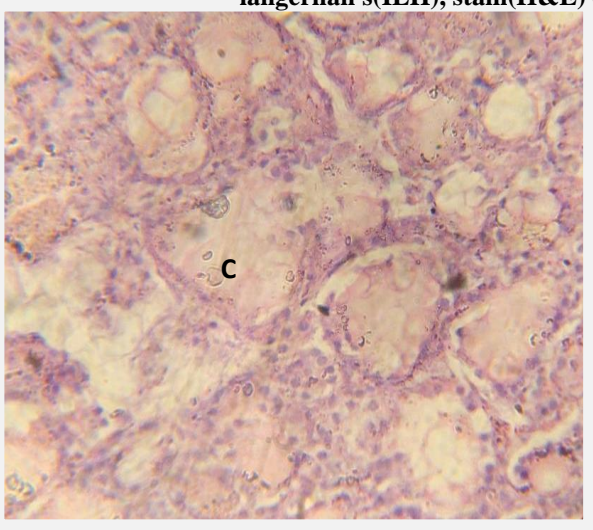


Fig7:Section thyroid gland control. Showing colloid-rich (C) uniform thyroid follicles are lined by a layer of cuboidal epithelial cells and

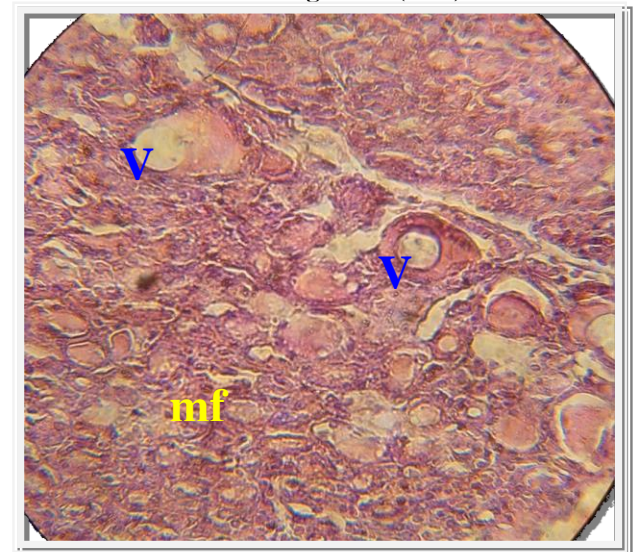

Fig.8:Section thyroid gland treatment DEX. Showing almost of follicles is microfollicles

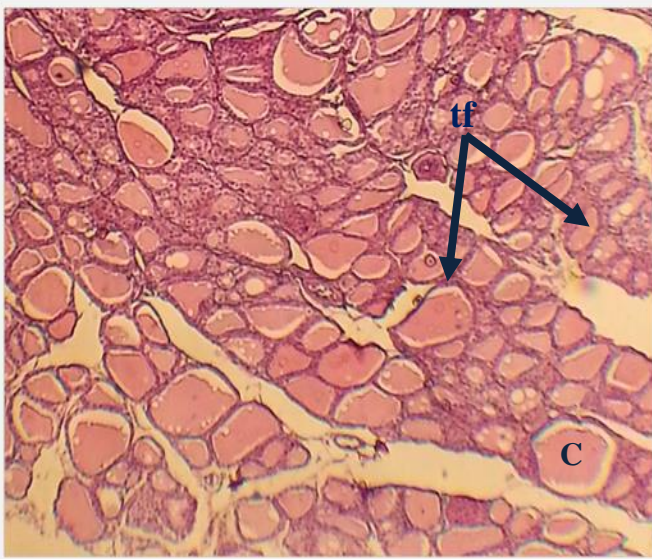


Fig.9: Section of thyroid gland of treated male rabbits with *Cyperus rotundus* alone. Showing colloid-rich (C) uniform thyroid follicles (tf) are lined by a layer of cuboidal epithelial cells and parafollicular cells can be distinguished. E&H stain. 100X.

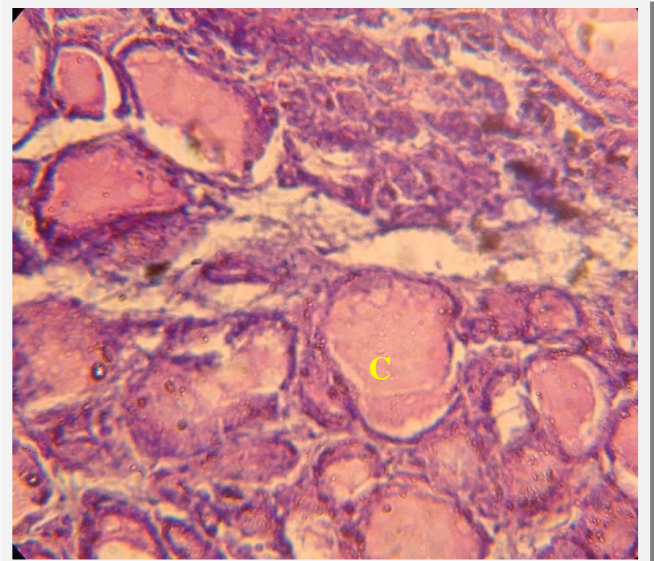


Fig.10: Section of thyroid gland of treated male rabbits with DEX+*Cyperus rotundus*. Showing colloid-rich (C) uniform thyroid follicles are lined by a layer of cuboidal epithelial cells and parafollicular cells can be distinguished. E&H stain. 400X.

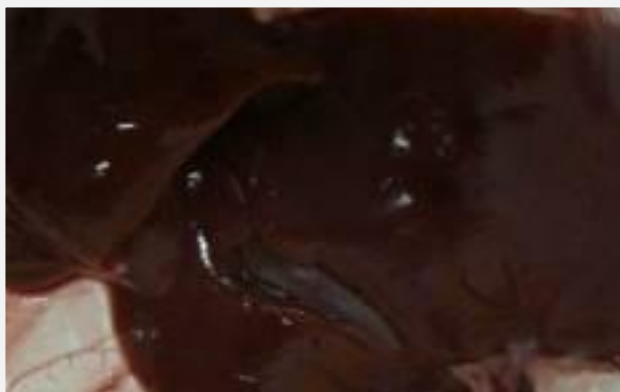

Fig.11: Gross of liver and gall bladder of male rabbits control.

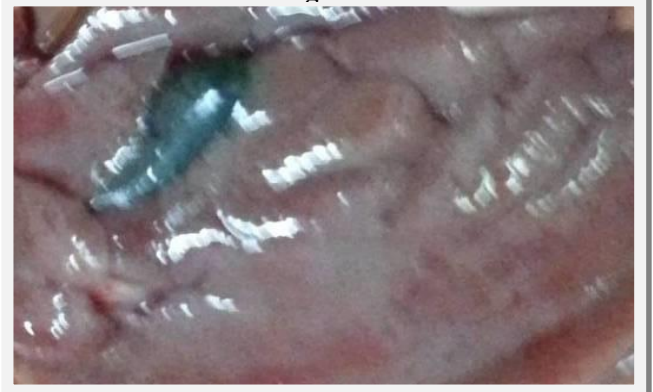

Fig.12: Gross appearance of liver and gall bladder of male rabbits treated with *Cyperus rotundus*. Showing normal liver and gall bladder.

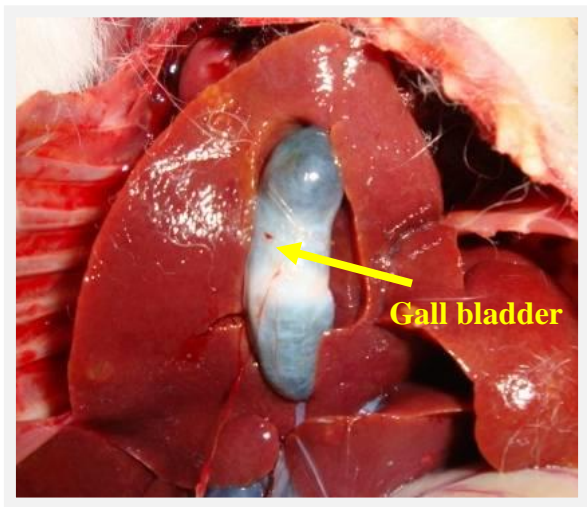


Fig.13 gross lesion of liver and fibroid of gall bladder treated with DEX. 111

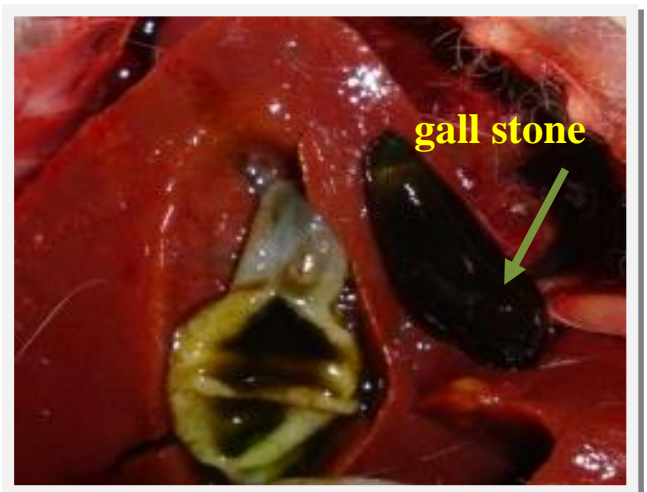

Fig.14 Gross lesion of gall bladder of male rabbits treated with DEX. Showing gall stone.

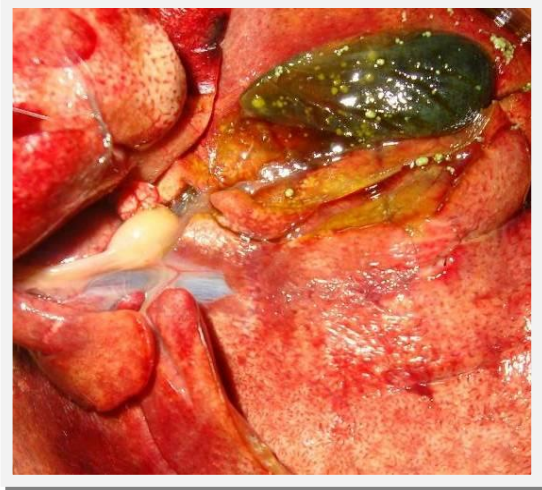

Fig.15 Gross lesion of gall bladder of male rabbits treated with DEX. Showing cholesterol crystal lead to gall stone.

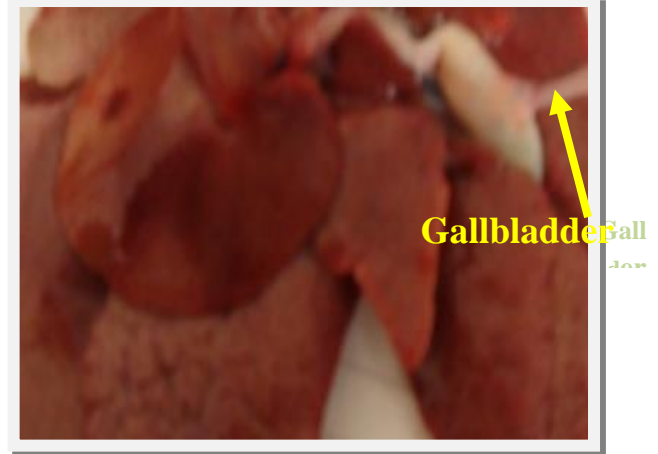

Fig.16: Gross lesion of gall bladder of male rabbits treated with DEX. Showing fibrosis of gallbladder.

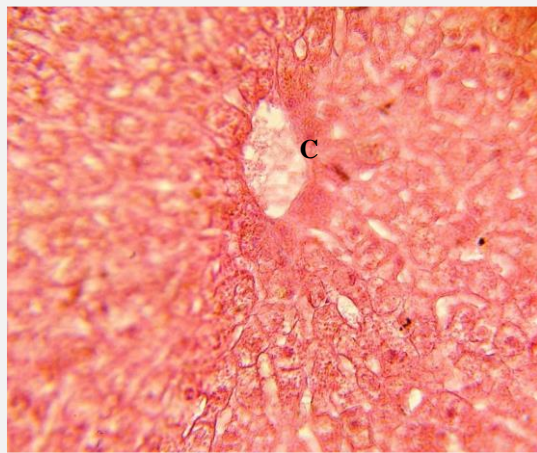


Fig 17 : Liver of male rabbit control. Showing normal of hepatocyte (observed of radiation cellular structure), clear the

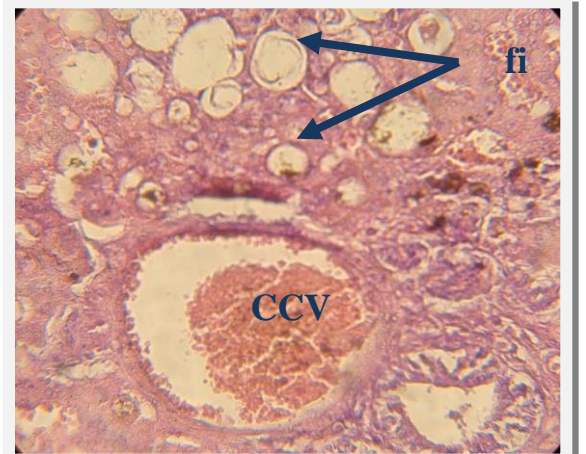


Fig18: Liver of male rabbit treated with DEX. Showing damage of hepatocyte (absent of radiation cellular structure), clear congestion of the central hepatic vein (CCV), absent of

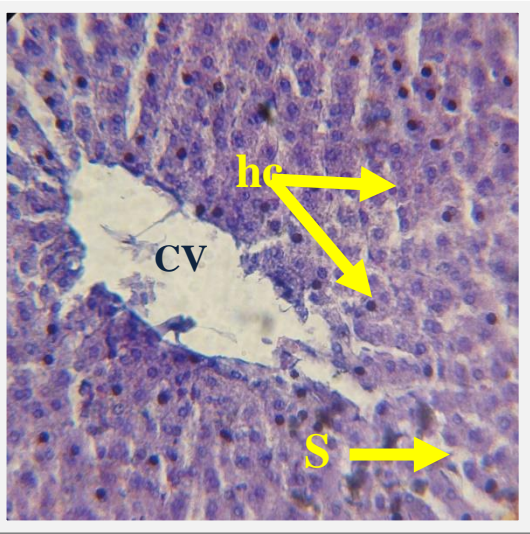


Fig 19: Liver of male rabbit treated with *Cyperus rotundus* alone. Showing normal of hepatocyte (hc) (observed of radiation cellular structure). clear the central hepatic

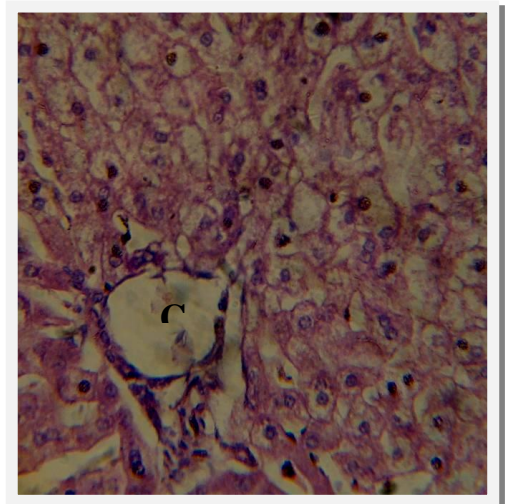


Fig 20: Liver of male rabbit treated with DEX+ *Cyperus rotundus*. Showing normal of hepatocyte (observed of radiation cellular structure). clear the central hepatic

Discussion

The decrease in the body weight gain may be attributed to the decrease in the thyroid hormones and zinc concentration in the serum of male rabbits treated with DEX. [11] stated that both thyroid hormones and zinc element play an important role in growth and The present study revealed development.

The hormones of the adrenal gland positively influence the glucose metabolism. In fact, when the adrenal gland remains hyperactive for a longer period, it always increases serum glucose level [12]. Interestingly, in the animals treated with both *Cyperus rotundus* and dexamethasone, nearly normal levels of fasting glucose was restored suggesting that the test extract may also ameliorate steroid induced type 2 diabetes mellitus. This appears to be a new observation. The dexamethasone-induced increase in the levels of both serum insulin and glucose indicating a state of insulin resistance as previously observed [13,14] was also reversed by *Cyperus rotundus* administration. This is in accordance with another report [15]. Because *Cyperus rotundus* in the present study could decrease the levels of both serum cholesterol and triglycerides in DEX-treated animals, as also observed in an earlier study [16], it should be expected that the decrease in insulin resistance might be the result of decreased level of lipid contents [17]. However, from the present findings, it also appears that the decreased concentrations of total cholesterol and triglycerides in the *Cyperus rotundus*-treated could also be a result of increased levels of thyroid hormones that are lipolytic in nature [18]. A marked increase in serum lipid peroxidation with a parallel decrease in antioxidants such as superoxide

dismutase, catalase and GSH was observed after DEX treatment, similar to our earlier findings [19]. However, these alterations were reversed with simultaneous administration of *Cyperus rotundus* suggesting the beneficial role of the extract with respect to liver function. Preventive treatment of *C. rotundus* extract significantly reduced the DEX induced elevated level of cholesterol triglycerides and LDL cholesterol. The treatment of rabbits with *C. rotundus* extracts significantly ($P < 0.05$) increased the HDL level in DEX induced decrease in HDL level. The extract was also active against hyperlipidemia; however, highest effect was observed which was near to normal. In another study administration of *C. rotundus* extract restored the age associated change in serum lipids (total cholesterol, LDL cholesterol, HDL cholesterol, triglycerides and VLDL triglyceride level) to the level of young control rats. In young rats, treatment of *C. rotundus* significantly increased HDL cholesterol level [20,21,22]. Free fatty acids liberated from adipose tissues. As peroxidation of membrane increase, phospholipids liberate free fatty acid by the action of the enzyme phospholipase A_2 . Ca^{2+} ions are important inducers of phospholipase A_2 , so the resulted increase in free fatty acid amount could have been due to the indirect effect of calcium level, which was reported to be changed in DEX-treatment. Hence, the significant increase was observed in the level of lipids in serum of DEX treated group of rabbits [23]. Prior administration of plant extracts significantly decreased the DEX induced elevated level of cholesterol. Treatment of different groups of rabbits with extracts of *C. rotundus* significantly blocked the DEX induced secretion of all enzymes

dose dependently. Extracts treatment has shown significant reduction in DEX-induced elevation in cholesterol, triglyceride and LDL and restored the HDL level. *C. rotundus* contained remarkable antioxidant compounds and showed antioxidant activity [24]. The decline in enzymes and lipids levels could be due to potential of extracts to repair and maintain the membrane due to antioxidant polyphenols. The DEX-induced increase in serum lipid peroxidation might be due to an increase in serum glucose concentration that might have provided an appropriate environment for oxidation of basement membrane lipids [25,26]. In fact, it has previously been suggested that glucose at higher concentrations exerts oxidative stress as indicated by increased serum lipid peroxidation, which is ameliorated by a reduction in its level [27-29]. It is also possible that the DEX-induced increase in lipid peroxidation could be a result of hyperlipidaemia because the dexamethasone induce gall stone [27]. This concept was further supported by the fact that high fat diet down-regulates the expression of the genes for the free radical scavenging enzymes [30]. From these possible reasons of DEX-induced alterations in lipid peroxidation system, we suggest that *Cyperus rotundus* might be exhibiting its protective role in the diabetic condition by reducing tissue lipid peroxidation and by enhancing superoxide dismutase, catalase and GSH. Observations on the changes in thyroid hormones revealed a hypothyroidic condition after dexamethasone administration as reported earlier [31,32], which was reversed after simultaneous administration with *Cyperus rotundus*. As decrease in serum lipid peroxidation and increase in

superoxide dismutase and catalase activities coincided with this elevation in thyroid hormones, it is quite possible that the toxic manifestation of dexamethasone might have been mediated through the alterations in thyroid hormones, which seems more justified because thyroid hormones are known to reduce tissue lipidperoxidation and increase the levels of natural antioxidants [33].

Of the two major circulating thyroid hormones, T_4 is synthesized only in the thyroid gland and the major amount of T_3 (80–90%) is produced by the peripheral conversion of T_4 primarily in hepatic tissues [34]. Because the levels of both thyroid hormones were increased in the present study, it seems that *Cyperus rotundus* regulates thyroid function both at the glandular level (the only source of T_4).

The obtained results revealed that a significant increase of uric acid, creatinine, urea concentrations in the serum of male rabbits treated with DEX. These results are attributed to deleterious effect of DEX on liver and kidney functions and these results is supported by histological findings of liver. Hypothyroidism leads to adverse effects in various tissues. The present cross-sectional study was performed to determine whether thyroid dysfunction has deleterious effects on renal function while when treatment with methanolic extract of *Cyperus rotundus* these parameters become near normal values.

The predominant liver abnormalities. The liver dysfunction usually presents with treatment of DEX, and can persist for several months despite discontinuation of the off ending drug. There is also evidence that hypothyroidism may directly affect the liver structure or function. Hypothyroidism is associated with

cholestatic jaundice attributed to elevation of bilirubin and reduction bile excretion. The results of gall bladder indicate these. Treatment with DEX lead to hyperglycemia, hypothyroidism and formation gall stone. In experimental hyperglycemia lead to hpothyroidism, the reduction in bile flow may be in part due to an increase in membrane cholesterol-phospholipid ratio and diminished membrane fluidity, which may affect a number of canalicular membrane transporters and enzymes, including the Na^+ , K^+ -ATPase. The hypercholesterolaemia and hypotonia of the gall bladder seen in treated with DEX increases the incidence of gallstones. When treated with *Cyperus rotundus* lead to improvement of glucose concentrations, lipid profile and bile flow.

Zinc (Zn) is an essential micronutrient which has an important role in the functioning of hundreds of enzymes [35], in insulin metabolism and acts as an efficient antioxidant [36.37]. Zn is considered important mainly because it plays a major role in the stabilization of insulin hexamers and the pancreatic storage of the hormone [38] and it is inefficient antioxidant[39],while oxidative stress is considered to be a main component in initiation and progression of insulin resistance and diabetes [40]. In dexamethazone treated group zinc concentration was significantly lower than the control group ($p < 0.05$). This result agreement with [41], [42]. They reported that corticosteroids lowered zinc by 30% to 40%, which persisted as long as the hormone continued to be administered.[41] also reported a gradual fall in serum zinc in cattle receiving i/v dexamethasone (2 mg) for 3 days. These results, however, do not agree with the observations of who

recorded that simulation of a stressing condition by a single injection of corticotropin did not affect serum zinc and even extending the duration of stress by giving four consecutive daily injections of corticotrophin did not statistically significantly change the serum zinc during 72 h injection period[11].

References

- 1- **Ganong, W.F.** Review of Medical Physiology, 22nd edn. Appleton & Lange, Connecticut, 2005.
- 2-**Su, X.; Hu, Q.; Kristan, J.M.; Costa,C.; Shen, Y.; Gero, D.; Matis, L.and Wang, Y.** Significant role for Fas in the pathogenesis of autoimmune diabetes. *J Immun.* 2000 ; 164: 2523-2532.
- 3-**Harris, M.** Descriptive epidemiology 1st edition chapter 1. National Institutes of Diabetes & Digestive and Kidney disease. 2007; P.p.:1-4.
- 4-**Hu, F.B., J.E. Manson, M.J. Stampfer, G. Colditz, S. Liu, C.G. Solomon and W.C. Willet,** Diet, lifestyle, and the risk of type 2 diabetes mellitus in women. *N. Engl. J. Med.*, 2001. 345:790–797.
- 5-**Schacke, H.; Docke, W.D. and Asadullah, K.** Mechanisms involved in the side effects of glucocorticoids. *Pharmacol Ther.*2002;96:23-43.
- 6-**Eid,Y.;Ebeid,T.; Moawad,M. and El-Habbak,M.** Reduction of Dexamethasone-induced oxidative stress and lipid peroxidation in laying Hens by dietary vitamin E supplementation. *Emir J Food Agric.* 2008; 20(2):28-40.

- 7- Langmead, L and Rampton, D.S.** Review article: herbal treatment in gastrointestinal and liver disease--benefits and dangers. *Aliment Pharmacol Ther.* 2001 Sep;15(9):1239-52.
- 8-Pal, D.K. and Dutta, S.** Evaluation of the antioxidant activity of the roots and Rhizomes of *Cyperus rotundus* L. *Indian J. Pharm. Sci.*, 2006. 68: 256-258.
- 9-Peterson, M.E.;Alszuler, N. and Nichols, C.E.** Decreased insulin sensitivity and glucose tolerance in spontaneous canine hyperadrenocorticism. *Res Vet Sci.* 1984;36:177-82.
- 10-SPSS Statistical Packages for the Social Sciences.** Statistical soft ware for windows version 13.0 Microsoft. SPSS®, Chicago, IL,USA.2007.
- 11-Henkin, R. I.** On the role of adrenocorticosteroids in the control of zinc and copper metabolism in man. In: Trace Elements Metabolism in Animals (Ed. W. G. Hoekstra, J. W.Suttie, H. E. Gonther and W. Me,1974.
- 12-Uddin, S.J.; Mondal, K.; Shilpi, J.A. and Rahman, M.T.** Antidiarrhoeal activity of *Cyperus rotundus*. *Fitoterapia*, 2006;77: 134-136
- 13-Severino, C.; Brizzi, P.; Solinas, A.; Secchi, G.; Maioli, M. and Tonolo G.** Low-dose dexamethasone in the rat: a model to study insulin resistance. *Am J Physiol Endocrinol Metab.* 2002; 283 :367-73.
- 14-Buckingham J.C.** Glucocorticoids: exemplars of multi-tasking. *Br J Pharmacol.* 2006;147 :S258-68.
- 15- Nishikant, A.; Raut, N.A. and Gaikwad, N.J.** Antidiabetic activity of hydro-ethanolic extract of *Cyperus rotundus* in alloxan induced diabetes in rats. *Fitoterapia.* 2006;77:585-8.
- 16-Kilani, S.; Ledauphin, J.; Bouhleb, I.; Ben Sghaier, M.; Boubaker, J. and Skandrani, I.** Comparative Study of *Cyperus Rotundus* Essential Oil by a Modified GC/MS Analysis Method. Evaluation of Its Antioxidant, Cytotoxic and Apoptotic Effects. *Chem Biodivers* 2008;5(5):729-42.
- 17-Yazdanparast, R. and Ardestani, A.** In Vitro Antioxidant and Free Radical Scavenging Activity of *Cyperus Rotundus*. *J Med Food* 2007;10(4):667-74.
- 18-Bartosikova, L.; Necas, J.; Suchy, V.;Kubinova, R.; Vesela, D.; Benes,L.; Bartosik, Illek, J.; Salphachta,J.; Klusakova, J.; Bartosova, L.;Starnadova, V.; Frana, P. and Franova, J.** Monitoring of antioxidative effect of morine in alloxan induced diabetes mellitus in laboratoer rat. *Acta.Vet.Brno.* 2003 ;(72): 191-200.
- 19-Nagulendran, K. R.; Mahesh, R. and Begum, V. H.** Preventive role of *Cyperus rotundus* rhizomes extract on age associated changes in glucose and lipids, *Pharmacologyonline*,2007,2, 318-325
- 20-Mehta, R. S.; Shankar, M. B.; Geetha, M.; Saluja, A. K.** Hepatoprotective effect of *Cyperus*

rotundus on paracetamol and rifampicin induced enzyme activity. *Indian J Natur Prod.* 2006; 1392-1657.

21-Chandratre, R. S.; Chandarana S., and Mengi, S. A. Lipid lowering activity of alcoholic extract of *Cyperus rotundus*. *IJRPC.* 2011, 1(4) : 2231-2781.

22- Severino, C.; Brizzi, P.; Solinas, A.; Secchi, G.; Maioli, M. and Tonolo, G. Low-dose dexamethasone in the rat: a model to study insulin resistance. *Am J Physiol Endocrinol Metab* 2002; **283**:367–73.

23-Nagulendran, H.R.; Velavan, S. Mahesh, R. and Begum, V.H. *In vitro* antioxidant activity and total polyphenolic contents of *Cyprus rotundus* rhizomes. *European J. Chem.*, 2007;4: 440–449

24-Szkudelski, T. The mechanism of alloxan and streptozotocin action in B cells of the rat pancreas. *Physiol Res* 2001; **50** :536–46.

25-Rungby, J.; Flyvbjerg, A.; Andersen, H.B. and Nyborg, K. Lipid peroxidation in early experimental diabetes in rats: effects of diabetes and insulin. *Acta Endocrinol* (Copenh) 1992; **126**:378–80.

26- Broderick, T.L., 2008. ATP Production and TCA activity are stimulated by propionyl-L-carnitine in the diabetic rat heart. *Drugs R.D.*, 9: 83-91.

27-Sreekumar, R.; Unnikrishnan, J. and Fu, A. Impact of high-fat diet and antioxidant supplement on mitochondrial functions and gene

transcripts in rat muscle. *Am J Physiol Endo. Metab* 2002; **282** :E1055–61.

28-Tiwari, A.K. Antioxidants: New-generation therapeutic base for treatment of polygenic disorders. *Curr Sci* 2004; **86** :1092–102.

29- Thompson,M.D.;Gallagher,W.J.;Ala izzo,P. and Lanier,W.L. The effect of chronic dexamethasone-induced hyperglycemia and its acute treatment with insulin on brain glucose and glycogen concentrations in rats. *Anthesio.* 2000; 93(5):127-84.

30-Rhee,S.J.; Choe,W.K. and Ha,T.Y. The effect of vitamin E on the antioxidative defense mechanism in streptozotocin-induced diabetic rats. *Nippon Eiyo Shokuryou Gakkaishi. J Jap Soci Nutri and FS.* 1995; 48:451-7.

31-Cameron-Smith,D.;Habito,R.; Barnett,M. and Collier,G.R. Dietary guar gum improves insulin sensitivity in streptozotocin induced diabetic rats. *J Nutri.* 1997; 127: 359-64.

32-Haase, H.; Overbeck, S. and Rink, L. Zinc supplementation for the treatment or prevention of disease: current status and future perspectives. *Exp Gerontol.*2008; 43:394-408.

33-Faure, P.; Lafond, J.L.; Coudray, C.; Rossini, E., Halimi, S. and Favier, A.(1994): Zinc prevents the structural and functional properties of free radical treated insulin. *Biochim Biophys Acta* , 1209:260-264.

34-Saper, R.B. and Rash, R.(2009): Zinc: an essential micronutrient. *Am Fam Physician*,79:768-772. 73. Wijesekara N, Chimienti F, Wheeler

MB: Zinc, a regulator of islet function and glucose homeostasis. *Diabetes Obes Metab* , 11(Suppl 4):202-214.

35-Prasad, A.S.(2008): Clinical, immunological, anti-inflammatory and antioxidant roles of zinc. *Exp Gerontol* , 43:370-377.

36-Wiernsperger, N.F. Oxidative stress as a therapeutic target in diabetes:revisiting the controversy. *Diabetes Metab* , 29:579-585.

37-Murry, R.K.; Granner, D.K.; Mayes, P.A. and Rodwell, V.W. *Harpers Biochemistry*. 24th ed. Appleton & Long <http://www.ncbi.nlm.nih.gov/pubmed/18054190?dopt=Abstract> e, London 1996;612-613.

38-Weeks, B. R., J. E. Smith, R. M. DeBower and J. M. Smith. Decreased serum iron and zinc concentration in

cattle receiving intravenous dexamethasone. *Vet. Pathol.* 1989; 26(4):345-346.

39-Wegner, T. N., D. E. Ray, C. D. Lox and G. H. Stott. Effect of stress on serum zinc and plasma corticoids in dairy cattle. *J. Dairy Sci.* 1973; 56(6):748-752.

40-Vallee, B. L. and Falchuk, K. H. The biochemical basis of zinc physiology. *Physiol. Rev.* 1993;73(1):92.

41-Falchuk, K. H. Effect of acute disease and ACTH on serum zinc proteins. *N. Engl. J. Med.* 1977; 269:1129-1134.

42-Flynn, A., W. J. Pories, W. H. Strain, O. A. Hill and R. B. Fratianne. Rapid serum zinc depletion associated with corticosteroid therapy. *The Lancet.* 1971. 27:1169.