

PROMINENT EAR CORRECTION BY TWO PARALLEL INTERRUPTED FULL THICKNESS CARTILAGE INCISION LINES

Mohammed Breesam Hatif[@], Arwa Kasim* and Jabir R Hameed[#]

[@] MB,ChB, FICMS, Consultant Plastic & Reconstructive Surgeon, Al-Wasity Plastic and Reconstructive Surgery Teaching Hospital, Baghdad. * MB,ChB, FICMS, Plastic & Reconstructive Surgeon, Al-Karama General Teaching Hospital in Baghdad. [#] MB,ChB, FICMS, Consultant Plastic and Reconstructive Surgeon, Al-Sadir Teaching Hospital, Basrah, IRAQ.

Abstract

Prominent ear is the most common congenital ear deformity affecting 5% of children in western world and has profound psychological effects on the bearer. The most common causes of protruded external ear are: an under developed or flat antihelix, an over developed deep concha, or combination of both of these features.

The aim of this study is to evaluate clinical outcome of otoplasty in prominent ears by two parallel interrupted full thickness cartilage incisions.

from February 2015 to November 2018, a prospective study accomplished on 40 patients (74 ears), they were 32 males and 8 females. The condition was bilateral in 34 patients and unilateral in 6 patients. Surgery was done by a modification of combined methods of Mustarde and Furnas with partial resection of conchal cartilage .

The preoperative helical rim, temporo-mastoid surface distance was 28-40 millimeters (mean 34.6 mm) and 10-15 mm postoperatively (mean 12.1 mm). The preoperative cephalo-auricular angle was 50-90 degrees (mean 75.4 degrees), and was kept at 20-25 degrees (mean 22.5 degrees) postoperatively.

Good esthetic and satisfaction results were noted by the patients, their families, and the surgical staff. No complication had occurred and no one needed surgical revision.

In conclusion, the procedure was found to be simple, easily applied with good esthetic and satisfaction results.

Key words: Prominent ear, Correction, Satisfaction, Cartilage, Incision lines

Introduction

Prominent ear is a common congenital deformity and may be a source of psychological distress in both sexes and at any age. It is seen at any age in 5% of Caucasian and has an autosomal dominant heritage pattern¹⁻³. Prominent ears are characterized by the following changes; Deletion or absence of antihelix with scapho-conchal angle of >90 degrees, excessively deep or hyperdeveloped shell with increased cephalo-auricular angle of >40 degrees, and protrusion of the ear lobe. Combination of the above is the

commonest finding⁴. More than 200 techniques have been suggested for surgical correction of the prominent ear with no consensus exists regarding the best technique, therefore new techniques and modifications continue to be developed⁴.

Otoplasty techniques can be divided into three broad categories: Cartilage-cutting, cartilage-sparing, and incisionless techniques⁵. The goals of otoplasty should be to create individually normal appearing auricles by maintaining the angle between the mastoid plane and the

upper helical rim at less than 40 degrees and a distance from the helical rim to the skull of 15-20 mm with creating symmetry between the two auricles⁶.

Patients and methods

From February 2015 to November 2018, a prospective study was accomplished in

Al-Wasity Plastic and Reconstructive Surgery Teaching Hospital and Al-Karama General Teaching Hospital in Baghdad, Iraq, on 40 patients (32 males and 8 females) (74 ears), with prominent ear deformities which had been measured at the outer most point of the ear rim at the most prominent part. Data are shown in table I.

Table I: Demographic data of the patients

Variables	Number of patients	Percentage
Age:		
Children up to 18 years	28	70%
Adults	12	30%
Gender :		
Males	32	80%
Females	8	20%
Bilaterally affected ears	34	85%
Right ear alone	5	12.5%
Left ear alone	1	2.5%
Preoperative cephaloauricular distance	28-40 mm (mean 34.6 mm)	
Preoperative cephaloauricular angle	50-90 degrees (mean 75.4 degrees)	

In this study we applied a modification of Mustarde technique to correct the prominent ears by two parallel full thickness cartilage incision lines, in addition to conchal elliptic excision as needed, and correction of the prominent ear lobe as required⁷.

A preoperative laboratory, medical and anaesthesiological consultation and evaluation were done to ascertain fitness of the patients to surgery under general anaesthesia.

Evaluation of the ear deformity (the site, severity, and etiology) of the prominence of the ears was completed, also assessment of the expectation of the patient and his family from the surgical correction was discussed.

Surgical procedure steps: With the patient in supine position, preparation of the ear and surrounding area with 10% povidone iodine solution was done. Planning and marking with gentian violet solution and needle tattooing to delineate the proposed antihelix and the skin ellipse that will be

excised. Local infiltration of the posterior aspect of the ear and the post auricular sulcus with 2% xylocaine and 1/200000 adrenalin solution. Then two parallel interrupted incision lines 3-5 millimeters in length on both sides of the supposed antihelix line, of 3-5 mm apart and 3-5 mm gaps between each incision line and the other was performed. Incisions involved full thickness of the cartilage and the scalpel can be felt by finger on the anterior skin surface of the ear. Nylon 4/0 mattress sutures was used with folding the cartilage by fingers of the assistant anteriorly create the wanted fold of the new antihelix as recommended by Mustarde, usually 3-4 mattress sutures were needed for each antihelix.

This technique has enabled us to get an easy and smooth bending and folding of cartilage resulting in a fine and nice antihelical fold.

Conchal hypertrophy and its severity was assessed preoperatively for marking a suitable amount of cartilage to be

resected enough for further correct the prominence with mattress suturing of the edges with 4/0 Nylon by about 2-3 sutures usually, after limited undermining of the skin from the cartilage anteriorly and using the same ends of the sutures to fix it to the periosteum of the mastoid as recommended by Furnas. Closure of the wound was completed with subcutaneous 4/0 Polyglactin (vicryl) followed by 4/0 Nylon sutures for the skin as interrupted or continuous intra-dermal suture. Correction of the ear lobe was done by the suitable technique of excision and closure. Fucidin skin ointment was

applied to the wound, followed by dressing with dry gauze, cotton, and crepe bandage of the ears and head. Figure 1 showed the technique used in this study.

The patient was discharged at the same day of surgery to be seen every 3-4 days later to assess the operation site and change dressings. The stitches were usually removed 10-14 days post-operatively, and the patient was kept on crepe bandage for about one month. After that, the patient was instructed to use elastic bands or crepe bandage at night for another month, and to be seen in 6 months and one year postoperatively or as needed.

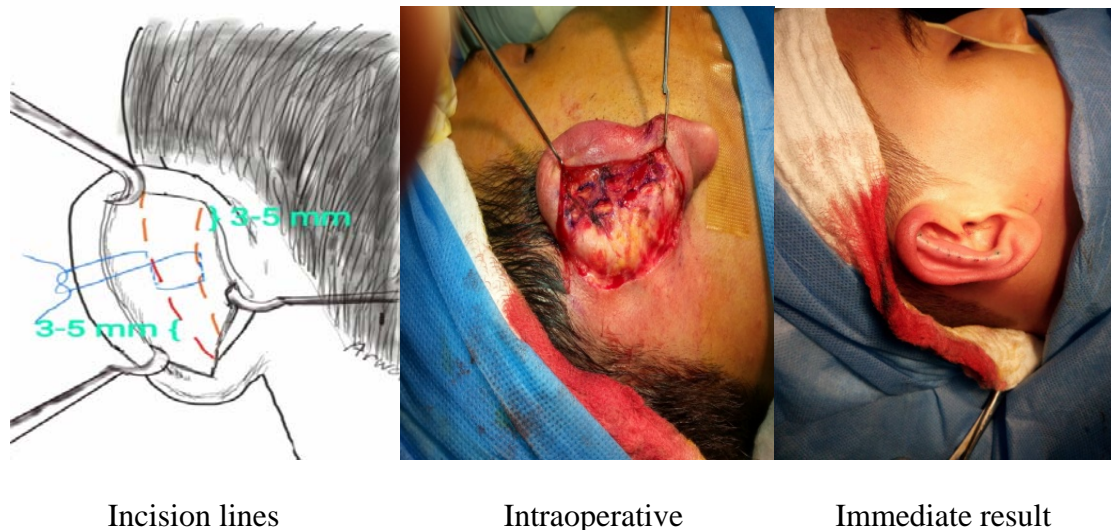


Figure 1: The technique used in this study

Results

In the total of 40 patients (74 ears) with prominent ears; preoperative ear protrusion distance from the mastoid which was 28-40 mm (mean 34.6 mm) is changed to 10-15 mm (mean 12.1 mm) postoperatively.

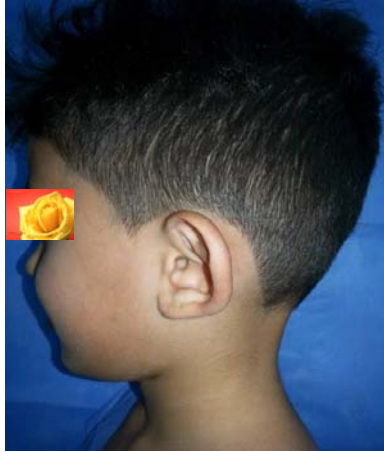Preoperative cephalo-auricular angle was 50-90 degrees (mean 75.4 degrees) and now is 20-25 degrees (mean 22.5 degrees) postoperatively as demonstrated in table II.

Table II: The results of postoperative measurements changes.

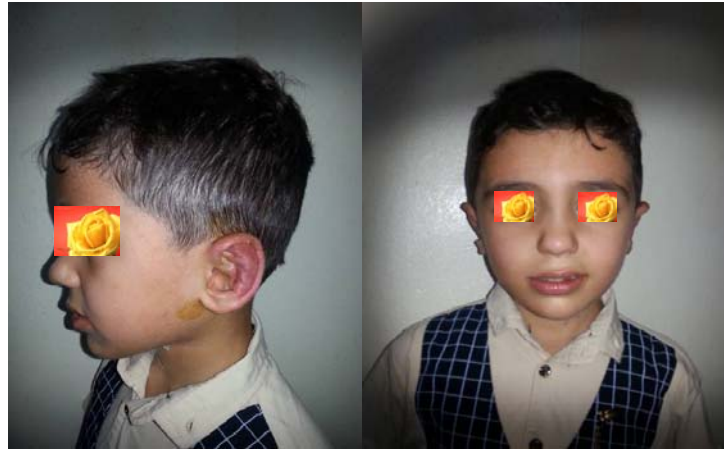	Preoperative measurements	Postoperative measurements
Ear protrusion distance	28-40 mm (mean 34.6 mm)	10-15 mm (mean 12.1)
Cephalo-auricular angle	50-90° (mean 75.4°)	20-25° (mean 22.5°)
Total no. of ears	74 ears	74 ears

No complications such as hematoma, infection, wound dehiscence, inadequate correction, recurrence or hypertrophic scars had been met. One patient asked for a mild limited upper pole correction of one ear which was not needed and we offered only reassurance.

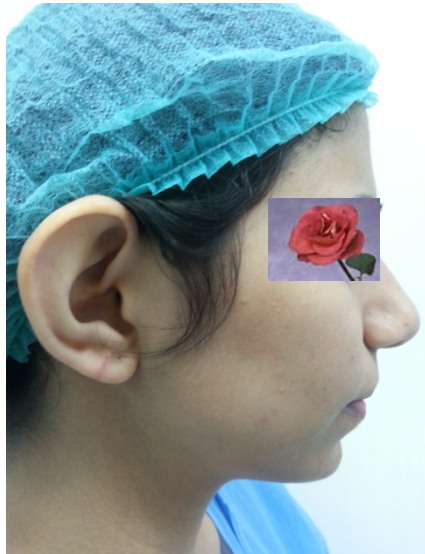One patient was concerned about intra-conchal skin folding at the first change of dressing which was fading with time. Good satisfaction and expression of happiness of the patients and their families and no patient needed surgical revision.



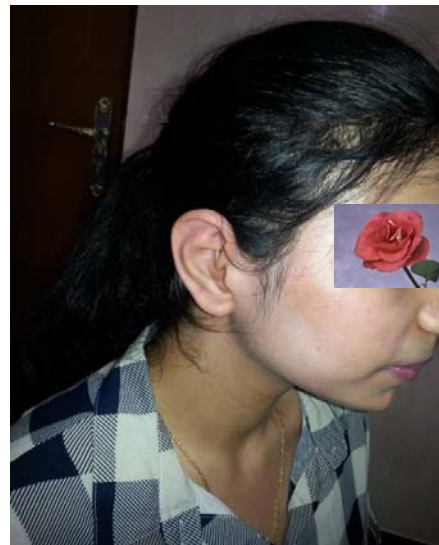Preoperative



Three days post operatively



Preoperatively



27 days post operatively

Discussion

Surgical techniques are always aiming at more natural-looking and lasting results. The ideal results are ears with certain symmetry that do not appear to have undergone surgery⁸⁻¹⁰. Because of the numerous problems leading to protruding ear, no appropriate single procedure has

been described for correcting all deformities¹¹.

The three most common causes of prominent ears (underdeveloped antihelical fold, prominent concha, protruding ear lobe) were found altogether in all cases of this study; they

were corrected simultaneously, by combination of different procedures to achieve the pleasant appearance, satisfying the patient, his family.

We corrected the cephalo-auricular distance and the concho-scaphal angles as well as the protrusion of the ear lobe simultaneously as mentioned by Olivera by application of a modification of Mustarde technique¹².

The postoperative cephalo-auricular distance was 10-15 mm (mean 12.1 mm) which coincides with the results obtained by multiple studies^{6,13-16}.

The post operative cephalo-auricular angle was 20-25 degrees (mean 22.5 degrees) which is consistent with the results achieved by different studies^{6,12-15}.

No complications such as; hematoma, infection, wound dehiscence, skin necrosis, hypertrophic or keloid scars, or recurrence have been met in this study

which have been found to occur with wide range of incidence in different studies^{8,11,17-20}.

The vast majority of patients and their families were satisfied with the results, since they gained accepted and pleasing ear position and configuration (except for two patients who were worried about mild upper pole protrusion and mild anterior conchal skin folding respectively, to whom only reassurance and encouragement was offered. These results were found to coincides with many other studies performed by many authors^{8,11,21,22}.

Conclusion: This approach of otoplasty for prominent ear correction has found to be safe, easily applied, and produce very good results and a fine and nice antihelical fold with natural looking ears, in addition to a good patient and family satisfaction.

References

1. Maslanskas K., Astranskas T. Comparison of Otoplasty outcomes using different types of suture materials. *Int.Surg.* 2010; 95:88-93.
2. Janis J.E., Rohrich R.J. Otoplasty. *Plast. Reconstr.Surg.* 2005;115:60-72.
3. Adamson P.A., Strecker H.D. Otoplasty techniques. *Facial Plast.Surg.* 1995;11:284-300.
4. Ernani Coelho Alencar. Brazilian Journal of plastic surgery. Artigo original-Ano 2015-vol.30.Numero 3.
5. Ozturan O., Dogun R. Percutaneous adjustable closed otoplasty for prominent ear deformity. *J.Craniofacial Surg.* 2013;24:398-404.
6. Strychowsky J.E., Moitri M. Incisionless otoplasty: A retrospective review and outcomes analysis. *Int.J.Pediatr.Otorhinolaryngol.* 2013;77:1123-7.
7. Mustarde J.C. The correction of prominent ears using simple mattress sutures. *Br. J. Plast. Surg.* 1963. Apr;16:170-178.
8. Calder J.C. Naasan A. Morbidity of otoplasty: A review of 562 consecutive cases. *Br.J.Plast.Surg.* 1994;47(3):170-174.
9. Ferreira L.M. Deformidades auriculares. In: *Manual Cirurgia Plastica.* Sao Paulo:Athena;1995;p.223-228.
10. Aygit A.C. Molding the ears after anterior scoring and concha repositioning. Combined approach for protruding ear correction. *Aesthetic Plast. Surg.* 2003 Jan-Feb;27(1):77-81.
11. Yugueros P, Friedland J.A. Otoplasty. The experience of 100 consecutive patients. *Plast.Reconstr.Surg.* 2001;108:1045-1053.
12. Francisco DE Olivera. Correction of prom. ears by cartilage non incision technique, definition of the antihelical with Mustarde sutures and fixation of the ear cartilage at the mastoid. *Rev.Bras.Cir.Plást.* 2011;26(4):602-607.
13. Erkan Yuce, Ali Can Gunenc. Surgical treatment of prominent ear: 5 year clinical experience in 108 patients.; *Turkish journal of plastic surgery.* 2017;25(1):12-9.
14. Mallen R.W. Otoplasty. *Can.J. Otolaryngol.* 1974;3: 74.
15. Adamson J.E, Horton C.E. The growth pattern of the external ear. *Plast. Reconstr. Surg.* 1965;36:466-470.
16. Wodak E. On the position and shape of the human auricle. *Arch.Klin.Exp.Ohren Nasen. Kehl kopfheilkd.* 1967;188:331-335.
17. S.L.A. Jeffery. Complications following correction of prominent ears: An audit review of 122 cases. Department of plastic surgery, The Queen Victoria Hospital, East Grinstead, UK. 28 Sep. 1998.
18. Kakrinn Anesti. Otoplasty Morbidity. *Modern Plastic Surgery.* 2013,3:28-33.
19. Felipe Yargas Borges. Complications of Otoplasty Surgeries. *Artigo Original-Anno 2016-Vol. 31-Numero 2 .*
20. Aki et al Coplcoes em Otoplastia: revisuo de 508 casos. *Rev.Bras.Cir.Plást.* 2006;21(3):140-144.
21. C.Bermneller. Quality of life and patient satisfaction after otoplasty. *European Arch.of Otolaryngol.* Nov.2012, Vol.269, Issue 11, PP. 2423-2431.
22. Murat Songu. Otoplasty in children younger than 5 years of age. *Otolaryngology.* Vol.74; Issue 3, March 2010 pp.292-296.