

The Value of Ultrasound in Diagnosing Acute Appendicitis

***Dr. Baha'a Mushref Abdulsalam**

Department of Surgery, College of Medicine, University of Anbar, Anbar, Iraq

Received 14/2/2012 Accepted 23/5/2012

Abstract

Acute appendicitis considered one of the causes of acute abdomen. The diagnosis is usually straight forward in typical cases, but this is not true in atypical cases. This study is to assess the value of ultrasound modality in diagnosing acute appendicitis. From January 2009 to January 2012 in Al-Ramadi teaching hospital, 196 patients were included in this study, 10 patients were excluded, and 186 examined by ultrasound, after adequate clinical assessment, for their signs and symptoms that suggestive of acute appendicitis. Age groups were 6-75 years, Mean age 33.5 years, with 105(54%) males, and 91(46%) females. 186 patients could be explained, and examined by ultrasound, with mean age of 33.5 years, the diagnosis had established in 34 patients. The false positive was three cases, and false negative was six cases, this means that the ultrasound had failed in these nine cases. The sensitivity is 81.8%, the specificity is 98%. 90% and 96.2% are the positive and negative predictive values respectively. The diagnostic accuracy is 95.5%. The P-value is <0.01. The ultrasound is a valuable tool of investigating patients with suspected acute appendicitis, alongside with proper physical examination.

Key words: *Acute appendicitis, Acute abdomen, ultrasonography.*

Introduction

Acute appendicitis is one of the most common causes of acute abdomen that required urgent surgical intervention in both adults and children [1,2]. It is easy to diagnose typical cases of this disease, but some times we face a great difficulty in diagnosing atypical cases. The obesity, excessive bowel gases, sever pain and tenderness, as well as pregnancy and childhood, were making the ultrasound examination some-how difficult. The removal of normal appendix is not a benign procedure and negative appendectomy carries a definitive morbidity[7]. Now a day many other authors recommend conservative treatment for catarrhal appendicitis, while surgery is needed for phlegmonous or more advanced appendicitis[8,9]. Early diagnosis of appendicitis is still a challenge [10].Diagnosis by the emergency physician (EP) remains challenging, because clinical evaluation alone yields sensitivity of 39-74% and specificity of 57-84%[11]. During the last decade ,use of white blood cell scans and ultrasound and computerized tomography (CT) scanning have improved the diagnostic accuracy for acute appendicitis [12,13]. The primary criterion for ultrasound diagnosis of appendicitis is a non-compressible, 6 mm, blind-ended, tubular structure at the base of the cecum without evidence of peristalsis[10]. Secondary signs include peri-appendiceal fluid collections, visible appendicolith, and interruption of the echogenic submucosa (indicating perforation)[11]. In contrary, an ovoid shape in the transverse plane along the entire length of appendix reliably excludes appendicitis[12]. Despite the use of ultrasound and special laboratory investigations (e.g.C-reactive protein), high diagnostic error

rates are still observed [13]. In spite of that , in many centers now a day they still use the ultrasonography as an initial modality for investigation [14,15,16,17,18,19,20]. In this study I shall assesses the value of ultrasonography in the diagnosis of AA.

Material and Method

From January 2009 to January of 2012 , and in Al-Ramadi teaching hospital, 196 patients,[aged range was 6-75 years with a mean of 33.5 years, 105(54%)males and 91(46%) females], where examined by ultrasound for signs and symptoms of acute abdomen , with professional diagnosis of acute appendicitis . All the referral doctors were a Known experienced surgeons or infrequently by physician. The ultrasound unit used was a semins /versa pro/model 1997, with linear probe of 7.5MHz that mainly used , although some times a curved probe with 3.5MHz used depending on the patients physique and the depth of appendix. The examination of appendix by ultrasound is made by uniform , continues pressure with ultrasound probe at the point of maximal tenderness in right iliac fossa to displace the air from intestinal loops, and to minimize pain caused to the patient. The criteria used to diagnose acute appendicitis were, the visualization of blind end, aperstaltic, non-compressible tubular structure with a diameter of more than 6mm, see figure(1), the appearance of appendicolith, see figure (2), , and/or the appearance of the inflamed perienteric fat or phlegmon, see figure (3), . The final diagnosis depend on the comparing the ultrasound finding with the histopathological finding, with exception of these cases of perforated appendix, for which the surgical

findings were taken into consideration. For non surgical cases a clinical-radiological follow up was made.

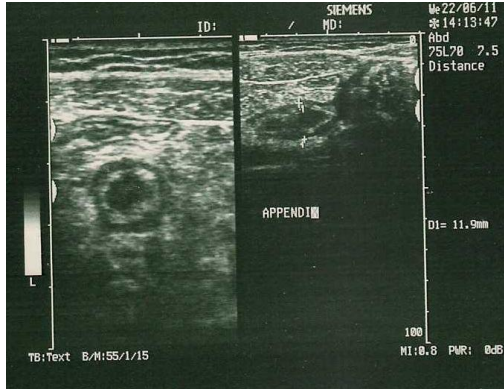


Figure (1):- Inflamed appendix with positive target sign.

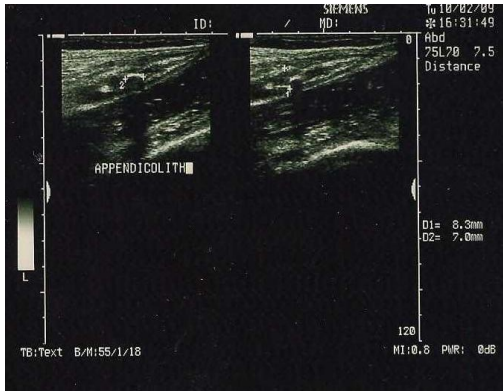


Figure (2):- Appendicolith.

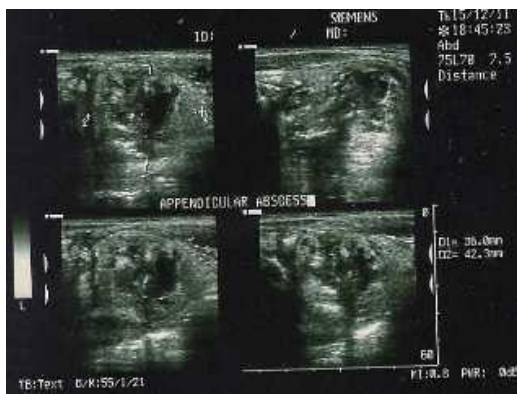


Figure (3):- Perforated appendix, phlegmon.

Results

10 patients, from the 196 chosed sample, were excluded from the results due to in ability to perform an adequate ultrasound examination, caused by obesity or excessive bowel gases. The remaining 186 patients, with a mean age of 33.5 years, were assessed clinically and ultrasounographically with final diagnosis, as seen in table-1. The more frequent diagnosis was a non-specific abdominal pain accounting about 125(67%) patients. Variables were compiled in Excel tables and analyzed and processed via the windows SPSS program version 17.o . Discrete variables were described using absolute frequencies and continuous variables as means and standard deviations. The X2 test(or Fisher exact test in calculated values under 5). Statistical significance was set at $p<0.05$.The results of ultrasound performance were, see table 2, as follow: 81.8% sensitivity, 98% specificity, 90% positive predictive value, 96.2% negative predictive value, with a diagnostic accuracy of 95.5%. From all the cases diagnosed by ultrasound as an acute appendicitis, see figure (4), Three cases were subsequently proved to be other, and the final diagnosis was, a non- specific abdominal pain in one case, acute gastroenteritis in other two cases. 6 cases was falsely diagnosed by ultrasound as a not cases of appendicitis, were showed a totally normal ultrasound exploration. There is a significant relation-ship between the histo-pathological examination and the ultrasound finding, and as proved statistically where P-value= <0.01 .

Diagnosis	No. of Patients	Percentage
Non specific abdominal pain	125	67%
Appendicitis	34	18%
Gastrointestinal disorders	16	9%
Gynecological disorders	5	3%
Others	6	3%

Table.1 Clinical-Ultrasound diagnosis for the 186 patients involved in the study.

		Clinical/histological end diagnosis		
		Appendicitis	Non-Appendicitis	Total
Ultrasound diagnosis	Appendicitis	27	3	30
	Non-Appendicitis	6	150	156
	Total	33	153	186

Sensitivity $27/33=0.82$
 Specificity $150/153=0.98$
 Positive predictive value $27/30=0.9$
 Negative predictive value $150/156=0.96$
 Diagnostic accuracy $27+150/186=0.95$

Table 2. The sensitivity, specificity, positive, and negative predictive values as well as the diagnostic accuracy.

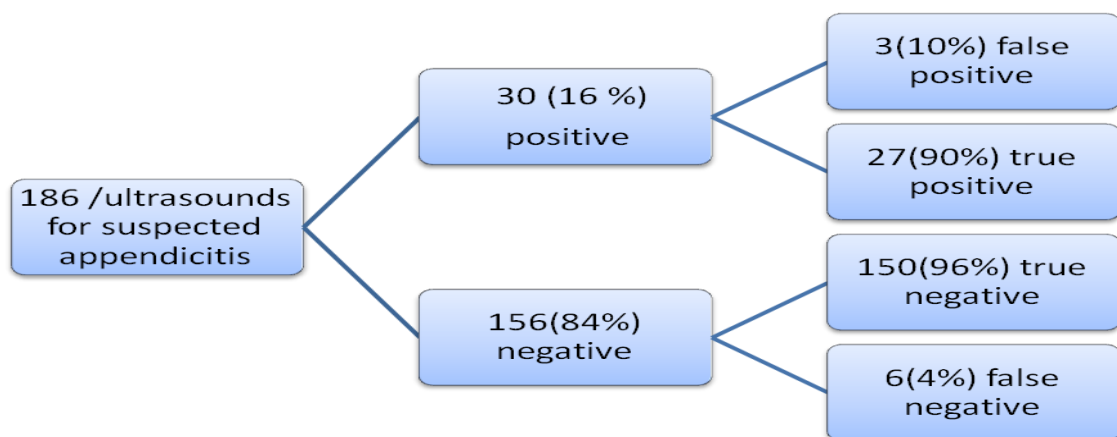


Figure 4:- ultrasounds results

Discussion

The diagnosis of acute appendicitis is not frequently straight forward, because of the atypical presentation seen in some patients, leading, in some instances, to remove a normal appendix, and this events happened even with a well experienced surgeon. Clinical decision to operate leads to removal of 20% of normal appendix, to avoid complication of delayed diagnosis[21]. The diagnosis of acute appendicitis is usually based on clinical history and physical examination[22]. In our locality we do some other testes to support our diagnosis , as blood investigation. Leukocytosis & positive Blumberg's sign considered the most important, of all the signs and symptoms, in diagnosing acute appendicitis. Early we use a plain abdominal radiography to confirm the diagnosis depending on the visualization of the appendicolith, which is considered the most specific sign in association with other clinical features[17] , in addition to other sign as dilated sentinel loop, fluid level, scoliosis, and obscuration of psoas shadow. Recently ultrasounography playing an important role in diagnosing acute appendicitis, and reduce the hazard of un wanted appendicectomy, and in this study was considered the second lines of testes after the clinical assessment. In this study, the ultrasound, proved to be a useful tool for investigating acute appendicitis with high positive predictive value, negative predictive value, and specificity. The high positive predictive value come from the demonstration of an enlarged, non compressible appendix. In general, the normal appendix cannot be defined with ultrasound, and clear visualization of appendix is suggestive of an inflammation[17]. The main reasons behind the false-negative diagnosis of appendicitis are: 1) obese with gaseous

distention of bowel,2) un usual site of appendix, as retrocecal,3)gases within appendicial lumen, either refluxing from cecum or due to gas forming organism infecting the appendix,4) ruptured appendix, as the ultrasonographic signs to identify appendix no more exist . In many studies[14,23,24,25] they recommend to keep the patients under observation, when there is a clinical suspicion of appendicitis with normal ultrasound finding, with repeating the clinical exploration and the ultrasonography , with even surgical intervention. In this study the ultrasound has been shown to be an effective modality of investigation in suspected acute appendicitis, and as the result showed, which is comparable to those published up to date[1,19]. The main cause behind the false positive result, is the treating of patients with antibiotics, rather than subjecting them to surgery. The lack of radiation, widespread availability, non-invasive,and the relatively low cost, making the ultrasound a modality of choice in diagnosing the acute appendicitis, or by offering the possibility to make an alternative diagnosis. In contrary, the ultrasound required an adequate skill, and is difficult to be conducted in obese patients with sever pain, and those likely to have a complicating abscess.

Conclusion

The graded-compression of appendix is a useful imaging modality in diagnosing acute appendicitis, and in offering an alternative cause in others, with condition, that the ultrasound is conducted by a well skilled radiologist.

References

1. Birnbaum BA, Wilson SR. Appendicitis at the millennium. *Radiology*,2000, 215:337–348.

2. Yacoe ME, Jeffrey RB Jr. Sonography of appendicitis and diverticulitis. *Radiologic Clinics of North America*, 1994, 32:899–912.
3. Flum DR, Koepsell T. The clinical and economic correlates of misdiagnosed appendicitis. Nationwide analysis. *Arch Surg.*, 2002;137(7):799-804.
4. Oshimo Y, Yamada H, Sumioka M, Nagata S, Ishimaru S, Miyamoto M, *et al.*: Usefulness of ultrasonography for diagnosing of acute abdomen of right lower abdominal pain (in Japanese). *Clinic all-round*, 2000, 49: 797-802.
5. Wada M. : Ultrasound of acute appendicitis (in Japanese). *Japneases Journal of Diagnostic Imaging*, 2002, 22: 865-872.
6. Ayaz A *et al.* Diagnostic accuracy of alvarado score in the diagnosis of acute appendicitis. *Pakistan Journal of Medical Sciences*, 2009, 25:118–121.
7. Paulson EK, Kalady MF, Pappas TN. Clinical practice. Suspected appendicitis. *N Engl J Med.*, 2003, Jan 16;348(3):236-42.
8. Balthazar EJ *et al.* Acute appendicitis: CT and ultrasound correlation in 100 patients. *Radiology*, 1994, 190:31–35.
9. Paulson EK, Kalady MF, Pappas TN. Suspected appendicitis. *New England Journal of Medicine*, 2003, 348:236–242.
10. Kessler N, Cyteval C, Gallix B, Lesnik A, Blayac PM, Pujol J, *et al.* Appendicitis: evaluation of sensitivity, specificity, and predictive values of US, Doppler US, and laboratory findings. *Radiology*. 2004, 230(2):472-8.
11. Birnbaum B, Wilson S, Appendicitis at the millennium, *Radiology*, 2000, 215:337–348.
12. Rettenbacher T, Hollerweger A. Ovoid shape of the vermiform appendix: a criterion to exclude acute appendicitis evaluation with US. *Radiology*, 2003, 226:95-100.
13. Hoffmann J, Rasmussen OO. Aids in the diagnosis of acute appendicitis. *British Journal of Surgery*, 1989, 76:774–779.
14. Bianchi A, Heredia A, Hidalgo LA, García F, Armella C, Suñol X. Is there enough clinical observation where appendicitis dudososde ? *Emergency*, 2005;17:176-9.
15. Del Cura JI, Oleaga L. The emergency radiology. *Topics. Serum Monograph* , 2006;79-86.
16. Gutierrez CJ, Mariano MC, Faddis DM, Sullivan RR, Wong RS, Lourie DJ, *et al.* Doppler ultrasound accurately screens patients with appendicitis. *Am J Surg*, 1999;65:1015-7.
17. Marincek B. Non traumatic abdominal emergencies: acute abdominal pain: diagnostic strategies. *Eur Radiol*, 2002;12:2136-50.
18. Paulson E, Kalady M, Pappas T. Suspected appendicitis. *N J Med* , 2003;3:236-43.
19. Del Cura JI, Oleaga L, Grande D, Fariña MA, Isusi M. Comparison of ultrasound and computed tomography in the diagnosis of acute appendicitis. *Radiology*, 2001;43:175-86.
20. Chen SC, Wang HP, Hsu HY, Huang PM, Lin FY. Accuracy of ED Sonography in the diagnosis of acute appendicitis. *Am J Emerg Med* , 2000;18:449-52.
21. Silberman VA. Appendectomy in a large metropolitan hospital: Retrospective analysis of 1,013 cases. *Am J Surg*, 1981; 142(5):615-18.
22. Vázquez MA, Monteruel E, García E, Mintegui S, Canapé S, Benito J. performance of abdominal ultrasonography in the diagnosis of acute appendicitis. *J. of pediatrics* , 2003;58:556-61.

23. Steven L, Ho S. Ultrasonography and computed tomography in suspected acute appendicitis. *Semin Ultrasound CT MR*, 2003;24:69-73..
24. Gallinas F, Garce C, Pérez A. Ultrasound in the selection of urgent surgical abdominal pain. A prospective study. *Cir Pediatrics*, 2004;17:141-4.
25. Garcia FJ, Gil P. Sonography in acute appendicitis: diagnosis utility and influence upon management and outcome. *Eur Radiol*, 2000;10:1886-93.