

REDO POSTERIOR URETHROPLASTY :LOCAL EXPERIENCE

Dr. Safaa.A.Mohssin*.

ABSTRACT

Purposes: to assess the different factors responsible for failure of posterior urethroplasty in recurrent stricture methods :- from "February 2000-december 2007" 17 patients (6-60 years)with failed urethroplasties under went redo urethroplasty for post traumatic posterior urethral distraction..Bulbo prostatic anastomosis was done through perincum in "15"patients and by perineo- abdominal transpubic in "2"patients.The operative records of all patients was registered and followed for (6 month-2years).

Results: There was failure in "2"cases (8%) ,satisfactory in 6 patients (30%) and successful in 9 patients (62%).

Discussion: The causes of failure and satisfactory results was in complete excision of the scared prestatic apex in ability to achieve tension-free- bulbo prostatic anastomosis and inproper lateral fixation of prostatic mucosa on sides.

Conclusions: Redo urethroplasty considered one of obstacks in urology ,that should be done by effecient,experts hands (urologist),that stick to the rules of surgical procedure (complete excision of fibrous tissue,lateral fixation of the prostatic mucosa and tension free-bulbo-prostatic anastomosis).

INTRODUCTION

The outlook for the patient with a traumatic posterior urethral stricture has improved almost beyond recognition in the last decade as aresult of the development of avariety of anastomotic techniques for urethral reconstruction. The combination of the relatively restricted surgical access together with its inherent sphincter function makes any reconstruction of the posterior urethra a much more complicated procedure ^(1,2) .One detailed analysis of the results of urethroplasty showed that the greatest rate of recurrence (29%) was noted in patients with membranous lesions who predominately had apost-traumatic stricture⁽³⁾.Most investigators ,have focused on cases of successfully reconstructed urethras.and only avery few have addressed the subject of failed posterior urethroplasty ^(1,4,5) .An analysis of these factors demonstrated that the

failure rate doubled from (14,3%) for patients without any prior manipulation to (27,6%) for those with multiple diletations and an even greater rate of failure (31,6%) if the patient had undergone previous urethroplasty⁽¹⁾.

MATERIAL & METHODS

From February 2000-december 2007."17"male patient all of them had previous failed urethroplasties done by different surgeons under went "19"anastomotic urethroplasty procedures for post traumatic posterior urethral distraction defects.patient age ranged from "6 to 60 years"."15" of them had sustained pelvic fracture urethral disruption as the intial causative trauma and "2"not associated with pelvic fractures .combined antegrade and retrograde urethrography revealed loss of urethral contineuity in all cases ,with prostate-

* department of surgery,division of urology- college of medicine.Basrah university.

Redo Posterior Urethroplasty :Local Experience

bulbar distraction defect varying from (1-6)cm.in length by radiographic measurement.The intervals between the original trauma and repairs in the new cases and since the last repair in the recurrent cases varied from (6-24)month. Urethral anastomosis was performed using a perineal approach in (15)cases and perineo-abdominal procedure in 2.urethroplasty was attempted first through the perineum in every case.First the bulbar urethra was circumferentially dissected down to its proximal end and the scar tissue involving the membranous-prostatic region was completely excised.This usually required retrograde resection of the sclerosed prostatic apex by the scalpel until healthy pliable mucosa was reached.This was laterally fitted to the prostatic edge to guarantee a mucosa to mucosa bulbo-prostatic anastomosis. After mobilization of the anterior urethra for a variable length. Usually to the peno scrotal junction,anastomosis of the already spatulated bulbar and prostatic urethral ends was done.If a tension-free anastomosis could not be achieved, the course of the mobilized urethra was shortened by the turner-warwick perineo-abdominal progressive approach (trans pubic)(1,6,7)partial pubectomy. In this series,complete excision of the sclerosed part of prostate could not be accomplished in "3 patients" because of a confined surgical field and to a high displaced prostate .In "2" additional cases the anastomosis was not completely free.of tension despite adequate urethral mobilization .In another "3" cases good fixation of the prostatic mucosa on one or other side of its circumference,could not be done. All repairs were done using 4|0 castgut,chronic sutures for fixation of the urethral mucosa and 3|0 dexone were used for urethral anastomosis A "20F" foleys catheter (silicone) was used as a urethral stent for adult patients.and (10F-14F) foleys catheter was used in children . All patients had documented pre operative urinary tract infection and received parenteral

antibiotics according to the results of the urine culture and sensitivity starting the morning of the operation. Treatment was continued for (5-7) days and then replaced by oral antibiotics until the catheters were removed. The urethral catheter was removed "3"weeks post operatively. Retrograde Urethrography ,was then done,and if satisfactory, the suprapubic catheter was removed (3 days)later.repeated urethrography (retrograde) .were done when indicated during follow up. which ranged (6months-5years).

RESULTS

The results were classified as successful when the patient voided as before the original trauma or had comfortable void and was continent and urethrography showed normal caliber of urethra at the site of repair.The results were classified as failure if he could not void as before the trauma or was incontinent and most of contrast medium was demonstrated at the site of repair on urethrography .The results were classified as satisfactory when there was need for urethral dilatation,optical urethrotomy (1or 2)times. The failure results were reported in "2" cases (8,2%).all after perineal urethroplasty,the patient age in this group (30,35),both of them had previous urethroplasty for (2 times)in addition to optical urethrotomy ,the length of the prostate-bulbar distraction defect was (4 and 6cm) In these "2" cases the operative records show incomplete excision of the sclerosed prostate apex .The satisfactory results reported in 6 cases (28%),"5"of them after perineal urethroplasty and "1"after transpubic urethroplasty , patient age (22-40 years),.all those patients have previous urethroplasty,the prostate -bulbar distraction was (3-6 cm)and operative records reveal incomplete excision of the sclerosed prostatic apex in 1, "2"of them had failure of tension-free anastomosis. "3"

patient had inadequate lateral fixation of the prostatic mucosa.

DISCUSSION

We are discussing apost traumatic posterior urethral strictures or distractions which are known to be limited pathologic segment, whatever its length, So,if proper surgical technique done can result in an ideal solutions.This is also accepted by several authors (7-8).So, I want to certain an essential facts in surgical repaire to achieve asuccessful results after urethroplasty.These facts include meticulous and good excision of the sclerosed prostatic apex ,lateral fixation of urethral mucosa with tension-free anastomosis .Koraitim and Mc C aninch(9.10)stressed that careful and complete excision of scar tissue is the single most important step for achieving asuccessful outcome after urethral reconstruction . In complete excision of scar tissue will necessarily result in anastomosing the bulbar urethra in to afibrosed prostatic apex with unhealthy mucosa,so ,the ultimate result is urethral obliteration shortly after removal of the urethral stent as actually occurred in "2"of patients.These should be corrected later by repeated excision and urethral anastomosis. After excising the sclerosed prostatic apex,including its adherent mucosa ,the free edge of the healthy pliable mucosa has the tendency to retract proximally.To prevent this we are Pulling down the mucosa and anchoring it to the prostatic capsule to ensure mucosa to.mucosa urethral anastomosis.If this step is not done well.it will result in alocalized soft mucosal narrowing at the site of anastomosis with minimal underlying fibrosis.(9)These patients usually present with aweak narrow urinary stream several months after surgery .correction may be easily accomplished by optical urethrotomy "3".I considered this procedure as complemetary step to urethroplasty,this is was seen in "3" cases of satisfactory results^(4 -11) .

Atension- free urethral anastomosis is very important for successful results^(1,2,7,8,9). This can be achieved in most of cases by mobilization of the bulbar urethra till the peno-scrotal junction, but extensive mobilization of the penile urethra will affect the retrograde blood supply of the penile urethra from the glans result in ischemia and chordee^(1,6) ,While the antegrade blood supply of the proximal urethra comes from the posterior bulbar arteries,which are necessarily divided during proximal urethral transection.Both these mechanisms can result in ischemic necrosis of the proximal urethra,⁽⁸⁾ ,this is could be the cause for satisfactory results in "3" cases and the need for complementary procedures. In "2" cases when the distraction of urethra is more than "3 cm" the tension-free-anastomosis cannot be achieved through perineal approach only and the mobilized anterior urethra has to take shorter direct course to anastomose the prostatic apex which was done by partial pubectomy abdomino-perineal approach ^(1,12) this procedure enable us more prompt excision of the scared upward displased prostatic apex and to ensure tension free urethral anastomosis and this is explain the results of this approach (no failure result).with less damage to the sphincter and the neurovas cular bundles .(6,8,12).

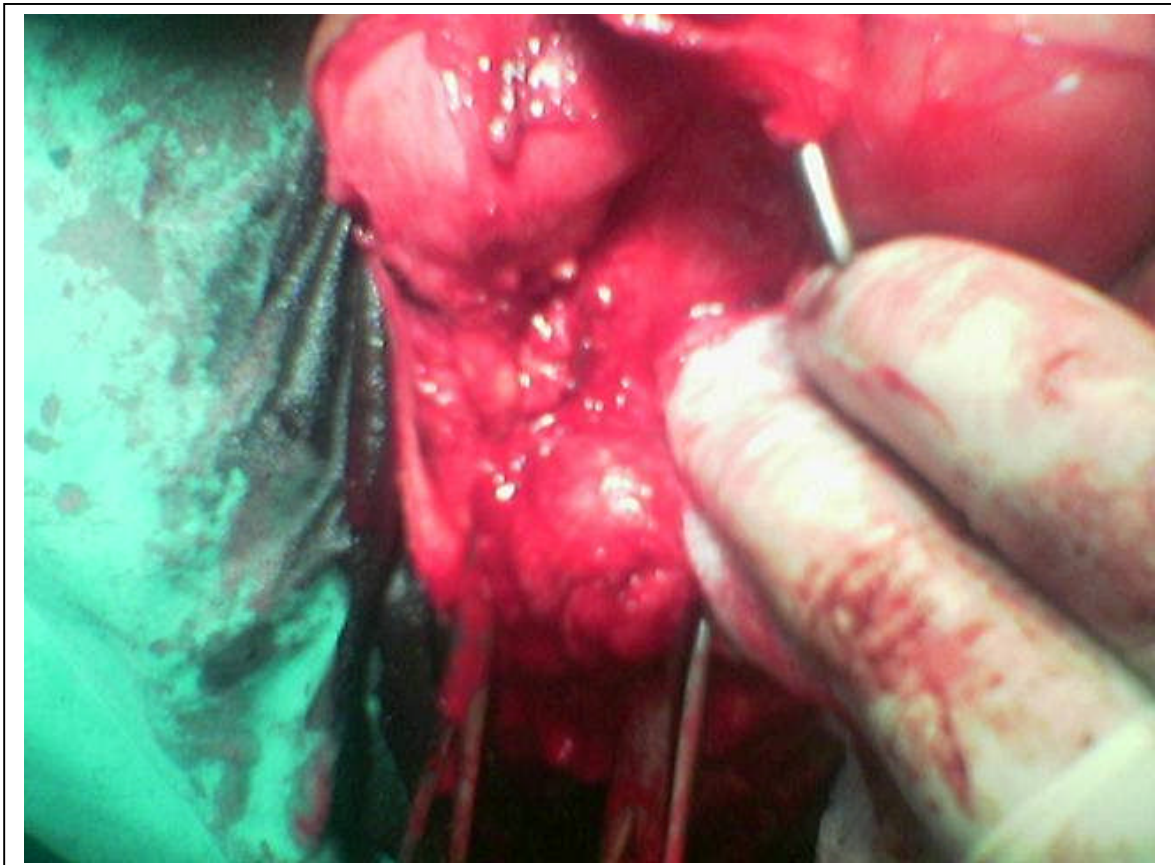
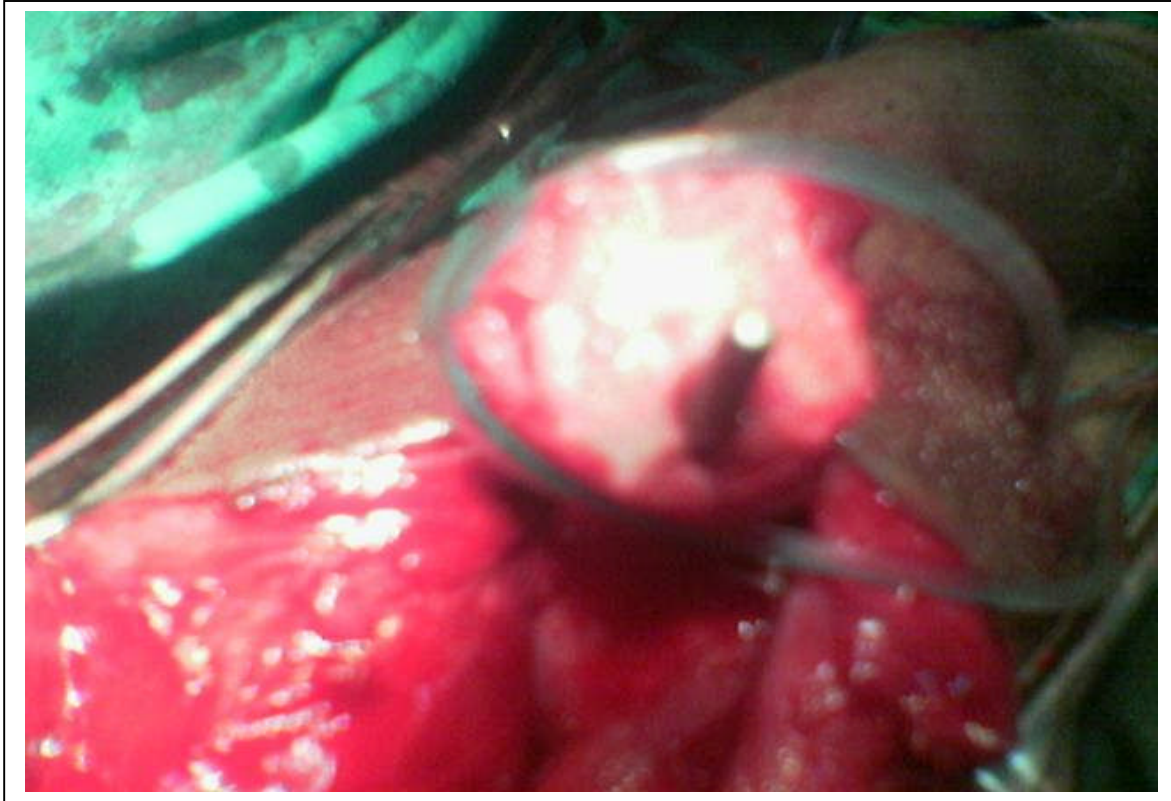
CONCLUSIONS

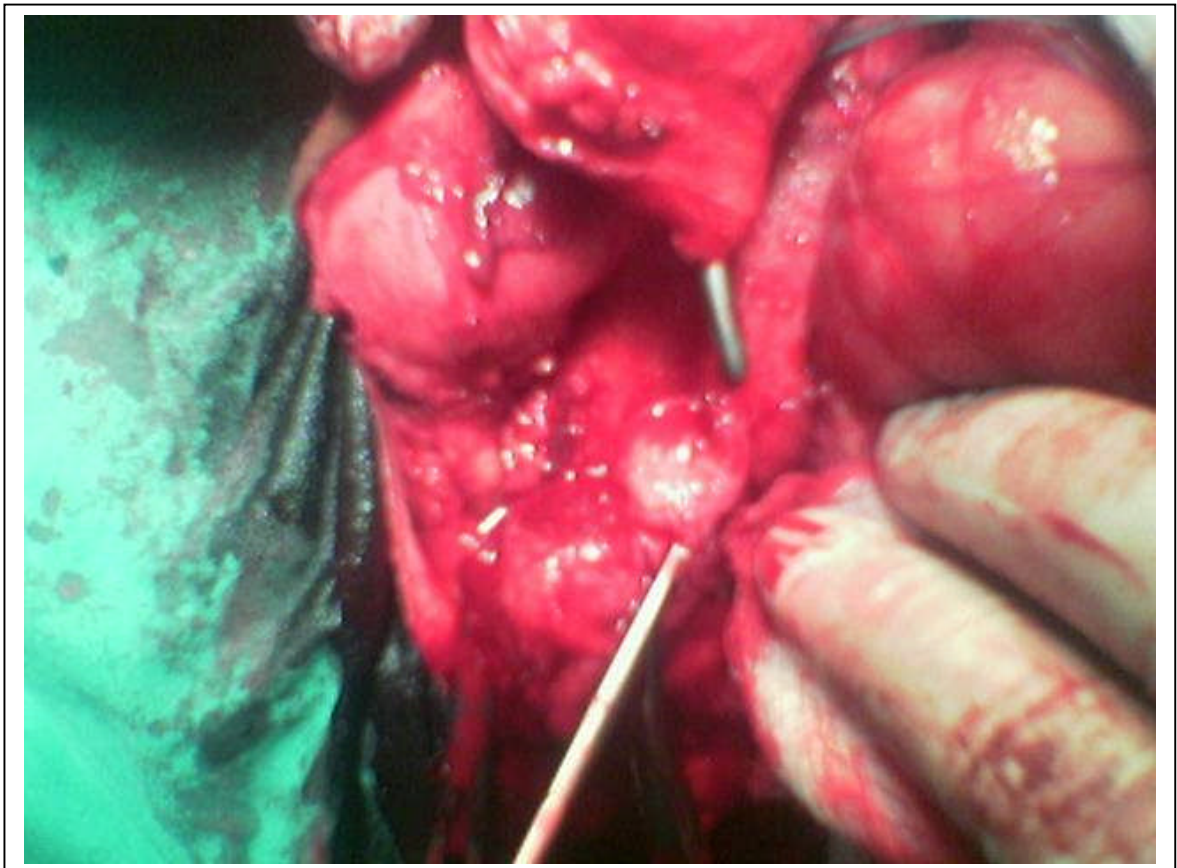
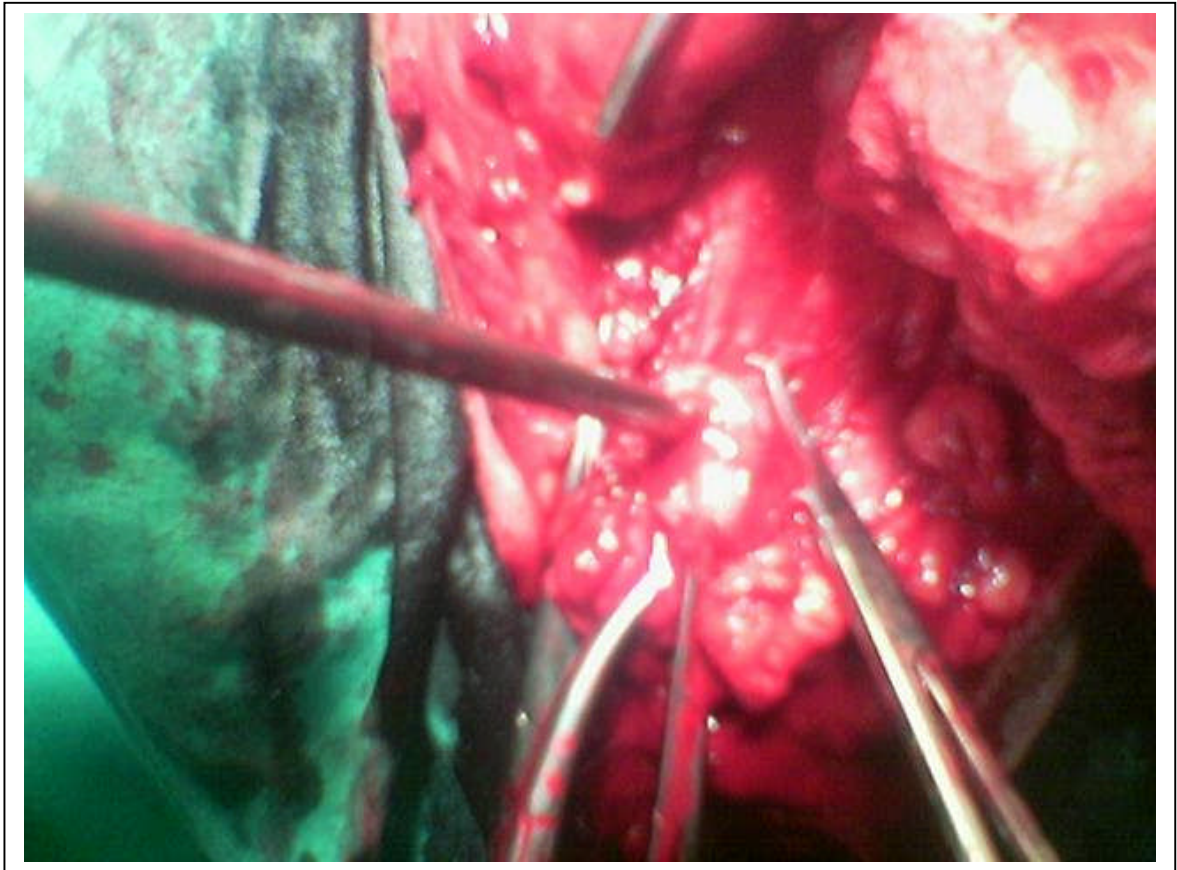
From this study I can conclude that redo urethroplasty is one of the difficult operations that need to be done by efficient urologist who had good experience with urethral surgery and the failure after anastomotic urethroplasty is primarily aresult of one or multiple defects in operative procedure,and if the procedure done perfectly we can have successful results ,so, the failure can be prevented by strict adherence to the surgical rules (complete excision of fibrosed prostatic apex ,lateral fixation of the prostatic mucosa and tension –free-anastomosis).

Redo Posterior Urethroplasty :Local Experience

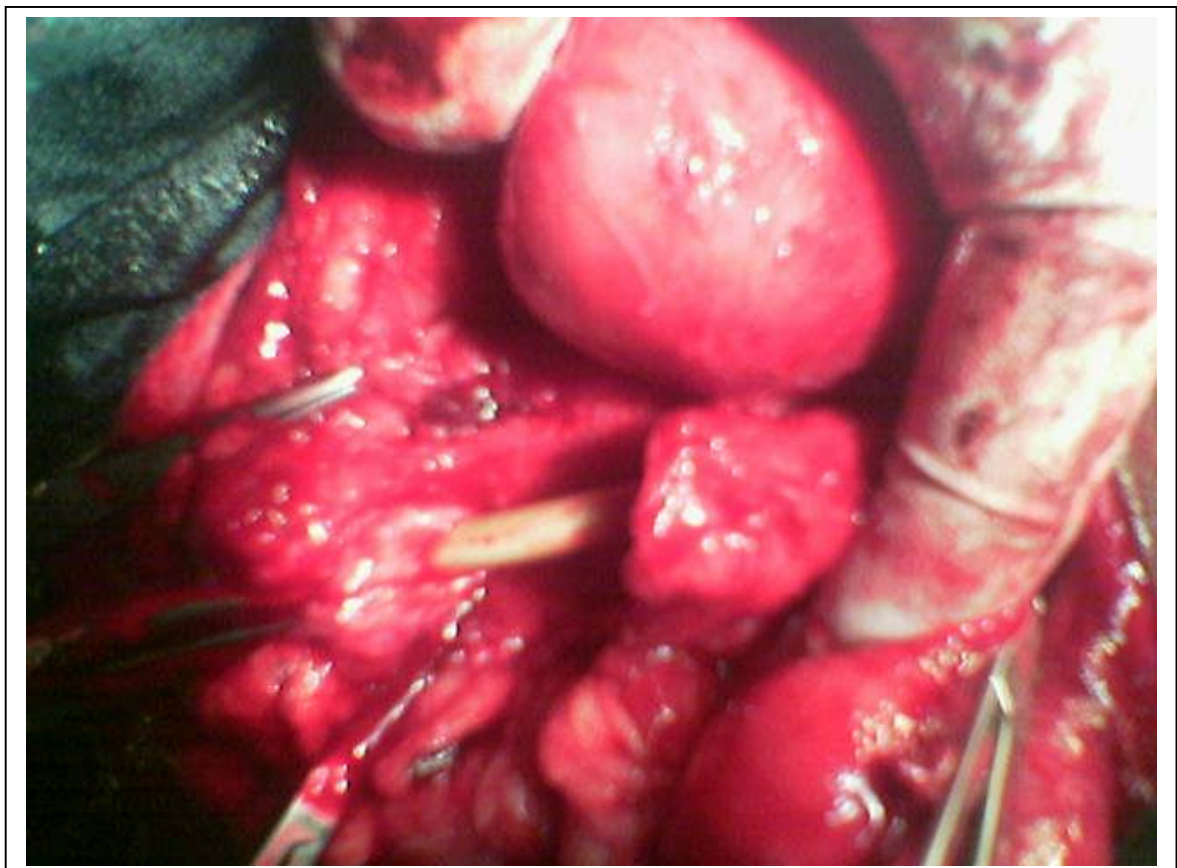
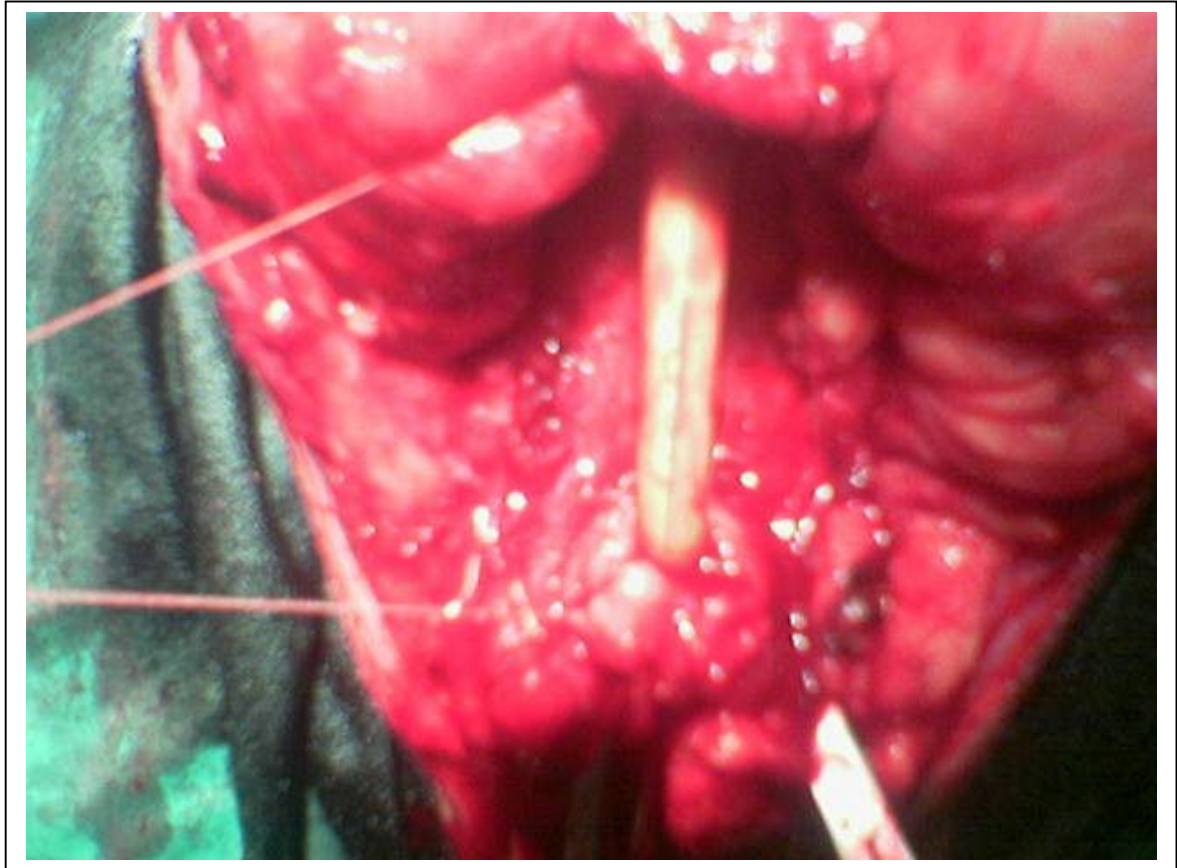In posterior urethroplasty .transpubic (partial) urethroplasty may be needed in

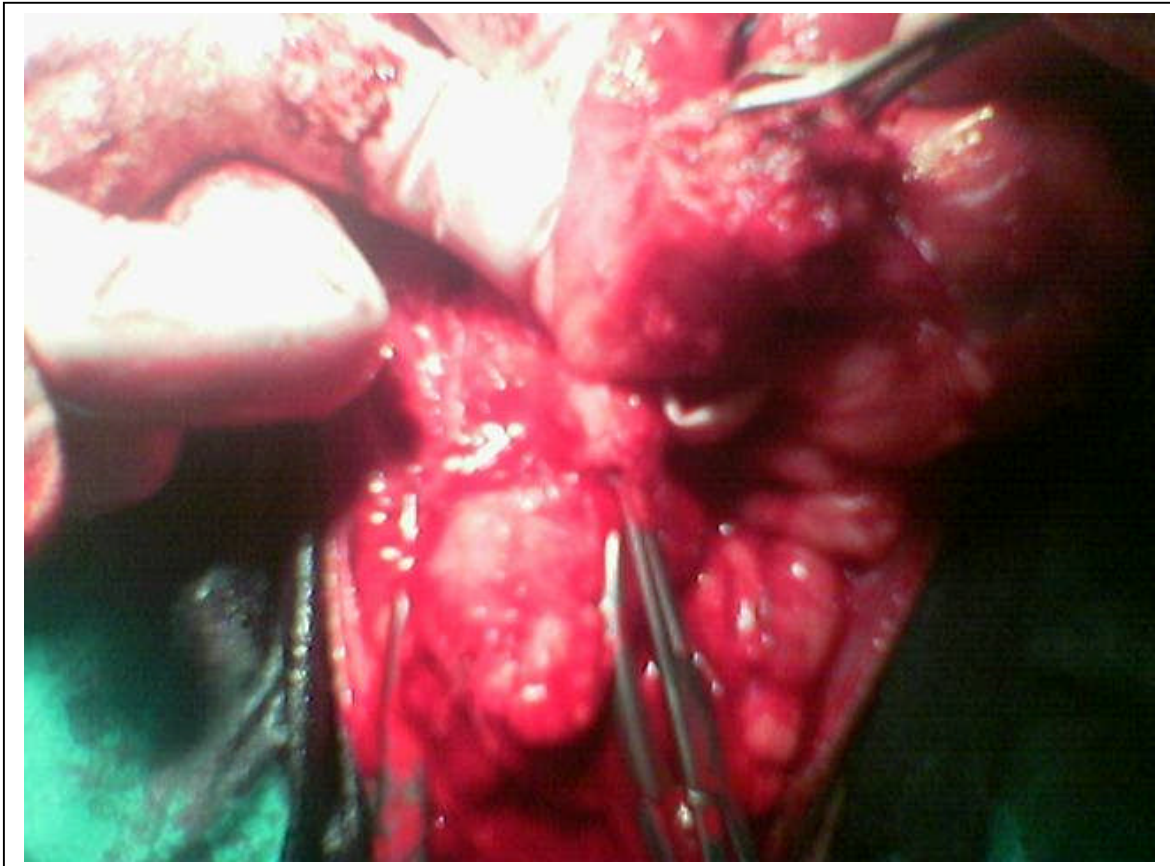
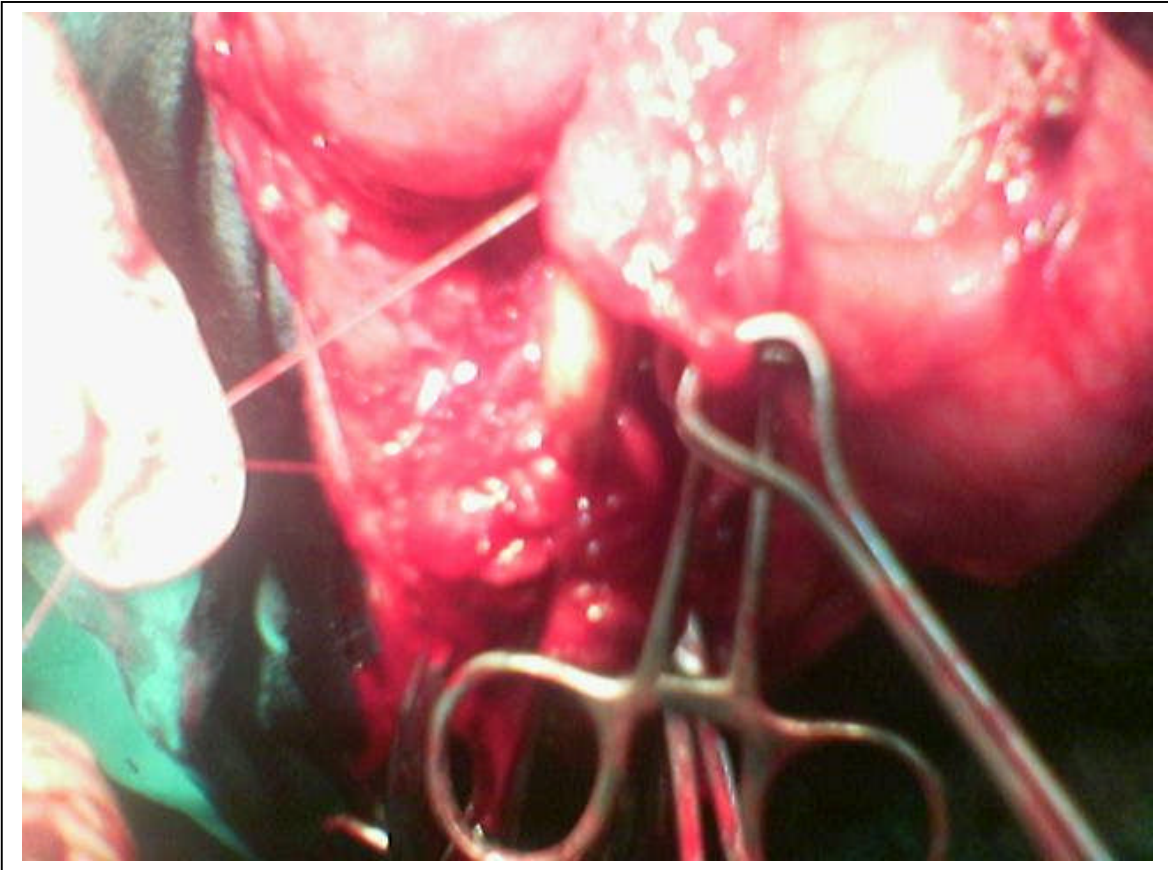
certain situations with acceptable results.



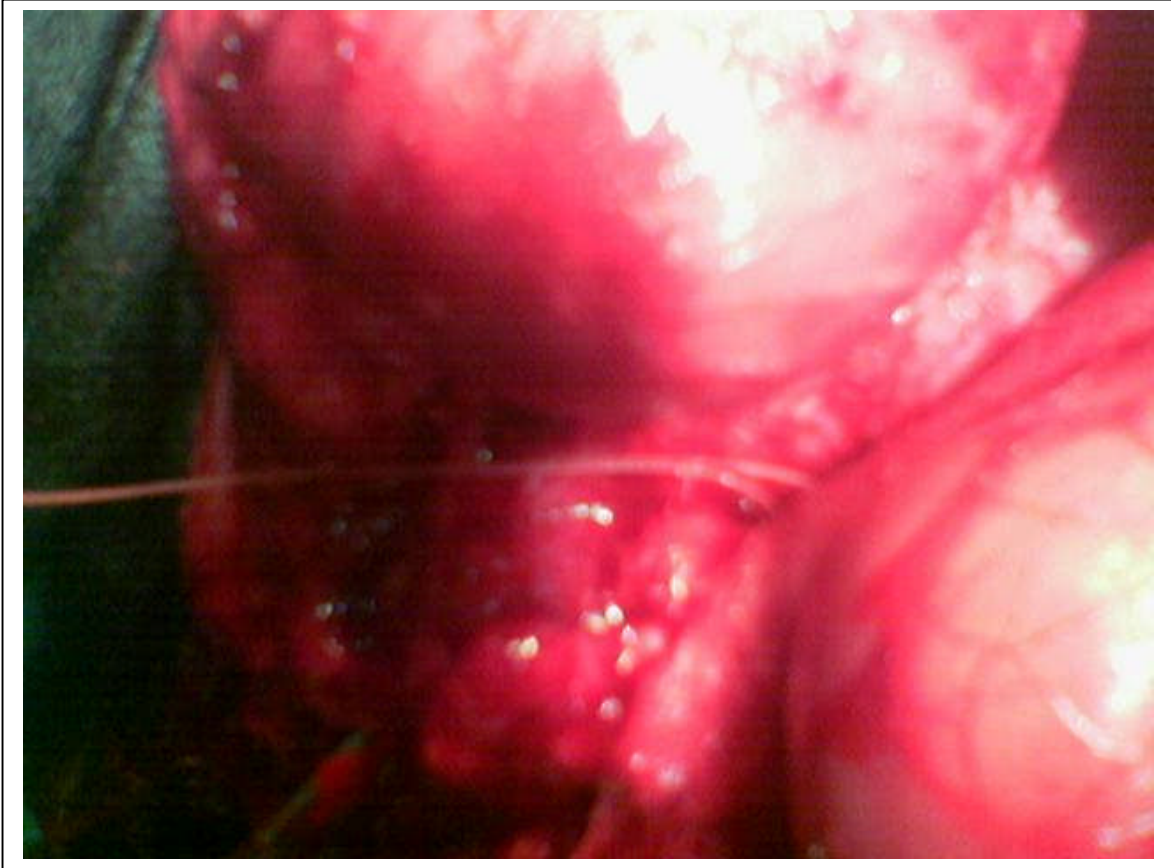


Redo Posterior Urethroplasty :Local Experience





Redo Posterior Urethroplasty :Local Experience



The successful results reported in "9" cases (61%).

Procedure	Successful	Satisfactory	Failure	Total
Perineal	8 (48%)	5 (33%)	2(7.5%)	15(91.5%)
Transpubic	1(50%)	1(50%)	-	2(8.5%)
Total No.	9	6	2	17

REFERENCES

1. Turner- Warwick R: complex traumatic posterior urethral strictures. J Urol. 118: 564-574,1977.
2. Webster GD, and Stephen S. : The management of strictures of the membranous urethra. J urol. 134: 469- 473,1985.
3. Roehrborn CG, and Mc Connell JD: Analysis of factors contributing to success or failure of one-stage urethroplasty for urethral stricture disease. J urol. 151: 869-874,1994.
4. Netto NRJr, Lemos GC, and claro JF: Internal urethrotomy as a complementary methode after urethroplasties for posterior urethral stenosis. J Urol. 141:50-51, 1989.
5. Jurner- Warwick R, and chapple C: Urethral strictures, in cohen MS, Resnick MI (Eds): Re operative urology. Boston, Little Brown, 1995, pp 135-171.
6. Turner- Warwick R: Prevention of complications resulting from pelvic fracture urethral injuries and from their surgical management . urol clinic North Am 16: 335-358, 1989.
7. Webster GD, and Ramon J: Repaire of pelvic fracture posterior urethral defects using an elaborated perineal approach: experience with 74 cases . Jurol 145 : 744-747, 1991.
8. Koraitim MM: Failed posterior urethroplasty lessons Learned. Jurol. 62: 719-722, 2003.
9. Koraitim MM ? The lessons of 145 post traumatic Jurol. 153: 63-66, 1995.
10. Morey AF, and Mc Aninch JW: Reconstruction of posterior urethral disruption injuries: outcome analysis in 82 patients. Jurol 157: 506-510, 1997.
11. Sabah AK, Safaa AM: Urethroplasty in posterior urethral injuries. Bas J surg, September, 12: 96-100, 2006.
12. Webster GD. Koefoot RB, Sihelnik SA: Urethroplasty management in 100 cases of urethral stricture: arationale for procedure selection. J urol 134: 892-898, 1983 .