

Conservative Treatment of Closed Fracture Shaft Humerus in Adult Patients

Ghadeer H. Majeed, F.I.C.M.S.*; Mohammed S. Al- Iedani, F.I.C.M.S.*.
Ismaeel Kalif, M.B.Ch.B.**

Abstract

Background: Fractures of the humeral shaft accounting for approximately 3% of all fractures. There is a wide array of good options for their treatment and controversy over the best methods. Although good techniques of osteosynthesis are available, the aim of this article is to emphasize on the benefit and good outcome of conservative treatment for properly selected cases to decrease the cost and avoid the complications of surgery.

Method : During the period from February 2011 to June 2012 fifty-five fractures of humeral shaft were treated at orthopedic department in the AL-Kindy teaching hospital. 22 fractures considered suitable for the study. The patients treated conservatively by using the 'U' shaped coaptation slab. Then we shift to POP cast or functional brace after one week. Then we follow the patient clinically and radiologically every 2 weeks until the fracture had united and the limb functions were restored. The outcome of treatment was assessed by specific parameters which include alignment, rate of union and limb functions. **outcome:** This study showed that the initial deformities of angulations were considerably reduced by the use of U slab and the POP cast which act as a

dynamic rather than a static splint, or functional brace through soft-tissue compression correcting angulation to less than 30° in coronal plane and less than 20° in sagittal plane. Manipulation of the fracture was not required and did not affect neither the rate of union nor the final position, as the cast appeared to be capable of correcting angulation deformities. Perfect anatomical reduction was found not to be essential for satisfactory limb function, which was present with varus angulation and posterior bowing. The incidence of delayed union compares favorably with other reported series, although the definition of delayed union is variable.

Conclusion: In fracture shaft of humerus, neither rigid immobilization nor perfect alignment are of great importance for final outcome, so conservative treatment is one of the most effective methods of treatment and the operative treatment can lead to adverse effect on the outcome in case of bad judgment and should be limited as much as possible to specific indications.

Key words: mid-Humeral shaft fractures, modalities of treatment, conservative treatment, and angulations deformities.

Al – Kindy Col Med J 2013; Vol. 9 No. 1 P:14

Introduction

Fractures of the humeral shaft account for roughly 3% of all fractures (Canale & Beaty)⁽¹⁾. A fall on the hand may twist the humerus, causing a spiral fracture, a fall on the elbow with the arm abducted exerts a bending force, resulting in an oblique or transverse fracture. Treatment of these injuries continues to evolve as advances are made in both nonoperative and operative management.

The earliest method of conservative treatment of humeral shaft fractures was simple immobilization of the upper extremity to the body. This thoracobrachial immobilization provided comfort to the patient, but was insufficient to control alignment and promote union and that is why this technique is actually only very rarely used. Caldwell⁽²⁾ proposed

his technique of treating humeral shaft fractures relying on gravity to achieve proper position of the fracture. In this method, the arm is immobilized in a long arm plaster cast. The cast is then suspended by a strap around the neck, which is connected to loops incorporated into the cast at the level of the forearm. Fracture alignment can be adjusted by adjusting the position at which the straps connect to the loops. Compared to thoracobrachial immobilization better results in terms of alignment are observed, but non-union due to excessive distraction was reported as one of the complications, besides elbow stiffness due to longstanding immobilization. The problem of distraction can be overcome with the use of a U-splint, which is a plaster molded from the axilla, around the elbow

and over the deltoid. The elbow is flexed at 90 degrees and the forearm supported by a collar-and-cuff suspension sling.

There is a wide array of good options for their treatment and controversy over the best methods for many situations Chapman⁽³⁾. Charnley stated, "It is perhaps the easiest of the major long bones to treat by conservative methods." Canale & Beaty⁽¹⁾. The range of motion afforded by the shoulder and elbow joints, coupled with a tolerance for small amounts of shortening, allow radiographic imperfections that cause minimal functional deficit and are well tolerated by the patient. Appropriate nonoperative and operative treatment of patients with humeral shaft fractures, however, requires an understanding of humeral anatomy, the fracture pattern and the patient's activity level and expectations.

The goals of humeral shaft fracture management are to establish union with an acceptable humeral alignment and restore the patients to their prior level of function. Many methods have been described for the treatment of humeral shaft fractures Epps and Grant⁽⁴⁾. Both patient and fracture characteristics (patient age, presence of associated injuries, soft-tissue status and fracture pattern) need to be considered to select the appropriate treatment option. The closed treatment methods available include:

- Hanging arm cast
- Coaptation or U-shaped brachial splint
- Velpeau dressing
- Abduction humeral splint/shoulder spica cast
- Skeletal traction
- Functional brace

Although good to excellent results have been reported using each of these different treatment modalities, Functional bracing has essentially replaced all other conservative methods and has become the "gold standard" for nonoperative treatment Ward *et al*⁽⁵⁾ because of its ease of application, adjustability, allowance of shoulder and elbow motion, and reproducible results Initially popularized by Sarmiento in 1977 (Canale & Beaty⁽¹⁾).

The hanging arm cast: The hanging arm cast uses dependency traction provided by

the weight of the cast to effect fracture reduction. Therefore, for this technique to be effective, the patient must remain upright or semi-erect at all times. The hanging arm cast may be the definitive fracture treatment or can be exchanged for a functional fracture brace. A concern with use of the hanging arm cast is fracture distraction resulting in delayed union. The indications for use of the hanging arm cast include displaced mid-shaft humeral shaft fractures with shortening, particularly those fractures with an oblique or spiral pattern. Treatment with the hanging arm cast requires meticulous attention to detail. The cast should be lightweight and applied with the elbow at 90° and the forearm in neutral rotation (Fig. 1). The cast should extend at least 2 cm proximal to the fracture. Three plaster or wire loops are applied at the distal forearm in dorsal, neutral and volar positions; stockinet is passed through one of these loops and around the patient's neck. Apex anterior angulation is corrected by shortening the sling; apex posterior angulation is corrected by lengthening the sling; apex medial angulation is corrected by using the volar loop and apex lateral angulation is corrected by using the dorsal loop (Fig. 2).

Coaptation splint: The U-shaped coaptation splint with collar and cuff is indicated for the acute treatment of humeral shaft fractures with minimal shortening. A carefully molded plaster slab is placed around the medial and lateral aspects of the arm, extending around the elbow and over the deltoid and acromion (Fig. 3). The forearm is suspended by a collar and cuff. The splint should hang free of the body. The patient is instructed in range of motion exercises of the shoulder, elbow, wrist and hand. Similar to the hanging arm cast, the coaptation splint is frequently exchanged for a functional cast brace 1-2 weeks after injury as the patient's pain permits Hunter⁽⁶⁾.

Thoracobrachial immobilization: A stockinette Velpeau shoulder dressing was used for immobilization of the shoulder girdle. This over-the shoulder device is inexpensive, comfortable and easily applied (Fig. 4). This device is most useful in nondisplaced or minimally displaced

fractures in children or the elderly who are unable to tolerate other methods of management.

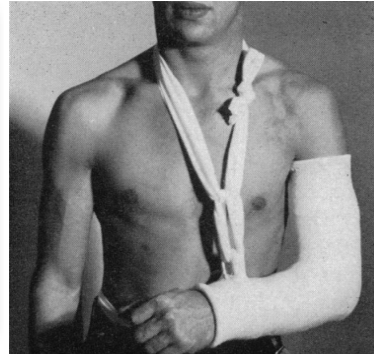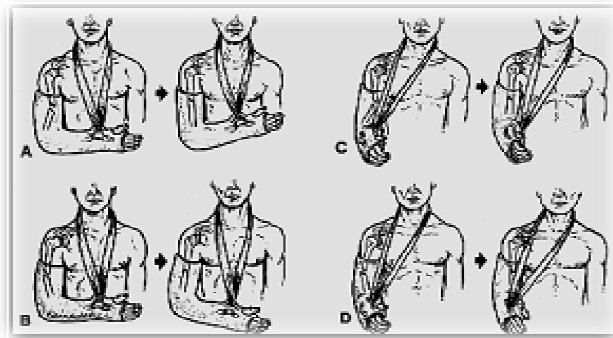


Fig. 2: (A) With use of the hanging cast, apex anterior angulation is corrected by shortening the sling; (B) Apex posterior angulation is corrected by lengthening the sling; (C) Apex medial angulation is corrected by using the volar loop; (D) Apex lateral angulation is corrected by using the dorsal loop

Fig. 1: The hanging arm cast

Shoulder spica cast: The indications for use of a shoulder spica cast are unclear. The primary indications may be when closed reduction of the fracture requires significant abduction and external rotation of the upper extremity. However, when this uncommon situation occurs, operative management is frequently performed.

Skeletal traction: Skeletal traction is rarely indicated for the treatment of closed or open humeral shaft fractures. The historical indications for use of skeletal traction are now considered indications for operative intervention. When indicated, skeletal traction is applied through a transolecranon Kirschner wire or Steinmann pin. The pin should be inserted from medial to lateral to minimize the risk of ulnar nerve injury, Terry Canal⁽⁷⁾.

Functional bracing: The humeral functional brace was first described by Sarmiento *et al*⁽⁸⁾. A functional brace is an orthosis that affects fracture reduction through soft-tissue compression. Use of this device maximizes shoulder and elbow motion. This brace initially was custom made and designed as a wraparound sleeve. However, current braces are prefabricated and consist of an anterior shell (contoured for the biceps tendon distally) and a posterior shell (Fig. 5). These shells are circularized with Velcro straps, which can be tightened as swelling

decreases. Contraindications to use of the functional brace include:

- Massive soft-tissue injury or bone loss
- An unreliable or uncooperative patient
- An inability to obtain or maintain acceptable fracture alignment. Naver and Aalberg⁽⁹⁾

The humeral fracture brace can be applied acutely or 1-2 weeks after application of a hanging arm cast or coaptation splint. The brace is worn for further 6 weeks. Louis Solomon⁽¹⁰⁾.

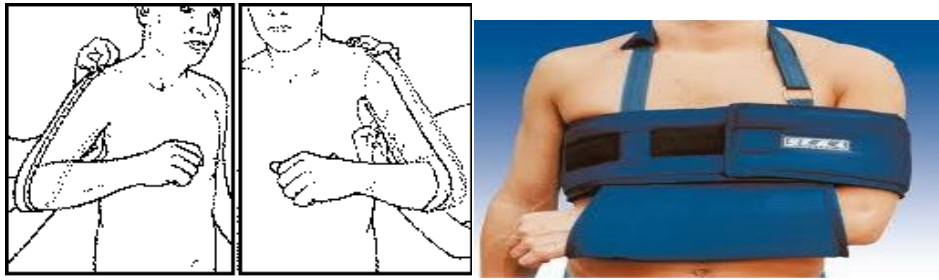


Fig. 3: U-shaped splint Similar to the hanging arm cast, the coaptation splint is frequently exchanged for a functional cast brace 1-2 weeks after injury as the patient's pain permits

Fig. 4: A Velpeau shoulder dressing

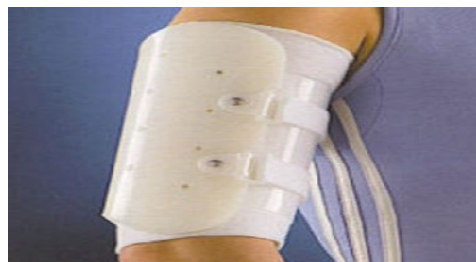

Fig. 5: A functional brace consists of an anterior shell (contoured for the biceps tendon distally) and a posterior shell, held together with Velcro straps

Complications:

Radial nerve injury: Up to 18% of humeral shaft fractures have an associated radial nerve injury particularly oblique fractures at the junction of the middle and distal thirds of the bone (Holstein–Lewis fracture). Most nerve injuries represent a neurapraxia or axonotmesis; 90% will resolve in 3-4 months (Pollock et al⁽¹¹⁾).

Vascular injury: Although uncommon, injury or laceration of the brachial artery can be associated with fractures of the humeral shaft. Fractures complicated by vascular injury constitute an orthopaedic emergency. Stabilization of the fracture is mandatory to protect the vascular repair and minimize additional soft-tissue injury (Connolly⁽¹²⁾; McNamara et al.⁽¹³⁾).

Nonunion: The literature suggests that 4 months is a reasonable period of time for humeral shaft fractures to unite (Foster et al.;⁽¹⁴⁾ Zuckerman et al.⁽¹⁵⁾). Nonunion is present when healing is no longer evident. The rate of non-union in conservatively treated low-energy fractures is less than 3 percent (Louis Solomon⁽¹⁰⁾). The proximal and distal thirds of the humerus are at increased risk of nonunion. Other factors associated with nonunion include a transverse fracture pattern, fracture

distraction, soft-tissue interposition and inadequate immobilization (Mast et al.⁽¹⁶⁾). Interestingly, there is no good evidence that the union rate is higher with fixation (Louis Solomon⁽¹⁰⁾).

Methods

During the period from Feb. 2011 to Jun. 2012 fifty –five fractures of humeral shaft were treated at Orthopaedic Department in AL-KINDY Teaching hospital. 22 fractures considered suitable for the study, those excluded are shown in the Table 1. There were 14 (63.6%) male and 8 (36.4%) female. The age of the patients range from 18-75 year. A fracture of the humeral shaft was defined as a fracture occurring below the surgical neck and above the epicondyles. only mid-shaft oblique or spiral fractures included. In the acutely fractured patient the application method of the 'U' shaped coaptation slab was standard. The patient was seated on a low stool, leaning to the injured side to expose the axilla. A collar and cuff were applied with elbow at a right angle. The upper arm was wrapped in a single layer of cotton from the shoulder to four inches distal to the elbow. The arm was encased in six inch, eight layers slab that passed

from the midclavicular region around the shoulder, down the arm, under the elbow and up the medial aspect of the arm just below the axilla. A wet gauze bandage was used to retain the slab and to mold it to the contours of the arm (Fig. 3). No anesthesia was used and the treatment was on out-patient basis. All patients were examined the following day as outpatient; the plaster, position of the limb, circulation and neurologic state were checked and the humeral shaft radiologically examined. Then after 1-2 weeks the patient seen and also examined clinically and radiologically, we shift to POP cast or functional brace and the patient re-examined every two weeks until union evident clinically and radiologically. POP cast applied according to these rules:

- The elbow must be in flexion 90°
- The POP cast extends from mid-palm to the fracture level or not more than one inch above

- The sling must be fixed at the level of the wrist with mid-pronation forearm
- The POP must be light and never be distracting force consist of 4-6 (6 inch) gypsum wrapped over single layer of cotton
- To correct lateral angulation, the loop should be placed on the dorsum of the wrist, to correct medial angulation, the loop should be placed over the volar side
- Along sling should be used to correct posterior angulation; short one, to correct anterior angulation
- The arm must be continuously dependent
- Early, active, vigorous, exercises of the longitudinal muscle of the arm (4-6 times daily) are imperative
- Systematic resistant exercise of the fingers and thumb are essential

Table 1: Cases excluded from the study

| | Case | No. of patient (Total 33) |
|---|--|---------------------------|
| 1 | Fractures in patient under 18 years | 5 |
| 2 | Open fractures | 13 |
| 3 | Pathology fractures | 2 |
| 4 | Fractures with incomplete treatment (other treat.) | 10 |
| 5 | insufficient clinical data | 2 |
| 6 | complicated by nerve injury | 1 |

Then we follow the patient clinically and radiologically every 2-4 week and until the fracture had united and the limb functions were restored.

Treatment was assessed by the following parameters:

- **Alignment:** Measurement of humeral angulation in coronal plane (varus and valgus) and in sagittal plane (anterior and posterior) was determined from initial and final radiographs
- **Rate of union :** (Fig. 6) Union was assessed clinically; by the absence of bone pain, tenderness and movement on stressing the fracture site. Radiographic union was determined by the evidence of callus formation on plane X-ray. Delayed union was defined as the absence of

clinical union 12 weeks after the original trauma

- **Limb functions:** This was determined by assessing the pain and the return of the movement at the shoulder, elbow and the hand and the final use of the limb and graded as:
 - **Grade-I:** Pain and total restriction preventing all activities
 - **Grade-II:** Less pain and severe restriction preventing or severely impeding daily activities
 - **Grade-III:** Restriction permitting daily activities with some difficulties
 - **Grade-IV:** Minimal restriction not impeding daily activities and no pain
 - **Grade- V:** No restriction of activities and no pain (Hunter)⁽⁶⁾

Results

Alignment: fractures getting sound union were assessed for deformity in coronal and sagittal planes by goniometer. Alignment in coronal plane (Table 2): 6 fractures (27.3%) were initially undisplaced, 9 fractures (40.9%) had varus angulation and 7 fractures (31.8%) had valgus angulation. At union 7 fractures (31.8%) were undisplaced, 10 fractures (45.5%) had varus angulation and 5 fractures (22.7%) had valgus angulation. Alignment in sagittal plane (Table 3): Six fractures (27.3%) were initially undisplaced, 4 fractures (18.2%) had anterior angulation and 12 fractures (54.5%) had posterior angulation. At union 13 fractures (59.1%) united without displacement, 2 fracture (9.1%) with anterior angulation and 7 fractures (31.8%) with posterior angulation.

Rate of union: In our study 20 fractures (90.9%) had union with an average time 48 days. No correlation was found between sex, or type of fracture and the effect of manipulation and the rate of union. Two fractures in uncooperative male's patient progress to delayed union and the fracture took 16 weeks to get safe union clinically and radiologically. So the incidence of delayed union was 9.1%.

Function: (Table 4): In assessing the function 12 fractures (54.5%) had grade V function and 8 fractures (36.4%) had grade IV function. Only 2 fractures (9.1%) had grade III function especially the shoulder joint and they were an elderly. Compensational movement of the upper limb was such that restriction of daily activity was minimal. The average rate of return to full function was 10 weeks and it was fast in patient younger than 35 year and slower and less complete in older.

Table 2: Alignment progression in coronal plane

| | | | |
|---------------------|--|--------------|---|
| Displacement | Initially undisplaced 6 patients | no change | 4 |
| | | final valgus | 2 |
| | initially Varus 9 patients | decrease | 6 |
| | | no change | 2 |
| | | increase | 1 |
| | initially valgus 7 patients | decrease | 5 |
| | | no change | 2 |
| | | increase | 0 |

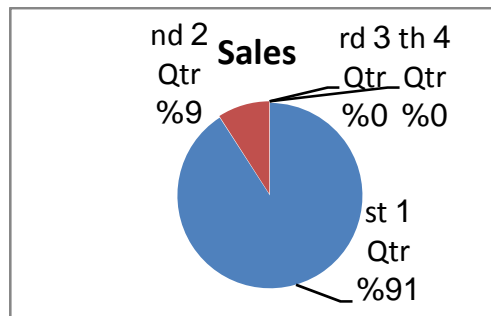
Table 3: Alignment progression in sagittal plane

| | | | |
|---------------------|--|-------------|---|
| Displacement | Initially undisplaced 6 patients | no change | 4 |
| | | Final ant. | 1 |
| | | Final post. | 1 |
| | initially ant. 4 patients | decrease | 3 |
| | | no change | 1 |
| | initially Post. 12 patients | decrease | 6 |
| | | increase | 2 |
| | | no change | 4 |

Table 4: Show distribution of patients according to functional grade

| grade | No. of patients | % |
|-------|-----------------|-------|
| I | 0 | 0 |
| II | 0 | 0 |
| III | 2 | 9% |
| IV | 8 | 36.4% |
| V | 12 | 54.6% |

Fig. 6: Pie chart showing distribution according to rate of union



Discussion

Closed treatment of humeral shaft fractures represents an effective method of fracture management and has sustained critical evaluation throughout the literature. Zagorski et al⁽¹⁷⁾ reported about a series of 170 patients treated conservatively, with a non-union rate of 1.8 %. Angulation in varus and valgus averaged 5 degrees, while anteroposterior angulation averaged 3 degrees. Hunter⁽⁶⁾ reported 60 humeral shaft fractures treated with a coaptation splint. The arm was suspended by a collar and cuff after application of the splint. Treatment success was based on fracture union, residual deformity and limb function. Fifty-six fractures (93%) united; all had less than 30° angulations. The average time to union was 40 days for males and 42 days for females. There was no correlation between healing and patient sex, fracture level, or need for fracture manipulation. With one exception, all patients younger than age 40 recovered full extremity function by 10 weeks. In older patients, functional return was slower. The authors concluded that a coaptation splint could be used effectively to treat patients with humeral shaft fractures.

Our results indicate that the initial deformities of angulation were considerably reduced by our treatment. The U slab and the POP cast act as a dynamic rather than a static splint, correcting angulation to less than 30° in coronal plane and less than 20° in sagittal plane. There was a tendency to residual varus angulation whether the fracture was manipulated or not. The deforming force

was sufficient to produce varus angulation from the undisplaced position. Therefore it did not merely exaggerate the preexisting angulation, but must have resulted from the application and maintenance of the slab and POP cast. The force producing the posterior displacement could not always be overcome by the conservative treatment, thus resulting in 2 fractures with initial posterior angulation uniting with increased posterior deformity and 1 initially undisplaced fracture unite with posterior angulation.

As 6 of the 12 fractures with initial posterior angulations united without displacement, the deforming force would appear not to be the type of conservative treatment and is most likely to originate from the Triceps muscle and most of the patients feel comfortable with the short sling. To oppose this force would require increasing the weight of the POP cast, which would increase the risk of distraction and consequence nonunion. Manipulation of the fracture was not required and did affect neither the rate of union nor the final position, as the cast appeared to be capable of correcting angulation deformities. Perfect anatomical reduction was found not to be essential for satisfactory limb function, which was present with varus angulation and posterior bowing. This supports the findings of Kennermann⁽¹⁸⁾ and Muzahim⁽¹⁹⁾ who noted good functional results in the presence of residual coronal and sagittal plane angulation, providing the deformity did not exceed 30°. The incidence of delayed union compares favorably with other reported series, although the

definition of delayed union is variable. The method of assessment of limb function has limitation, but despite that, it is apparent that significant functional impairment was not found. Attempts to define final function by methods used by other reports show similar result. Therefore we should not operate on fractures of the shaft unless there is clear indication which includes:-

1. Open fracture
2. Associated vascular injury.
3. Floating elbow.
4. Humerus fracture in polytrauma patient.
5. Radial nerve dysfunction after manipulation.
6. Pathological fracture
7. Nonunion
8. Unacceptable malunion

Conclusion

The vast majority of humeral shaft fractures can be treated conservatively and good to excellent results can be expected but several features about the humerus cause fractures of that bone to present special attention in treatment make it necessary to depart from common lines of treatment of fractures of long bones. These features are:

- It is the most freely movable long bone and its movement can be amplified by the movement of the scapula. So it can overcome wide range of malalignment and malrotation
- Its entire function is that of a lever, so that nearly all stress is in tension or at an angle to its long axis. The bone has to stand comparatively little stress in compression
- When at rest while the person is standing, the axis of the bone hangs vertically and is influenced by gravity alone, this can be used effectively for treatment
- It is a single bone, well enclosed in soft tissues (mainly muscles) which give very good vascular supply and can mask malunion in any plane with acceptable cosmetics
- Fractures of bones with a rich blood supply, such as the rib or humerus, where there is slight motion at the fracture site, usually heal rapidly, provided that there is no infection or mechanical interference,

such as excessive trauma, soft tissue interposition, or gross malposition

- The acceptable alignment is:

<20° anteroposterior

<30° varus or valgus

With very good functional outcome because of wide range of movement in the upper limb which can be overcome these deformity from these features we can conclude that: In fracture humerus, like fracture clavicle, neither rigid immobilization nor perfect alignment are of great importance for final outcome of the fracture. So conservative treatment is the most effective way of treatment and the operative treatment can have adverse effect on the outcome in case of bad judgment and should be limited as much as possible to these indications.

Recommendations: The surgeon needs to consider all the advantages and disadvantages of nonoperative and operative management for a majority of these fractures to coordinate an appropriate treatment plan best serving the fracture characteristics and patient expectations. Because of the high union rate and good to excellent functional outcome we recommend conservative treatment for fracture shaft humerus as treatment of choice and to operate only in the presence of strict indications.

References

1. Canale & Beaty: Campbell's Operative Orthopaedics, 11th ed. 2007. Fracture of the humeral shaft.
2. Caldwell JA. Treatment of fractures of the shaft of the humerus by hanging cast. *Urg Gynecol Obstet* 1940; 70: 421-5.
3. Chapman, M.W., 2003. Fractures and Dislocations of the Shoulder Girdle and Humerus. In: Chapman's Orthopedic Surgery. JB Lippincott, Philadelphia, pp: 1004-1012. ISBN: 13: 9780781714877.
4. Epps, C.H., Jr. and R.E. Grant, 1991. Fractures of the Shaft of the Humerus. In: Rockwood and Green's Fractures in Adults. JB Lippincott, Philadelphia, pp: 843-869. ISBN: 0-397-50975-8
5. Ward, E.F., F.H. Savoie and J.L. Hughes, 1992. Fractures of the Diaphyseal Humerus. In: Skeletal Trauma, Browner, B.D., J.B. Jupiter, A.M. Levine and P.G. Trafton (Eds.). WB Saunders, Philadelphia, pp: 1177-1200. ISBN: 0-7216-2726-9

6. Hunter, S.G., 1982. The closed treatment of fractures of the humeral shaft. *Clin. Orthop.*, 164: 192-198. PMID: 7067285.
7. Terry Canal, S., 2008. Fractured Shaft Humerus. In: *Campbell's Operative Orthopaedic*. 11th Edn. 3389-3400. Mosby Elsevier. Philadelphia. ISBN: 978-0-323-03329-9.
8. Sarmiento, A., P.B. LaFerte and E.G. Galvin. 1977. Functional bracing of fractures of the shaft of the humerus. *J. Bone Joint Surg.*, 59A: 596-601. PMID: 873955.
9. Naver, L. and J.R. Aalberg, 1986. Humeral shaft fractures treated with a ready-made fracture brace. *Arch. Orthop. Trauma Surg.*, 106: 20-22. DOI: 10.1007/BF00435647
10. Louis Solomon MD FRCS, *Apley's System of Orthopaedics and Fractures*, Ninth Edition, 2010
11. Pollock, F.H., D. Drake and E.G. Bovill, 1981. Treatment of radial neuropathy associated with fractures of the humerus. *J. Bone Joint Surg.*, 63A: 239-243. PMID: 7462281.
12. Connolly, J., 1970. Management of fractures associated with arterial injuries. *Am. J. Surg.*, 120(3): 331. PMID: 5456914.
13. McNamara, J.J., D.K. Brief and J.F. Stremple 1973. Management of fractures with associated arterial injury in combat casualties. *J. Trauma*, 13: 17-19. PMID: 4687242.
14. Foster, R.J., G.L. Dixon and A.W. Bach, 1985. Internal fixation of fractures and non-unions of the humeral shaft: Indications and results in a multi-center study. *J. Bone Joint Surg.*, 67A: 857-864. PMID: 4019533.
15. Zuckerman, J.D., C. Giordano and H. Rosen, 1993. Humeral Shaft Nonunions. In: *Complications of Shoulder Surgery*, Bigliani, L.U. (Ed.). Williams and Wilkins, Baltimore, pp: 173-189. ISBN: 0683007513
16. Mast, J.W., P.G. Spiegel and J.P. Harvey, 1975. Fractures of the humeral shaft: A retrospective study of 240 adult fractures. *Clin. Orthop.*, 112: 254-262. PMID: 1192642
17. Zagorski JB, Latta LL, Zych GA, Finnieston AR. Diaphyseal fractures of the humerus: treatment with prefabricated braces. *J Bone Joint Surg Am* 1988; 70: 607-10.
18. Kerner, L., 1966. Fractures of the humeral shaft. *J. Bone Joint Surg.*, 48B: 105-111. PMID: 5909054
19. muzahim M. Taha. The outcome of conservative treatment of closed fracture shaft humerus in adult patients. *American medical journal* 2(1):32-39, 2011.