

# ***Disc Battery-The escalating risk of ingestion by children in Iraq And subsequent clinical events and complications.***

**Sabah N. Jabir, MBChB, FICM ; Muthana D. Al-Assal, MBChB, FICM; Ahmed A. Mohammed, MBChB**

## **Abstract**

**Background:** Disc battery ingestion is a common serious problem in Iraq. It increase in the last years because of the increase in number of electronic toys that uses these batteries. These batteries contains many types of irritant chemicals that increases the risk of it's ingestion.

**Methods:** We reviewed the medical records of children aged between 1 year and 7 years old admitted to Surgical Specialty Hospital/Baghdad Medical City due to disc battery ingestion from January 2007 through December 2010). The diagnosis of disc battery ingestion was based upon history, clinical symptoms, and results of imaging studies. The clinical data reviewed included sex, age, clinical manifestation and duration of symptoms, hospital course, imaging findings, and endoscopic results.

**Results:** 50 patients were admitted to Thoracic and vascular Department/Surgical Speciality Hospital/Baghdad Medical city Complex (26 males and 24 females) of disc battery ingestion with a mean age of 1.873 years (range, 7 months to 7 years). Forty one patients had Symptoms of Dysphagia, vomiting, nausea, and abdominal pain. Four cases with no history of disc battery ingestion and were accidentally found by X ray studies. Two patients complained from Aspiration and chalking, two patients had mediastinitis and died at later on due to sepsis, and only one case had surgical emphysema.

Thirty-eight cases had their batteries impacted in the upper esophagus and Nine cases had their batteries impacted in mid-esophagus, and Three cases had their battery impacted in the lower-esophagus. In those patients with upper esophageal

Impaction, two cases end with acquired trachea-esophageal fistula, in those patients with mid-esophageal impaction two of them were died from mediastinitis and sepsis, while those with lower esophageal impaction only one case ends with esophageal perforation and the battery removed by left thoracotomy under general anesthesia, and in 45 patients , were removed by endoscopy. The duration of hospitalization varied from 1 day to 30 days.

**Conclusion:** Most cases of disc battery ingestion run uneventful courses.

However, the ingestion of some disc batteries may be fatal or complicated with life-threatening events. If the battery impacts in the esophagus, emergency endoscopic management is necessary. Once in the stomach, the battery will usually pass through the gastrointestinal tract without long-term complications.

**Aim:** The purpose of this study was to evaluate the characteristics ,management, and out comes of disc battery ingestion in Iraq.

**key words:** Disc battery ,esophageal disc battery ingestion, risk of disc battery ingestion.

***Al – Kindy Col Med J 2013; Vol. 9 No. 1 P:31***

## **Introduction**

Button batteries are those small, coin-shaped batteries used in watches, calculators, hearing aids, and other similar appliances. (picture.1)The incidence of ingestion of button batteries has increased during the past several years as the availability of these devices has increased.(1) Disk batteries are formed by compacting metals and metal oxides

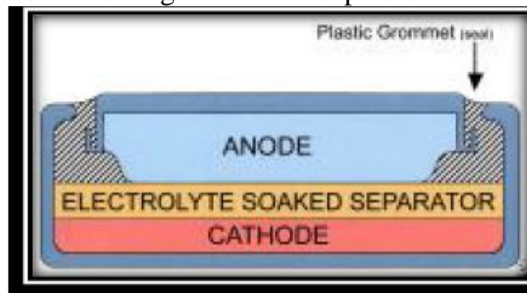


**Picture 1: Different types of batteries available in the market places**

on either side of an electrolyte-soaked separator. The unit is then placed in a 2-part metal casing held together by a plastic grommet The grommet electrically insulates the anode from the cathode.(pic.2) The metal undergoes oxidation on one side of the separator, while the metal oxide is reduced to the metal on the other side, producing a current when a conductive path is provided

Disk batteries contain mercury, silver, zinc, manganese, cadmium, lithium, sulfur oxide, copper, brass, or steel. These are the components of the anode, cathode, and case containing the

battery. Disk batteries also contain sodium hydroxide or potassium hydroxide to facilitate the electrochemical reaction through the separator.



picutre2: Different types of batteries available in the market places

Disk batteries do not usually cause problems unless they become lodged in the gastrointestinal (GI) tract. The most common place disk batteries become lodged, resulting in clinical sequelae, is the esophagus. Batteries that successfully traverse the esophagus are unlikely to lodge at any other location.

Esophageal damage can occur in a relatively short period of time when a disk battery is lodged in the esophagus. Liquefaction necrosis may occur because sodium hydroxide is generated by the current produced by the battery (usually at the anode). Perforation has occurred as rapidly as 6 hours after ingestion.

Ingested button batteries have strong potential for corrosive injury to the gastrointestinal tract with major complications, including esophageal burns, fistula, or perforation. The management of button battery ingestions, including radiographic localization and removal, depends upon the location of the battery and the age of the patient. Neither battery size nor the presence of symptoms can be us to reliably predict esophageal location in children.

Direct corrosive action, low voltage burns, and pressure necrosis.(9) Liquefaction necrosis and perforation can occur as soon as 4 to 6 hours after a disk battery is lodged in the esophagus.(5,10,11).

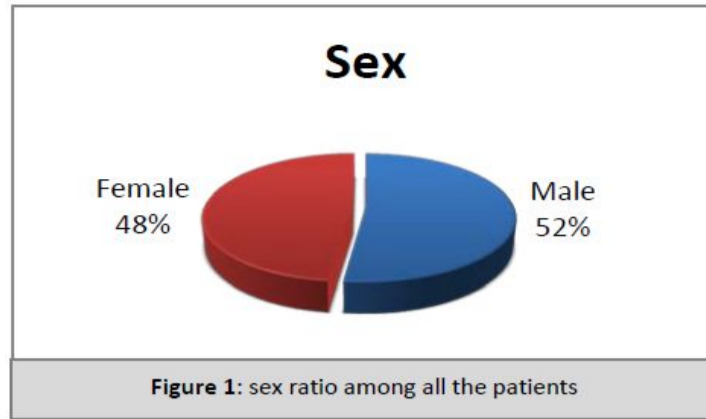
According to previous reports, the ingestion of button batteries usually occurs in children. The sizes of button batteries vary in diameter from 7.9 to 23 mm and in weight from 1 to 10 grams.(12) Button battery ingestion usually causes problems in children if the diameter of battery greater than 20 mm.(1)

### Methods

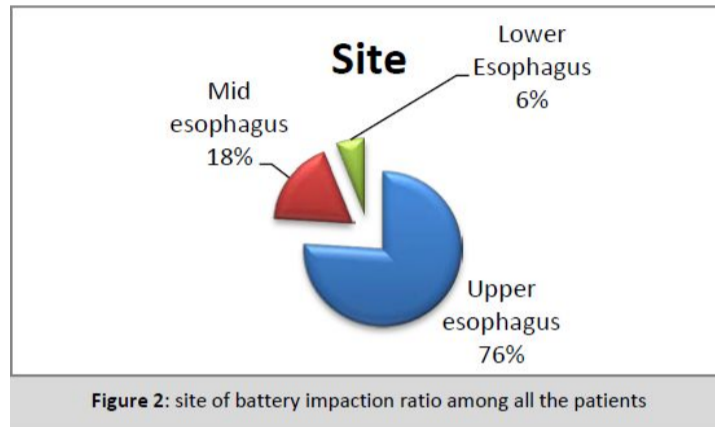
We reviewed the medical records of children aged between 1 year and 7 years old admitted to Surgical Specialty Hospital/Baghdad Medical City due to disc battery ingestion from January 2007 through December 2010). The diagnosis of disc battery ingestion was based upon history, clinical symptoms, and results of imaging studies. The clinical data reviewed included sex, age, clinical manifestation and duration of symptoms, hospital course, imaging findings, and endoscopic results.

### Results

50 patients were admitted to Thoracic and vascular Department/Surgical Speciality Hospital/Baghdad Medical city Complex (26 males and 24 females) of disc battery ingestion with a mean age of 1.873 years (range, 7 months to 7 years). (52%) were male, and (48%) were female. (See fig.1)

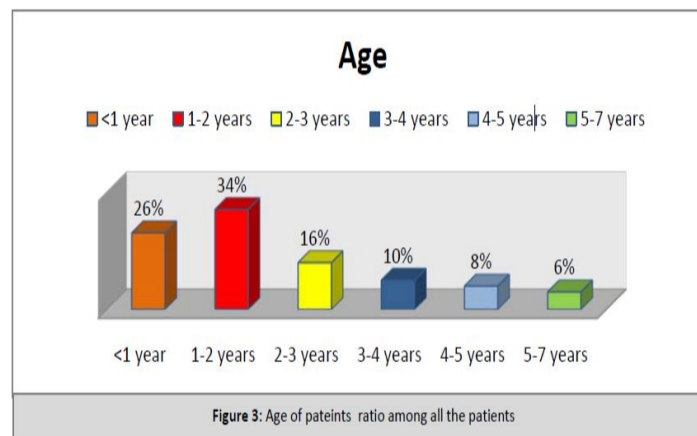


The disc battery lodged in the esophagus with (76%) in upper esophagus, (18%) in the middle esophagus, and (6%) in the lower esophagus. (See fig.2)



age of children ranged from 7 months to 7 years with a mean age of (1.873) the results were(26%) of cases below one year of age, (34%) of cases from one year to two years of

age, (16%) of cases between two years to three years of age, (10%) between the age three to four years, (8%) between four to five years of age, and (6%)from five years of age to seven years of age. (See Fig.3)



Among all the children admitted only (8%) were asymptomatic even with positive history of foreign body ingestion, (82%) were complained from dysphagia and vomiting and abdominal

pain collectively, while (4%) were complained from symptoms of choking.(4%) only were complained from mediastinitis and sepsis and died later on in the ICU.(See fig.4)

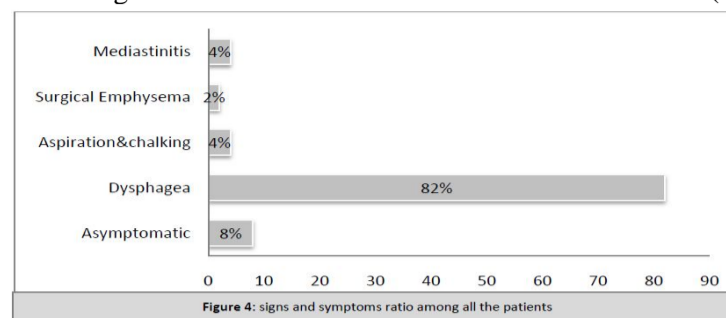


Fig.5

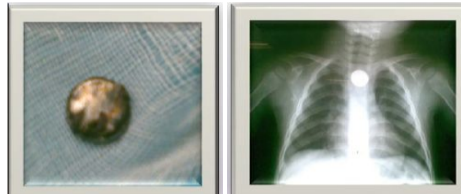


Figure 5: chest radiograph of a child ingested a disc battery (left),the disc battery (Right).

All the cases admitted were diagnosed by taking history and physical examination and the diagnosis was confirmed by chest radiography which was clear and obvious and straight forward aiding the diagnosis of the disc battery ingestion in children after full and rapid diagnosis endoscopy done for all the patients and the battery removed (54%) of batteries impacted were removed by esophagoscope, and (46%) by direct laryngoscope. Despite few hours of history there was marked sloughing and erosion of the mucosa of the esophagus, and severe reaction was found in the battery and burned tissue around and stuck on it.

Among all 50 patients two patients had acquired tracheo-esophageal fistula both of them had the battery stuck in their upper esophagus and removed successfully without delayed.

Two patients were died from perforation, mediastinitis and sepsis, both of them the battery stuck in the mid-esophagus, and were delayed in referral from other governorates.

One of the cervical esophagostomy done for him and drainage of pus from the mediastinum but was collected pus and severe medical illness made the patient to die from sepsis in ICU one week later.

One patient had battery stuck in his lower esophagus and couldn't removed at that time the next day left thoracotomy done for the patient and the battery removed, there was severe perforation and mucosal erosion resection of injured area and anastomosis of the lower esophagus done.

### Discussion

All our cases were below 7 years of age, 26 cases were males, 24 cases were females, 13 cases were below one year of age, 17 cases were aged between (1-2) years, 8 cases between age of (2-3) years, 5 cases between age of (3-4) years, 4 cases between age of (4-5) years, and only 3 cases between age of (5-7) years. This goes with finding of other authors (12,13.)

Most cases of disc battery ingestion run uneventful courses and are usually benign. Severe complications are usually caused by large button batteries lodged in esophagus. Such batteries may cause necrosis or perforation of esophagus which leads to tracheoesophageal fistula, mediastinitis, pneumothorax, and even sepsis or shock with time.(5) Emergent endoscopic

management and close follow up of the clinical course are necessary when the disc battery is impacted in esophagus. Once lodged in the stomach, the battery will usually pass through the gastrointestinal tract without difficulty. Among all those patients 4 cases were asymptomatic, 41 cases had dysphagia, 2 cases had aspiration and choking, one case had surgical emphysema, and two cases had mediastinitis and one of them died after admission to ICU .

Radiography is a reliable method for establishing the location of the ingested button .

In our cases 38 case batteries were lodged in upper esophagus, 9 cases in the mid-esophagus, and only 3 cases batteries were lodged in lower esophagus. 20 cases batteries removed by direct laryngoscope, 27 cases by rigid esophagoscope, only 3 cases by the use of both.

We agree with other authors that ; button batteries lodged in the esophagus is a true emergency and the batteries should be immediately removed because of the possible fatal complications due to rapid action of the alkaline substance on the mucosa and the pressure necrosis.(14) Once lodged in the stomach, most disk batteries pass through uneventfully. Some authors have indicated that 85% of such button batteries are passed within 72 hours.(13) The benefits of H2 blockers or laxatives have not been confirmed for those patients with disc batteries in the gastrointestinal tract.(15) Surgery is indicated only if the patient develops signs of perforation or obstruction of the bowel.(16-17. (

Prevention plays an important role in button battery ingestion. We recommend that the batteries should be kept in a safe place where children are unable to reach them, also we recommend in targeting media institutes to educate the people about the great risk of batteries with the development of children toys and remote controls and audio devices .

## References

- 1 .Willam AW. Management of foreign bodies of the upper gastrointestinal tract: pdate. *GastrointestEndosc* 1995; 41:39-51.
- 2 .Kulin K, Rumack CM, Rumack BH, Duffy JP. Disk battery ingestion.Elevated urine mercury levels and enema removal of battery fragments. *JAMA* 183;249:2502-4 .
- 3 .David TJ, Ferguson AP. Management of children who have swallowed button batteries.*Arch Dis Child* 1986; 61:321-2.
- 4 .Kost KM, Hapiro RS. Button battery ingestion: a case report and review of the literature. *J Otolaryngol* 1987;16:252-7 .
- 5 Litovitz TL. Button battery ingestion. *JAMA* 1983;249:2495-500 .
- 6 .Blatnik DS, Toohill RJ, Lehman RH. Fatal complications from an alkaline battery foreign body in the esophagus.*AnnOtol* 1977;86:611-5 .
- 7 .Nolan M, Tucker I. Health risks following ingestion of mercury and zinc air batteries. *ScandAudiol* 1981;10: 189-91. 10 .
- 8 .Katz L, Cooper MT. Danger of small children swallowing hearing aid batteries. *J Otolaryngol* 1978;7:467 .
- 9 .Temple DM, McNeese MC. Hazards of battery ingestion. *Pediatrics* 1983;71:100-3 .
- 10 .Shabino CL, Feinberg AN. Esophageal perforation secondary to alkaline attery ingestion. *JACEP* 1979;8:360-2 .
- 11 .Maves MD, Carithers JS, irck HG. Esophageal burns secondary to disc battery ingestion. *Ann OtolRhinolLaryngol* 1984;93:364-9 .
- 12 .Litovitz TL, Schmitz BF. Ingestions of cylindrical and button batteries: an analysis of 2382 cases. *Pediatrics* 1992;89:745-57 .
- 13.Temple AR, Veltri JC. One
- 14 .Ito Y, Ihara N, Sohma S. Magnetic removal of alkaline batteries from the stomach. *J PediatrSurg* 1985;20:250-1.

