

CORNEAL STROMAL DEMARCATION LINE DEPTH AFTER CORNEAL COLLAGEN CROSS-LINKING FOLLOWING CONVENTIONAL VERSUS CUSTOMIZED CORNEAL EPITHELIAL DEBRIDEMENT

DOI: 10.33762/bsurg.2022.136657.1032

Received Date: 01 October 2022

Acceptance Date: 18 November 2022

Published Date: 27 December 2022

Salah Zuhair Al-Asadi *

* Ophthalmologist, Department of Surgery, College of Medicine, University of Basrah, Basrah, Iraq. salah.abed@uobasrah.edu.iq

Abstract

The study aims to Use anterior segment optical coherence tomography (AS-OCT) to compare the depth of corneal demarcation line (DL) after corneal collagen cross-linking (CXL) with subtotal versus customized corneal epithelium debridement.

This is a Prospective multi centric case-control study that enrolled 18 patients with bilateral progressive keratoconus. Both patients eyes were treated by CXL using 3 mW/cm² / 30 minutes setting. One eye with subtotal epithelial debridement (about 9 mm diameter) and the contralateral eye with customized debridement (approximately 1 mm single horizontal scratch). One month postoperatively, patients had AS-OCT imaging to detect and measure the depth of DL.

Patients' age mean was 25.17 years +/- 4.81 SD . Epithelial healing completed with in 3-7 days in conventional treatment group and demarcation line was evident in 16 eyes (89%) with a mean depth of 290.31 micro m while in customized epi-off treatment group, the epithelial healing lasted less than 24 hours and DL was detectable in 10 patients (55.5 %) with a mean DL depth of 221 micro m with a statistically significant difference ($p < 0.05$)

Subjective postoperative pain graded as "moderate to severe" in 77% of eyes underwent 9 mm epi-off CXL compared with 55% of those with customized treatment.

in conclusion; although the DL if found in majority cases, but the shallow location in customized corneal debridement cases questioned the efficacy of this technique despite the quick re-epithelialization and less postoperative pain that accompanied it.

Keywords: anterior segment optical coherence tomography (AS-OCT) , corneal collagen cross-linking (CXL), Cornea, corneal epithelium debridement.

Introduction

Keratoconus is a bilateral, usually asymmetrical noninflammatory progressive ectatic corneal disorder that can cause a significant visual morbidity. It affect the central and paracentral cornea and the cornea progressively becomes conical in shape. It typically present in puberty and is usually associated with progressive corneal thinning and irregular myopic astigmatism that may mandate transplantation ¹. Estimated incidence of keratoconus ranged from 1.3 to 22.3 cases/ 100000 and prevalence from 0.4 to 86 cases /100000 ^{2,3}. This wide range of incidence is thought to be governed by a variety of genetic and environmental factors ⁴⁻⁶. keratoconus is a common eye problem in Mid-

dle East area, including the current study locality where atopy and vernal keratoconjunctivitis is endemic ⁷⁻¹⁰. Since the introduction of collagen cross linking using ultraviolet radiation type A (UV-A) and riboflavin as a treatment option to limit the progressive keratoconus by Spoerl and Seiler at the University of Dresden ¹¹, it gained a worldwide popularity as a novel conservative strategy to halt or decrease the progression of various corneal ectasia including keratoconus, pellucid marginal degeneration, post-LASIK ectasia and keratoglobus ¹²⁻¹⁴. This technique reported to flatten the cornea and stabilize the progression of irregular astigmatism ¹⁵ with the standard protocol suggested (

Dersden protocol) that involve debridement of the central 9 mm of the corneal epithelium and application of UV-A 3mW/cm² for 30 minutes (5.4 J/cm² dose)¹⁶. UVA excite to riboflavin to liberate a singlet oxygen molecule that causes the corneal collagen fibers cross linking through polymer chains connection to each other^{17, 18}. Keratocytes apoptosis reaches to a depth of about 300 micro m leaving the posterior stroma intact¹⁹ causing increased density of extracellular matrix and change in refractive index between the anterior treated stroma and posterior stroma that is visible within one month by slit lamp examination and called "Demarcation Line" and line is thought to be a clinical sign of the depth and effectiveness of CXL^{20,21}. With the advances in anterior segment optical coherence tomography (AS-OCT) it become feasible to demonstrate the presence of DL and measure the depth with the built in calipers. The corneal epithelium physiologically acts to protect the underlying stroma due to the presence of tight junctions between its cells that preclude the intrusion of microorganisms and at the same time retard the penetration of riboflavin molecules²². So during this protocol, the de-epithelilized corneal stroma in immediate postoperative period is subjected to the attendant risk of bacterial keratitis, delayed epithelialization, persistent haze, sterile corneal infiltrate²³. At the same time, the exposed corneal nerve endings causes variable bout of pain that may be severe enough to need systemic administration of potent analgesia. In addition the central corneal stroma thickness is pathologically thinned in advanced keratoconus, thus in case of subtotal epithelial debridement there's risk of UVA-induced corneal endothelial cytotoxicity specially if the residual stromal thickness is below 400 micro m. So other protocols has been suggested to replace the conventional subtotal epi-off CXL to decrease the risk of postoperative bacterial keratitis and to provide a rapid visual rehabilitation and less postoperative pain. Suggested alternative protocols included performing CXL with intact epithelium (epi-on CXL) with or without iontophoresis that electrically direct the negatively charged riboflavin molecule into the corneal stroma and in this protocol the corneal epithelium is not breached and the need for debridement is abolished with sufficient penetration of riboflavin molecule into the corneal stroma^{24,25} but previous studies questioned the ef-

ficacy of epi-on CXL and revealed the shallow on non-evident corneal demarcation line²⁶⁻³⁰. The corneal epithelium tight junctions thought to retard the absorption of riboflavin by the corneal stroma and thus decrease the efficacy of epi-on procedure, in addition, adequate oxygen is vital for effective cross linking is decreased as the epithelium acts as a barrier³¹, also the corneal epithelium metabolic activity far exceed the stroma so the oxygen needed is consumed by the intact epithelium in epi-on procedures which is a crucial factor for successful crosslinking³².

We suggested performing corneal cross linking with a customized limited epithelial debridement much less than the classical subtotal 9mm diameter to decrease the immediate postoperative pain and time needed for complete epithelial healing, hence decrease the grave risk of postoperative bacterial keratitis and at the same time gain the advantage of opening a path for the riboflavin to pass unimpeded by the corneal epithelium tight junctions and thus decrease the time for visual rehabilitation without compromise the effectiveness of the corneal stiffening.

Aim of study

To compare the clarity and depth of corneal stromal demarcation line in subtotal versus limited epithelial corneal debridement before C3R using anterior segment optical coherence tomography.

Patients and Methods

This is randomized prospective study conducted in Ophthalmology Center of Basrah General Hospital, south of Iraq. All patients signed informed consent and according to the ethical committee of college of Medicine, University of Basrah.

This study enrolled 18 patients from February 2018 to October 2019, with documented bilateral progressive keratoconus who had grade I to III according to Amsler-Krumeich classification^{33,34} with documented progression. The progression criteria was one or more of the following:

- increased K-max reading by 1D or more
- refractive error changes (> 0.5 D sphere or > 1.0 D cylinder)
- decreasing Best Corrected Visual Acuity (BCVA) by two lines or more

Exclusion criteria

K-max>60.

- Central Corneal thickness <400µm
- Corneal epithelial healing disorders
- Previous herpes keratitis
- Corneal scar
- Corneal melting disorders
- Pregnancy

All patients underwent a thorough ophthalmological examination including BCVA, slit lamp examination, tonometry and baseline corneal topography using Scheimpflug camera device (Sirius, CSO). Patients underwent successive CXL of both eyes in same session. under sterile aseptic technique After adequate topical anesthesia with 0.5% Proparacaine drop 2 drops every 5 minutes for 15 minutes, one eye underwent subtotal debridement of central 9 mm of the corneal epithelium and the contralateral eye had a limited rebridement of a narrow horizontal line of central corneal that does not exceed 4x1 mm dimensions using a small corneal scraper then the corneal stroma is soaked with riboflavin (Ricola, Softe) 0.1% solution in 20% Dextrose one drop every 3 minutes for 30 minutes. After disinfection and draping, lid speculum is inserted and the eye is irradiated using UVA 370 nm (CBM Vega X-linker, CSO) with setting of 3.0 mW/cm² energy and 8 mm beam diameter for 30 minutes during this period the patient is asked to fixate on the flashing target light, during which time continue riboflavin drop every 5 minutes and topical anesthesia when needed. postoperatively, bandage contact lens fitted after adequate rinsing of riboflavin with Sodium Chloride 0.9% saline and the patient prescribed Tobramycin drop 0.3% solution (Tobrex , Alcon) and oral analgesics on need

and followed closely waiting for complete corneal healing when the bandage contact lens is removed topical steroids and antibiotic mixture (Tobramycin 3mg and Dexamethasone 1mg suspension) Tobradex, Alcon drop prescribed 4 times daily for 2 weeks and tapered over 1 month. The patient is asked to describe the pain out of 3 descriptions (mild, moderate and severe) and the time needed for complete re-epithelialization is recorded in days. Anterior segment OCT imaging using Nidek RS-3000 platform is performed at the end of first postoperative month to evaluate the presence and depth of corneal stromal demarcation line and the depth measured by the built in caliper. The three researchers evaluated the clarity and depth of the DL and questionable clarity is excluded from the study statistics.

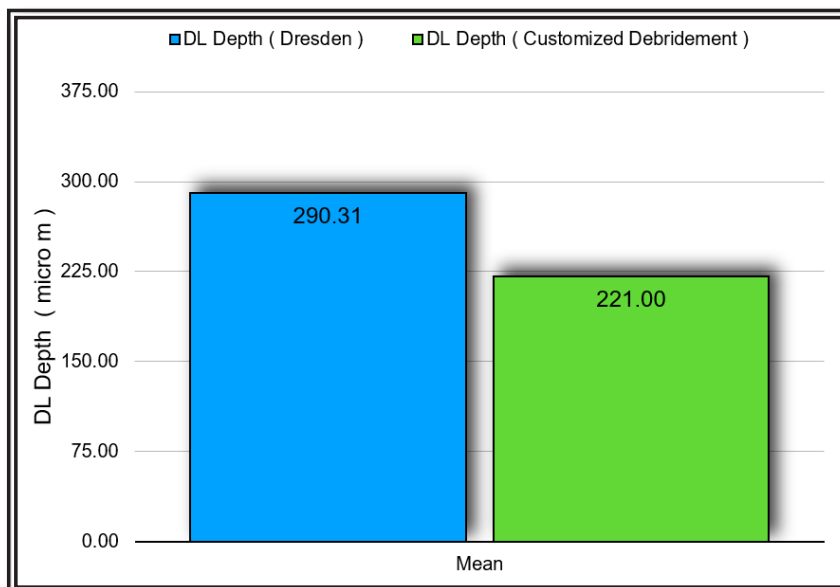
Statistical Analysis

Analysis performed using SPSS software (SPSS, Inc.) version 24 and Numbers software (Machintosh). We used means, standard deviation, range and Mann-Whitney U tests. P value of less than 0.05 considered statistically significant.

Results

The corneal epithelium healed within 3-7 days in 9 mm epi-off CXL, on the other hand, all eyes with customized epi-off technique healed within 24 hours.

Subjective postoperative pain graded as “moderate to severe” in about 77% of eyes underwent 9 mm epi-off CXL compared with 55% of those with customized treatment.



Discussion

Efficacy of CXL is well documented *in vitro* by Wollensak et al who demonstrated increased rigidity of treated human cornea by 4.5 times³⁵, but this experiment is not suitable for clinical testing of the efficacy of CXL as it used a stripped corneal tissue, so clinical indications of effectiveness are suggested including confocal microscopy and density and depth of demarcation line using AS-OCT.

In this study, out of enrolled 18 patients underwent classical CXL by Dresden protocol with 9 mm de-epithelialization, 2 eyes only had indeterminate DL with faint anterior stromal hyper reflectivity (about 11% of cases), on the other hand, 5 eyes with customized epi-off cases did not show a clear DL (about 28%) of cases.

The statistically shallow DL in customized epi-off CXL group reflects decreased volume of corneal tissue treated and indicated relatively less efficacy than those eyes treated with conventional protocol. Corneas with custom epi-off technique showed less DL depth previous reports demonstrated that a shallow DL give a clue about the effectiveness of CXL and its stabilizing effect^{36,37}. The shallow demarcation line in this study results may reflect the decreased corneal tissue volume subjected to the direct exposure to UV-A impeded by the intact epithelium due to the limited area of debridement and this reflect the relative decrease in efficacy of custom epi-off CXL. This result coincide with other previous studies assessed the efficacy of different CXL protocols²⁶⁻³⁰.

This robustly demonstrates that the conventional CXL is still the most effective strategy for sufficient corneal stiffening to halt KC progression

References

1. Davidson AE, Hayes S, Hardcastle AJ, et al. The pathogenesis of keratoconus. *Eye*. 2014;28:189e95. <https://doi.org/10.1038/eye.2013.278>.
2. Gordon-Shaag A, Millodot M, Shneur E, Liu Y. The genetic and environmental factors for keratoconus. *Biomed Res Int*. 2015;2015:795738. <https://doi.org/10.1155/2015/795738>
3. Godefrooij DA, Ardine de Wit G, Uiterwaal CS, et al. Age-specific incidence and prevalence of keratoconus: a nationwide registration study. *Am J Ophthalmol*. 2017;175:169e72. <https://doi.org/10.1016/j.ajo.2016.12.015>
4. Mas Tur, V., MacGregor, C., Jayaswal, R., O'Brart, D., & Maycock, N. (2017). A review of keratoconus: Diagnosis, pathophysiology, and genetics. *Survey of Ophthalmology*, 62(6), 770–783. <https://doi.org/10.1016/j.survophthal.2017.06.009>
5. Krachmer JH, Feder RS, Belin MW. Keratoconus and related non-inflammatory corneal thinning disorders. *Surv Ophthalmol*. 1984;28:293e322. [https://doi.org/10.1016/0039-6257\(84\)90094-8](https://doi.org/10.1016/0039-6257(84)90094-8)
6. Hammerstein W. Zur genetic des keratoconus. *Albrecht Von Graefes Arch Klin Exp Ophthalmol*. 1974;190:293e308. <https://doi.org/10.1007/BF00407890>
7. Naderan M, Jahanrad A, Farjadnia M. Clinical biomicroscopy and retinoscopy findings of keratoconus in a Middle Eastern population. *Clin Exp Optom*. 2018;101(1):46-51. doi:10.1111/cxo.12579

and customized epithelial debridement is still to be revised. Kaya V et al. investigated custom epi-off CXL in which they preserved the epithelium over critically thin cornea as a trial to decrease the corneal endothelial cells damage and showed limited area of keratocytes apoptosis studied by confocal microscopy with absence of demarcation line beneath the area of intact epithelium³⁰. The study reliability needs to be strengthened in view of the small sample size of two patients.

New protocols of CXL aimed principally to decrease the operative time and postoperative complications. Epi-on protocols aimed in addition to decrease the UVA-induced corneal endothelial cells damage but few research questioned its efficacy in terms of shallow demarcation line³⁸. Preservation of intact epithelium is thought to decrease the penetration of riboflavin to corneal stroma and also decrease the oxygen available for adequate cross linking³².

Conclusion

Although we have a theoretical decrease in potential complications of corneal de-epithelialization by performing a custom epi-off CXL, but still the effectiveness of in not as equal to the classical protocol using a 9 mm epithelial debridement.

Disclosure

We have no financial interest to disclose

Authership & conflict of interest

This is to verify authership of this article and there is no conflict of interest in any way.

8. Mořtovoy D, Vinker S, Mimouni M, Goldich Y, Levartovsky S, Kaiserman I. The association of keratoconus with blepharitis. *Clin Exp Optom*. 2018;101(3):339-344. doi:10.1111/cxo.12643
9. Totan Y, Hepřen IF, Cekiç O, Gündüz A, Aydın E. Incidence of keratoconus in subjects with vernal keratoconjunctivitis: a videokeratographic study. *Ophthalmology*. 2001;108(4):824-827. doi:10.1016/s0161-6420(00)00664-3
10. Assiri, A. A. (2005). Incidence and severity of keratoconus in Asir province, Saudi Arabia. *British Journal of Ophthalmology*, 89(11), 1403–1406. doi:10.1136/bjo.2005.074955
11. SPOERL, E., HUHLE, M., & SEILER, T. (1998). Induction of Cross-links in Corneal Tissue. *Experimental Eye Research*, 66(1), 97–103. doi:10.1006/exer.1997.0410
12. Wollensak G, Spoerl E, Seiler T. Riboflavin/ultraviolet-A-induced collagen crosslinking for the treatment of keratoconus. *Am J Ophthalmol*. 2003;135(5):620–627. [https://doi.org/10.1016/s0002-9394\(02\)02220-1](https://doi.org/10.1016/s0002-9394(02)02220-1)
13. Spadea L. Corneal collagen cross-linking with riboflavin and UV-A irradiation in pellucid marginal degeneration. *J Refract Surg*. 2010; 26(5):375–377. <https://doi.org/10.3928/1081597x-20100114-03>
14. Ziaei M, Barsam A, Shamie N, et al; ASCRS Cornea Clinical Committee. Reshaping procedures for the surgical management of corneal ectasia. *J Cataract Refract Surg*. 2015;41(4):842–872. <https://doi.org/10.1016/j.jcrs.2015.03.010>
15. Spoerl E, Huhle M, Seiler T. Induction of cross-links in corneal tissue. *Exp Eye Res*. 1998;66(1):97–103. <https://doi.org/10.1006/exer.1997.0410>
16. Spoerl E, Seiler T. Techniques for stiffening the cornea. *J Refract Surg*. 1999;15(6):711–713. <https://doi.org/10.3928/1081-597x-19991101-21>
17. Kamaev P, Friedman MD, Sherr E, Muller D. Photochemical kinetics of corneal cross-linking with riboflavin. *Invest Ophthalmol Vis Sci*. 2012;53(4):2360–2367. <https://doi.org/10.1167/iovs.11-9385>
18. Mazzotta C, Balestrazzi A, Baiocchi S, Traversi C, Caporossi A. Stromal haze after combined riboflavin-UVA corneal collagen cross-linking in keratoconus: in vivo confocal microscopic evaluation. *Clin Experiment Ophthalmol*. 2007;35(6):580–582. <https://doi.org/10.1111/j.1442-9071.2007.01536.x>
19. Wollensak G, Spoerl E, Wilsch M, Seiler T. Keratocyte apoptosis after corneal collagen cross-linking using riboflavin/UVA treatment. *Cornea*. 2004;23(1):43–49. <https://doi.org/10.1097/00003226-200401000-00008>
20. Seiler T, Hafezi F. Corneal cross-linking-induced stromal demarcation line. *Cornea*. 2006;25(9):1057–1059. <https://doi.org/10.1097/01.icc.0000225720.38748.58>
21. Kymionis GD, Tsoulnaras KI, Liakopoulos DA, Skatharoudi CA, Grentzelos MA, Tsakalis NG. Corneal stromal demarcation line depth following standard and a modified high intensity corneal cross-linking protocol. *J Refract Surg*. 2016;32(4):218–222. <https://doi.org/10.3928/1081597x-20160216-01>
22. Randleman JB, Khandelwal SS, Hafezi F. Corneal cross-linking. *Surv Ophthalmol*. 2015;60(6):509–523. <https://doi.org/10.1016/j.survophthal.2015.04.002>
23. Spadea L, Salvatore S, Paroli MP, Vingolo EM. Recovery of corneal sensitivity after collagen crosslinking with and without epithelial debridement in eyes with keratoconus. *J Cataract Refract Surg*. 2015;41(3):527–532. <https://doi.org/10.1016/j.jcrs.2014.06.030>
24. Raiskup F, Spoerl E. Corneal crosslinking with riboflavin and ultraviolet A. I. Principles. *Ocul Surf*. 2013;11(2):65–74. <https://doi.org/10.1016/j.jtos.2013.01.003>
25. Ziaei M, Barsam A, Shamie N, et al; ASCRS Cornea Clinical Committee. Reshaping procedures for the surgical management of corneal ectasia. *J Cataract Refract Surg*. 2015;41(4):842–872. <https://doi.org/10.1016/j.jcrs.2015.03.010>
26. Eraslan, M., Toker, E., Cerman, E., & Ozarslan, D. (2017). Efficacy of Epithelium-Off and Epithelium-On Corneal Collagen Cross-Linking in Pediatric Keratoconus. *Eye & Contact Lens: Science & Clinical Practice*, 43(3), 155–161. <https://doi.org/10.1097/icl.0000000000000255>
27. Al Fayezi, M. F., Alfayez, S., & Alfayez, Y. (2015). Transepithelial Versus Epithelium-Off Corneal Collagen Cross-Linking for Progressive Keratoconus. *Cornea*, 34, S53–S56. DOI: 10.1097/ICO.0000000000000547
28. Torres-Netto EA, Kling S, Hafezi N, Vinciguerra P, Randleman JB, Hafezi F. Oxygen Diffusion May Limit the Biomechanical Effectiveness of Iontophoresis-Assisted Transepithelial Corneal Cross-linking. *J Refract Surg*. 2018;34(11):768-774. <https://doi.org/10.3928/1081597x-20180830-01>
29. Torres-Netto EA, Randleman JB, Hafezi NL, Hafezi F. Corneal stromal demarcation line after 4 protocols of corneal crosslinking in keratoconus determined with anterior segment optical coherence tomography. *J Cataract Refract Surg*. 2018;44(12):1535. doi:10.1016/j.jcrs.2018.08.034

30. Kaya V, Utine CA, Yilmaz OF. Efficacy of corneal collagen cross-linking using a custom epithelial debridement technique in thin corneas: a confocal microscopy study. *J Refract Surg.* 2011;27(6):444-450. <https://doi.org/10.3928/1081597x-20101201-01>
31. Kling S, Hafezi F. An algorithm to predict the biomechanical stiffening effect in corneal cross-linking. *J Refract Surg* 2017; 33:128–136. <https://doi.org/10.3928/1081597x-20161206-01>
32. Freeman, R. D. (1972). Oxygen consumption by the component layers of the cornea. *The Journal of Physiology*, 225(1), 15–32. <https://doi.org/10.1113/jphysiol.1972.sp009927>
33. Amsler, M. (1946). Kératocône classique et kératocône fruste; arguments unitaires. *Ophthalmologica*, 111(2-3), 96–101. DOI:10.1159/000300309
34. Kamiya, K., Ishii, R., Shimizu, K., & Igarashi, A. (2014). Evaluation of corneal elevation, pachymetry and keratometry in keratoconic eyes with respect to the stage of Amsler-Krumeich classification. *British Journal of Ophthalmology*, 98(4), 459–463. <https://doi.org/10.1136/bjophthalmol-2013-304132>
35. Wollensak G, Spoerl E, Seiler T. Stress-strain measurements of human and porcine corneas after riboflavin-ultraviolet-A-induced cross-linking. *J Cataract Refract Surg.* 2003;29:1780-1785. [https://doi.org/10.1016/s0886-3350\(03\)00407-3](https://doi.org/10.1016/s0886-3350(03)00407-3)
36. Moramarco, A., Iovieno, A., Sartori, A., & Fontana, L. (2015). Corneal stromal demarcation line after accelerated crosslinking using continuous and pulsed light. *Journal of Cataract & Refractive Surgery*, 41(11), 2546–2551. <https://doi.org/10.1016/j.jcrs.2015.04.033>
37. Caporossi, A., Mazzotta, C., Paradiso, A. L., Baiocchi, S., Marigliani, D., & Caporossi, T. (2013). Transepithelial corneal collagen crosslinking for progressive keratoconus: 24-month clinical results. *Journal of Cataract & Refractive Surgery*, 39(8), 1157–1163. <https://doi.org/10.1016/j.jcrs.2013.03.026>
38. Spadea, L., Di Genova, L., & Tonti, E. (2018). Corneal stromal demarcation line after 4 protocols of corneal crosslinking in keratoconus determined with anterior segment optical coherence tomography. *Journal of Cataract & Refractive Surgery*, 44(5), 596–602. <https://doi.org/10.1016/j.jcrs.2018.02.017>