

A method of Craniofacial suspension of the fractured middle third of facial skeleton through a cranial arch bar

A method of Craniofacial suspension of the fractured middle third of facial skeleton through a cranial arch bar

*** Dr.Ghalib Abid Humaidi BDS,FFDRCSI**

ABSTRACT :

Fractures of the middle third of the facial skeleton which associated with the fractured zygomatic process of the frontal bone and or fractured zygomatic arch are happened . And in these cases it was difficult to use frontal or zygomatic suspension for fixation . A technique is described which enables the majority of these fractures to be fixed by maxillary or mandibular suspension to the cranial arch bar implanted inside a plaster of Paris head cap . The plaster head cap can be done in the clinic or in the ward and the only thing you need to do in the theater is reduction and suspension . The benefits of the patient and the hospital are highlighted .

Keywords : Craniofacial suspension , cranial arch bar .

*Department of surgery Thi-Qar Medical College

INTRODUCTION:

Fractures of middle third specially Le fort I , II , III of the facial skeleton are frequent injuries seen at that region in oral surgery practice . The techniques for fixation of Le fort I , II , III of the middle third of facial skeleton are many . In 1942 , Adams introduced a new method of treating fractures of the middle third of facial skeleton , to suspend a mobile part below to a firm stable part above the fracture by means of a subcutaneous wire . The stable point of fixation which he described was to the fronto

zygomatic suture which is now termed lateral frontal suspension . Kufner 1970 introduced his method of craniofacial suspension now termed central frontal suspension . Provided that the frontal bone is intact , a fixed stable point is taken above the frontal sinus to introduce a Roger Anderson pin from which the fractured maxilla is suspended by wires . More recently stol et al .(1982) advocate the use of two contoured mini-bone plates which are screwed above to the frontal bone centrally and below on each side to the frontal process of the maxillary bone . External skeletal fixation is still

advocated by some (Georgiade et al . 1981) . The primary indication for external skeletal fixation of the mid-face is the presence of antero-posterior instability of the facial skeleton . This situation is classically seen when the mid-face fracture is associated with concomitant bilateral condylar fractures of the mandible . There are four methods of external skeletal fixation which are in general use at the present time 1.plaster of Paris head cap , 2.Halo frame , 3.Box frame , 4. Levant frame . All of these systems involve the use of external rods and universal joints to link the base of skull via the cranium , to the maxilla or mandible via cap splints , Gunning type splints or arch bars . The following method has been used by the author enabling many of the fractured facial skeleton seen , in the oral surgery clinic , to be fixed part on an outpatient clinic or in the ward and part in the theater and this will be comfortable to the patient and at the same time it will reduce the theater time to be convenient to the hospital

METHOD:

The lefort I , II , III fractured of the middle third of the facial skeleton which associated with fracture zygomatic arch or zygomatic processes of frontal bone or both make their fixation through circum zygomatic or frontal suspension impossible . And the external skeletal fixation need special equipments which is not always available also silver cap splint need special laboratory work . This method make combination between internal skeletal suspension and external skeletal fixation which element all of

these difficulties in both techniques . It is simply consist of cranial arch bar addepted to the cranium with two soft stainless steel wires fixed on both side of the cranial arch bar to make two triangles one on each side it is anterior angle above the fronto – zygomatic suture , posterior angle three fingers backward and it`s tip downward two fingers above zygomatic arch and from that tip a cranio- maxillary or mandibular suspension will be made which is a combination between external fixation (Plaster of Paris head cap) and the suspension wires of the internal frontal suspension.

TECHNIQUE

DETAILS

The cranial arch bar suspension technique which I call for suspension of lefort I , II , III fractures can be done simply , part in the out patient clinic or in the ward and part in the theater as fallows : 1-The patient hair either collected on top of the head and tieded up with a ribbon in female and long hair patient with closely trimming of the hair at the sides particularly around the mastoid process and over the occipital protuberance .2- Plastic protective clothing is used to cover the patient and secured around the patient ; neck . 3- Stockinet sleeve is passed over the patients head without disturbing the hair and left covering the face to protect the eyes and any associated wounds from being splashed with plaster 4-Afetr immersion in cold water until all bubbles cease to rise , the plaster bandage is squeezed free from excess

A method of Craniofacial suspension of the fractured middle third of facial skeleton through a cranial arch bar

moisture and the first turn is taken around the head the lower border passing horizontally from the mark just above the supra-orbital ridges to the back of the head and it must be fitted correctly on the head .

5-The second bandage should be applied rather up the fore head and the first bandage should be taken low down below the occiput posteriorly . 6- Additional two bandages applied at the same maner . 7-After the first four bandages are in position the cranial arch bar is adjusted until it lie accurately as fitted and tighted circle against the head cap surface 8-The cranial arch bar is hold level by an assistant and the two triangles made with the cranial arch bar one in each side by soft stainless steel wire . The anterior angle of the triangle should lie above the fronto-zygomatic sututer and the posterior angle three fingers backward . The cranial arch bar form it's base while it's tip should be two fingers above the zygomatic arch leveled slightly above the fronto zygomatic suture 9- Then a fifth bandage is applied over the cranial arch bar putting in mind not to cover the tip of the triangle and the cranial arch bar should be embedded in the plaster 10- After another layer of plaster putted around the arch bare and the arch bar adequately embedded in the fasion the stockinet is cut off 0.5 cm from the margins of the plaster head cap . And turned downward in the upper border and up ward in the lower border and another layer of plaster bandage putted around . 11-Macke the plaster head cap with your fingers until the plaster has set and at that stage the patient will be ready for the cranial

suspension in the theater In the theater : the only thing you need to do in the theater is reduction of leforte I , II , III fractures of the middle third of facial skeleton by Rowe disimpaction forcepes or other disimpaction forcepes designed to the same purpose and then cranio maxillary or cranio mandibular suspension by passing a sterile soft stainless steel wire around the tip of the triangle and holding the two ends of the same wire and threaded through the eye of a Rows zygomatic awl and creped . the awl is then passed below the tip through the skin and pushed downwards and forwards behind the frontal process of zygomatic bone (deep to the zygomatic arch) to pierce the oral mucosa in the upper buccal sulcus adjacent to the molar teeth . The wire end are detached from the awl and secured with heavy artery clip , and the awl is then with drawn . And then the suspension wire fixed around the maxillary or mandibular dental arch bar after inter maxillary fixation .

RESULTS:

Since 1990 the author has preformed this procedure on group of patients with leforte I , II , III fractures at Rasheed Military hospital . The majority were male with a different ages , and always the procedure was acceptable according to the patients . The pre operative symptoms were those usually see with lefort I , II , III fractures type of facial skeleton these included swelling and bruising , oedema of the face , bleeding from the nose , mobility of the upper jaw , and disturbance of occlusion (gagging the bit open) , circum orbital and

subconjunctival ecchymosis develop later, ballooning of the face, bulging of the eyelids. Post operative recovery was complete in all cases. The complications to note that in one patient there was an infection around the entrance of suspension wire through the skin which was treated successfully with antibiotic. The other patients did very well with complete healing of LeFort I, II, III fractures of the facial skeleton

DISCUSSION :

The two things to consider are the external skeletal fixation and the internal skeletal suspension combined together to form the cranial arch bar suspension. External skeletal fixation: This method is still advocated by some (Greogiadet al. 1981). External skeletal fixation formed the principle basis for stabilization of the mid-face fracture. This method of treatment produces satisfactory results when there is minimal displacement at the LeFort I and II levels, and accurate alignment may not be achieved at LeFort III level with a gross separation. There are four common methods of external skeletal fixation: 1- Plaster of Paris head cap; 2- Haloframe (various designs); 3- Boxframe; 4- Levant frame. In these systems they need external rods and universal joints to link the base of the skull, via the cranium, to the maxilla or mandible, via cap splints, gunning type splints, or arch bars, when the cranial element of fixation is by means of a head cap, with intervening mobile scalp between the plaster and the bone the method is referred to as (indirect external fixation). When the fixation is applied by pins to the outer table of

the skull the term (direct external fixation) is employed. The disadvantages of external skeletal fixation is that it lengthens the period of hospitalization and it is contraindicated in mental confusion, cerebral irritation, epilepsy which might lead to further injury or dislodgement of the appliance. Internal skeletal suspension: In 1942 Adams introduced a new method of treating fractures of the middle third of the facial skeleton by suspension a mobile part to a firm stable part above the fracture by means of subcutaneous wire. Which is comfortable to the patient and accurate to the surgeon but it has the disadvantages of applying backward pull which might lead to subsequent relapse. Kufner (1970) introduced his method of craniofacial suspension, now termed central frontal suspension, through an external Roger Anderson pin fixed above the frontal sinus with 0.5 cm penetration which he proved safe bone depth on a CT scan survey. The disadvantages of internal skeletal suspension are that it is not rigid and exerts backward pull which might lead to relapse. The common methods of internal skeletal suspension are

- 1- Frontal suspension,
- 2- Circumzygomatic suspension,
- 3- Infraorbital suspension,
- 4- Circumpalatal suspension. A combination of external skeletal fixation and internal skeletal suspension through a cranial arch bar is the method which I use. This method consists of a Plaster of Paris head cap which is part of the external skeletal fixation and subcutaneous suspension wire which is part of the

A method of Craniofacial suspension of the fractured middle third of facial skeleton through a cranial arch bar

internal skeletal suspension joint together by a triangle of soft stainless steel wire which is fixed to the cranial arch bar its base up and tip down in both sides of the temporal region and the cranial arch bar embedded inside the plaster of Paris head cap. So the tip of the triangle of soft stainless steel wire represent the fixed point to which the frontal suspension depend which is the zygomatic process of frontal bone and at the same time it will be at the same level and closed to that holes which normally used for frontal suspension in the zygomatic process of frontal bone. And this will prevent surgical exposure and drilling of that process and gives more stability to the plaster of Paris head cap. and element these rods and joints which is used in external skeletal fixation which make very much embarrassment to the patient and at the same time this technique will shorten the stay of the patient in the hospital in case of using the external skeletal fixation with Halo frame or box frame. Or the projecting frame work with its connections in case of using plaster of Paris head cap.

CONCLUSION:

A technique is described for the fixation of the fractures of the middle third of facial skeleton lefort I, II, III through cranio-mandibular, or cranio-maxillary suspension from a cranial arch bar imbedded inside a Plaster of Paris head cap to a dental arch bar, silver cap splint or gunning splint. The advantages of this technique for treating a common fractures are described these may be summarized as

follows:

- 1-Easy and simple procedure and this will aid for : A. Easy to be used for beginner maxillofacial surgeons . B. Need simple and available materials C. Less time consuming in the theater D. Suitable for old age and medically unfit patient.
- E. Beneficial when you have large number of patients . F. It does not need supra orbital incision and drilling.
- 2- It can be used when there is fracture in the zygomatic process of frontal bone or fracture zygomatic arch . Which make frontal and zygomatic suspension impossible .
- 3- It can be tolerated more than the halo frame in hot climate .
- 4- It is less costly than the internal suspension or external fixation .
- 5-The patient can be discharged early from the hospital.
- 6-You can tight the suspension wire if it became loose during healing period and even you can change the wire when it is broken under local anesthesia
- 7- The suspension wire easy to removed after complete treatment .
- 8- Over come the complications which can be happened with frontal and circumzygomatic suspension like damage to the eye , facial nerve and failure to pass the wire around the zygomatic arch .
- 9-You can do the plaster of Paris head cap with cranial arch bar in the ward for patients with associated injuries .
- 10-The vertical pull of the suspension wire in both sides will create a good fixation for the fractured middle third at the same time good stabilization of the plaster of Paris head cap .
- 11- It will leave invisible scar in the temporal region.
- 12-Plaster of Paris Head cap with cranial arch bar and the dental arch

bars can be done in the clinic to reduce the theater time . 13- It is more acceptable by the patient than the other types of external skeletal fixation of the fractured middle third of facial skeleton .

DISADVANTAGES

1-It cannot be used with patients need craniotomy 2-In depressed fracture of the skull it is difficult to be used 3-In server lacerations in the scalp make procedure unacceptable.

Table 1

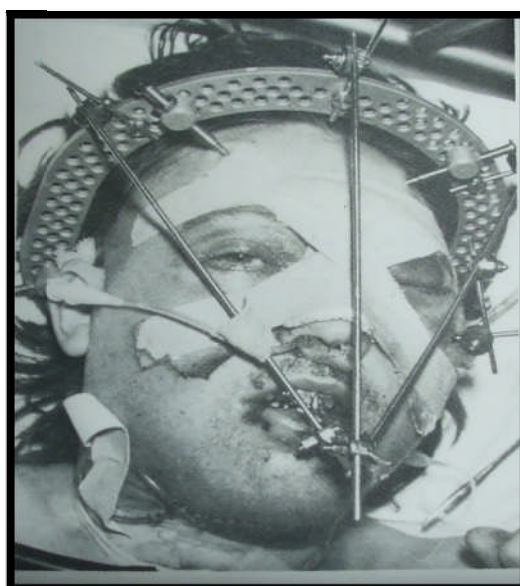Age	Sex	Type of fracture	Anaesthesia	Complication
21	M	Leforte fracture	G.A	none
25	M	Leforte fracture	L.A+G.A	none
29	M	Leforte fracture	L.A+G.A	none
22	M	Leforte fracture	L.A+G.A	Lacks suspension wire
30	M	Leforte fracture	L.A+G.A	none
27	M	Leforte fracture	G.A	none
22	M	Leforte fracture	L.A+G.A	none
22	M	Leforte fracture	L.A+G.A	none
39	M	Leforte fracture	G.A	Infected suspension wire
19	M	Leforte fracture	L.A , G.A	none

L.A.=Local anaesthesia with 2% lignocaine

G.A.=General anaesthesia

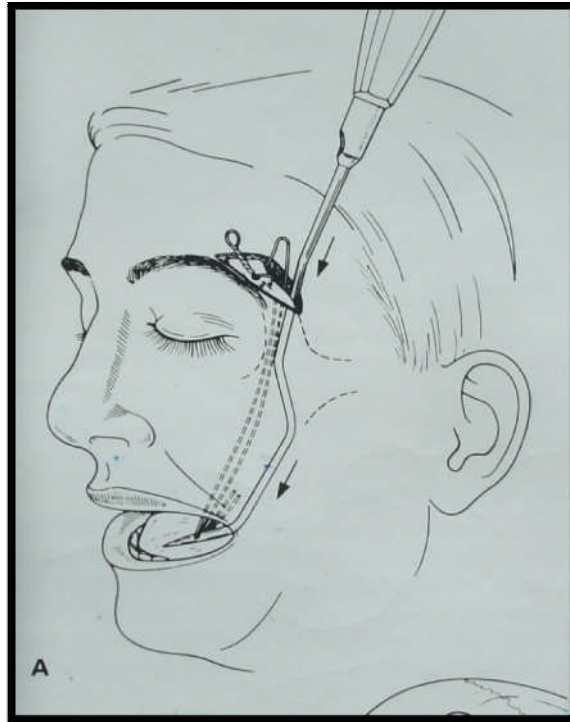
Note : In server leforte fractures the dental arch bars not fixed with local anaesthesia

Halo frame for external skeletal fixation of the middle third fracture

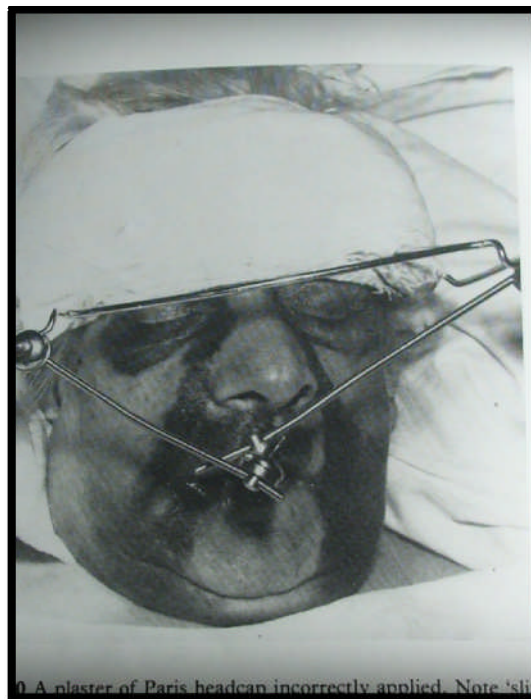

A method of Craniofacial suspension of the fractured middle third of facial skeleton through a cranial arch bar

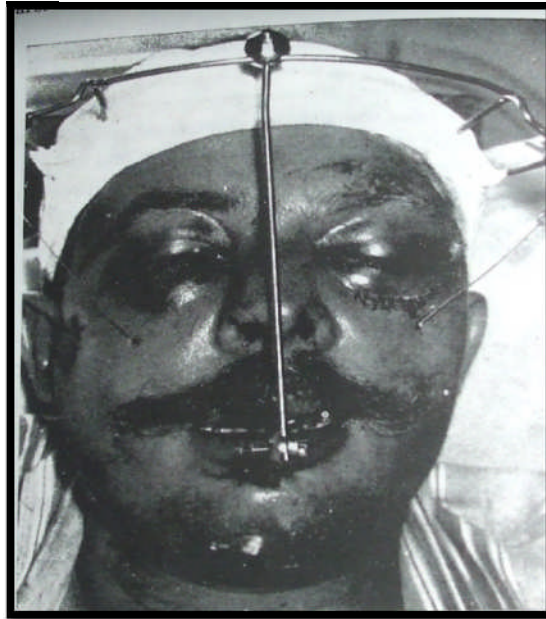Frontal skeletal suspension



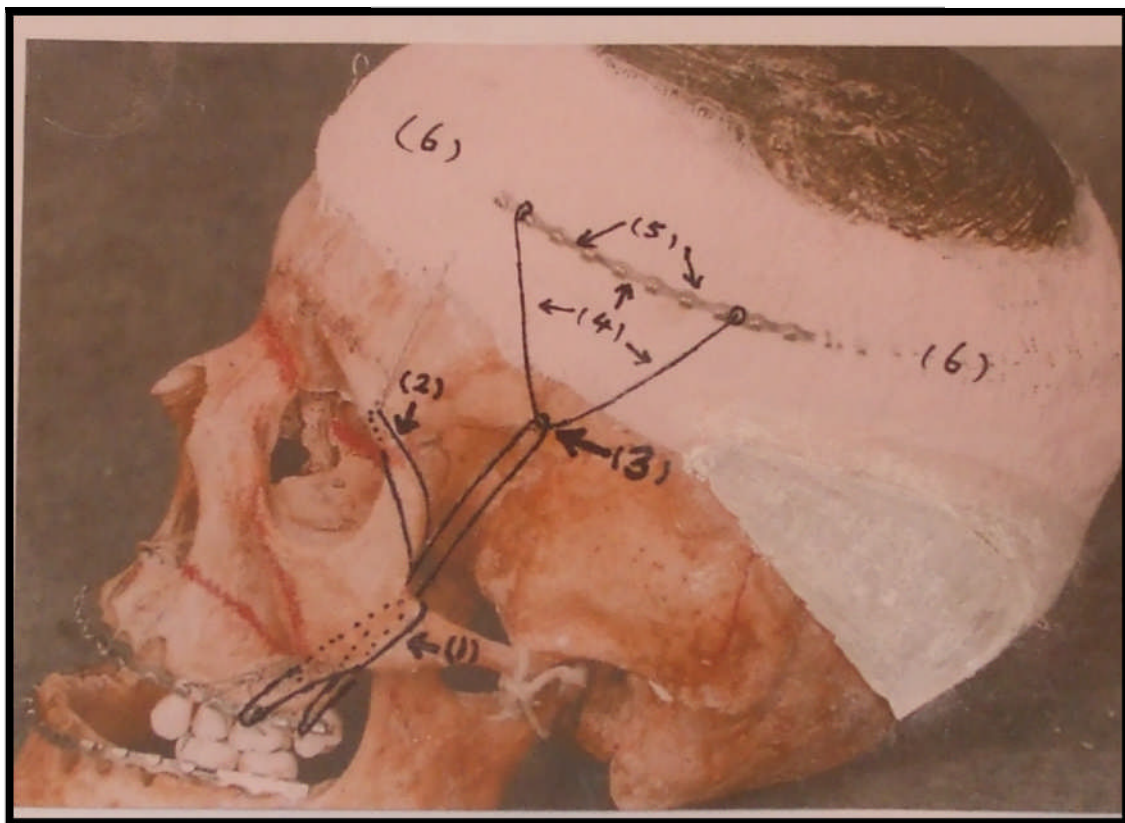
Faller plaster of Paris head cap with roads and Joints



**plaster of Paris head cap for external skeletal
fixation**

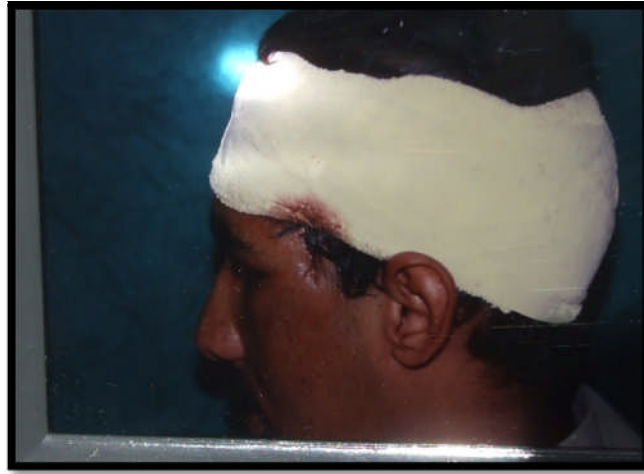

1-Circum zygomatic suspension 2-Frontal suspension 3-Cranial arch bar
suspension 4-The triangle 5- The cranial arch bar
6- Plaster of Paris head cap

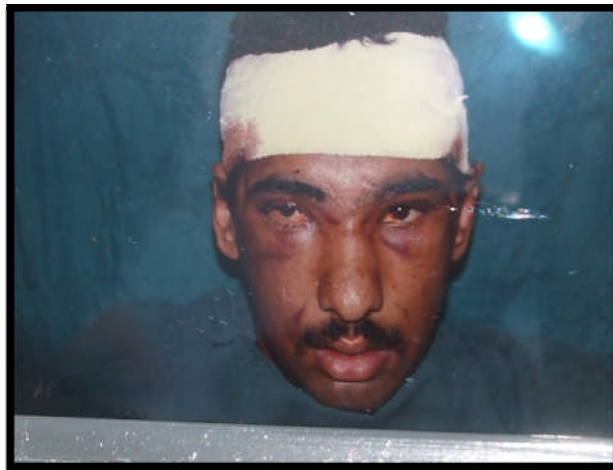

A method of Craniofacial suspension of the fractured middle third of facial skeleton through a cranial arch bar

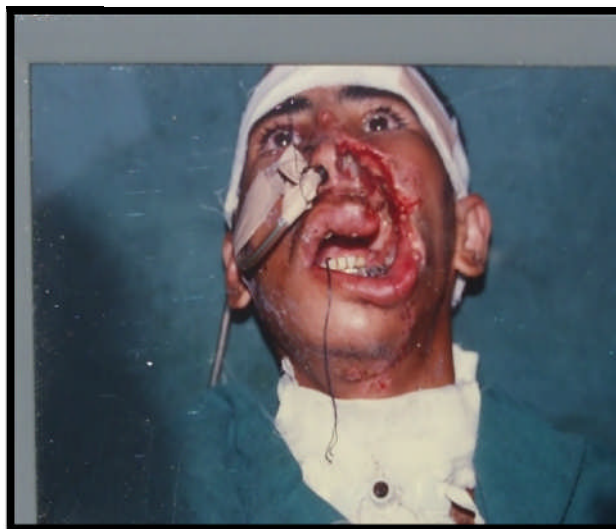Leforte III fracture treated by cranial arch bar suspension



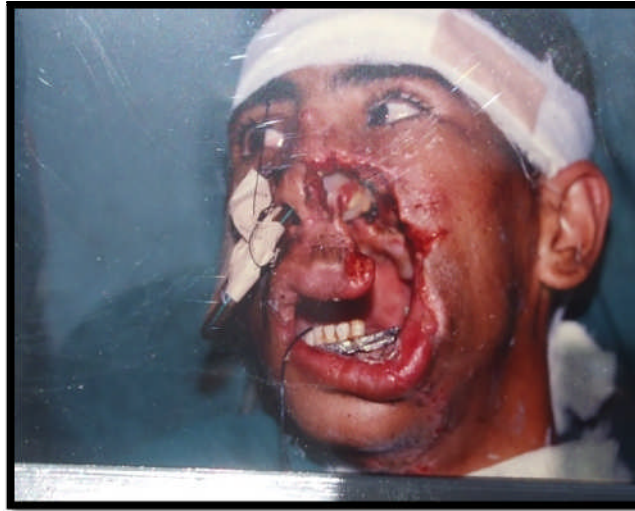The same patient



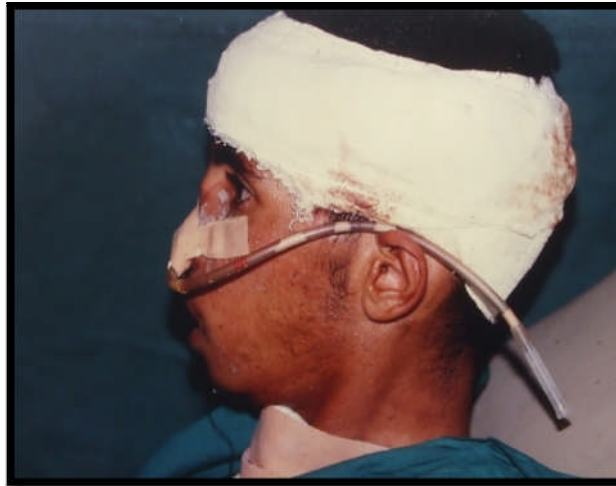Severe maxillofacial injury with Leforte fractures pre operative



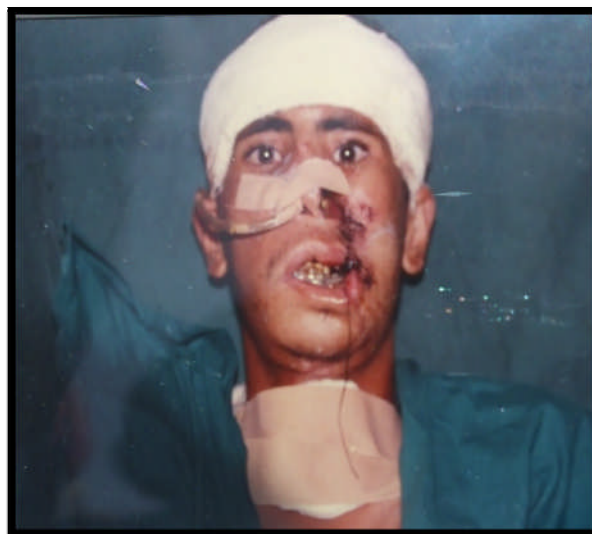The same patient pre operative



The same patient treated by cranial arch bar suspension post operative

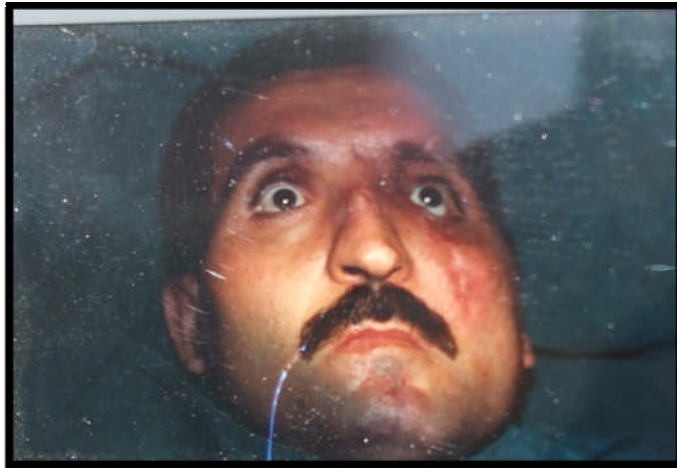

The same patient post operative

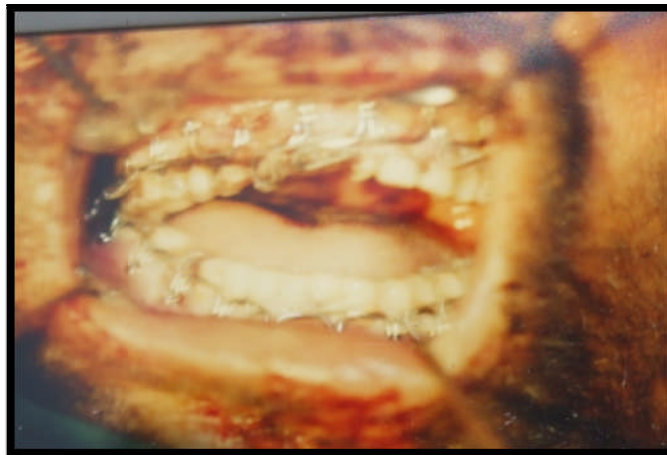

A method of Craniofacial suspension of the fractured middle third of facial skeleton through a cranial arch bar

The same patient postoperative



**Severe road traffic accident injury (patient face crashed between two cars)
with Leforte I , II , III fractures . the first patient treated by cranial arch bar
suspension preoperative**



The same patient postoperative



Severe maxillofacial war injury treated by cranial arch bar suspension



REFERENCES

1-Brown , P. , Fryer , I. & Mac Dowell , R.(1952) . Internal wire pin fixation fractures of upper face , orbit zygoma and sever facial crushes . Plastic and Reconstructive surgery , 9 , 276 .

2- Crawford , M.J (1943) Appliances and attachment for treatment of upper jaw fractures . U.S. Naval Medical Bulletin , 41 , 1151.

3- Crew, T.C.(1963) Facial trans fixation in maxillofacial injuries . The New Zealand dental Journal , 59 , 201 .

4-Dawson ,R.L.G& Fordyce , G.L(1953) . Complex fractures of the middle third of the face and their early treatment . British Journal of surgery , 41 , 254 .

5- Geogiade , N. , Geogiade , G. , Serafin , D. & Riefhohl , R. (1981) . Twenty – five year evaluation of external halo fixation for sever maxillofacial injuries . Plastic and reconstructive surgery , 68 ,444 .

6- Geargaid , N . G & Nash , T . Jr . (1966) An external cranial fixation apparatus for sever maxillofacial injuries Plastic and reconstructive surgery , 38 , 142 .

A method of Craniofacial suspension of the fractured middle third of facial skeleton through a cranial arch bar

- 7-Gerlook , A.J. , Jr , Sinn , D. P. and Mc Bride ,K.L. : clinical and radiographic interpretation of facial fractures Boston ,1981 , little , Brown & Co.
- 8-Gossman , J.R ,Jr . , and Pogrel , M .A : The frontal screw : a fixed point for internal suspension , J . oral surg. 39 : 305 (1981)
- 9- Gustav O . Kruger (1984) Oral and Maxillofacial Surgery sixth edn. The C.V. Mosby company .
- 10- Kuepper , R.C. , and Harrigan , W.F. : treatment of mid-facial fractures at Bellevue Hospital center 1955 – 1976 J.oral surg. 35:420, 1977
- 11-Kufner , J. (1970) A method of craniofacial suspension a , Journal of Oral surgery,28 , 260.
- 12-Lesney , T.A. (1953)method of immobilizing a common type of maxillary fracture . Journal of Oral Surg. ,11 ,49
- 13-Levant ,B.A . , Gardner-Berry , D. & snow R.S . (1969) An improved cranio maxillary fixation . British Journal of plastic Surgery ,22 , 288 .
- 14- Levant ,B.A., Cook ,R.M. & Mac Farlane , W.I.(1973) . Experience with levant frame for cranio –Maxillary fixation . British Journal of oral surg. , 11 ,30 .
- 15- MacIntosh , R . B. , and OBwegeser , H.L , : Internal wiring fixation Oral surg. 23 : 703 , 1967
- 16- MeKtubjian , S.R. : Technique of internal suspension for transverse fractures of the middle third of the face , J. oral surg. 39 : 301 (1981)
- 17- Rowe , N.L & Killy, H.C.(1968) fractures of the facial skeleton 2nd edn. Edinburgh : E.& S. Livingstone .
- 18- Rowe , N.L. & Williams ,J.L I . (1985) Maxillofacial injuries Istedn ,. Churchill Livingstone .
- 19 –Stoll ,P.,Schilli , W. & Joos , U . (1983) The stabilization of mid –face fractures in the vertical dimension . Journal of maxillofacial surgery , 11 , 248 >

طريقة التعليق الوجهي القحفي لتثبيت كسور الثلث الوسطي لهيكل عظام الوجه بواسطة الطوق القحفي

*د. غالب عبد حميدي زميل كلية الجراحين الملكية البريطانية

أخلاصه :

كسور الثلث الوسطي لهيكل عظام الوجه التي يكون فيها أيضا كسر عظم الجبهة أو العظم الوجني أو كليهما تحدث أحيانا . وفي هذه الحالات تكون عملية تثبيت كسور الأنواع الثلاثة واحد و اثنان وثلاثة لعظام الثلث الوسطي للوجه غير ممكنه عن طريق التعليق الداخلي والذي يعتمد على عظم الجبهة والعظم الوجني . وبالطريقة التي استخدمتها والتي سيتم إيضاحها تمكنت من تثبيت عدد كبير من هذا النوع من الكسور وبنجاح . وقد سميت بطريقة استعمال الطوق القحفي حيث من خلاله تعلق كسور عظام الثلث الوسطي لهيكل عظام الوجه بدون الحاجة إلى عظم الجبهة أو العظم الوجني . وفي هذه الطريقة يتم زرع طوق من (الأرج بار) والمستعمل في تثبيت كسور الفكين في داخل جبيرة مثبتة على فروه الرأس . ومن خلاله تعلق كسور الثلث الوسطي لهيكل عظام الوجه . حيث يمكن عمل هذه الجبيرة داخل الردهة أو في العيادة وهذا مما يقلل من الوقت داخل صالة العمليات . بما في ذلك من منفعه كبيره الى المريض والمستشفى معا

*قسم الجراحه / كلية الطب / جامعة ذي قار / ذي قار