

A Comparative Study between Dynamic Hip Screw and External Fixation for Evans stable and unstable type I Intertrochanteric Femoral Fractures

Issam Al-Azzawi (FICMS)* & Wamieth AJ Augla*

Abstract:

Introduction: Intertrochanteric fractures are common among elderly people and considered to have a serious impact on patient and community. Various classification systems and treatment methods are described which also vary in their results.

Aim: To compare between external skeletal fixation and dynamic hip screw fixation in the treatment of intertrochanteric fractures of Evans stable and unstable type 1, in regard to age, gender, treatment choice, perioperative and postoperative outcome, and complications.

Patients and methods: Seventy-four patients who met the criteria were selected for this study in which 54 patients were treated by external skeletal fixation while the other 24 were treated with dynamic hip screw fixation. Perioperative measures, post-operative follow-up and final outcome were recorded for each patient.

Results: Patient who were treated with external fixation were subjected to less anesthesia time, less operative time, less perioperative blood loss, less exposure to radiation, faster healing rates, and minimal complications.

Conclusion: Treatment with external fixator is an effective choice of treatment for Evans stable and unstable type 1 intertrochanteric fractures in elderly high risk patient.

Keywords: Intertrochanteric fractures, External skeletal fixation, dynamic hip screw

Introduction:

Intertrochanteric Fracture (ITF) is a fracture that occurs between the greater and lesser trochanters of femur along the intertrochanteric line^(1,2), that usually affects elderly with osteoporosis commonly a female around the 8th decade of life after suffering a trivial trauma or fall from standing which is the most common mechanism of injury^(1,2,3,4,5), the intertrochanteric area extends from the extracapsular part of the neck to the distal end of the lesser trochanter (Figure 1).

Risk factors: The patients are geriatric population with osteoporosis^(1,2,3,4,5,6), in which the bone is fully mineralized but its structure is abnormally porous resulting in decreased bone strength when compared to persons' age and gender standards. In the geriatric population, a careful evaluation for medical co-morbidities should be undertaken.

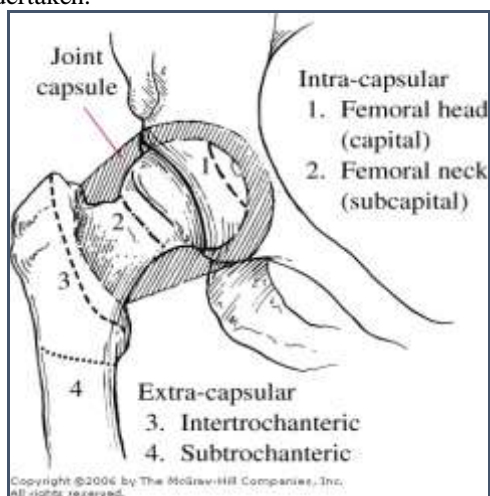


Figure 1: Anatomic regions of proximal femur.

The number of co-morbidities is directly related to 1-year mortality figures: Patients with four

or more co-morbidities have been reported to have a higher 1-year mortality rate than patients with three or fewer⁽¹⁾. The incidence of ITFs is gender and race dependent and varies from country to country⁽⁶⁾ due to variance in life span, social and cultural factors. Hip fractures (intertrochanteric and femoral neck fractures) account for 30% of all hospitalized patients in the United States, and the estimated cost for treatment is approximately \$10 billion a year⁽³⁾.

Classification: Multiple classification systems were described for ITFs, in each classification the author tries to describe the fracture in terms fracture shape and stability which in turn influences the choice of management and prognosis. Some of widely used classifications include:

1. **Evans classification:** which is the classification used in our study. In 1949, Evans⁽⁸⁾ made an important contribution to our understanding of intertrochanteric hip fractures with publication of his classification system based on the stability of the fracture pattern and the potential to convert an unstable fracture pattern to a stable reduction. All other intertrochanteric fracture classification schemes, including the AO/OTA classification, are variations on the Evans classification^(1,3,6). Evans devised a widely used classification system based on the division of fractures into stable and unstable groups.
2. **The AO group** classified trochanteric fractures. A1 fractures are uncomminuted, A2 fractures have increasing comminution, and A3 fractures have subtrochanteric extensions or reverse obliquity^(3,6).
3. **Boyd and Griffin** classified fractures in the peritrochanteric area of the femur into four types⁽³⁾.

Clinical features: The classical clinical presentation of ITFs is old and unfit patient with average age of 70 years, female affected more than

male, the patient has sustained a minor trauma or fall from standing height presented with hip pain, unable to stand on or move the affected limb which is usually shorter and externally rotated (more than with femoral neck fracture because its extra-articular)⁽²⁾. No specific investigation is required for the diagnosis of the fracture but for the patients' general condition assessment and to prepare for operative treatment when the choice of surgery is made. The investigations required usually include a full hematologic and biochemical laboratory tests as well as ECG, echocardiograph, and pulmonary function test.

Treatment: Non-operative treatment of ITFs has largely been abandoned. In the 1960s, Horowitz reported a mortality rate of 34.6% for trochanteric fractures treated by traction and 17.5% for fractures treated by internal fixation⁽³⁾. Rigid internal fixation of intertrochanteric fractures with early mobilization of the patient should be considered standard treatment. Operative treatment goal is strong, stable fixation of the fracture fragments, to obtain the best possible position and to get the patient up and walking as soon as possible and thereby reduce the complications associated with prolonged recumbency^(1,2). The two main devices used for internal fixation of Evans stable and unstable type 1 ITFs are the Dynamic hip screw/side plate (DHS) and the intramedullary hip screw^(1,2), with disadvantages of increased blood loss, increased failure in reverse obliquity or subtrochanteric extension patterns, excessive collapse resulting in limb shortening, fracture deformity in unstable fracture patterns periprosthetic fracture, increased incidence of screw cutout and cost. While for Evans unstable type 2 ITFs with reverse oblique pattern are best thought of as subtrochanteric femur fractures and therefore should be treated with either an intramedullary nail or a fixed-angle device such as a blade plate or dynamic condylar screw^(1,2). External skeletal fixation (EF) is not commonly considered for the treatment of intertrochanteric femur fractures. Early experiences with EF for ITFs were associated with minor postoperative complications, such as pin loosening, infection, and varus collapse. However, the ability to treat ITFs with short operative times, minimal blood loss, and potentially with only local anesthesia have led some to advocate its use in selected patients. The patients most suitable for such treatment include those at unacceptably high risk for complications related to general or regional anesthesia. The device typically consists of one or two half pins placed into the femoral neck to within 10 mm of the subchondral bone. The fracture is reduced under fluoroscopic guidance and the pins are connected through clamps and a bar to two or three half pins placed in the proximal femur⁽⁶⁾. Satisfactory healing rates (95% to 100%) have recently been reported in several European studies of EF for the treatment of ITFs⁽⁶⁾.

Postoperative management should focus on early mobilization of the patient and minimization of complications such as DVT, disorientation, bowel or bladder irregularities, and pressure sores. Depending on the patient's condition and the stability of the fixation, weight bearing to tolerance is begun using a walker. Early hospital discharge with adequate outpatient medical treatment has been demonstrated to decrease overall cost and improve recovery^(1,2,3).

The aim of the study is to compare between external skeletal fixation and dynamic hip screw fixation in the treatment of intertrochanteric fractures of Evans stable and unstable type 1, in regard to age, gender, treatment choice, perioperative and postoperative outcome, and complications.

Patients and methods:

A prospective study carried out in orthopedic department at Al Yarmouk Teaching Hospital from December 2011 to June 2013 on 74 patients with ITFs. Patients selected are geriatric population with a single Evans stable or unstable type 1 ITF, with exclusion of multiple trauma cases, open fractures and pathological fractures. The study design includes age, gender, occupation, mechanism of injury, type of fracture, operative choice, operative time, perioperative blood loss, perioperative radiation exposure by fluoroscope, and postoperative outcome. Evans classification was used to determine the type of ITF in which stable and unstable type 1 were the only included types in this study.

The preoperative planning starts as the patient is received at the emergency room (ER), to begin with primary evaluation of the general condition, basic investigation (Hematology and Biochemistry), evaluating any associated injuries. Primary fixation methods took place in the ER with skin traction.

The anesthesia type and time was determined according operative choice. Closed reduction under fluoroscopic guidance was performed for all cases. Fifty patients were treated with EF, the fixation was unipolar uniplaner type and consisted of 2 half pins inserted to femoral neck parallel to its direction and 2-3 half pins to shaft perpendicular to its direction with 1st generation clamps and single or double rod in between, all under fluoroscopic guidance. The remaining 24 pt. were treated by DHS which was applied by standard method. Operative time is recorded for each case (in minutes), as well as perioperative blood loss by the use of the standard 18×18 inch X-ray detectable lap sponges, in which a soaked lap sponge holds about 100ml of fluid, also radiation exposure was calculated by the fluoroscope in seconds of exposure. Movement starts on the day following surgery, active exercises of the upper and lower extremities are begun and weight bearing to tolerance is begun using a walker and any limitation of hip and knee was recorded. Patients are followed up till healing, in which any complications

encountered were recorded with fracture healing time (union). Follow up continued after removal of fixation for patients treated by EF and until healing for patients with DHS in which the apparatus was retained unless complications occurred.

Statistical analysis was done by specialist in community medicine using SPSS program version 17.

Results:

Mean age of studied patients was (73±5.7 years). The highest age group affected was the 8th decade with 48 patients (64.87%). Female patients were more commonly affected (74.32%), table 1. From the two types of fractures selected; Evans unstable type 1 ITFs presented in 57 pt. (77%) while Evans stable type ITFs was presented in the remaining 17 pt. (23%), figure 2.

Fifty patients (64.1%) were treated with EF with mean operative time of 25.32±4.75 minutes, blood loss of < 100ml and mean radiation exposure of 14.82±2.45 seconds by fluoroscope (Table 6). While the remaining 24 pt. (30.8%) treated with DHS with mean operative time of 89.17±16.78 minutes, blood loss of ≥500ml and mean radiation exposure of 57.9±8 seconds by fluoroscope. A

significant association was observed between CR+EF technique with shorter operative time, shorter fluoroscope exposure duration and shorter healing time than DHS technique (p<0.001), table 2 and figure 3, 4.

Postoperative limitation in hip joint movement was found in 30 pt. (60%) in EF group and 14 pt. (58.33%) in DHS group that was mostly resolved after 2 weeks, while limitation of knee joint movement was found 25 pt. (52%) of EF group and 8 pt. (33.33%) in DHS group that also resolved after 2 weeks, figure 5.

Healing and union (Table 8) of the fracture occurred in all pt. (100%), in which mean time required for clinical and radiological union was 12.6±1.6 weeks for patients treated with EF and 14.4±1.66 weeks for patients treated by DHS.

From the patients treated by EF seven patients (9.47%) developed superficial pin tract infection, three patients (4.05%) developed pin loosening and two cases with varus of about 10-20 degree. From the patients treated with DHS one patient (1.35%) suffered DHS cutout with varus. no construct failure, insignificant hip and knee stiffness was noted in both groups, figure 6.

Table 1: The demographic characteristics of study participants.

Variable	No.	%
Age mean±SD (73±5.7 years)		
60-69 years	23	31.0
70-79 years	48	65.0
80-89 years	3	4.0
Total	74	100.0
Gender		
Male	19	26.0
Female	55	74.0
Total	74	100.0

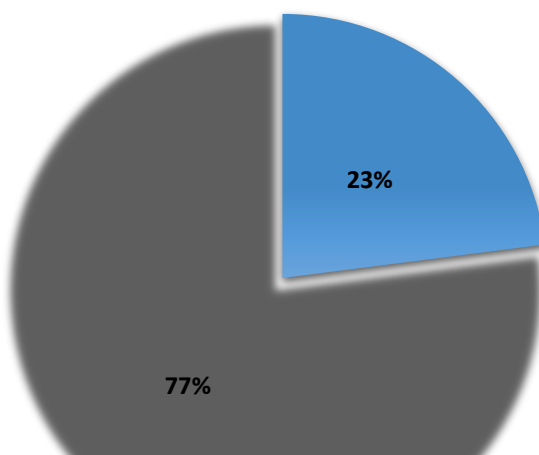


Figure 2: The distribution of patients according to fracture type.

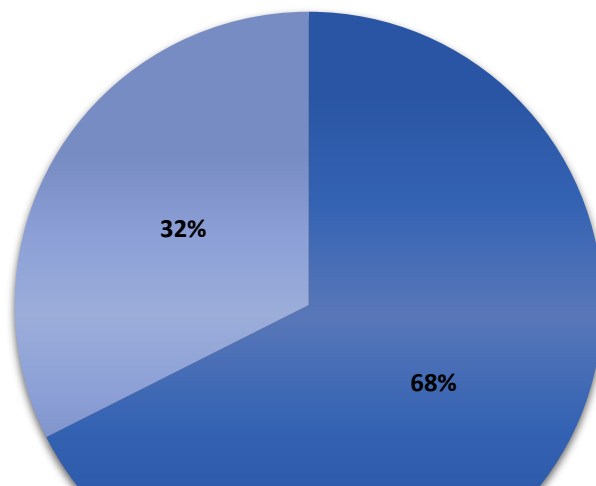


Figure 3: The distribution of patients according to surgery type.

Table 2: The distribution of operative time according to surgery type.

Variable	CR+EF	DHS	t-test	P
	Mean±SD	Mean±SD		
Operative time (minutes)	25.3±4.7	89.1±6.7	25.1	<0.001
Fluoroscope exposure (seconds)	14.8±2.4	57.9±8	35.1	<0.001
Healing time (weeks)	12.6±1.6	14.4±1.6	4.5	<0.001

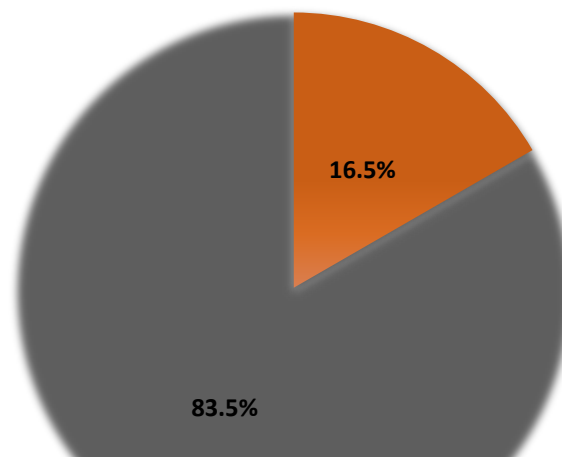


Figure 4: The distribution of soaked lap sponges according to surgery type.

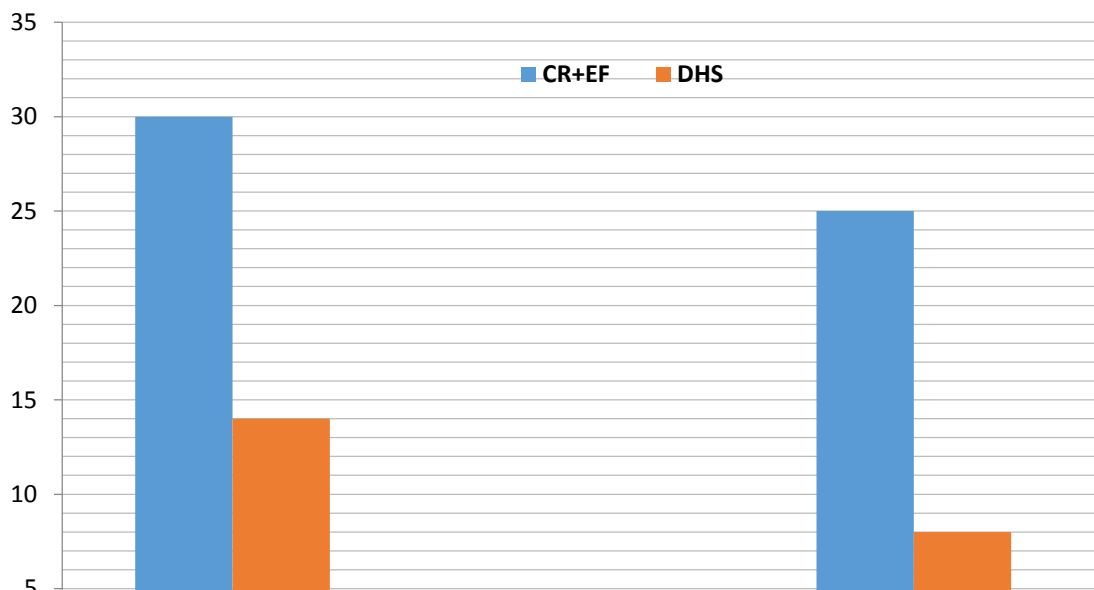


Figure 5: The distribution of joints limitations according to surgery types.

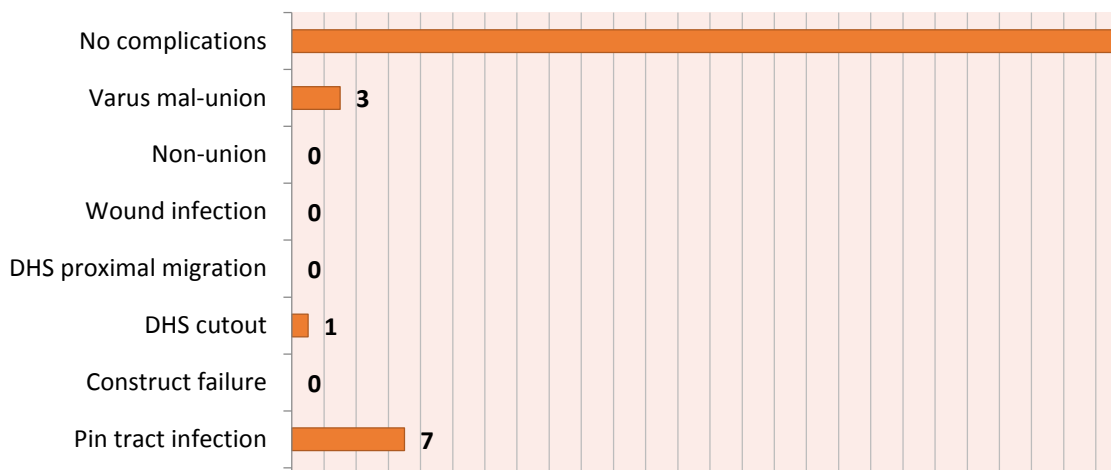


Figure 6: The distribution of complications.

Discussion:

In our study 74 patients were selected in whom ITFs commonly affected age group was the 8th decade which coincides with studies by Lieberman, Solomon, Terry Canale, and others (1, 2, 3, 4, 5, 8, 11, 12). Contrasting the age predilection was found by Eksioglu et al., Subasi et al., and Devgan and Swangwan (13, 14, 15) in which the 7th decade was the most age group affected. Female were affected more than male as indicated by all studies except what was found in one study by M. J. Al Sa'ad (11) and was attributed to social and habitual factors at the region where the study was conducted. This age and gender variance is mostly attributed to poor general condition of the geriatric population with chronic diseases and the female predilection by postmenopausal osteoporosis.

Fifty patients were treated with EF and their mean operative time was 25.32 min which was comparable with studies by Atici T., Ali A.M. (16-20),

shorter mean operative time was found by Karn et al., Petsatodis et al. (21, 22), while longer mean operative time was found by Kazakos K., and Moroni A. (13, 23, 24), but all authors agreed with our study regarding the advantage of short operative time required for patients treated by EF owing to its simple and safe application, closed technique, and familiarity with the device, like Becholz RW, Gani Nu, Moroni A, Karn NK, Vossinakis & Badras, He SH, and others (6,8-10,12,13,15,17-24,26).

Twenty-four patients were treated with DHS and their main operative time was 89.17 min which was comparable with findings of Karn et al. (19), but shorter mean operative time was found by Moroni et al. and Adams et al. (24, 25), and significantly shorter mean operative time by Vossinakis and Badras (18) but still significantly longer operative time than for patients who underwent EF (18,19, 24, 26).

Vossinakis & Badras (18) reported no operative blood in cases treated by EF and a mean of

568±147ml of blood loss in cases treated by DHS. Karn⁽¹⁹⁾ reported comparable results. Moroni⁽²⁴⁾ reported the need for blood transfusion, in which EF group needed none while DHS group needed a mean of 2 units of blood transfusion. In our study blood loss was measured by lap sponge method, results were similar to other studies in that blood loss was negligible for EF group owing to closed technique and percutaneous pin insertion, on the other hand a rough mean of 500±100 ml of blood loss in DHS group which was attributed to open technique, evacuation of hematoma and drilling. Only Adams et al.⁽²⁵⁾ found mean blood loss by DHS of 260ml which was still significantly higher than EF group.

Ali et al.⁽¹⁷⁾ reported a mean radiation exposure by fluoroscope by 15 seconds. In our study we calculated the seconds of radiation taken by fluoroscope, in which mean radiation exposure was 14.82±2.45 seconds for each EF session and a mean of 57.9±8 seconds for each DHS session, this clearly would be attributed to the simplicity of EF and the lesser steps needed for application when compared to DHS that is more complex and needs more steps for application.

In studies by Ali et al., Karn et al., Vossinakis & Badras^(17, 21, 27) the EF was well tolerated and no hip or knee stiffness was reported, in another study by Vossinakis & Badras⁽¹⁸⁾ hip or knee stiffness was not reported by either groups, while Karn et al.⁽¹⁹⁾ reported hip joint stiffness in the EF group that resolved after 18 weeks and more significant knee joint stiffness that resolved after 24 weeks. Devgan & Sangwan⁽¹⁵⁾ reported pin-track infection (PTI) and knee stiffness as a major complication of external fixation. In our study we found mild hip joint limitation of movement in 30 patients (60%) from EF group and 14 patients (58.33%) in DHS group that was mostly resolved in both groups at the 2nd week visit after surgery which could be attributed to fracture pain, soft tissue fixation by EF, and soft tissue injury by DHS. Knee joint limitation was higher in EF group with 25 patients (52%) while found in 8 patients (33.33%) probably as a result of the fixation of the soft tissue by the EF that was also resolved after few weeks which could be attributed to proximal placement of shaft pins.

Complications in general were not reported the study by Ali et al. for patients treated by EF, while less complication rate was reported for EF when compared to DHS in studies by Vossinakis & Badras, Karn, Moroni, and He^(18, 19, 24, 26).

Devgan & Sangwan⁽¹⁵⁾ as mentioned, reported PTI and knee stiffness as a major complication of external fixation. Karn et al.⁽²¹⁾ reported superficial PTI to occur in 60% of his study group. Atici et al.⁽¹⁶⁾ also reported PTI occurrence in 47.8%. Vossinakis & Badras⁽¹⁸⁾ reported PTI of 30%, while Moroni et al. and Ali et al. reported 0% occurrence of PTI in their studies. In our study we noticed superficial PTI to affect seven patients (9.47%), which was comparable with studies by

Subasi et al., Vossinakis & Badras, and Eksioğlu et al.^(13, 27, 29) with 7%, 15.9% and 12.5% consequently. This percentage could be attributed to low speed drilling and constant pin tract care, and these cases were treated with saline wash, topical antibiotic cream and systemic antibiotics administration. No case of grade II or higher PTI was noticed and no case of wound infection in the DHS cases was recorded.

Vossinakis & Badras⁽¹⁸⁾ reported There was no difference in the time required for the healing of the fracture between the two groups. All were judged to be healed at a mean of 11.4±1.2 weeks. Karn et al.⁽¹⁹⁾ reported that all fractures united clinically and radiologically at 12 weeks. He et al.⁽²⁶⁾ reported no statistically significant deference in fracture union time among the study groups. In our study we found that the mean healing time for EF group was shorter (12.6±1.6wks) than that needed for DHS (14.4±1.66wks) which could be attributed to closed method (i.e. less surgical trauma, no surrounding tissue and blood supply interruption, no periosteal stripping), and uninterrupted of the fracture hematoma in the EF group; an important factor pinpointed by Subasi et al., Devgan and Sangwan, and Dhal et al.^(13, 15, 28), as well as, the natural behavior of the EF apparatus which allows macromotion at the fracture site (less rigid than DHS) which also considered an important factor contributing to callus formation; hence healing of the fracture. No case of non-union was recorded in our study that compares with most other studies.

Varus collapse reported by Karn et al.⁽¹⁹⁾ to occur in 15% of EF group and 0% for DHS group, also Vossinakis & Badras⁽¹⁸⁾ reported mean varus of 12.9° to occur in 12 fractures treated by EF and 8 fractures treated by DHS with mean varus of 11.9°, on the other hand Moroni et al.⁽²⁴⁾ reported that at six months varus collapse of the fracture averaged 6° ± 8° in DHS group and 2° ± 1° in EF group. In our study varus malunion was found in one case treated with DHS due to the DHS cutting out superiorly that was noticed at 8th postoperative week which is attributed to very poor bone quality of that specific case which was treated by supplement of calcium + vitamin D₃, limitation of movement that involves weight bearing and use of crutch for another 8 wks, at the final visit there was no progression of varus or the DHS cutting out. Two more cases of varus collapse was noticed in the EF group which was due to pin loosening affecting the most proximal pins which is also attributed to poor bone quality of specific cases that also caused the third case of pin loosening but with no varus collapse.

Vossinakis & Badras⁽¹⁸⁾ reported that in a number of cases one of the proximal pins of EF or the screw of DHS advanced further into the proximal fragment due to collapse, without cutting out. In the EF group this usually involved the more proximal of the two pins and was seen in 15 fractures, while in the DHS group this occurred in

28. The difference between the two groups was statistically significant. Cut-out of the implant was noticed in a much smaller number of patients in each group (three for the EF and five for the DHS). All cases of cut-out in the EF group were treated by retracting the offending pin without anesthesia. In the DHS group, however, all five patients required a second operation. In our study no case of proximal migration was recorded in either group, only one case of cutting-out of DHS that was mentioned in the paragraph above. No case of implant failure was recorded in our study.

Conclusion:

We concluded that the External Fixator is a favorable treatment option for intertrochanteric fractures in unfit high risk geriatric patients in our developing country.

Acknowledgment:

We would like to express my gratitude to all the orthopedic faculty and fellow postgraduates in Al Yarmouk Teaching Hospital for their immense help in the completion of this study, especially DR. Abdul Jabbar Rasheed, Orthopedic Consultant, for his help and guidance.

References:

- 1-Lieberman JR. AAOS Comprehensive Orthopedic Review; 2nd Ed. (2009), Ch. 55, Fractures of the Hip - Steven J. Morgan, MD.
- 2-Solomon L, Warwick D, Nayagam S: Apley's System of Orthopedics and Fractures; 9th Ed. (2010), p. 853.
- 3-Canale ST, Beaty JH: Campbell's Operative Orthopedics; 11th Ed. (2008), Chap. 52, Intertrochanteric Fractures.
- 4-Miller MD, Thompson SR, Hart JA: Review of Orthopedics; 6th Ed. (2012), Chap. 11, Sec. 3, p. 747.
- 5-Moore D. Intertrochanteric Fractures; orthobullets.com, update Sep. 2012, online.
- 6-Bucholz RW, Heckman JD, Court-Brown CM. Rockwood and Green's Fractures in Adults; 6th Ed. (2006), Chap. 45, pp. 1794-823.
- 7-Snell RS. Clinical Anatomy for Medical Students, 6th Ed. (2000), p. 526.
- 8-Evans E. The treatment of trochanteric fractures of the femur. Journal of Bone and Joint Surgery (JBJS), 1949;31B:190-203
- 9-Anderson R, McKibbin WB, Burgess E: Intertrochanteric Fractures; JBJS, 1943, 25, pp. 153-68.
- 10-Scott HI: Treatment of intertrochanteric fractures by skeletal pinning and external fixation. Clin. Orthop., 1957, 10, pp. 326-34.
- 11-Al-Sa'ad MA: Intertrochanteric Fractures in Yemeni Patients; Arab Board of Medical Specialties, Jan. 2008-San'aa-Yemen.

- 12-Gani Nu, Kangoo KA, Bashir A, et al.: External fixation of intertrochanteric fractures; Orthop Rev (Pavia). 2009 October 10; 1(2): e18.
- 13-Subasi M, Kesemenli C, Kapukaya A, Necmioglu S: Treatment of Intertrochanteric Fractures by External Fixation; Acta Orthopeda (Belg). 2001 Dec, Vol.67(5),pp.468-74.
- 14-Eksioglu F, Sepici B, Cavusoglu T, Gudemez E. Treatment of intertrochanteric fractures with external fixation. Joint Disease and Related Surgery 1998; 9(1):40-42.
- 15-Devgan A, Sangwan SS. External fixator in the management of trochanteric fractures in high-risk geriatric patients: a friend to the elderly. Indian Journal of Medical Science 2002;56: 385-90.
- 16-Atıcı T, Sahin N, Oztürk A, Yaray O: Treatment of intertrochanteric femur fractures in high-risk geriatric patients (≥ 65 years) with external fixation; Turkish Journal of trauma and Emergency Surgery, 2010 sep., Vol. 16(5), pp. 413-20.
- 17-Ali AM, Abdelkhalek M, El-Ganiney A: External fixation of intertrochanteric fractures in elderly high-risk patients; Acta Orthopeda (Belg). 2009 Dec; 75(6):748-53.
- 18-Vossinakis IC, Badras LS: Management of pertrochanteric fractures in high-risk patients with an external fixation; International Orthopedics 2001; 25(4):219-22.
- 19-Karn NK, Singh GK, Kumar P, Shrestha BP, et al. Comparison between external fixation and sliding hip screw in the management of trochanteric fractures of the femur in Nepal. JBJS. 2006; Vol.88-B: pp.1347-50.
- 20-Boghdady GW, Shalaby M: Safety and reliability of external fixation for basicervical and intertrochanteric fractures in high-risk elderly patients; Strategies in Trauma and Limb Reconstruction. 2007 Dec; Vol.2 (2-3):83-89.
- 21-Karn NK, Singh GK, Kumar P, et al.: Management of trochanteric fractures of the femur with external fixation in high-risk patients; International Orthopedics, 2009 Jun; 33(3):785-88.
- 22-Petsatodis G., Maliogas G., Karikis J., et al.: External fixation for stable and unstable intertrochanteric fractures in patients older than 75 years of age: a prospective comparative study; Journal of Orthopedic Trauma. 2011 Apr; 25(4):218-23.
- 23-Kazakos K, Lyras DN, Verettas D, et al. External fixation of intertrochanteric fractures in elderly high-risk patients. Acta Orthop. Belg. 2007 Feb;73(1):44-48.
- 24-Moroni A, Fadini C, Pegreff F, et al.: Dynamic hip screw compared with external fixation treatment of osteoporotic pertrochanteric fractures: a prospective, randomized study. J Bone Joint Surg (Am), 2005;87-A:753-59.

- 25-Adams CI, Robinson CM, Court-Brown CM, McQueen MM. Prospective randomized controlled trial of an intramedullary nail versus dynamic screw and plate for intertrochanteric fractures of the femur. *J Orthop. Trauma* 2001; 15: 394-400.
- 26-He SH, Peng JY, Zhao X. The comparison of three operation methods for treatment of femoral intertrochanteric fracture. *China Journal of Orthopedics and Traumatology*. 2009 Jan;22(1):6-9.
- 27-Vossinakis IC, Badras LS. Management of pertrochanteric fractures in high-risk patients with an external fixation. *International Orthopedics*. 2001; 25: 219-22.
- 28-Dhal A, Varghese M, Bhasin VB. External fixation of intertrochanteric fractures of the femur. *J. Bone Joint Surg.*, 1991, 73-B, 955-958.
- 29-Eksioglu F, Gudemez E, Cavusoglu T, Sepici B. Treatment of intertrochanteric fractures by external fixation. *Bull. Hosp. Joint. Dis.*, 2000, 59, 131-35.
-
- *Orthopedic surgeon, e-mail: isam57alazzawi@yahoo.com