

Atrial Flutter, The Commonly Misdiagnosed Arrhythmia as Supraventricular Tachycardia or Sinus Tachycardia

Amar T. Alhamdi MRCP(UK), FRCP(Ed.)

Alhamdi Heart Clinic, Sulaymaniyah, KRG, Iraq

Abstract

Background	Atrial flutter is a common arrhythmia in structurally normal or abnormal heart. The electrocardiographic features of it can be mistaken for sinus tachycardia or supraventricular tachycardia. By careful electrocardiogram (ECG) inspection or by electrophysiological study differentiating atrial flutter can be reliably done.
Objective	To differentiate atrial flutter from supraventricular tachycardia and sinus tachycardia.
Methods	Twenty-one patients, ten females and eleven males, collected over 6 years at the author's practice in Sulaymaniyah, diagnosed as sinus tachycardia or supraventricular tachycardia and then found to be in atrial flutter were included in this study. The atrial flutter differentiated by careful inspection of the 12 leads ECG or with electrophysiological study.
Results	Ten patients were misdiagnosed as sinus tachycardia and eleven patients as supraventricular tachycardia. Eleven diagnosed by careful ECG inspection and ten by electrophysiological study where ablation therapy was done in 8 patients. In 13 patients, drug therapy was applied where 4 reverted to sinus rhythm and in 6 patients reverted by synchronized DC shock. Two failed to revert to sinus rhythm.
Conclusion	Differentiating atrial flutter from sinus tachycardia and supraventricular tachycardia is essential for management strategy decision.
Keywords	Atrial flutter, misdiagnosis, sinus tachycardia, supraventricular tachycardia
Citation	Alhamdi AT. Atrial flutter, the commonly misdiagnosed arrhythmia as supraventricular tachycardia or sinus tachycardia. <i>Iraqi JMS</i> . 2021; 19(1): 82-89. doi: 10.22578/IJMS.19.1.11

List of abbreviations: AFI = Atrial flutter, AT = Atrial tachycardia, AVC = Atrio-ventricular conduction, CCW = Counter clockwise, CTI = Cavo-tricuspid isthmus, ECG = Electrocardiogram, EPS = Electrophysiological study, ST = Sinus tachycardia, SVT = Supraventricular tachycardia

Introduction

Atrial flutter (AFI) is clinically commonly encountered arrhythmia in normal heart, structural heart diseases and after cardiac surgery ⁽¹⁾. It is commonly misdiagnosed arrhythmias because of non-identification of the characteristic flutter waves in the 12 leads electrocardiogram (ECG) classically described as saw teeth appearance ⁽²⁾. The flutter waves may be mistaken for a P

wave of sinus rhythm and accordingly sinus tachycardia (ST) is over diagnosed ⁽³⁾. When a single P seen after the QRS, a supraventricular tachycardia (SVT) or atrial tachycardia (AT) is over diagnosed and if two P seen in between the QRS an atrial tachycardia with 2:1 AV conduction (AVC) is diagnosed which led to miss-management ^(2,3,4). The mechanism of AFI is a macro re-entry circuit passing through the right atrial wall, around the tricuspid annulus and the narrow slow part of the circuit is at the cavo-tricuspid isthmus (CTI) ^(3,4). The atrial rate in AFI is about 240-350 bpm, while the ventricular rate varies widely from 50-200

depending on the AV node conduction ^(1,3,4). Surface ECG can diagnose AFI if carefully inspected but it might be not easy to differentiate it from ST or other SVT ^(3,4,5). Quantitative ECG analysis may help to differentiate AFI from other arrhythmias ⁽²⁾. When AFI is conducted in 2:1 pattern, the resulting ventricular rate is around 125-175 per minute (usually around 150); at this rate, it can appear that there is a P wave in front of each QRS and a T wave after each QRS. This causes the misdiagnosis of ST or SVT even with computer-based interpretation ⁽⁶⁻⁸⁾. Differentiating AFI from ST and SVT is essential for management strategy and at certain clinical situations ⁽⁹⁻¹⁴⁾.

The objectives of this study are to differentiate AFI from ST and SVT and avoiding misdiagnosis of AFI by the surface ECG.

Methods

Patients misdiagnosed as ST or SVT and then diagnosed as AFI are included in this study. A total of 21 patients were collected from the author's practice at Sulaymaniyah, KRG, Iraq over 6 years' period from 2013-2019. The diagnosis of AFI is made by careful re inspection of the surface 12 leads ECG or by electrophysiological study (EPS) with back revision of the misdiagnosis through the ECG to evaluate the characteristic features and pattern of the flutter waves indicating AFI. The characteristic ECG features of AFI used in this

study were the typical flutter waves and the undulating iso-electric line in between the flutter waves. The unclear flutter waves were clarified by slowing the ventricular rate by either carotid massage or iv adenosine injection. Electrophysiological study applied when the tachycardia could not be surely identified by the surface 12 leads ECG and when catheter ablation is considered as a therapeutic option.

Results

Over a period of 6 years, a total of 21 patients were collected; ten females and 11 males. Age ranged from 26-75 yr. The main clinical presentation was palpitation in 15 patients and dyspnea with vague chest pain in 4 and in 2 patient's syncope was the presenting symptom. The AFI was misdiagnosed for ST in 10 patients and SVT in 11. In 8 patients, an EPS and CTI ablation done successfully after the diagnosis of counter clockwise (CCW), typical isthmus dependent AFI was confirmed. In the rest 13 patients, drug therapy with either amiodarone or flecanide was used; with reversion and stabilization in to sinus rhythm in 4 patients and reversion by DC shock in 6 and then maintained on antiarrhythmic drug, the other three advised for ablation therapy but they refused (Table 1).

The followings figures (1-5) are examples of the misdiagnosed cases of AFI

Table 1. The demographic features of cases.

Total number	Male	Female	Clin. pres.	ST	SVT	EPS +Abl.	Drugs
21	11	10	15 P 4 CP & SOB 2 S	10	11	8	4 SR 6 DCS 3 no Abl

Clin. pres.: Clinical presentation and type of misdiagnosis and treatment afforded. P: Palpitation, CP: chest pain, SOB: Shortness of breath, S: Syncope, ST: Sinus tachycardia, SVT: Supraventricular tachycardia, EPS: Electrophysiological study, Abl: Ablation, SR: Sinus rhythm, DCS: Direct current shock.

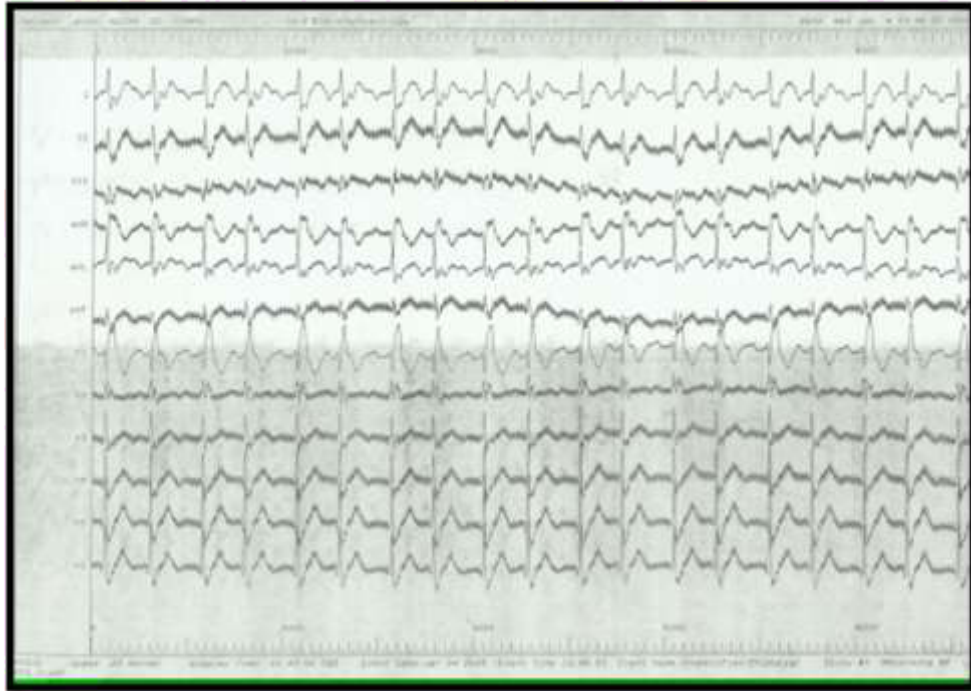


Figure 1A. A 55 yr male diagnosed as SVT for two years and treated with BB and amiodarone with no improvement. EPS confirmed CCW typical AFI. Careful inspection flutter waves and undulating isoelectric line seen in lead III. 2:1 AFI seen. QRS is of RBBB pattern. SVT: Supraventricular tachycardia, BB: Beta blockers, EPS: Electrophysiological study, CCW: Counter clockwise, AFI: Atrial flutter, RBBB: Right bundle branch block

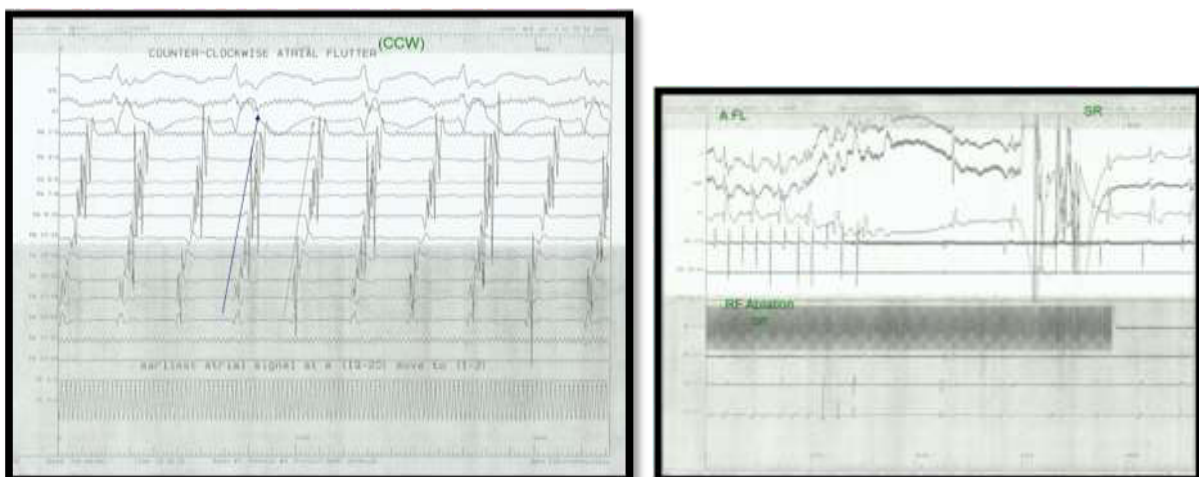

Figure 1B. Same patient in figure 1A, EPS confirmed 2:1 CCW typical AFI and CTI ablation reverted him in to SR. CTI: Cavo-tricuspid isthmus

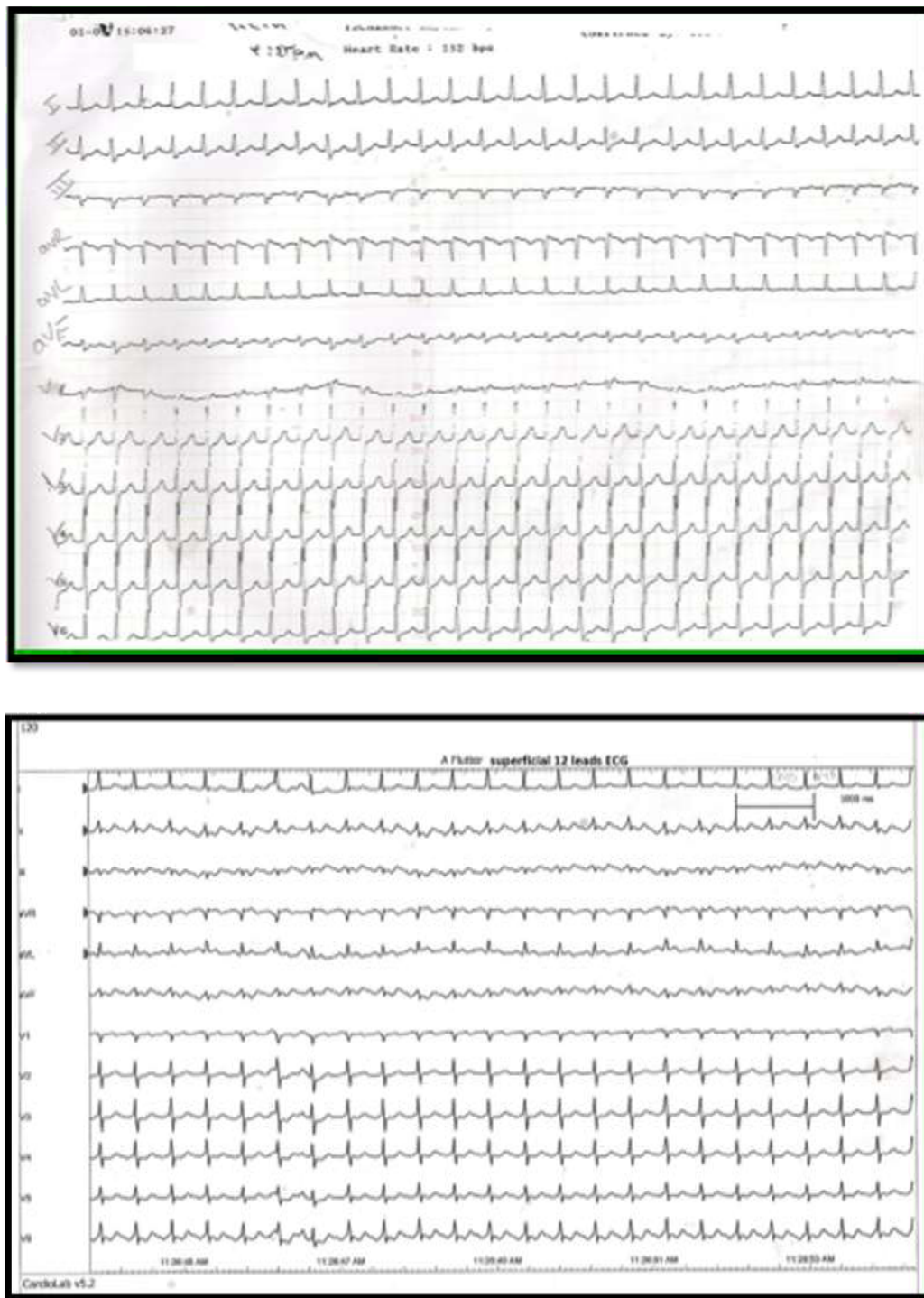


Figure 2. A 36 yr male, structurally normal heart with palpitation, diagnosed as SVT of short RP long PR, s/f AVNRT diagnosed for 4 years (top ECG). The bottom ECG showed undulant isoelectric line and 2:1 atrial flutter seen clearly in lead III and aVF

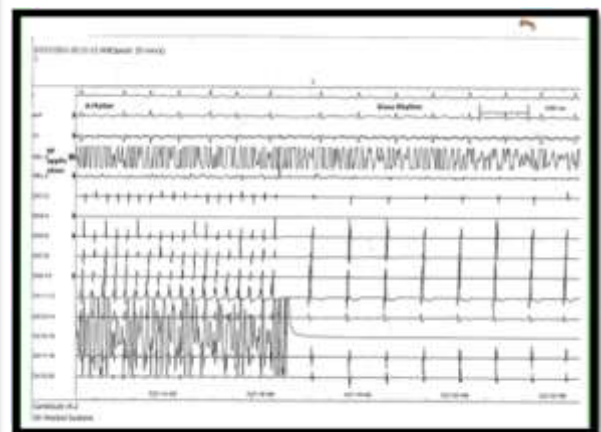
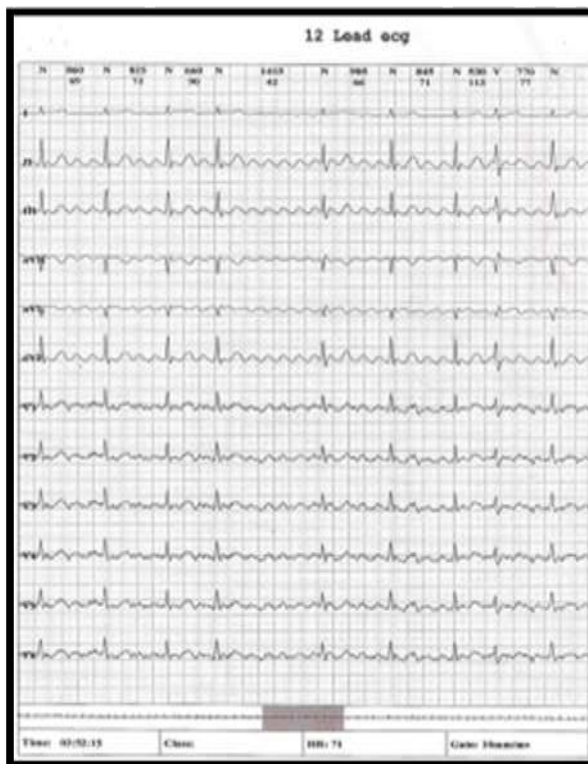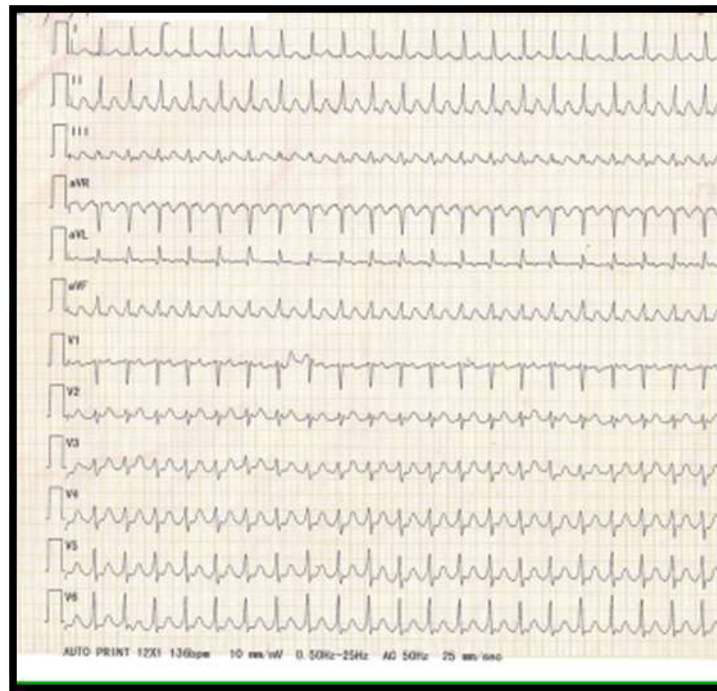


Figure 3. A 56 ye female with structurally normal heart with sustained tachycardia referred as extreme ST or SVT (top). Holter (lower left) clearly showed atrial flutter with variable AVC. EPS and CTI ablation (lower right) reverted her in to sinus rhythm

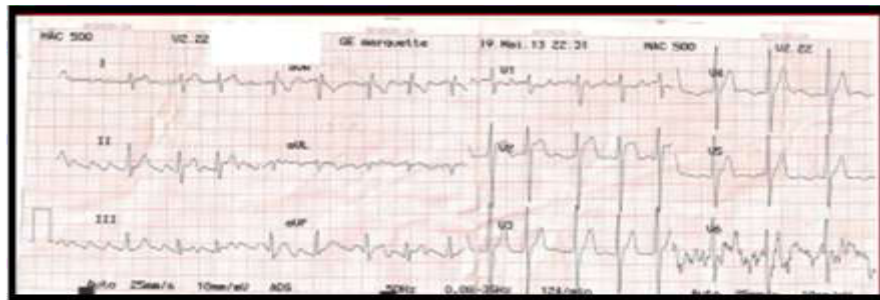
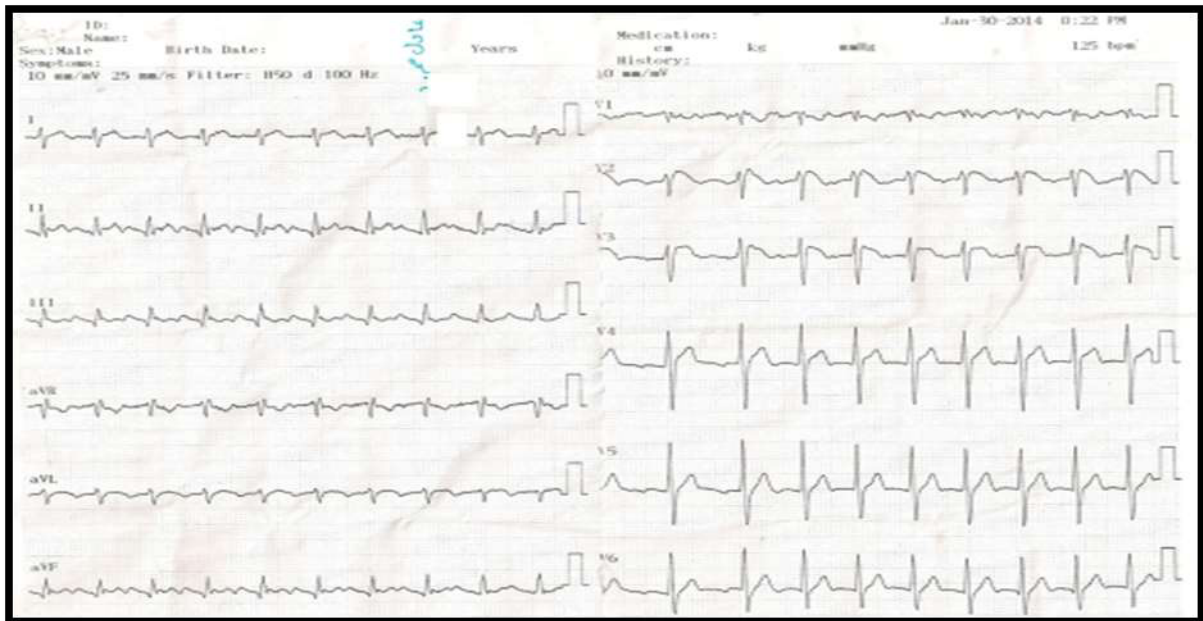


Figure 4. A 34 yr male presented with pre syncope and palpitation. ECG reported as sinus tachycardia where a P wave seen in II, III, aVF and V1 (Top). Bottom ECG showed clearly atrial flutter with 3:1 and 2:1 AVC in leads I, II and III. In V2, V3 a Brugada syndrome features

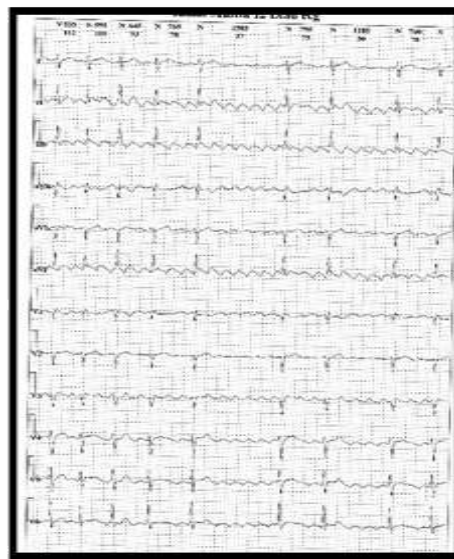
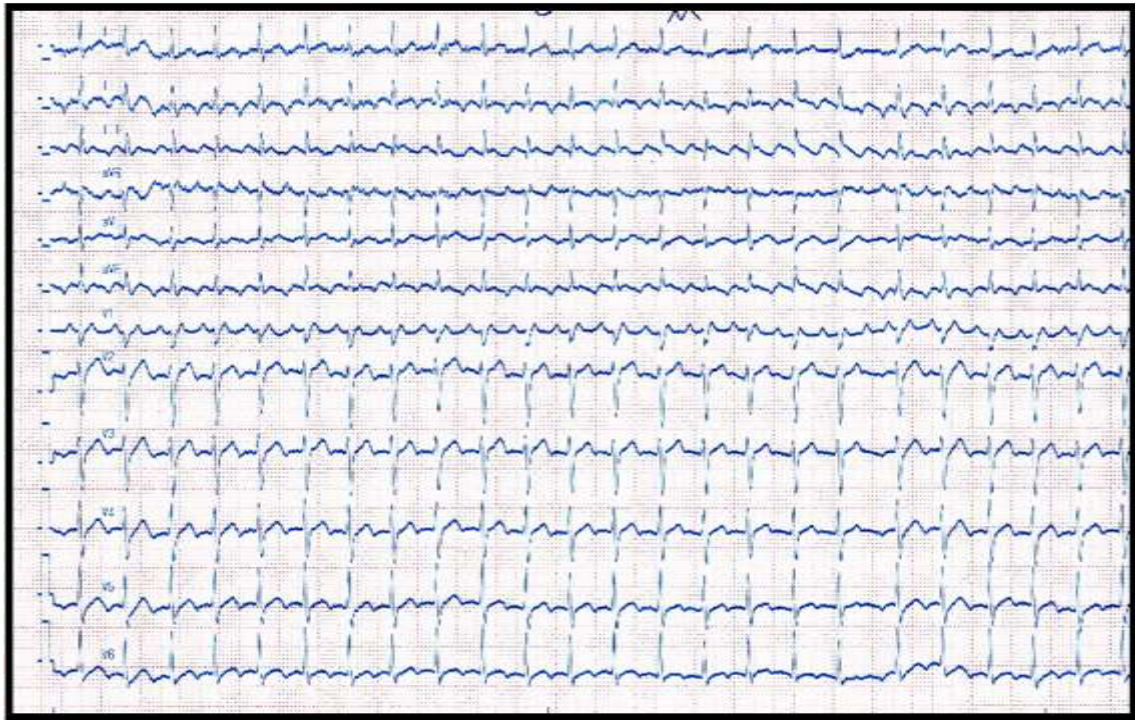


Figure 5. ECG of a 45 yr male diagnosed as extreme sinus tachycardia based on P wave at V1 before the QRS. Holter recording clearly showed atrial flutter with variable AVC

Discussion

The recognition of AFI from ST and other SVT is clinically important for management's decisions. Differentiating AFI from ST and SVT can be done by considering the clinical status, careful inspection of all the 12 leads ECG with long strips or if in doubt by EPS where ablation therapy can be offered at the same session.

A cardiac rhythm of about 150 bpm should raise the possibility of AFI mostly with 2:1 AVC, ST is a common suspect in this situation but it should be remembered that ST usually have an underlying clinical reason, is not sudden in onset and can fluctuate with activities like exercise or changing position, while AFI patients has no obvious reasons for ST and

shows a high rate suddenly, maintain it and may ends suddenly to go in to SR or continue in to persistent AFI.

The 12 leads ECG with long strips of selected leads is much superior than few leads ECG to interpret for differentiation because the flutter waves can be seen only in some leads than others where either the classical saw teeth appearance flutter waves and undulating isoelectric line are seen. Occasionally the 2:1 AVC may go in to 3:1 or more by itself, with carotid message or iv adenosine, which immensely help to diagnose AFI rather than ST or SVT; remembering that SVT and AT may conduct in 2:1 pattern but the isoelectric line is very stable and not undulant as in AFI. In our series of 21 patients, the differentiation of AFI could be done with careful inspection of the 12 leads ECG in 50% and by EPS in the other 50%. In conclusion, AFI can be distinguished by careful ECG inspection of all the 12 leads and long strips of some leads or by EPS to avoid misdiagnosis as ST or SVT where management is different.

Acknowledgement

None.

Conflict of interest

The author declares no conflict of interest.

Funding

Self-funding.

References

- DeSimone CV, Naksuk N, Asirvatham SJ. Supraventricular arrhythmias: Clinical framework and common scenarios for the internist. *Mayo Clin Proc.* 2018; 93(12): 1825-1841. doi: 10.1016/j.mayocp.2018.07.019.
- Cosío FG. Atrial flutter, typical and atypical: A review. *Arrhythm Electrophysiol Rev.* 2017; 6(2): 55-62. doi: 10.15420/aer.2017.5.2.
- Sorokivskyy MS, Chernyaha-Royko UP. Interpretation of uncommon ECG findings in patients with atrial flutter. *Heart Vessels Transplant.* 2017; 1(1): 20-4. doi: 10.24969/hvt.2017.6.
- Buttà C, Tuttolomondo A, Giarrusso L, et al. Electrocardiographic diagnosis of atrial tachycardia: classification, P-wave morphology, and differential diagnosis with other supraventricular tachycardias. *Ann Noninvasive Electrocardiol.* 2015; 20(4): 314-27. doi: 10.1111/anec.12246.
- Krummen DE, Patel M, Nguyen H, et al. Accurate ECG diagnosis of atrial tachyarrhythmias using quantitative analysis: a prospective diagnostic and cost-effectiveness study. *J Cardiovasc Electrophysiol.* 2010; 21(11): 1251-9. doi: 10.1111/j.1540-8167.2010.01809.x.
- Lindow T, Kron J, Thulesius H, et al. Erroneous computer-based interpretations of atrial fibrillation and atrial flutter in a Swedish primary health care setting. *Scand J Prim Health Care.* 2019; 37(4): 426-33. doi: 10.1080/02813432.2019.1684429.
- Stewart AM, Greaves K, Bromilow J. Supraventricular tachyarrhythmias and their management in the perioperative period. *Cont Educ Anesth Crit Care Pain J.* 2015; 15(2): 91-6.
- Link MS. Clinical practice. Evaluation and initial treatment of supraventricular tachycardia. *N Engl J Med.* 2012; 367(15): 1438-48. doi: 10.1056/NEJMcp1111259.
- Shiyovich A, Wolak A, Yacovich L, et al. Accuracy of diagnosing atrial flutter and atrial fibrillation from a surface electrocardiogram by hospital physicians: analysis of data from internal medicine departments. *Am J Med Sci.* 2010; 340(4): 271-5. doi: 10.1097/MAJ.0b013e3181e73fcf.
- García-Cosío F, Pastor Fuentes A, Núñez Angulo A. Arrhythmias (IV). Clinical approach to atrial tachycardia and atrial flutter from an understanding of the mechanisms. *Electrophysiology based on anatomy. Rev Esp Cardiol (Engl Ed).* 2012; 65(4): 363-75. doi: 10.1016/j.recesp.2011.11.020.
- Brugada J, Katritsis DG, Arbelo E, et al. 2019 ESC Guidelines for the management of patients with supraventricular tachycardia. 2019 ESC Guidelines for the management of patients with supraventricular tachycardia. The Task Force for the management of patients with supraventricular tachycardia of the European Society of Cardiology (ESC): Developed in collaboration with the Association for European Paediatric and Congenital Cardiology (AEPC). *Eur Heart J.* 2020; 41 (5): 655-720. doi: https://doi.org/10.1093/eurheartj/ehz467.
- de Luna AB, Baranchuk A. *Clinical arrhythmology*, 2nd ed. Wiley-Blackwell. 2017. p. 253.
- Bibas L, Levi M, Essebag V. Diagnosis and management of supraventricular tachycardias. *CMAJ.* 2016; 188(17-18): E466-E473. doi: 10.1503/cmaj.160079.
- Ziccardi MR, Goyal A, Maani CV. Atrial Flutter. *StatPearls [Internet].* 2021.

E-mail: amaralhamdi@yahoo.com

Received Dec. 1st 2020

Accepted Mar. 23rd 2021