

New record of chewing lice *Piagetiella titan* (Menoponidae: Mallophaga) Isolated from buccal cavity of White Pelican *Pelecanus onocrotalus* in Thi-Qar province-Southern Iraq

Zainab Abd-Ali Mohammad

Bio. Dep.- Coll. of Edu. for Pure Sci.- Thi-Qar Univ.

Summary:

In the present study the oral cavity of white pelican *Pelecanus onocrotalus* (collected from Al-Sanaf marsh southern Thi-Qar province, Iraq) was examined in the Biology department / College of Education for Pure Science / Thi-Qar University. A total of 23 chewing lice (10 males and 13 females) were collected from the oral cavity of *P. onocrotalus* bird and identified as *Piagetiella titan* during microscopical examination. The aim of this study is to give detailed information about *P. titan*, which was first found in Pelicans in Iraq to contribute parasitological fauna of Iraq.

Key words: *Piagetiella titan*, *Pelecanus onocrotalus*, buccal cavity, Thi-Qar province, Iraq

تسجيل جديد للقمل القارض (*Piagetiella titan* (Menoponidae: Mallophaga)

المعزول من التجويف الفمي للبعج الأبيض *Pelecanus onocrotalus* في محافظة ذي قار، جنوب العراق

زينب عبد علي محمد

قسم علوم الحياة-كلية التربية للعلوم الصرفة-جامعة ذي قار

الخلاصة:

فحص في الدراسة الحالية التجويف الفمي لطيور البجع الأبيض *Pelecanus onocrotalus* في قسم علوم الحياة/ كلية التربية للعلوم الصرفة/ جامعة ذي قار والتي جمعت من هور السناف جنوب محافظة ذي قار/العراق. تم جمع 23 من القمل القارض (10 ذكور و 13 انثى) من التجويف الفمي لطيور البجع الأبيض *Pelecanus onocrotalus* وشخصت من خلال الفحص المجهرى على انها *Piagetiella titan*. هدفت الدراسة الحالية الى اعطاء معلومات تفصيلية حول *P. titan* والتي عزلت لأول مرة في العراق ومن طيور البجع.

Introduction:

White pelicans *Pelecanus onocrotalus* are large water birds feeding by hunting fish and living usually in the marine and fresh water. This species and Dalmatian pelican *P. crispus* are the only species of the family Pelecanidae were reported from Iraq (Allose, 1960). The classification of the aquatic birds was confirmed by Dr. Mehna Kassem Habeeb/ Science College/ Basrah University. The study area Al-Sanaf marsh was located in the western north part of Al-Hammar marsh eastern south of Thi-Qar province. its area is nearly 250 km². It is used by many aquatic birds such as fish eating-birds. Many of snail and fish species were very common in these areas, it is used as important rural fisheries resources and had a very important ecological effects on man and animal parasites (Mohammad, 2013). The lice living on the bird order Pelecaniformes were found in the genera *Pectinopygus*, *Saemundssonina*, *Eidmanniella*, *Fregatiella*, *Austromenopon*, *Colpocephalum* and *Piagetiella* (Price *et al.*, 2003). The genus *Piagetiella* are interesting from an ecological standpoint, since they were principally found in the pouches of the hosts (Price, 1970). Hellenthal *et al.* (2004) listed chewing lice and their hosts in Belgium and reported *P. titan* on white pelicans. In France Seguy (1994) mentioned that the *P. titan* was seen in white pelicans and gave information about its morphological characteristics. Dik and Uslu (2006) recorded *P. titan* for the first time in Turkey from the buccal cavity of wounded white pelican *Pelecanus onocrotalus*, they found that the four sternit had a ctenidium in both sides, each second and third tibia had two stout subapical setae, in the female, terminalia had two slender lateral plates and the male genitalia was longer than 3 mm. Tavassoli *et al.* (2011) isolated *P. titan* from the buccal cavity of white pelican *P. onocrotalus* and they determined the frequency of infestations in white pelicans living in Urmia Lake, Iran. The aim of this study is to give detailed information about *P. titan*, which was first recorded in Iraq in Pelican birds to contribute parasitological fauna of Iraq.

Materials and Methods:

The oral cavity of white pelican *P. onocrotalus* (collected from Al-Sanaf marsh southern Thi-Qar province, Iraq) was examined in the Biology department / College of Education for Pure Science / Thi-Qar University. The isolated lice were put into a

tube with 70 % alcohol and cleared in lactofenol for a few days. They mounted on microscope slides. These slides were examined through microscope. The specimens were measured in millimeter photographed by using light microscope (Leica, Germany) provided with camera and drew by Camera Lucida (Novel, China). Lice were identified according Price (1970), Dik and Uslu (2006), Tavassoli *et al.* (2011).

Results:

A total of 23 lice (10 males and 13 females) were collected from the oral cavity of a white pelican, this lice species caused ulcerative lesions in the walls of oral cavity by their chewing mouth parts. The body of *P. titan* lice was dorso-ventrally flattened and its abdomen was much wider in females than that in males, but less sclerotized (Fig. 1, 2). The head was broad across temples (Fig. 3), the head with deep preocular slit, rounded front, antennae concealed beneath head, maxillary palpus with subterminal setae on last segment and the sclerite of hypopharynx was weakly developed. Occipital setae of female longer than that of female, The venter of each third femur with 4-5 well developed ctenidia. Thorax with triangular metasternal plates and the abdomen with undivided tergites and without anterior setae, the female tergites separate from pleurites, male with fusion at least on 4-6 segments. Tergal pigmentation of female with 3-6 dark medially and round spiracles, while 1-2 and 7-9 were lighter, in male with 2-5 mostly dark, while 1 and 8-9 were lighter, male with or without evident sterna sclerite on first segment, the venter of each third femur posed five ctenidia (Fig. 4) Female terminalia with slender lateral plates having posterior portion curving medially and the segments 7-8 with fused sternites, anus with greater number of anal setae and the dorsal finger setae more than ventral finger setae (Fig. 5). The structure of ventral female terminalia was the most distinguish feature of this species because it had straight stout lateral plates which much thinner and with posterior end curved medially, while male ventral terminalia 8-9 with fused sternites, male genitalia characterized with large size (Fig. 6), with large genital sac, anterior fourth with very short spinules followed posteriorly by longer spinules. In the present the dimensions of this lice species were done in millimeter, (Table 1), and male and female were and drew by Camera Lucida, (Fig. 7).

Table. (1). The morphological measurement of *P. titan* in mm.

No.	Character	Male			Female		
		Min.	Max.	Av.	Min.	Max.	Av.
1	Head length	0.50	0.75	0.73	0.51	0.59	0.54
2	Head width	1.00	1.18	1.03	1.03	1.22	1.08
3	Prothorax width	0.77	0.88	0.79	0.78	0.89	0.81
4	Metathorax width	1.09	0.20	1.13	1.08	1.23	1.10
5	Thorax length	1.33	1.40	1.35	1.30	1.38	1.35
6	Abdomen length	3.10	4.00	3.19	3.07	4.00	3.83
7	Total length	5.00	6.12	5.41	4.93	6.14	5.53




Fig .1: Male

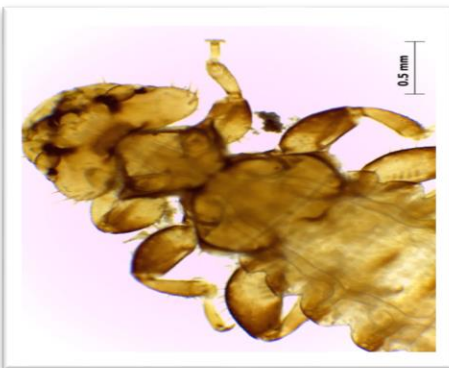


Fig.2: Female

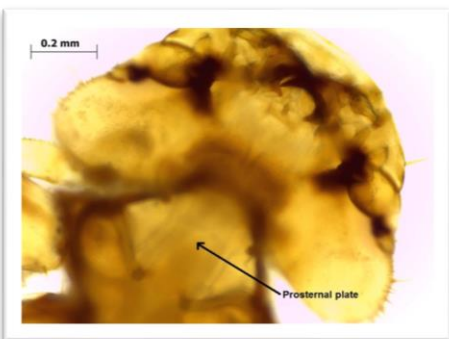


Fig.3: The head

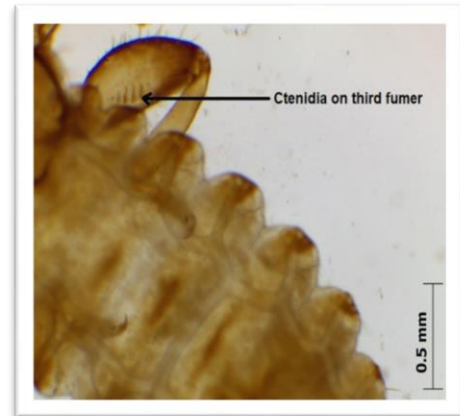


Fig .4: Third fumer



Fig .5: Female posterior end

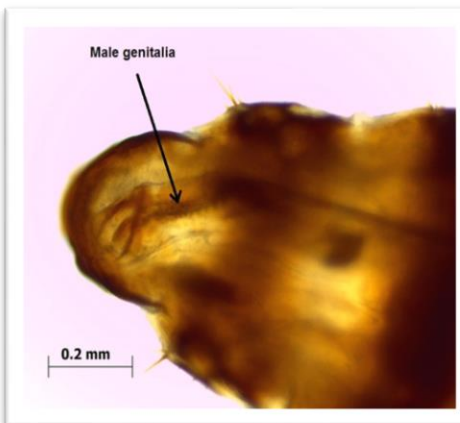


Fig.6: Male posterior end

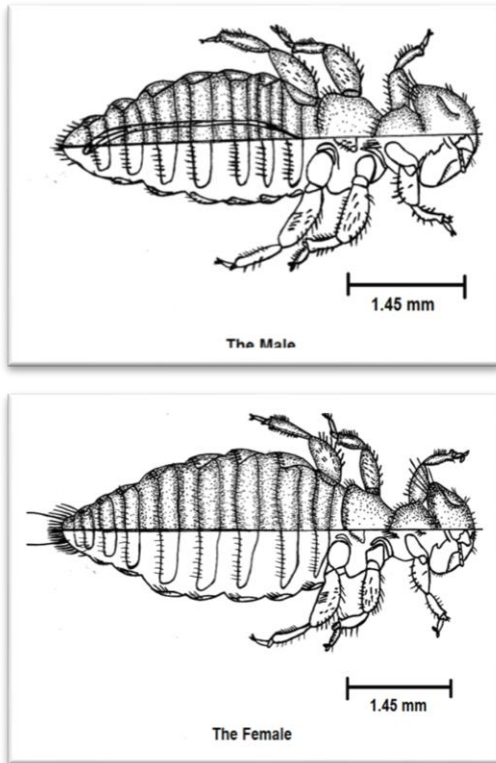


Fig.7: Camera Lucida drawing for male and female of *P. titan*.

Discussion:

The chewing lice infested pelicans were *Pectinopygus forficulatus*, *Colpocephalum eucarenum* and *P. titan*, the third species only was found in oral cavity, while the others on feathers (Dalglish, 2006). The pelican lice *P. titan* and its morphological characteristics were described for the first time by Price (1970) and he revealed that these lice were among some of the larger forms, ranging in length from 4 to 6 mm and with little sexual dimorphism except that associated with generally darker pigmentation and possession of apical tibial processes by the male. According to Price *et al.* (2003) the main characteristics of *P. titan* which distinguish it from other species were the both sides of the fourth sternit with a short and well-developed ctenium, the second and third tibia with two stout subapical setae on ventral sides, every stigma with at least one setae, in female the ventral terminalia with slender, curving lateral plates and in male genitalia being longer than 3 mm. Dik and Uslu (2006) found that the second and third tibia had two stout subapical setae, the venter of third femur with 5 ctenidae, but in some specimens, it was observed 6 ctenidae, the female,

terminalia had two slender lateral plates and the male genitalia was longer than 3 mm. The current study found that the morphological characteristics were agreed with previous studies as Price (1970), Dik and Uslu (2006) and Tavassoli *et al.* (2011). According to Price (1970), some dimensions of this species were; Preocular width: 0.85-0.88 mm, temple width: 1.10-1.18 mm, prothorax width: 0.90-0.94 mm, metathorax width: 1.15-1.26 mm, total length: 5.61-6.03 mm. Dik and Uslu (2006) showed some morphological measurements in *P. titan* males: head length (0.5-0.6) 0.57 mm, head width (temple) (1.13-1.24) 1.17mm, head index (1.93-2.25) 2.05 mm, prothorax width (0.86-0.91) 0.89 mm, metathorax width (1.13-1.27) 1.20 mm, thorax length (1.38-1.47) 1.42 mm, abdomen length (3.87-4.29) 4.12 mm, total length (5.92-6.28) 6.11 mm, females head length (0.54-0.61) 0.57 mm, head width (temple) (1.12-1.27) 1.20 mm, head index (2.07-2.22) 2.12 mm, prothorax width (0.87-0.91) 0.90 mm, metathorax width (1.16-1.26) 1.21mm, thorax length (1.25-1.41) 1.32 mm, abdomen length (2.79-4.18) 3.67 mm, total length (4.65-6.42) 5.74 mm. The fact that the adults of *P. titan* chewing lice were located within the pouch and protected from preening, might favor the development of large populations of this lice on pelicans, the heavy populations of lice may exert a serious effect on sick, captive or birds (Tavassoli *et al.*, 2011). In this study the large chewing mouth parts *P. titan* caused some ulcerative lesions in the oral cavity tissues of bird. Tavassoli *et al.* (2011) reported that the *P. titan* can produce a severe hemorrhagic stomatitis as evidenced in white pelicans. This lesion might cause significant blood loss, and would provide a potential portal of entry for other pathogens. Samuel *et al.* (1982) reported ulcerative lesions on the body of naked birds approximately 1 week of age and in the throat pouches of older juveniles (2-7 weeks old) of infested pelicans to be due to *P. peralis*.

References:

- Dalglish, R.C. (2006). Birds and their associated chewing lice. Pelecanidae-Pelicans; <http://www.phthiraptera.org/Birds/Pelecanidae.html>.
- Dik, B. and Uslu, U. (2006). The First Recording of *Piagetiella titan* (Menoponidae: Mallophaga) on a White Pelican (*Pelecanus onocrotalus*, Linnaeus) in Turkey. *Turk. Parasitol. Dergisi J.*, 30: 128-131.

- Price, R. D. (1970). The *Piagetiella* (Mallophaga: Menoponidae) of the Pelecaniformes. *Can. Ent. J.*, 102: 389-404.
- Price, R. D.; Hellenthal, R. A.; Palma, R. L. and Johnson, K. P. (2003). Clayton, DH. The Chewing Lice: World Checklist and Biological Overview. Illinois Natural History Survey Special Publication.
- Mohammed, K. H. (2013). The environmental impacts of reviving Hor Al-Sanaf by the water of the river of out fall drain in the province of Thi- Qar. *Basic Edu. Coll. J. Babylon Univ.*, 12: 291-311. (In Arabic).
- Samuel, W. M.; Williams, E.S. and Blair, A. B. (1982). Infestation of *Piagetiella peralis* (Menoponidae: Mallophaga) on juvenile white pelicans (*Pelecanus onocrotalus*, Linneaus). *Can. J.Zoo.* 60: 951-953.
- Seguy, E. (1944). Faune de France. 43. Insectes Ectoparasites (Mallophages, Anoploures, Siphonaptères). Paris. (English summary).
- Tavassoli, M. Salmanzadeh, R. and Jabbari, H. (2011). Infestations of (Menoponidae: Mallophaga) on juvenile white pelicans (*Pelecanus onocrotalus* L.) in Urmia Lake National Park, northwest Iran. *Int. J. Vet. Res.*, 5: 105-108.